


CASE REPORT

Desmoid fibromatosis in the pharyngeal wall: A case report and literature review

Katharina Geisenhainer¹ | Daniela Klenke² | Norman Moser³ | Oliver Kurbad⁴ | Felix Bremmer⁵ | Philipp Kauffmann³ | Henning Schliephake³ | Philipp Brockmeyer³ 

¹Department of Oral and Maxillofacial Surgery, University Medical Center Greifswald, Greifswald, Germany

²Department of Orthodontics, University Medical Center Goettingen, Goettingen, Germany

³Department of Oral and Maxillofacial Surgery, University Medical Center Goettingen, Goettingen, Germany

⁴Department of Prosthodontics, University Medical Center Goettingen, Goettingen, Germany

⁵Institute of Pathology, University Medical Center Goettingen, Goettingen, Germany

Correspondence

Philipp Brockmeyer, Department of Oral and Maxillofacial Surgery, University Medical Centre Goettingen, Robert-Koch-Str. 40, D-37075 Goettingen, Germany.
Email: ph.brockmeyer@gmail.com

Funding information

We acknowledge the support by the Open Access Publication Funds of the University of Goettingen

Abstract

Desmoid fibromatosis (DF) is one of the rarest locally aggressive growing benign tumor entities. We present an overview of the literature and a rare clinical case of a 22-year-old female patient, who was diagnosed with aggressive DF in the left pharyngeal wall at the age of 4 years old.

KEYWORDS

desmoid fibromatosis, head and neck region, malocclusion

1 | INTRODUCTION AND LITERATURE REVIEW

Desmoid fibromatosis (DF) is a rare and aggressively growing benign tumor entity derived from connective tissues. DF shows no metastatic potential but the tendency for local invasion and a high rate of recurrences (30%–60%).^{1–4} The incidence of DF is about 2–4 cases per million population and accounts for 0.3% of all neoplasms.² In principle, DF can occur in any part of the body.⁵ About 15% of all DF cases are located in the head and neck region; it is more common in children than in adults.⁶ Common predilection sites are the maxillary sinus and the mandible. The cranial location of DF is mostly associated with nonspecific symptoms like nasal obstruction and epistaxis.⁴

Fibromatosis colli (FC) is a childhood form of DF with yet unknown etiology that occurs most often in the sternocleidomastoid muscle.^{7–9} The prevalence is approximately 0.4% of live births; it is associated with birth trauma, difficult delivery, or breech birth in >60%–90% of cases.⁷ Here, the possible underlying mechanisms are traumatic neck compression during childbirth leading to pressure necrosis or occlusion of the venous drainage system with subsequent development of muscular edema and fibrosis.^{7,9} A scar-like response to these lesions of the sternocleidomastoid muscle (in rare cases of the trapezius muscle) in the last trimester of pregnancy or during childbirth is assumed.⁷ A genetic component is likely as 11% of patients report a positive family history. Symptoms typically occur only 10–14 days after birth, and some tumors may

This is an open access article under the terms of the Creative Commons Attribution-NonCommercial License, which permits use, distribution and reproduction in any medium, provided the original work is properly cited and is not used for commercial purposes.

© 2022 The Authors. *Clinical Case Reports* published by John Wiley & Sons Ltd.

regress after a few months.⁷ Its symptoms include torticollis with ipsilateral rotation and inclination due to infiltration of the sternocleidomastoid muscle (in 14%–30%).^{7,9} Additionally, facial and cranial asymmetry may develop with the reduced size on the affected side. Other associated congenital anomalies are developmental dysplasia of the hip, rib anomalies, talipes equinovarus, thoracic scoliosis, metatarsus adductus, mental retardation, and seizure disorders.¹⁰

Desmoid fibromatosis often appears in association with familial adenomatous polyposis (FAP) syndrome and Gardner's syndrome (GS).^{2,7} The risk of developing familial DF is 1000-fold higher in FAP patients than in healthy individuals.^{2,7} As many as 5%–15% of FAP-induced DF cases are associated with mutations of the Wnt/APC/ β -catenin signaling pathway and specific gene mutations located on the chromosome 5q21–5q22.¹¹ In most cases, DF appears sporadically and is frequently (in 64% of cases) associated with somatic mutations in the CTNNB1 gene, a common Wnt pathway activator.¹¹ Moreover, mutations of T41A, S45F, and S45P genes are DF specific. Data suggest that mutations in the S45F gene are associated with a higher recurrence rate after primary surgery.¹²

Desmoid fibromatosis in pediatric patients was shown to be associated with *AKT1* (31%), *BRAF* (19%), and *TP53* (9%) gene mutations. The polymorphism Q472H *VEGFR* was found in pediatric (56%) and adult (40%) DF cases.¹³ Trautmann et al. described new DF-associated mutations including mutations in *AKT1* (G311S/D and T312I), *ALK* (R806H and G924S), *AR* (A159T), *EGFR* (P848L), *ERBB2* (H174Y), *IDH2* (H354Y), *KIT* (V559D), *RET* (T1038A), *SDHA* (R325 M), and *SDHD* (R115W) with imatinib-sensitive *KIT*(V559D).¹⁴

In addition to molecular and genetic changes, high estrogen levels during pregnancy, oral contraceptive medication, and previous surgery and trauma are known to be the most common risk factors.^{2,3}

Computed tomography (CT) and magnetic resonance imaging (MRI) are the most commonly used three-dimensional imaging techniques for DF detection.^{7,8} In MRI, a linear extension of the lesion along the fascial plane is characteristic.⁷ MRI imaging is the diagnostic method of choice. The characteristics of fibromatosis are infiltrative margins, low or medium signal intensity at all pulse sequences, and low-signal-intensity bands representing highly collagenized tissue.⁸

Fibromatosis colli diagnosis is primarily performed by ultrasound imaging (US) to reduce any radiation exposure during childhood.^{7,9} Focal or diffuse enlargement in the lower two-thirds of the sternocleidomastoid muscle is a typical US sign of FC.⁷ In FC radiographs, lytic lesions in the clavicular head at the base of the sternocleidomastoid

muscle can be found. These can be associated with skeletal anomalies such as ipsilateral lateral mandibular asymmetry, cervicothoracic scoliosis, facial deformity, hypertrophy of the ipsilateral mastoid process, and ipsilateral elevation of the clavicle or shoulder.^{7,15} Consideration of these specific FC imaging features can avoid unnecessary tissue biopsies.

Owing to the low prevalence of DF, there is no generally established treatment. Individual interdisciplinary therapeutic decisions depend on clinical behavior and tumor localization.¹⁶ The commonly preferred treatment option for DF is surgical tumor resection.³ Recent data show that clinical observation is an option for symptom-free patients, given the significant side effects of surgical therapy.¹⁷ Even in spite of adequate resection margins, the recurrence rate after resection is approximately 30%, which makes adjuvant therapies essential.^{18,19} Both neoadjuvant and adjuvant radiotherapies are central strategies in the treatment of DF.¹⁷ Several studies report evidence for the effectiveness of radiotherapy in the treatment of aggressive fibromatosis.^{18,20} When the tumor becomes symptomatic or leads to functional impairment, a wide range of additional therapy options are discussed.¹⁷ Moreover, hormone therapy (tamoxifen), nonsteroidal anti-inflammatory drugs, chemotherapy, and tyrosine kinase inhibitors (imatinib and sorafenib) are among the treatment options to ensure long-term tumor control.^{17,21} Recent findings on the Wnt/ β -catenin-dependent-signaling pathway in DF have shown that CTNNB1 gene mutations have a prognostic impact and might be associated with an improved therapeutic response.^{22,23} Recent immunohistochemical investigations have shown that PDGFR and COX-2 overexpression in DF and the treatment of adult patients with sorafenib and celecoxib have resulted in tumor regression and 2-year progression-free survival in 81% of patients.¹⁶

Fibromatosis colli is primarily treated conservatively with clinical follow-ups and serial stretching exercises.^{7,24,25} Most lesions and secondary contractures spontaneously regress in 70%–90% of cases.⁷ In 10%–15% of cases, FC is severely therapy refractory: Surgical intervention in terms of the proximal or distal relief of the sternocleidomastoid muscle is necessary.⁷ More recently, botulinum toxin type A has been used to treat refractory FC cases and to prevent surgical intervention.^{7,10} In some studies, the treatment with methotrexate plus vinblastine, administered every 7–10 days over several months, led to long-term stability in advanced aggressive fibromatosis.²⁶ Pegylated liposomal doxorubicin is another chemotherapeutic option for the treatment of aggressive fibromatosis.²⁷ Retrospective data on the VAC (vincristine, actinomycin, and cyclophosphamide) therapy regime propose a high response rate in tumors with mesenchymal

origin.²⁸ By inhibiting PDGFRB kinase activity, imatinib is another effective agent for the treatment of FC.²⁹

2 | CASE PRESENTATION

A 22-year-old female patient was diagnosed with aggressive DF at the age of 4 years old in 2002 due to a swelling in the neck region. The primary manifestation was localized in the left pharyngeal wall. DF was surgically removed with an additional neck dissection of the upper two lymph node levels.

After one year of disease-free survival (DFS), a local recurrence on the left neck was histologically confirmed. After treatment discussion in an interdisciplinary tumor board, chemotherapy following the VAC therapy regime was performed over 5 months. The treatment reduced the rate of tumor growth.

Three years after the end of chemotherapy, the patient developed a second local recurrence. Chemotherapy was restarted for 42 more cycles. After completion of chemotherapy, a tumor mass reduction surgery was performed.

After two further years of DFS, a large recurrence occurred in 2014 with mediastinal extensions. Accordingly, another tumor resection surgery of the left neck was

performed. This was followed by adjuvant regional radiotherapy with up to 50.4 Gy of radiation.

After another 2 years of DFS (2016), the patient introduced herself to the interdisciplinary malocclusion consultation for assessment. Three-dimensional X-rays and soft-tissue images were obtained for evaluation and surgical planning. Over the course of the disease, the patient had developed extensive skeletal Angle's class II malocclusion with an additional anterior open bite and a transverse tightness in the upper jaw (Figure 1).

The patient indicated a high level of suffering and wished for skeletal correction. She was aware of the whole therapeutic concept (duration, individually planned operations, and orthodontic pre- and post-treatment).

After primary orthodontic treatment, a surgically supported enlargement of the palate was performed in 2017. After three years of further orthodontic therapy, the final bimaxillary osteotomy was planned. For preoperative planning, a CT scan of the skull was performed (Figure 2). The scan revealed a new solid retromaxillary tumor mass with a dimension of axial 2.4×2.8 cm, craniocaudal max. 5 cm. The tumor bulged into the left maxillary sinus and beyond the lateral left orbit. In addition, advanced osteoarthritis of the left TMJ and a retrognathia with the receding chin were diagnosed.

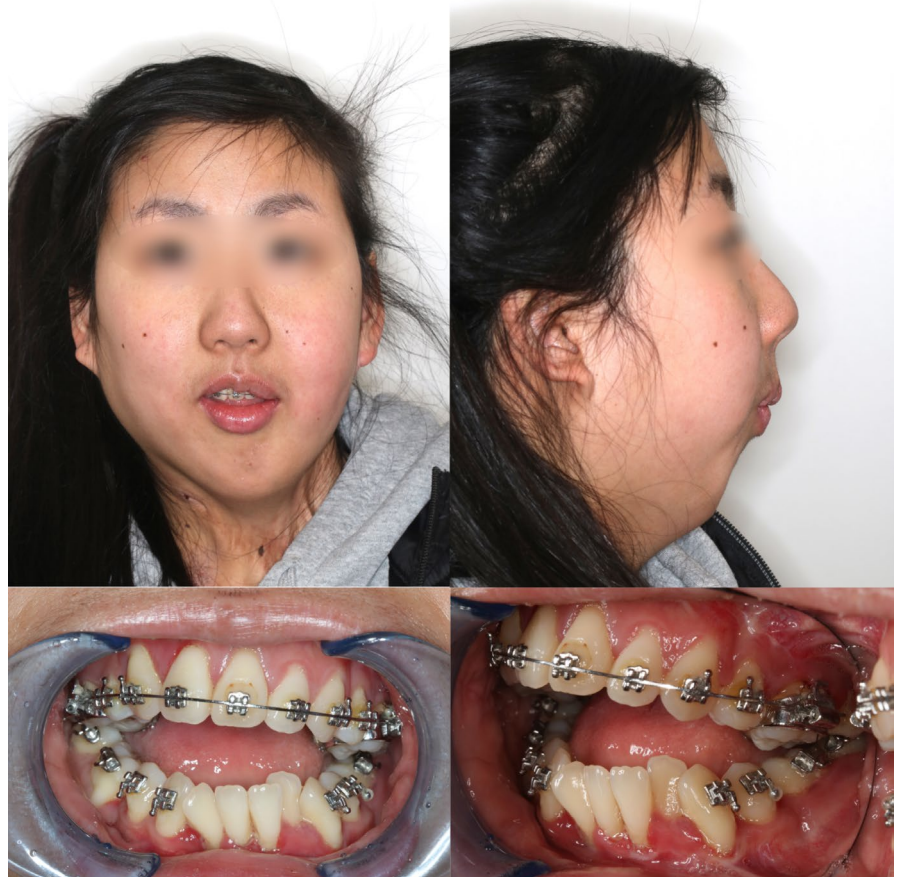

FIGURE 1 Clinical aspect and extent of skeletal malocclusion

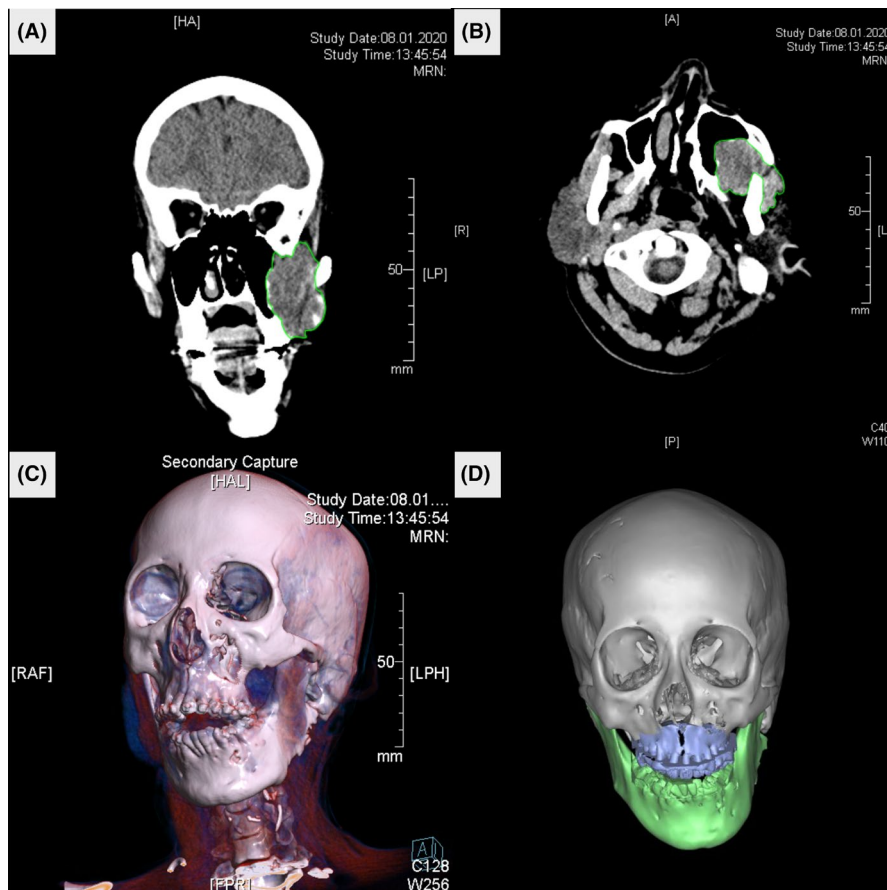


FIGURE 2 CT imaging in coronal (A) and axial (B) plane. The well-delimited and heterogenous lesion (green line) did not cause bone invasion or metastases. Three-dimensional reconstruction shows the extent of skeletal malocclusion (C). Three-dimensional reconstruction with segmentation for digital osteotomy planning (D)

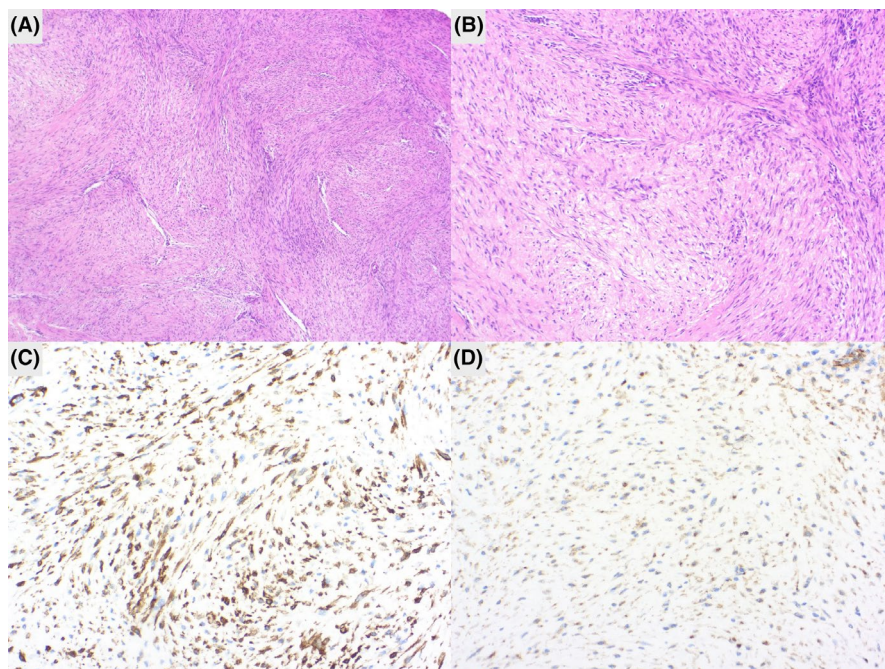


FIGURE 3 Histological examination of the tumor mass. A Hematoxylin and eosin staining (overview image, ×100 magnification). B Hematoxylin and eosin staining (enlarged view, ×400 magnification). C Actin expression (IHC analysis, ×400 magnification). D β-catenin expression (IHC analysis, ×400 magnification)

The planned bimaxillary osteotomy was postponed, and a tumor biopsy was performed (Figure 3). Histological examination of the tissue material with additional molecular pathological analyses confirmed a recurrence with a CTNNB1 mutation in exon 3.

Henceforth, a combined tumor resection and bimaxillary osteotomy were planned with additional bilateral TMJ resection and reconstruction using rib grafts. Moreover, resection of the extensive scar tissue of the neck was planned with a local plastic defect reconstruction. After a detailed

consultation, the patient only decided on tumor resection with subsequent prosthodontic defect rehabilitation.

In 2020, tumor resection was successfully performed via osteotomy at the Le Fort I level. An esthetic prosthodontic reconstruction was postoperatively performed without functional improvement. Since then, the patient presented herself to the tumor follow-up care and has been tumor-free so far.

3 | DISCUSSION

Desmoid fibromatosis shows a locally aggressive growth without any metastatic potential. This study describes a severe case where the tumor mass was located in the lateral pharyngeal wall. There is only one more case report of aggressive fibromatosis in the pharynx⁵ and DF in the submandibular region.³⁰

So far, the commonly preferred treatment option is surgical tumor resection.³ Therapy for DF should be based on an interdisciplinary decision at an early stage of disease in which a variety of factors must be taken into account. A precise diagnosis using imaging, histological, and immunopathological evaluations should be performed. Owing to slow tumor growth and minor symptoms, new therapeutic options with few side effects (hormone therapy and anti-inflammatory therapy) should be primarily considered for severe cases, to prevent potentially difficult-to-correct extensive growth disorders. However, a primary surgery with negative surgical margins shows the best outcome for patients due to the high recurrence rate.³¹

4 | CONCLUSIONS

Desmoid fibromatosis can occur in atypical anatomical locations of the head and neck region and can lead to malfunctions during skull skeletal development. Alternative therapeutic approaches may be the favorable alternatives in the case of purely locally spreading DF diseases.

ACKNOWLEDGMENTS

None.

CONFLICT OF INTEREST

The authors declare that they have no conflicts of interests.

AUTHOR CONTRIBUTIONS

KG and PB are mainly responsible for writing the manuscript. DK, NM, and OK are mainly responsible for data collection. FB is responsible for histological examination and immunohistochemical staining. PK and HS revised the manuscript.

CONSENT

Written informed consent was obtained from the patient to publish this report in accordance with the journal's patient consent policy.

DATA AVAILABILITY STATEMENT

Data from this case report can be obtained by consulting the corresponding author.

ORCID

Phillipp Brockmeyer  <https://orcid.org/0000-0003-3694-2828>

REFERENCES

1. Barthel M, Halsband H. *Aggressive Fibromatosis in Childhood*. Springer Berlin Heidelberg; 1996:1108-1111.
2. Ganeshan D, Amini B, Nikolaidis P, Assing M, Vikram R. Current Update on desmoid fibromatosis. *J Comput Assist Tomogr*. 2019;43(1):29-38.
3. Skapek SX, Ferguson WS, Granowetter L, et al. Vinblastine and methotrexate for desmoid fibromatosis in children: results of a Pediatric Oncology Group Phase II Trial. *J Clin Oncol*. 2007;25(5):501-506.
4. Thompson LDR. Desmoid-type fibromatosis. *Ear Nose Throat J*. 2021;100(5_suppl):518S-519S.
5. Lu D, Yang H, Chen F, Zhao Y. Aggressive fibromatosis (desmoid tumour) of the pharynx. *ANZ J Surg*. 2011;81(10):734-736.
6. Sargar KM, Sheybani EF, Shenoy A, Aranake-Chrisinger J, Khanna G. Pediatric fibroblastic and myofibroblastic tumors: a pictorial review. *Radiographics*. 2016;36(4):1195-1214.
7. Murphey MD, Arcara LK, Fanburg-Smith J. From the archives of the AFIP: imaging of musculoskeletal liposarcoma with radiologic-pathologic correlation. *Radiographics*. 2005;25(5):1371-1395.
8. Robbin MR, Murphey MD, Temple HT, Kransdorf MJ, Choi JJ. Imaging of musculoskeletal fibromatosis. *Radiographics*. 2001;21(3):585-600.
9. Wojcicki KM, Krieger RH, Berry AC, Reuther WL 3rd. Fibromatosis colli spuriously presenting as a retropharyngeal mass on cervical spine radiographs. *Intern Emerg Med*. 2016;11(2):277-279.
10. Khalid S, Zaheer S, Wahab S, Siddiqui MA, Redhu N, Yusuf F. Fibromatosis colli: a case report. *Oman Med J*. 2012;27(6):e011.
11. Penel N, Chibon F, Salas S. Adult desmoid tumors: biology, management and ongoing trials. *Curr Opin Oncol*. 2017;29(4):268-274.
12. Lazar AJ, Tuvin D, Hajibashi S, et al. Specific mutations in the beta-catenin gene (CTNNB1) correlate with local recurrence in sporadic desmoid tumors. *Am J Pathol*. 2008;173(5):1518-1527.
13. Meazza C, Belfiore A, Busico A, et al. AKT1 and BRAF mutations in pediatric aggressive fibromatosis. *Cancer Med*. 2016;5(6):1204-1213.
14. Trautmann M, Rehkemper J, Gevensleben H, et al. Novel pathogenic alterations in pediatric and adult desmoid-type fibromatosis - A systematic analysis of 204 cases. *Sci Rep*. 2020;10(1):3368.
15. Ablin DS, Jain K, Howell L, West DC. Ultrasound and MR imaging of fibromatosis colli (sternomastoid tumor of infancy). *Pediatr Radiol*. 1998;28(4):230-233.

16. Robles J, Keskinyan VS, Thompson M, Davis JT, Mater DV. Combination therapy with sorafenib and celecoxib for pediatric patients with desmoid tumor. *Pediatr Hematol Oncol*. 2020;37(5):445-449.
17. Skubitz KM. Biology and treatment of aggressive fibromatosis or desmoid tumor. *Mayo Clin Proc*. 2017;92(6):947-964.
18. Hong AM, Jones D, Boyle R, Stalley P. Radiation therapy as an alternative treatment for desmoid fibromatosis. *Clin Oncol (R Coll Radiol)*. 2018;30(9):589-592.
19. Nath MC, Torbenson MS, Erickson LA. Desmoid tumor. *Mayo Clin Proc*. 2018;93(4):549-550.
20. Nuytens JJ, Rust PF, Thomas CR Jr, Turrisi AT 3rd. Surgery versus radiation therapy for patients with aggressive fibromatosis or desmoid tumors: a comparative review of 22 articles. *Cancer*. 2000;88(7):1517-1523.
21. Janinis J, Patriki M, Vini L, Aravantinos G, Whelan JS. The pharmacological treatment of aggressive fibromatosis: a systematic review. *Ann Oncol*. 2003;14(2):181-190.
22. Martínez Trufero J, Pajares Bernad I, Torres Ramón I, Hernando Cubero J, Pazo CR. Desmoid-type fibromatosis: who, when, and how to treat. *Curr Treat Options Oncol*. 2017;18(5):29.
23. Timbergen MJM, Smits R, Grünhagen DJ, Verhoef C, Sleijfer S, Wiemer EAC. Activated signaling pathways and targeted therapies in desmoid-type fibromatosis: a literature review. *Front Oncol*. 2019;9:397.
24. Lowry KC, Estroff JA, Rahbar R. The presentation and management of fibromatosis colli. *Ear Nose Throat J*. 2010;89(9):E4-8.
25. Oliveira JC, Abreu MS, Gomes FM. Sternocleidomastoid tumour in neonate: fibromatosis colli. *BMJ Case Rep*. 2018;2018(bc r2017223543):1-2.
26. Azzarelli A, Gronchi A, Bertulli R, et al. Low-dose chemotherapy with methotrexate and vinblastine for patients with advanced aggressive fibromatosis. *Cancer*. 2001;92(5):1259-1264.
27. Gega M, Yanagi H, Yoshikawa R, et al. Successful chemotherapeutic modality of doxorubicin plus dacarbazine for the treatment of desmoid tumors in association with familial adenomatous polyposis. *J Clin Oncol*. 2006;24(1):102-105.
28. Schütte J, Stamatis G, Taeger G, Hartmann KA. Weichteilsarkome des erwachsenen. *Best Pract Onkol*. 2009;4(2):16-34.
29. Heinrich MC, McArthur GA, Demetri GD, et al. Clinical and molecular studies of the effect of imatinib on advanced aggressive fibromatosis (desmoid tumor). *J Clin Oncol*. 2006;24(7):1195-1203.
30. Roychoudhury A, Parkash H, Kumar S, Chopra P. Infantile desmoid fibromatosis of the submandibular region. *J Oral Maxillofac Surg*. 2002;60(10):1198-1202.
31. Buitendijk S, van de Ven CP, Dumans TG, et al. Pediatric aggressive fibromatosis: a retrospective analysis of 13 patients and review of literature. *Cancer*. 2005;104(5):1090-1099.

How to cite this article: Geisenhainer K, Klenke D, Moser N, et al. Desmoid fibromatosis in the pharyngeal wall: A case report and literature review. *Clin Case Rep*. 2022;10:e05268. doi:[10.1002/ccr3.5268](https://doi.org/10.1002/ccr3.5268)