

# ANGIOGRAPHIC SMOKESTACK LEAKAGE NOT ASSOCIATED WITH CENTRAL SEROUS CHORIORETINOPATHY

Bahaeddin A. El Khatib, MD,\* Carl W. Noble, DO,\* Luke Chang, MD,† Lily Im, MD,† Marena Patronas, MD\*

**Purpose:** To report a series of cases with smokestack leakage on fundus fluorescein angiography outside the clinical setting of central serous chorioretinopathy.

**Methods:** A multicenter, observational retrospective case series evaluating fundus fluorescein angiography on Topcon and Optos systems.

**Results:** Seven patients with neovascularization due to ischemic retinopathy demonstrated a unique smokestack pattern of angiographic leakage. The patients' ages ranged between 44 and 71 years and were seen at 3 academic teaching hospitals in the Washington–Baltimore metropolitan area. Five patients had been diagnosed with proliferative diabetic retinopathy, one with sickle cell ischemic retinopathy, and one with branch retinal artery occlusion; none of the patients had a known history or clinical signs of current or past central serous chorioretinopathy.

**Conclusion:** This is the first published case series to the author's knowledge of ischemic retinopathy displaying a smokestack leakage pattern on fundus fluorescein angiography that is classically described with idiopathic central serous chorioretinopathy.

**RETINAL CASES & BRIEF REPORTS** 16:643–648, 2022

*From the \*Department of Ophthalmology, the George Washington University, Washington, District of Columbia; and †Department of Ophthalmology, the University of Maryland, Baltimore, Maryland.*

Central serous chorioretinopathy (CSCR) serous detachments of the neurosensory retina typically display focal areas of leakage from the retinal pig-

None of the authors has any financial/conflicting interests to disclose.

There was no funding received for this work from any of the following organizations: National Institutes of Health (NIH), Wellcome Trust, Howard Hughes Medical Institute (HHMI), and other(s).

This is an open-access article distributed under the terms of the Creative Commons Attribution-Non Commercial-No Derivatives License 4.0 (CCBY-NC-ND), where it is permissible to download and share the work provided it is properly cited. The work cannot be changed in any way or used commercially without permission from the journal.

Reprint requests: Bahaeddin A. El Khatib, MD, Department of Ophthalmology, the George Washington University, 2150 Pennsylvania Avenue NW, Washington, DC 20037; e-mail: baha.elkhatib@gmail.com

ment epithelium into the subretinal space in two patterns, “ink blot” or the less common “smokestack” pattern.<sup>1</sup> Smokestack leakage on fundus fluorescein angiography (FFA) is considered a near pathognomonic sign seen in CSCR. It is described as progressive hyperfluorescence that spreads beyond the borders of the defect in a linear configuration. It is significantly more common in primary acute episodes and usually develops early in the acute phase of the disease. The smokestack leakage pattern is described by the direction of the leakage with the ascending type being the most common (94.28%), although the size and extent of the leakage varies. The reported prevalence of smokestack leakage in CSCR varies from 7% to 29%.<sup>2</sup> To the authors' knowledge there have been no reports describing a smokestack leakage pattern outside the clinical setting of CSCR. This retrospective case series reports seven cases of ischemic retinopathy displaying a smokestack leakage pattern on FFA outside the clinical setting of idiopathic CSCR.

## Methods

This study was a multicenter, observational retrospective chart review of patients with ischemic retinopathy evaluated between July 2016 and January 2020. All fundus photographs and angiograms were performed using the Optos widefield 200Tx and Topcon TRC 50 DX retinal camera. Institutional review board and ethics committee approval was obtained at each of the individual centers in compliance with the Declaration of Helsinki. In each patient, we performed a complete clinical ophthalmological examination and obtained ocular coherence tomography, fundus photographs, and fluorescein angiography. Proper fixation was ascertained by direct observation of the fovea through the fundus camera. For fluorescein angiography, 5 mL of a 10% fluorescein in sterile aqueous solution was injected into the cubital vein. Digital images were recorded for a minimum of 5 minutes after injection and analyzed. The diagnostics and treatment interventions were performed by one retina specialist.

## Results

### Case 1

A 68-year-old White man with type 2 diabetes mellitus (T2D) and an ocular history of proliferative diabetic retinopathy (PDR) without macular edema status after panretinal photocoagulation (PRP) in both eyes, presented to the eye clinic for scheduled routine examination with no new eye complaints or concerns. On examination, his best-corrected visual acuity (BCVA) was 20/25 in both eyes, the intraocular pressure was within normal limits, and anterior segment examinations were unremarkable. Fundus examination displayed neovascularization of the right optic nerve (NVD), with regression of previously noted NVD of the left optic nerve.

Fundus fluorescein angiography of the right eye revealed leakage of the superior aspect of the optic nerve ascending vertically into the vitreous cavity confirming NVD (Figure 1). No active leakage was noted in the left eye. Optical coherence tomography (OCT) did not reveal any central, intra, or subretinal fluid.

The patient was treated with PRP in the right eye, followed by intravitreal bevacizumab until complete resolution of NVD was achieved.

### Case 2

A 48-year-old African man with sickle cell trait and an ocular history of enucleation related to traumatic

glaucoma in the left eye and proliferative sickle cell retinopathy in the right eye status post-PRP and laser retinopexy for a retinal tear in the right eye. He presented for a routine fundus examination. On examination, the BCVA was 20/20-1, intraocular pressure was within normal limits, and anterior segment examinations were unremarkable. On fundoscopic examination there was concern for neovascularization (NVE) in the superior mid periphery, and FFA confirmed an early pinpoint area of superior hyperfluorescent leakage consistent with NVE. It was noted that the leakage expanded vertically into the vitreous cavity in the late phase (Figure 2). In addition, extensive peripheral capillary nonperfusion was noted. Optical coherence tomography at this time did not reveal any central, intra, or subretinal fluid. It was recommended that the patient receive a series of intravitreal anti-vascular endothelial growth factor (VEGF) treatments, fill in PRP, or combination of the two. After discussion, the patient refused intervention and was lost to follow-up.

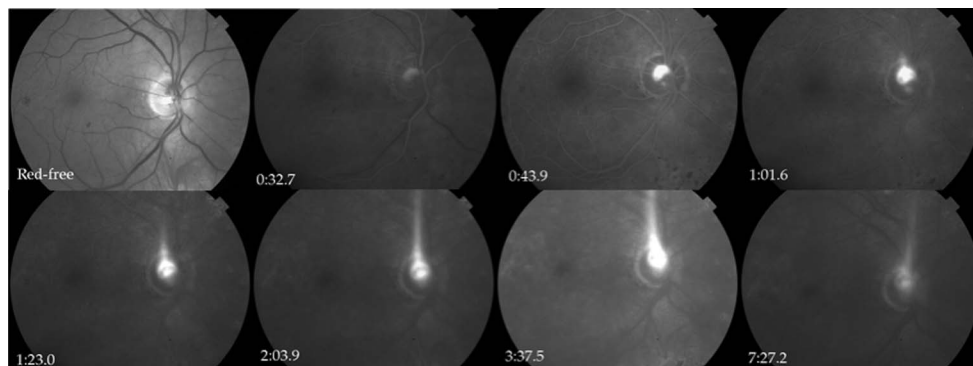
### Case 3

A 47-year-old African American woman with T2D and an ocular history of hypertensive retinopathy and inferior temporal branch retinal artery occlusion in the right eye presented to the retina clinic for scheduled follow-up. On examination, the BCVA was 20/80-2 in the right eye and 20/25-2 in the left eye, intraocular pressure was within normal limits, and anterior segment examinations were unremarkable. Fundus examination of the right eye showed mild nerve pallor, a central foveal pigmented subretinal scar, and significant arteriolar sclerosis and concern for NVE along the inferior temporal arcade (ITA); the left eye was relatively unremarkable.

Further workup with FFA confirmed NVE along the ITA with demonstration of an area of broad hyperfluorescent leakage that extended vertically into the vitreous cavity (Figure 3). Optical coherence tomography did not reveal any central, intra, or subretinal fluid. This patient was recommended to undergo intravitreal anti-VEGF therapy, PRP fill in, or combination therapy but was lost to follow-up.

### Case 4

A 65-year-old White man with T2D and an ocular history of PDR in both eyes related to T2D status post-PRP and multiple intravitreal anti-VEGF injections in both eyes, presented for routine follow-up. On examination, the BCVA was 20/40 in the right eye and 20/30 in the left eye, the intraocular pressure was within normal limits, and anterior segment examination was



**Fig. 1.** Fundus fluorescein angiography of the right eye displays gradual enlargement of hyperfluorescence along the superior aspect of the optic nerve head with leakage extending vertically into the vitreous cavity during the late phase.

unremarkable. Fundus examination of the right eye displayed scattered intraretinal hemorrhages and NVE along the ITA. Fundus examination of the left eye remained unchanged. Fundus fluorescein angiography revealed leakage along the ITA with vertical extension into the vitreous cavity of the right eye confirming NVE, in addition to microaneurysms in both eyes (Figure 4). Optical coherence tomography did not reveal any central, intra, or subretinal fluid.

One week after presentation, PRP was performed in the right eye. The patient was also scheduled for intravitreal bevacizumab injection and subsequent repeat FFA, but he was lost to follow-up.

#### Case 5

A 44-year-old African woman with T2D and an ocular history of PDR in both eyes and macular edema in the left eye status post-PRP in both eyes, multiple intravitreal anti-VEGF injections in the left eye, an epiretinal membrane in the right eye status after pars plana vitrectomy with membrane peel, and neovascular glaucoma status after Ahmed glaucoma valve in the right eye presented for routine follow-up. The BCVA was no light perception in the right eye and 20/60 in the left eye, the intraocular pressure was stable, and anterior segment examination was unremarkable. Fundus examination showed vitreous hemorrhage and NVE in the inferior macula with scattered peripheral PRP scarring

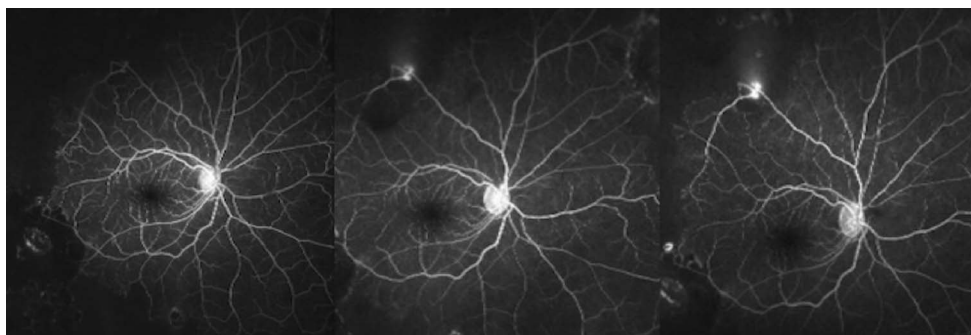
in the left eye. The examination of the right eye was stable with complete PRP and no active NVE or NVD.

Fundus fluorescein angiography imaging revealed hyperfluorescent leakage along the ITA with vertical extension into the vitreous cavity of the left eye consistent with NVE (Figure 5). Optical coherence tomography did not reveal any central, intra, or subretinal fluid. The examination was unremarkable in the right eye. The patient was recommended to undergo intravitreal anti-VEGF therapy, PRP fill in, or combination therapy. Follow-up imaging reveals decreased hyperfluorescence and resolving NVE.

#### Case 6

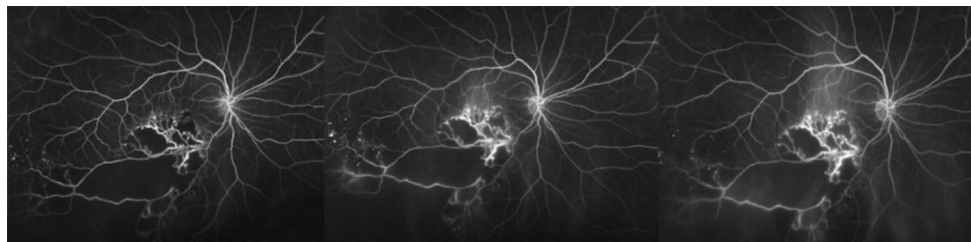
A 63-year-old African woman with T2D and an ocular history of PDR in both eyes with macular ischemia (edema) in the left eye status after focal laser in the left eye. Patient presented to establish care. The BCVA was 20/60 in the right eye and count fingers in the left eye, the intraocular pressure was within normal limits, and anterior segment examination was unremarkable. Fundus examination of the right eye showed NVD and scattered macular microaneurysms and few extramacular intraretinal hemorrhages. Central focal laser scarring and few scattered macular microaneurysms were noted in the left eye.

Fundus fluorescein angiography imaging demonstrated hyperfluorescent leakage of the optic nerve



**Fig. 2.** Fundus fluorescein angiography of the right eye displays gradual enlargement of hyperfluorescence along the superior temporal arcade with leakage extending vertically into the vitreous cavity during the late phase.

**Fig. 3.** Fundus fluorescein angiography of the right eye displays gradual enlargement of hyperfluorescence along the ITA with leakage extending vertically into the vitreous cavity during the late phase.



head that extended vertically into the vitreous cavity consistent with NVD in the right eye along with central microaneurysms (Figure 6). Optical coherence tomography did not reveal any central, intra, or subretinal fluid. There was no evidence of neovascularization in the left eye.

The patient received intravitreal anti-VEGF therapy and PRP fill in. She is stable without recurrence of vitreous or intraretinal hemorrhage.

#### Case 7

A 60-year-old Qatari man with T2D and an ocular history of PDR in both eyes status post-PRP and multiple intravitreal anti-VEGF injections in both eyes, hypertensive retinopathy in both eyes, and open-angle glaucoma in both eyes with no light preception vision in the right eye secondary to glaucoma and PDR. He presented as a new patient with concern of blurry vision in the left eye. On examination, his BCVA was no light preception in the right eye and 20/40 in the left eye, intraocular pressure was elevated in the mid 20's, and anterior segment examinations were unremarkable.

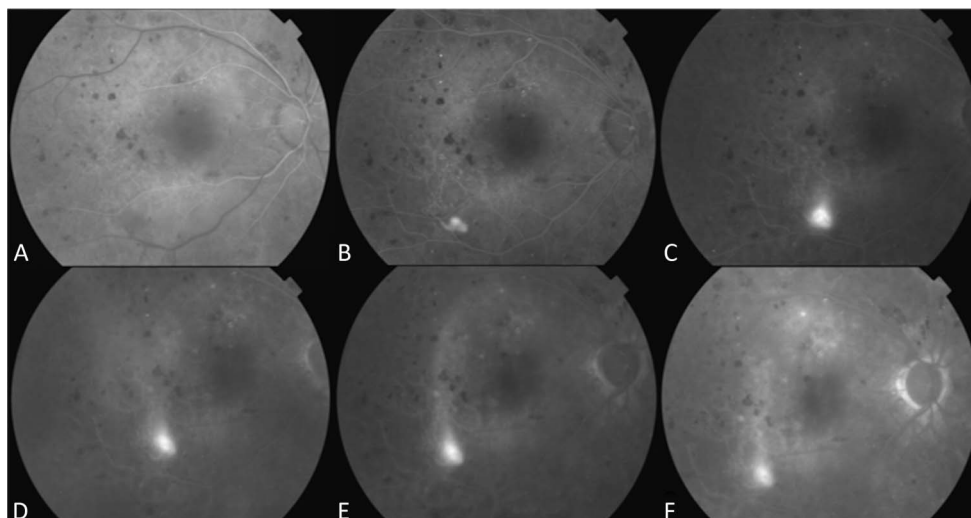
Fundus examination showed optic nerve head pallor in both eyes with scattered microaneurysms and macular edema in the left eye. Vitreous hemorrhage

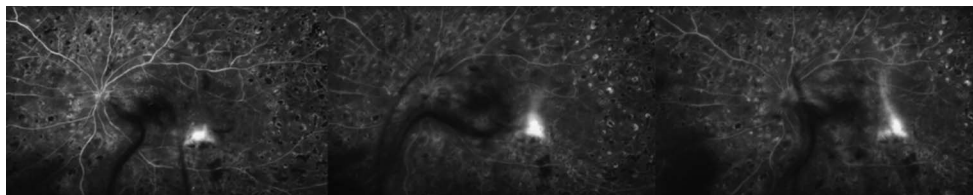
was noted inferiorly in the periphery of the left eye. There was concern for NVE along the superior temporal arcade, and FFA confirmed an early pinpoint area of hyperfluorescent leakage along the superior temporal arcade consistent with NVE. It was noted that the leakage expanded vertically into the vitreous cavity in the late phase (Figure 7). Optical coherence tomography revealed macular edema in the left eye. The patient received intravitreal anti-VEGF therapy and PRP fill in. He is stable without recurrence of vitreous hemorrhage.

#### Discussion

This is the first case series to our knowledge to report a smokestack leakage pattern on FFA outside the setting of CSCR. All of the patients demonstrated ischemic retinopathy, five were related to PDR, one was related to sickle cell retinopathy, and one was related to branch retinal artery occlusion. None of the patients had a known history or clinical signs of current or past CSCR, the posterior hyaloid was determined to be attached based on clinical examination and OCT imaging, and no patient had previously undergone pars plana vitrectomy.

**Fig. 4.** Fundus fluorescein angiography of the right eye displays gradual enlargement of hyperfluorescence along the ITA with leakage extending vertically into the vitreous cavity during the late phase.





**Fig. 5.** Fundus fluorescein angiography of the left eye shows gradual enlargement of hyperfluorescence along the ITA with leakage extending vertically into the vitreous cavity during the late phase.

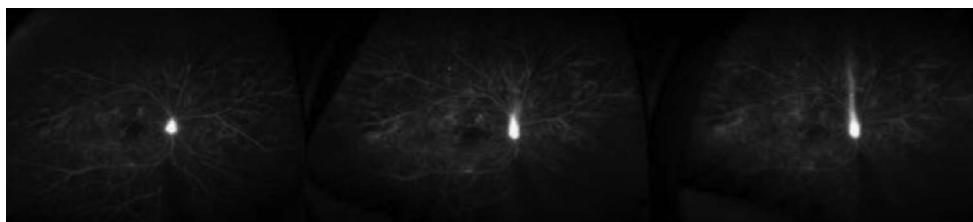
The pathophysiology of idiopathic choroidal vascular hyperpermeability in CSCR has been explained by several indocyanine green angiography studies and FFA. Bujarborua et al<sup>2</sup> studied the demography, various morphological patterns, and fluid dynamics of CSCR leakage by FFA to help explain the smokestack pattern. They demonstrated that convection currents in the subretinal fluid plays a major role in the production of smokestack leakage, and the morphology is due to altered fluid current dynamics in the presence of hyperdense substances such as fibrin in the subretinal space. In their study, fluid containing a low concentration of fluorescein ascended because of convection currents while highly concentrated dye descended. The smokestack leakage in CSCR manifests itself as a point leakage from the retinal pigment epithelium at the arteriovenous or early venous phase of the angiography, which gradually increases in size during the midphase and begins to ascend. After reaching a certain height, the dye may extend temporally and/or nasally in an umbrella or mushroom-like pattern.<sup>2</sup>

Several studies have aligned fluid dynamics in CSCR to choroidal vascular hyperpermeability.<sup>3</sup> Although other studies have observed delayed filling in choriocapillaris segments before the development of hyperpermeability, this is likely resulting from decreased arterial perfusion.<sup>4,5</sup> It is well established in the literature that decreased arterial perfusion leads to oxygen deprivation and its sequelae of ischemia; ultimately leading to a decrease in venous outflow in these areas, creating a pressure overload and thus resultant choroidal vessel hyperpermeability.<sup>3</sup>

Garg et al studied the natural course of CSCR with FFA and observed that single leaks in natural history progress from smokestack to circular to pinpoint leaks. The various patterns of leakage are said to be due to

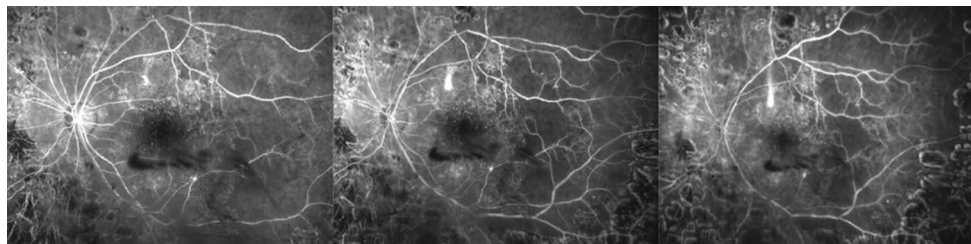
the osmotic gradient resulting from the different protein concentrations in the content of the fluid within the neurosensory detachment and the fluid entering through the point leakage.<sup>6</sup> Garg et al showed that CSCR with high-protein content in the subretinal fluid will present as a “pinpoint” or “ink blot” pattern of leakage. The high-protein content in the subretinal fluid is believed to bring the circulation to a complete stop. However, when fluid is transudate during the initial presentation of CSCR, fluorescein dye will enter as a point leak and ascend to reach the highest point of the neurosensory detachment, presenting as a smokestack pattern of leakage.<sup>7</sup>

Fluorescein leakage seen in neovascularization related to PDR or proliferative sickle cell retinopathy is secondary to proliferation of endothelial-incompetent retinal vessels on the surface of the retina with fluorescein leaking into the vitreous cavity creating a diffuse, white haze in the late phases of angiography that is often described as a cotton ball surrounding the neovascularization.<sup>8</sup> Although no known pathophysiologic explanation of this novel smokestack leakage in proliferative retinopathy cases exists, previous studies on CSCR help guide possible theories. In proliferative retinopathy and retinal neovascularization, the natural vitreoretinal relationship is altered, leading to progressive degrees of adhesion and incomplete posterior vitreous detachment (PVD).<sup>9</sup> Similar to CSCR, there likely exists a thermodynamic temperature gradient between the retina and vitreous body. We hypothesize that the pathologic alterations of the vitreoretinal interface creates subhyaloid pockets or tracks adjacent to areas of neovascularization that allows for columns of hyperfluorescence to form. These columns of hyperfluorescence may form a smokestack sign secondary to local convection currents from thermodynamic alterations between



**Fig. 6.** Fundus fluorescein angiography of the right eye shows gradual enlargement of hyperfluorescence of the optic nerve with leakage extending vertically into the vitreous cavity during the late phase.

**Fig. 7.** Fundus fluorescein angiography of the left eye shows gradual enlargement of hyperfluorescence along the superior temporal arcade with leakage extending vertically into the vitreous cavity during the late phase.



the retina and vitreous. Although the anatomic space for smokestack leakage differs between CSCR and proliferative retinopathy, the mechanism of this uncommon angiographic leakage pattern may be similar between these very different clinical processes.

In conclusion, just as a smokestack leakage pattern in CSCR is uncommonly seen, so is the smokestack pattern from neovascular retinopathy. As imaging quality continues to improve, the observation of this phenomenon may become increasingly more apparent. Further studies may be performed to examine the pathophysiology of this phenomenon in neovascular retinopathy, to include peripheral OCT and OCT angiography imaging directly overlying the smokestack leakage to assess vitreoretinal interface and microvascular perfusion in this region. The authors do not propose any alteration of typical treatment patterns for proliferative retinopathy because the observed atypical leakage resolved with photocoagulation or anti-VEGF therapy,<sup>10</sup> but this study does challenge the basic premise that smokestack leakage is reserved solely for CSCR.

### Limitations

The authors recognize that this is a retrospective observational case series with a small number of patient cases. The absence of indocyanine green angiography imaging on each of these patients is another limitation to the study.

**Key words:** angiography, central, chorioretinopathy, diabetic, ischemic retinopathy, leakage, proliferative, retinopathy, serous, smokestack.

### References

1. Shahin MM. Angiographic characteristics of central serous chorioretinopathy in an Egyptian population. *Int J Ophthalmol* 2013;6:342–345.
2. Bujarborua D, Nagpal PN, Deka M. Smokestack leak in central serous chorioretinopathy. *Graefes Arch Clin Exp Ophthalmol* 2010;248:339–351.
3. Spaide RF, Goldbaum M, Wong DW, et al. Serous detachment of the retina. *Retina* 2003;23:820–826.
4. Guyer DR, Yannuzzi LA, Slakter JS, et al. Digital indocyanine green videoangiography of central serous chorioretinopathy. *Arch Ophthalmol* 1994;112:1057–1062.
5. Iida T, Kishi S, Hagimura N, Shimizu K. Persistent and bilateral choroidal vascular abnormalities in central serous chorioretinopathy. *Retina* 1999;19:508–512.
6. Shetty NS, Sharma T, Shanmugan MP, et al. Google Books. Web. Atlas of Fundus Fluorescein Angiography. New Delhi, India: Jaypee Brothers Medical Publishes (P) Ltd; 2004.
7. Garg SP, Tewari HK, Khosla PK, Azad RV. Fluorescein angiography in central serous retinopathy. *Indian J Ophthalmol* 1982;30:593–596.
8. Ryan MD, Stephen J, Schachat MD, et al. Google Books. Web. Retina. 5th ed. Vol 1. Beijing, China: Elsevier Saunders, Inc; 2013.
9. Tagawa H, McMeel JW, Furukawa H, et al. Role of the vitreous in diabetic retinopathy. I. Vitreous changes in diabetic retinopathy and in physiologic aging. *Ophthalmology* 1986;93:596–601.
10. Avery RL, Pearlman J, Pieramici DJ, et al. Intravitreal bevacizumab (Avastin) in the treatment of proliferative diabetic retinopathy. *Ophthalmology* 2006;113:1695–1715.