

# Complications of auricular correction

## Abstract

The risk of complications of auricular correction is underestimated. There is around a 5% risk of early complications (haematoma, infection, fistulae caused by stitches and granulomae, allergic reactions, pressure ulcers, feelings of pain and asymmetry in side comparison) and a 20% risk of late complications (recurrences, telephone ear, excessive edge formation, auricle fitting too closely, narrowing of the auditory canal, keloids and complete collapse of the ear). Deformities are evaluated less critically by patients than by the surgeons, providing they do not concern how the ear is positioned. The causes of complications and deformities are, in the vast majority of cases, incorrect diagnosis and wrong choice of operating procedure. The choice of operating procedure must be adapted to suit the individual ear morphology. Bandaging technique and inspections and, if necessary, early revision are of great importance for the occurrence and progress of early complications, in addition to operation techniques. In cases of late complications such as keloids and auricles that are too closely fitting, unfixed full-thickness skin flaps have proved to be the most successful. Large deformities can often only be corrected to a limited degree of satisfaction.

**Keywords:** auricular correction, complications, corrective operations

Otto Staindl<sup>1</sup>

Vanessa Siedek<sup>2</sup>

1 University Clinic for Ear, Nose and Throat Medicine and Head and Neck Surgery, Paracelsus Medizinische Privatuniversität, Salzburg, Austria

2 Clinic for Ear, Nose and Throat Medicine, Ludwig Maximilians University, Großhadern Clinic, Munich, Germany

## 1 Introduction

Correction of protruding auricles is considered to be a small and 'easy' routine operative procedure that is usually learnt as part of the training to be a specialist in ear, nose and throat medicine and carried out independently [59], [126]. However, auricular correction is among the repertoire of operations of a number of other specialist disciplines: Paediatric surgery, jaw and facial surgery, plastic surgery and occasionally also general surgery [15], [43], [45], [53], [54], [55], [61], [62], [66]. The respective specialist literature on operation techniques and modifications is therefore correspondingly comprehensive [10], [75], [79], [80], [109]. It is striking that in the vast majority of publications successful operative procedures are usually presented with excellent results, while complications and failures are seldom mentioned [1], [8], [9], [84]. This seems all the more noteworthy because the topics of 'failures and complications in plastic surgery' have been mentioned more and more in specialist literature in recent years [59], [60], [66], [85], [106], [132]. Only the large number of publications on secondary rhinoplasty is referred to here.

The evaluation of the success or failure of auricular correction is subject to subjective and objective criteria [112]. The subjective estimation of the post-operative result depends on the one hand on the expectations of the patient and on the other hand on the degree of their aesthetic sensitivity and that of the surgeon [7], [74]. However, there are often different points of view on this point specifically, although it should be noted that the patient is considerably less critical of the post-operative

result than the doctor treating them. In some investigations we were able to determine that the expectations of the patients were initially primarily restricted to the ear being in the right position [59], [101], [104], [105]. Some of the details about the post-operative result that concerned the surgeons, especially edge formations, but also excessive contouring, were scarcely noticed by the patients or at least not evaluated negatively [32], [33], [94]. However, the present paper shall only discuss the objective failures and complications that are almost exclusively caused by incorrect diagnosis and/or incorrect operation technique.

A protruding auricle is a deformity that can occur in a number of abnormalities of position and shape. Because there is no universal operation method that takes all of the variations into consideration, almost unlimited procedures for correction have been published as yet [11], [13], [14], [18], [21], [22], [34], [35], [36], [42], [44], [48], [53], [58], [60], [65], [77], [78], [90], [92], [93], [95], [133]. However, they can essentially be divided up into three basic techniques [40], [55], [75]:

- pure stitching techniques [2], [3], [20], [41], [81], [83], [86]
- pure incision techniques [4], [5], [16], [17], [30], [47], [52], [94], [95], [100], [107], [108], [114]
- combined stitching-incision techniques [24], [25], [27], [28], [53], [90], [105], [111], [113].

They all demonstrate specific possibilities of complication, which are considered in detail in the following chapters.

## 2 Complications of auricular correction

Complications of auricular correction can be divided into three groups:

1. complications caused by incorrect diagnosis and wrong choice of operation techniques,
2. early complications,
3. late complication (Table 1).

**Table 1: Statistical frequency of the most important complications according to Weerda 2004**

Early complications	
Bleeding and haematoma	11/712 = 1.5%
Infections (inc. perichondritis pressure ulcers)	22/593 = 3.7%
Late complications	
Feelings of pain	7/213 = 3.3%
Fistulae caused by stitches and granulomae	53/533 = 9.9%
Scar hypertrophy/keloids	14/775 = 1.8%
Deformities of the ear muscle (incl. asymmetry, over-correction, formation of edges, telephone ear, complete collapse of ear)	255/3100 = 8.2%

### 2.1 Complications caused by incorrect diagnosis and wrong choice of operation techniques

Auricular correction is an operation that comes under the umbrella of aesthetic surgery. As always with these types of interventions the diagnosis should originally be made by the patient themselves. A desire for correction must be deduced from this. However the treating physician must match the diagnosis to the operating technique required. An exact analysis and documentation of the type of deformity of the ear has to take place before the operation [31], [51], [66], [92]. The quality of the cartilage, the skin and the tendency to scar hyperplasia etc. should be evaluated. It was mentioned at the start that there is no universal operating procedure that is suitable for all deformities of the form and the position of the auricle. Pre-operative planning therefore requires an exact analysis of the deformity and consequently the choice of operation technique, which is also adapted to it. However, this requires the respective surgeon to manage several operation methods that correspond to the individual circumstances and requirements. Weerda emphasizes that a skilled ear surgeon is undoubtedly able to correct the various types of protruding auricle using their preferred operation technique. The surgeon must also be able to create a harmonious auricle shape using additional interventions like cavum rotation, antitragus reduction, lobu-

lous reduction, narrowing of the helix and other operative additions [21], [75], [129], [130].

The pre-operative analysis of the auricle should be done both from the front view and from the side view (the same goes for the evaluation of the post-operative result). Thus for example a protruding auricle with a pronounced anthelix bulge is contraindicated for correction by Stenström. This concerns pure anthelix correction that would lead to a considerable over-emphasis of the anthelix bulge and that would also not be able to reduce the concha-mastoid angle. On the other hand a fully formed or missing anthelix fold presents a contradiction of what is known as 'concha rotation' or also 'cavum rotation' because the auricle can still be protruding. However, the formation of a satisfactory antihelix structure is hardly possible.

The composition of the ear cartilage can also influence the choice of operation technique [55], [75]. Very thin cartilage represents a contradiction to the anterior cut or incision technique that can lead to unsightly formation of edges. Pure stitching techniques on the other hand are not suitable for correcting thick cartilage structures. The composition of the skin can also determine the choice of operation technique. For example, in the case of a known tendency towards keloids, the diagnosis for auricular correction would be set very strictly and an operation process chosen where no extended skin incisions or excisions would be made.

### 2.2 Early complications

#### 2.2.1 Haematoma

Post-operative haematoma can occur as a consequence of insufficient haemostasis. They can also be observed if the operation is done under local anaesthetic using vasoconstriction. Only after a few hours have passed since the operation does bleeding occur in the area of the operation because of reactive vessel widening. In rare cases coagulation disorders that were not recognised pre-operatively can lead to extensive subsequent bleeding (Figure 1). Such occurrences require a rapid revision of the wound area under sterile conditions, exact haemostasis [19], [37], [101], possible drainage and light compression. Post-operative haematomas may occur primarily following incision techniques and in principle can encourage the occurrence of an infection. They are often noticed because of post-operative pain. In order to prevent a haematoma it is recommended that the auricle is modeled with pointed swabs. The use of transcutaneous mattress stitching is less common [55], [59], [92], [101]. Organised ear haematomas that have been in existence for longer lead to indurative, scar-like thickenings and deformities of the auricle that are difficult to correct. In collection of statistic for all operation techniques, Weerda cites haematoma for 11 of 712 or 1.5% [124] (Figure 2).

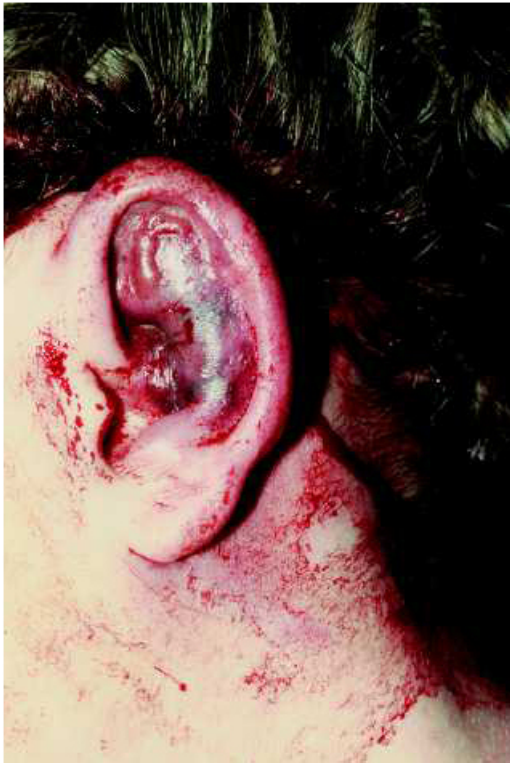

Figure 1: Acute othaematoma on first post-operative day

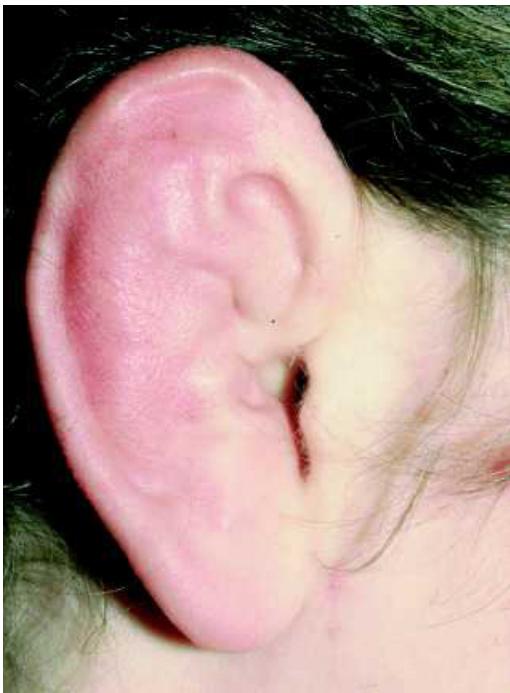

Figure 2: Chronically indurated scar-like, thickened old othaematoma ('ring ear')

## 2.2.2 Infections

Wound infections can be caused by insufficient preoperative hygiene (head and hair washing). This complication requires the use of broadband antibiotics (e.g. 2<sup>nd</sup> or 3<sup>rd</sup> generation cephalosporin [55]) and analogous local treatment of the auricle. Stitches that are too tight should be removed. If necessary the wound edges should be spread in order to prevent overlapping of the swelling on the auricle (perichondritis) that can lead to deformities of the auricle. This would then be a surgical emergency where prompt debridement of necrotic tissue is necessary [59], [101]. Incipient perichondritis also responds well to appropriate antibiotics and local measures. Pseudomonas aeruginosa or staphylococcus aureus are the most common causes. A swab is obligatory [120] (Figure 3). A complete overview of literature showed an infection in 3.6% of cases (22 out of 593 ears) [124].

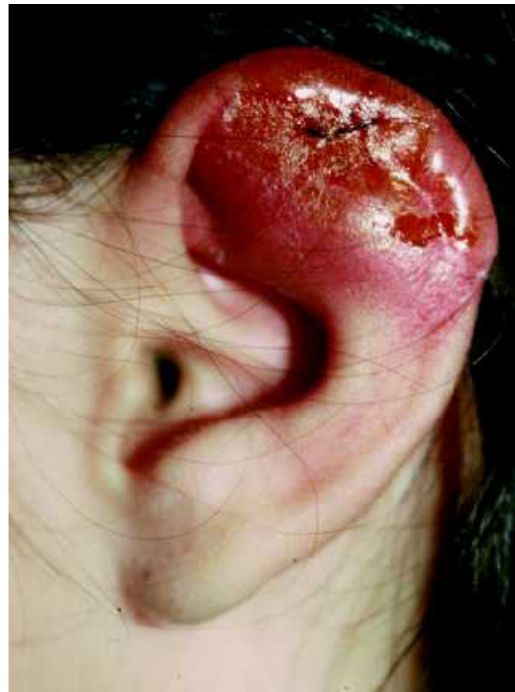

Figure 3: Wound infection. Incipient perichondritis

## 2.2.3 Fistulae caused by stitches and granulomae

They can occur as an intolerance reaction to stitching materials and principally occur in corrections that are done purely through stitching techniques more frequently than with other operation techniques. Oversensitivity to the stitching material, stitches that are too close beneath the skin surface of the scar or knots or thread ends that have been cut too long are usually present. The reaction to braided polyester threads is said to be greater than to other stitch materials. Heppt et al. [55] recommend the use of undyed, non-resorbable stitches of thickness 4.0 or 5.0, retroauricular 3.0. On the other hand the use of monofilament threads is risky because the knots can easily come undone. As far as possible there should not be any stitches whose tension is too high, because this

could result in stitch perforation [66]. In any case, in the presence of fistulae and granulomae, the stitching material used should be carefully completely removed. The same is also valid for ligatures or scars on the surface, whose edges can be seen through the skin of the auricle. After removal of 1-2 stitches there is usually no change in the cosmetic result. Fistulae caused by stitches are found in 9.9% of cases (53 out of 533 ears) [116], [118], [124] (Figure 4).

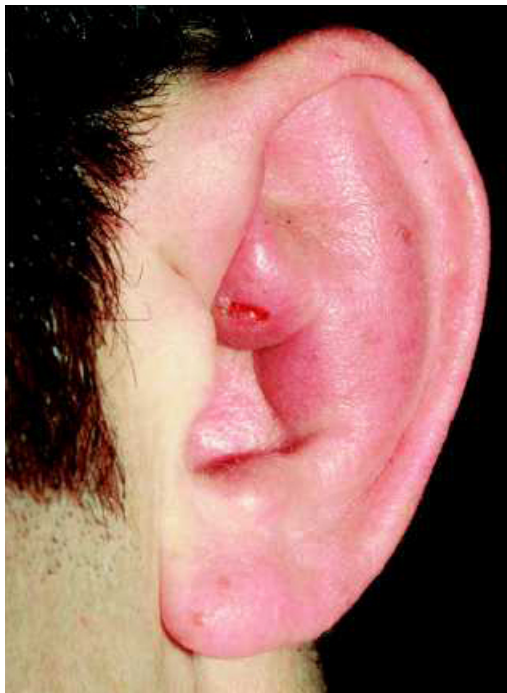

Figure 4: Abscess forming on the stitch granuloma just before the perforation

#### 2.2.4 Allergic reactions

Allergic reactions on the skin of the auricle can occur as allergies to washing agents. However they are caused considerably more frequently by ointment bandages (iodine allergy for example). Auricle pressure bandages with antibiotic ointment are frequently used for post-operative treatment. In individual cases we could observe the most serious swellings and blister-forming dermatoses as a consequence of allergic reactions [55] (Figure 5).

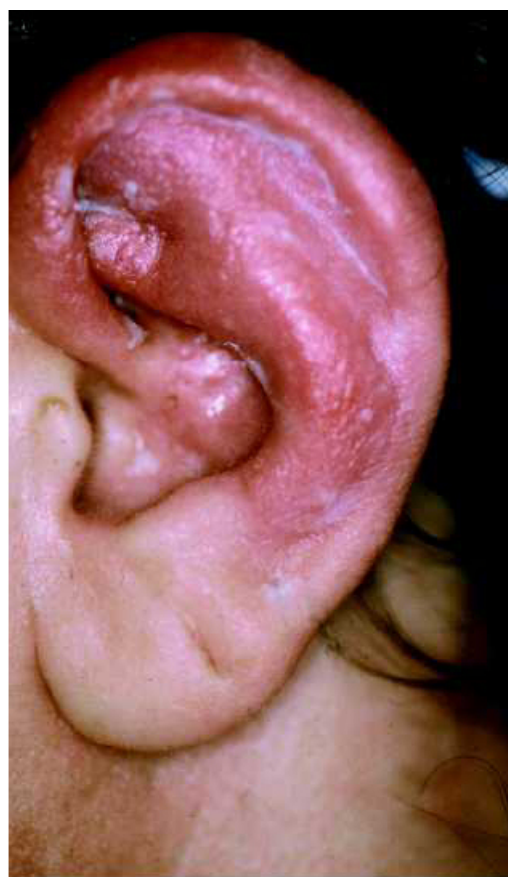

Figure 5: Allergic reaction with incipient blister-forming dermatosis

#### 2.2.5 Pressure ulcers

In the case of head bandages that are too closely fitting or that dig in, pressure ulcers can occur on the skin of the auricle but also on the ear cartilage as a result of pressure necrosis. Ulcerations of this kind are usually associated with considerable feelings of pain. Removal of the bandages and inspection of the operation area and possible operative revision is indicated. The individual bandaging technique is referred to in this respect: After the operation the front and back sides of the auricle are greased with natural salve (Vaseline/Bepanthen) and the auricle contour is lined with bandaging wadding moistened with 3% carbon super oxide. Thick layers of dried wadding are placed over it and then a light compression bandage. Checks are always made on bandages after 24 hours and every 3 days if there is no pain. The bandage is removed on the 7<sup>th</sup> to 8<sup>th</sup> day. Because the damp bandage wadding fits directly to the auricle, it also represents an excellent prophylaxis for a haematoma and for the occurrence of pressure ulcers (Figure 6). Mattheis und Siegert [75] recommend a foam protective bandage for 7 days with betaisodona/Vaseline/salve compresses and then a forehead bandage overnight for a further 4 weeks and regular photographic documentation to check on progress. Several current studies emphasise that the post-operative bandage should be a retaining bandage and not a pressure bandage [55], [101]. Patients are made to wear a forehead bandage at night 4-6 weeks

after the operation and not practise any team sports or other sports that could result in the stitches being ripped out.

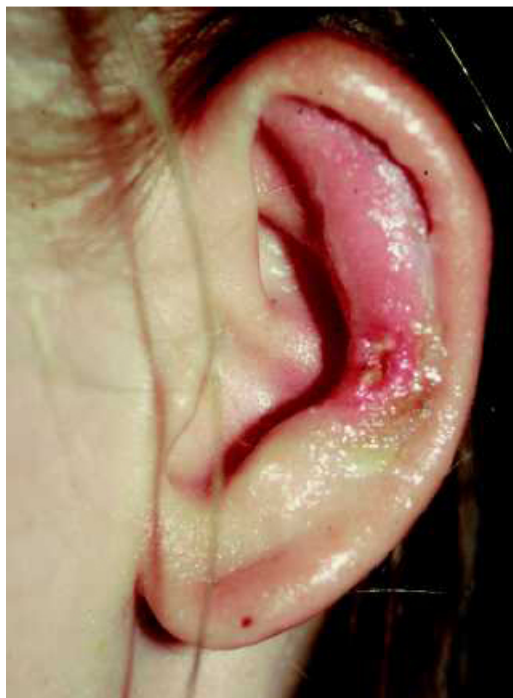

Figure 6: Pressure ulcer in typical position with incipient perichondritic irritation

### 2.2.6 Post-operative pain

Light to medium pain can occur on the day of the operation, regardless of the operation technique chosen, that makes administration of an analgesic necessary. However, the post-operative process is usually already completely painless 24 hours following intervention. Pain that persists beyond this period is always an alarm signal for one of the complications given above. Careful removal of bandages and inspection of the operation area is indicated. Frequently it is only an auricular pressure bandage that is too tightly fitted and the patients are normally pain free once the bandages have been changed [15], [23], [60], [92], [101].

### 2.2.7 Asymmetry of auricles in comparison of sides

Post-operative asymmetry, i.e. different levels of protrusion of the auricle, is usually iatrogenic if the ears have not been measured before and after the surgical intervention. Asymmetry can be avoided by measuring the distance during the operation. However, it can also occur if there are differently shaped auricles on both sides and if different operative techniques have been applied to each respective side. Insufficient stitches, torn out stitches and knot slipping etc. [75] are indicated. Asymmetry requires observation over a longer period of time because after pure stitching or incision techniques the auricle that has been operated on will only start to rebuild itself again in accordance with the natural flexural force

of the cartilage after a longer time. If the asymmetry remains, a corrective operation may be undertaken after a period of 8-12 months (Figure 7) [15], [88], [97], [101].

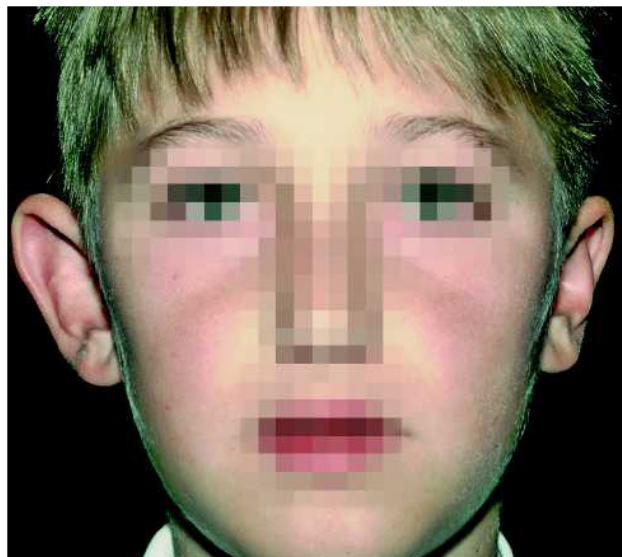


Figure 7: Post-operative state following bilateral otopexia. Asymmetry of auricles in side comparison

## 2.3 Late complications

### 2.3.1 Recurrences

Recurrences are directly dependent on the operation technique used, but they cannot be reliably ruled out with any one corrective method. It is not to be expected that the frequency of recurrence is higher with pure stitching techniques than with incision/stitching techniques. However this contradicts the number of collected statistics published by Weerda where 7.7% of recurrences (164 of 2,136 ears) were seen following the mustard technique. On the other hand the frequency of recurrences following the converse technique is 10.5% (85 of 812 ears). Recurrences are most seldom observed following incision techniques. If an auricle that has been operated on according to these methods protrudes even further, this concerns an intra-operative under-correction [46], [125], [127] (Figure 8).

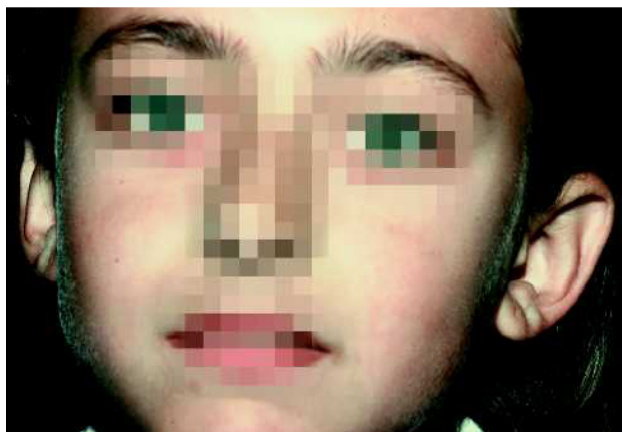

Figure 8: Post-operative state following bilateral otopexia. Recurring apostasy of the left auricle

According to Spira [101] a slight over-correction is desirable. Reprotrusion after one year is unlikely. Reasons for recurrence could be:

- too few stitches;
- stitches incorrectly positioned;
- excessive skin resection leads to tension in the skin that the skin itself yields to.

Mattheis und Siegert [75] observed that the same cartilage tension can principally lead to recurrences if resorbable stitches are used.

### 2.3.2 Telephone ear

'Telephone ear' is characterised by the protrusion of the upper helix edge and of the earlobe. It is a consequence of the overcorrection of the middle part of the auricle. Over-proportional resection of retroauricular skin makes telephone ear more likely to occur. It can be avoided if a dumbbell-shaped skin excision is used instead of elyptoid skin excision. The auricle should be evaluated from the front aspect in order to make any early corrections, while the patient is still on the operating table. Late corrections of telephone ear require an extended mobilization of the auricle, whereby the skin deficits have to be replaced with sealing flaps or a full-thickness skin transplant [16], [57], [115], [123] (Figure 9).

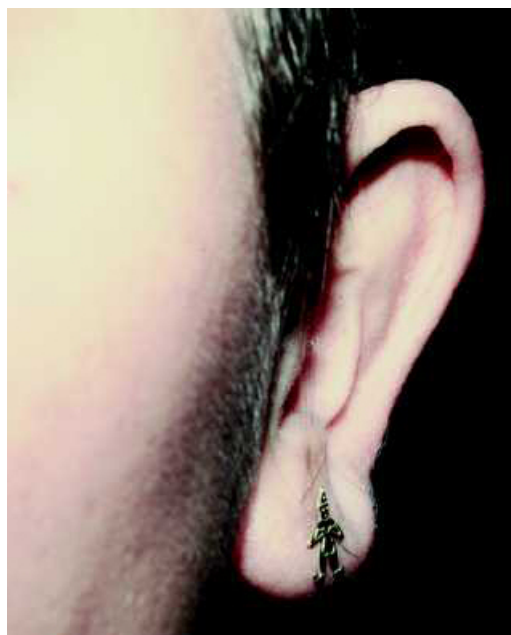

Figure 9: Telephone ear

### 2.3.3 Excessive edge formations

Increased formation of edges in the anthelix area primarily occurs with pure cutting techniques and is particularly common with extremely thin auricular skin. The causes of this type of edge formation are usually incorrect incision technique, excessively deep incision of the anthelix and over-extended excision between the anthelix and the concha. Edges principally occur if the auricle is not only incised but also completely severed by mis-

take. Sharp edges can also occur because of separation of the ventral perichondrium or incisions in the incorrect place [75]. The corrective operation can be done by careful abrasion of the cartilage in the anthelix area or by equalisation using a scalpel. According to the extent and the severity of edge formation, fascia temporalis can be used to smooth out the edges following undermining of the anterior skin, depending on the shape of the anthelix or crura. However, if the skin of the auricle is extremely thin and the formation of edges is pronounced, recreation of a soft and smooth auricle edge is hardly possible [116], [119], [121], [122] (Figure 10).

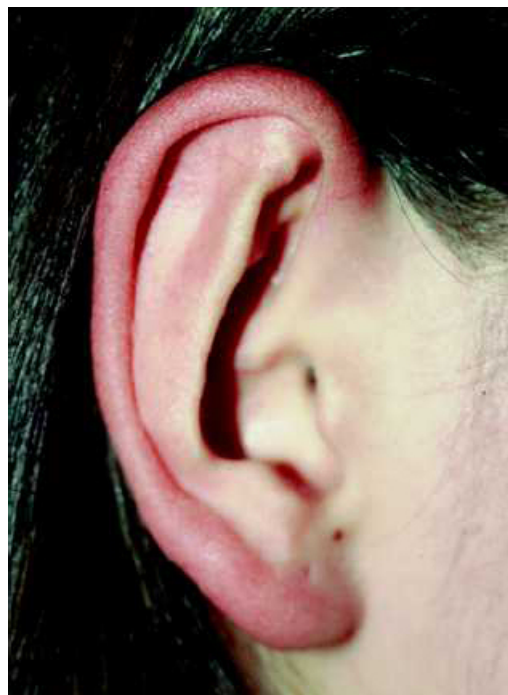
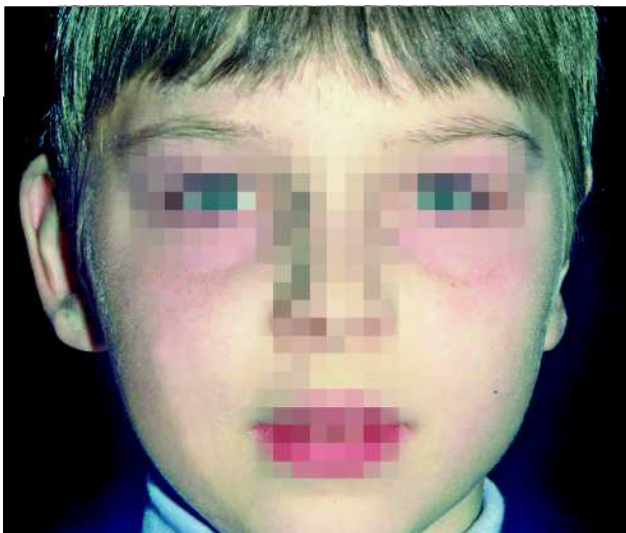
Figure 10: Excessive edge formation on the right auricle

### 2.3.4 Auricle too closely fitting

An excessive correction leads to an excessively close fit of the auricle. This causes problems for aesthetic reasons, because the auricle, which does contribute to the overall impression of the face, is practically invisible from the front, giving the face a certain emptiness. The excessively close fit of the auricle is almost exclusively caused by excessive resection of the retroauricular skin (Figure 11). If the stitches are too tight the helix may be raised, giving the impression that the ear is getting more narrow, which is described as a 'hidden helix'. The auricle that has been thus fixed on the mastoid also exhibits a variety of functional defects. Because the retroauricular fold is no longer maintained, glasses-wearers may experience problems and directional hearing may also become more difficult. Patients with ears that have been too closely attached often complain that their hearing has become worse following the corrective operation and that they always have to search for the source of sound. Actually the hearing of patients with ears that are too close-fitting is not worse. However, their ability to locate the source of the sound is insufficient [56].



**Figure 11:** State following over-correction of the left auricle with excessively closeness. The impression of 'emptiness' of the left half of the face is apparent.

Patients with auricles that are too close-fitting also frequently complain about pain, especially when lying down. It is possible to correct these complications using targeted lobe correction [12], [64], [87]. We have achieved considerably better results using free full-thickness skin transplants. However, care should be taken to ensure that the transplants taken are not too small, because, on the one hand, the defect to be covered is surprisingly extensive after unpicking the scar and separation of the auricle from the mastoid. On the other hand full-thickness skin transplants tend to shrink so that complications could occur again as a result. We take the grafts required from the groin region [89], [128], [131].

### 2.3.5 Narrowing of the auditory canal

This complication occurs primarily following concha rotation. Often the retroauricular skin has not been prepared widely enough from the dorsal to the mastoid and the cavum has not been stretched widely enough towards the dorsal during rotation and then fixed, when results in auditory canal stenosis. If the narrowing is more pronounced it can lead to unpleasant sensations and, in particular, to a subjective impression of hearing difficulty, which has already been mentioned in the previous chapter [48]. Narrowing of the auditory canal can prevent earphones (Walkman) from being inserted. Treatment takes the form of excision of the cartilage from an incision in the auditory canal outwards.

### 2.3.6 Hypaesthesia, sensitivity to cold

Patients frequently report hypaesthesia or sensitivity to cold following auricular correction [55], [59]. In the vast majority of cases this is a temporary phenomenon that gradually returns to normal.

### 2.3.7 Keloids

A keloid is the most feared complication of wound healing. It results from scar tissue that encroaches over the original wound area onto the adjoining health tissue, like a tumour. It concerns an excessive regeneration of fibroblasts whose activity is partly influenced by growth factors from inflammation cells and from epidermal keratinocytes. The balance between synthesis and deconstruction of the dermal collagen is clearly shifted because of the disrupted interactions of these factors. A wide range of authors consider raised wound tension to be a cause of increased collagen synthesis. In addition an abnormal increase in melanocyte hormones (MSH) is assumed. This could also explain the accumulation in dark-skinned persons [67], [69], [70], [71], [72].

Some areas of the body (presteral area, outside of the upper arms, neck and shoulder areas) are predisposed to developing keloids. Keloids in the face area are extremely rare [6]. We are of the opinion that keloids following auricular correction are not exclusively determined by a corresponding predisposition, but that comprehensive skin excision also plays a role. The consequence is a continual forward pull of the ear cartilage that works against normally progressing scar formation. During the reformation of tissue as part of normal wound healing, the collagen fibres align themselves in the direction of the main pull. However, an excessively strong pull can form more connective tissue and blood vessels. The result is excessive scar formation - the keloid.

For treatment of keloids a) local injections of triamcinolon and b) radiotherapy are generally indicated. However, we do not carry out either of these procedures in the ear area of children and adolescents. On the one hand triamcinolotherapy seems to us to be problematic during childhood. On the other hand radiotherapy can leave lasting damage on to the growing ear cartilage [38]. Attempts at treatment using cortisone infiltration can lead to scar tissue in keloids that are just starting or at least small. Because the solution for injection disperses very poorly, at least in the very coarse keloids, dermojet treatment should be favoured. Dermojet treatment can also be used intraoperatively if larger keloids have been removed. It is then used to prevent keloids. Radiotherapy is also used for post-operative prevention of keloids. We apply a total dose of 20 Gy (10 x 2 Gy in 3 individual sessions per week).

Alternative procedures such as kryotherapy and pressure treatment are not carried out in our clinic [29].

Luckily we very seldom have to treat keloids and we do so by careful and complete excision and cover of the resulting defect with a free full-thickness skin transplant [73], [102], [103]. This is taken from the groin area. We prefer skin transplants over complete keloid excision whose frequency of recurrence is indicated at up to 60%. Weerda reported on 25 patients who did not have any further treatment after excision of a keloid. There was recurrence in all patients (100%). During 25 years we have treated a total of 17 retiauricular keloids with full-

thickness skin transplants (Figure 12, Figure 13). There was recurrence in one case where a keloid occurred at the removal point - the groin region. The frequency of keloids is given in the statistics collected by Weerda with 1.8% (14 of 775) [124].

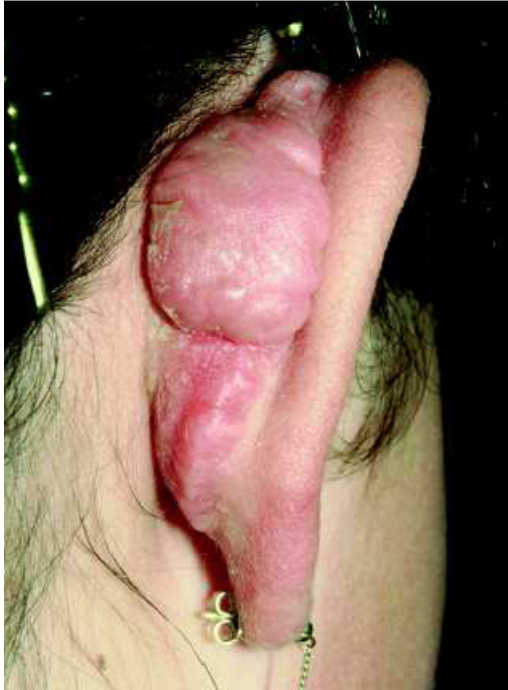

Figure 12: Massive retroauricular keloid

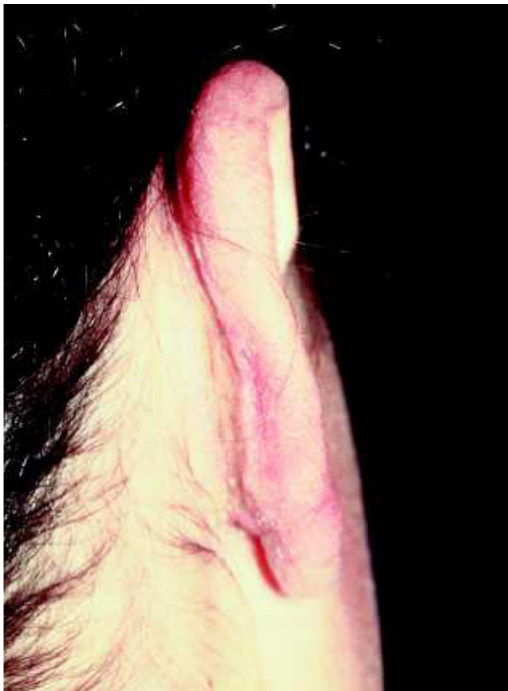

Figure 13: State following keloid removal and covering of defect with free full-thickness skin transplant from the groin region (18 months postoperative)

### 2.3.8 The “collapsed ear”

Collapsed ear concerns disorders that occur when all of the complications described above come together, along with the use of wholly inappropriate operation techniques, without consideration of the anatomy of the auricle [104]. We have been able to observe auricles where there were massive, coarse, induced thickenings caused by a haematoma with loss of relief of the auricle or excessive formation of edges. There are also ears where nearly the entire cartilage has clearly been removed and the remaining skin has been attached to the mastoid. (Figure 14, Figure 15, Figure 16, Figure 17, Figure 18). Such excessive deformities are usually the consequence of inadequate operation techniques that contradict all of the principles of plastic and reconstructive surgery. It is assumed that these types of disorders, whose causes are usually iatrogenous, have medical and legal consequences. It is therefore essential that exact and comprehensive pre-operative explanations are made, together with corresponding documentation.

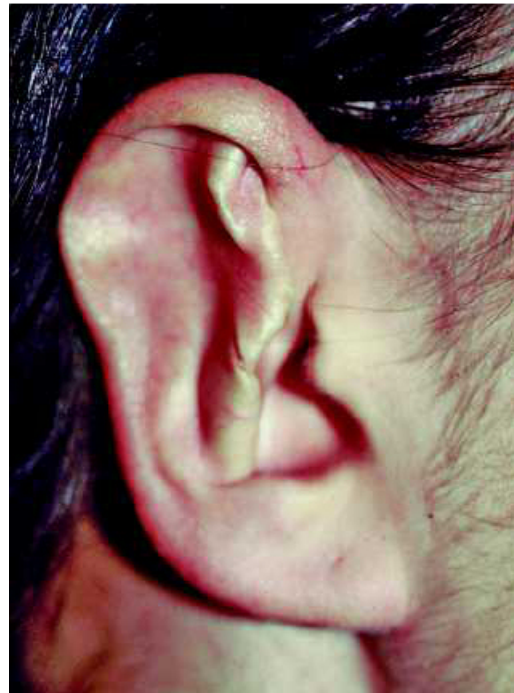

Figure 14: Collapsed ear following otopexia with complete destruction of the ear cartilage structure. Side view



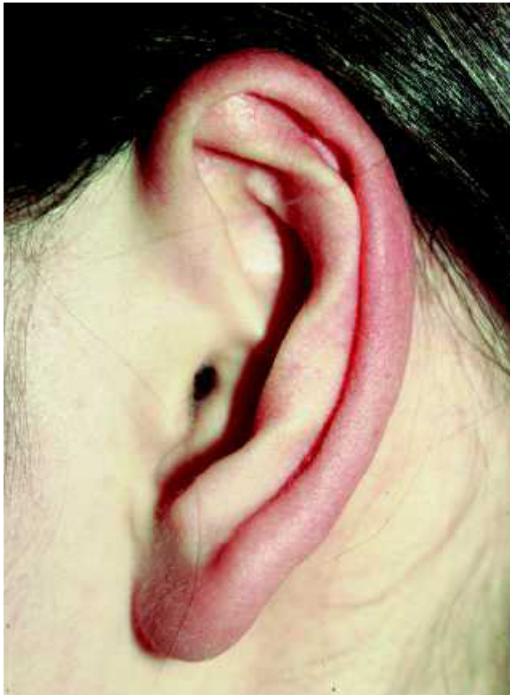

Figure 15: State following otopexia with extensive removal of ear cartilage

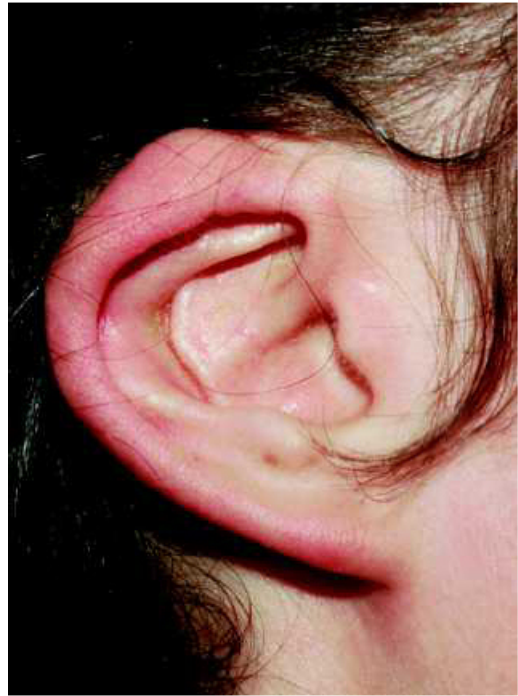

Figure 17: State following separation of the ear cartilage. The entire cavum cartilage was attached to the mastoid for cavum rotation.



Figure 16: Over-correction in the cranial part of the auricle, under-correction in the caudal auricle. This leads to the formation of what is called a 'spock ear'.

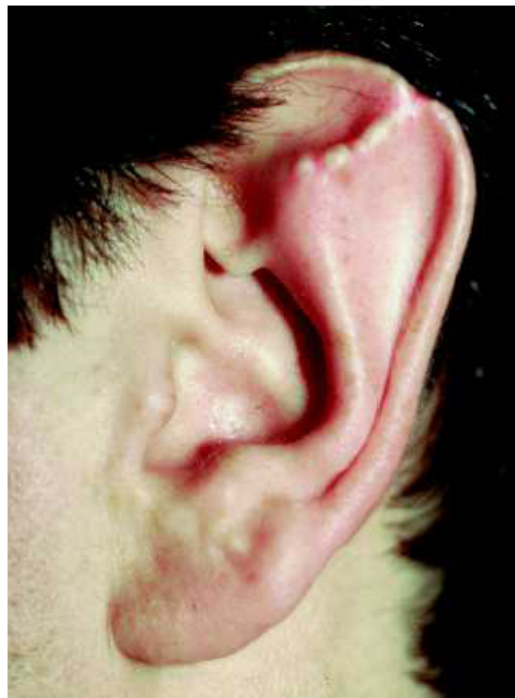

Figure 18: An unsuitable operatin procedure, namely wedge excision was carried out here to correct an apostasies.

Finally it has been determined that the correction of the protruding auricle is usually a small and relatively easy operation. However, in order to correct all forms of protruding auricles in a way that satisfies all subjective and objective criteria, several operative procedures must be managed. These must be individually adjusted to the anomaly. The choice of operation technique, the execution of the procedure and the post-operative care should be treated with the upmost care in order to avoid one or more of the complications mentioned. Their occurrence is suspected to be more frequent than is normally mentioned in the literature [110].

## References

1. Adamson PA. Otoplasty: Critical review of clinical results. *Laryngoscope* 1991; 101: 883.
2. Alexander G. Zur plastischen Korrektur absteher Ohren [Plastic correction of the protruding ears]. *Wien Klin Wschr* 1928; 41: 1217.
3. Andes C, Koch A. Die Ohrmuschelplastik - Ergebnisse und Komplikationen mit einer abgewandelten Technik nach Mustardé [Plastic surgery of the auricle -results and complications with a modified technique of Mustardé]. *Laryngo-Rhino-Otol* 1991; 70: 620-624 .
4. Argamaso RV, Lewin M. The lateral transhelical approach for correction of deformities of the external ear. *Aesth Plast Surg* 1978; 2: 357-362.
5. Argamaso RV. Ear reduction with or without setback otoplasty. *Plast Reconstr Surg* 1989; 83: 967-975.
6. Bahmer F. Keloid der hinteren Ohrmuschel: Therapie mittels Laser und „Austernschale“ [Keloid of the posterior auricle: therapy using laser and "oyster shell"]. *Z Hautkrh* 1997; 72: 785.
7. Bauer E, Wodak E. Spätergebnisse nach Ohrmuschelplastiken [Late results of otoplasty]. *Mscr Ohrenheilk und Laryngol Rhinol* 1968; 102: 468-477.
8. Beck J. Über die plastischen Operationen an Nase und Ohr [Plastic surgery of nose and ear]. *Internat Zbl Ohrenhkd* 1923; 21: 134.
9. Becker O. Correction of the protruding ear deformity. *Br J Plast Surg* 1952; 5: 187-196.
10. Becker O. Surgical correction of the abnormally protruding ear. *Arch Otol* 1949; 50: 541.
11. Benedikt M, Pirwitz KU. Minimal invasive Otoplastik [Minimally invasive otoplasty]. *HNO* 2005; 53 (3): 230-237.
12. Berghaus A. Surgical concepts for reconstruction of the auricle. History and current state of the art. *Arch Otolaryngol Head an Neck* 1986; 112: 388-397.
13. Bethmann W, Zoltan J. Operationen an der Ohrmuschel [Surgery of the auricle]. In: Bethmann W, Eds. *Methoden der plastischen Chirurgie*. Jena: Fischer; 1968. p. 267-282.
14. Biesenberger H. Plastische Operationen absteher Ohren nach Gersuny [Plastic surgery of the protruding ear using the technic of Gersuny]. *Zbl Chir* 1924; 51: 1126-1127.
15. Bisaccia E, Lugo A, Johnson B, Scarborough D. The surgical correction of protuberant ears. *Skin Therapy Lett*. 2005;10(2):7-9.
16. Black P. Correction of the flap-folded helix. *Plast Reconstr Surg* 1971; 48: 86-87.
17. Borges AF. Prominent ears: Modification of Dr. Forrest Young's technique. *Plast Reconstr Surg* 1953; 12: 208.
18. Brent B. The acquired auricular deformity. *Plast Reconstr Surg* 1977; 59: 475-485.
19. Brusis T. Die Behandlung des Otseroms mit Fibrinkleber [Treatment of otic serom with fibrin adhesive]. *HNO* 1982; 30: 272-274.
20. Bull T, Mustardé JC. Mustardé Technique in Otoplasty. *Facial Plast Surg* 1985; 2: 101-108.
21. Bulstrode NW, Huang S, Martin DL. Otoplasty by percutaneous anterior scoring. Another twist to the story: a long-term study of 114 patients. *Br J Plast Surg* 2003; 56 (2): 145-149.
22. Burstein FD. Cartilage-sparing complete otoplasty technique: a 10-year experience in 100 patients. *J Craniofac Surg* 2003; 14 (4): 521-525.
23. Caouette-Laberge L, Guay N, Bortoluzzi P, Belleville C. Otoplasty. Anterior scoring technique and results in 500 cases. *Plast Reconstr Surg* 2000; 105 (2): 504-515.
24. Chongchet V. A Method of anthelix reconstruction. *Br J Plast Surg* 1963; 16: 268-272.
25. Cloutier AM. Correction of outstanding ears. *Plast Reconstr Surg* 1961; 28: 412-416.
26. Coban YK. Visible Helical Rim Deformity Resulting from Excessive Resection of Postauricular Skin during Otoplasty. *Aesth Plast Surg* 2005; 29: 565-566.
27. Converse JM, Nigro A, Wilson F, Johnson N. A technique for surgical correction of lop ears. *Plast Reconstr Surg* 1955; 15: 411-418.
28. Converse JM. *Reconstructive plastic surgery*. 2nd ed. Philadelphia: Saunders; 1977.
29. Cosman B, et al. The surgical treatment of keloids. *Plast Reconstr Surg* 1961; 27: 335-358.
30. Crikelair GF. Another solution for the problem of the prominent ear. *Ann Surg* 1964; 160: 314-324.
31. Davis J. *Otoplasty: Aesthetic and Reconstructive Techniques*. Berlin: Springer; 1987.
32. Davis J. *Prominent ear. Aesthetic an Reconstructive Otoplasty*. Berlin: Springer; 1997
33. Davis JE. *Aesthetic Otoplasty*. In: Lewis J, eds. *The art of aesthetic plastic surgery*. Boston: Little Brown; 1989. p. 1.
34. Dufourmentel C. Chirurgie plastique de l'oreille externe [Plastic surgery of the external ear]. *La Revue du Practicien* 1958; 8 : 3097-3107.
35. Eitner E. Eine einfache Methode zur Korrektur absteher Ohren [A simple method to correct prominent ears]. *Wien Klin Wschr* 1937; 50: 1206.
36. Ely ET. An Operation for prominence of the auricle. *Arch Otolaryngol* 1881; 10: 97.
37. Erich JB. Plastic correction of the lop ear. *Proc Staff Meet Mayo Clinic* 1963; 38: 38-96.
38. Ernst H, Besserer A, Flemming J. Strahlenprophylaxe von Keloiden und Narbenhypertrophien [Prophylactic irradiation to avoid keloid and hypertrophic scars]. *Strahlentherapie* 1979; 155: 614-617.
39. Erol OO. New modification in otoplasty: anterior approach. *Plast Reconstr Surg* 2001; 107 (1): 193-202; discussion 203-205.
40. Feuerstein SS. Complications and revisions in otoplasty. *Fac Plast Surg* 1985; 2: 141-151.

41. Fissette J, Nizet JL. Evaluation de la technique de „Mustardé” dans le traitement des oreilles décollées [Evaluation of the Mustardé technique in treatment of prominent ears]. *Ann Chir Plast Esth* 1992; 37: 189-193.
42. Fregenal F, Garcia-Morato V, Salinas V. Surgical correction of lop and cup ear deformities. *Eur J Plast Surg* 1992; 15: 90-93.
43. Friedmann HS. Otoplasty. *Arch Otolaryngol* 1959; 70: 454-458.
44. Fritsch MH. Incisionless otoplasty. *Laryngoscope* 1995; 105: 1-11.
45. Fritze HE, Reich OFG. Von der Otoplastik (Ohrbildung) [About otoplasty]. In: Fritze HE Reich OFG, eds. *Die plastische Chirurgie, in ihrem weitesten Umfang dargestellt und durch Abbildungen erläutert* [Plastic surgery in detail and explained in figures]. Berlin: Hirschwald; 1945. p. 110-111.
46. Furnas D. Complications of surgery of the external ear. *Clin Plast Surg* 1990; 17: 305-318.
47. Furnas D. Correction of prominent ears by concha mastoid sutures. *Plast Reconstr Surg* 1968; 42: 189.
48. Goldstein MA. The cosmetic and plastic surgery of the ear. *Laryngoscope* 1908; 18: 826-851.
49. Gonzalez-Ulloa M. An easy method to correct prominent ears. *Br J Plast Surg* 1952; 4: 207.
50. Goodyear HM. Plastic operations for protruding ears. *Arch Otolaryngol* 1933; 18: 527-530.
51. Gosain AK, Recinos RF. A novel approach to correction of the prominent lobule during otoplasty. *Plast Reconstr Surg* 2003; 112 (2): 575-83.
52. Gruber W, Staindl O. Die modifizierte Stenström-Plastik zur Behandlung der abstehenden Ohrmuschel [The modified Stenström' technique in treatment of the prominent ear]. *Wien Med Wochenschr* 1978; 13: 397-399.
53. Haas E. *Plastische Gesichtschirurgie* [Plastic surgery of the face]. Stuttgart: Thieme; 1991.
54. Haug R. Eine Einführung neuer Methoden zur Rücklagerung hochgradig abstehender Ohrmuscheln [The first use of new techniques in correcting severely outstanding ears]. *Dtsch Med Wschr* 1894; 20: 776.
55. Heppt W, Trautmann Y. Otoplastik zur Korrektur abstehender Ohrmuscheln [Otoplasty in correction of prominent ears]. *HNO* 1999; 47: 688-694.
56. Herrmann A. Fehler und Gefahren bei Operationen am Hals, Ohr und Gesicht [Risks and failures in operations of the neck, ear and face]. Berlin: Springer; 1968. p. 197
57. Hoehn JG, Ashruf S. Otoplasty: sequencing the operation for improved results. *Plast Reconstr Surg* 2005; 115 (1): 5e-16e.
58. Horlock N, Misra A, Gault DT. The postauricular Fascial Flap as an Adjunct to Mustardé and Furnas Type Otoplasty. *Plast Reconstr Surg* 2001; 108 (6): 1487-1490; discussion 1491.
59. Jeffery SL. Complications following correction of prominent ears: an audit review of 122 cases. *Br J Plast Surg* 1999; 52 (7): 588-590.
60. Jeffrey EJ, Rohrich RJ, Gutowski KA. Otoplasty. *Plast Reconstr Surg*. 2005; 115: 60e.
61. Joseph J. Die Gestaltungsfehler der Ohren [Failures in designing of the ear]. In: Katz L, Preysing H, Blumenfeld F, eds. *Handbuch der speziellen Chirurgie des Ohres* [Handbuch der speziellen Chirurgie des Ohres]. Würzburg: Kabitzsch; 1912. p. 167.
62. Joseph J. Ohrdefekte (Otoneoplastik) [Otoplasty]. In: Joseph J, Eds. *Nasenplastik und sonstige Gesichtsplastik. 3. Abteilung* [Plasty of the nose and other plastic operations of the face 3. Section]. Leipzig: Kabitzsch; 1931. p. 717-736.
63. Jost G, Legent F, Meresse B, Ocker K. *Atlas der ästhetischen plastischen Chirurgie* [Atlas of esthetic plastic surgery]. Stuttgart: Schattauer; 1977.
64. Kastenbauer E. Spezielle Rekonstruktionsverfahren im Gesichtsbereich [Special reconstructive techniques in plastic surgery of the face]. *Arch Otorhinolaryngol* 1977; 216: 123-250.
65. Kazanjian V. Surgical treatment of congenital deformities of the ears. *Am J Surg* 1958; 95: 185-188.
66. Kelly P, Hollier L, Stal S. Otoplasty: evaluation, technique, and review. *J Craniofac Surg* 2003; 14 (5): 643-653.
67. Kischer CW, et al. Hypertrophic Scars an Keloids: A Review an New Concept Concerning their Origin. *Scan Electron Microsc* 1982; 4: 1699-1713.
68. Kompatscher P, Schuler CH, Clemens S, Seifert B, Beer GM. The Cartilage Sparing versus the Cartilage Cutting Technique: A Retrospective Quality Control Comparison of the Francesconi and Converse Otoplasties. *Aesthetic Plast Surg* 2003; 27 (6): 446-453. Epub 2004 Mar 4.
69. Koonin AJ. The Aetiology of Keloids: A Review of the Literature an a New Hypothesis. *S Afr Med J* 1964; 38: 913-916.
70. Lametschwandtner A, Staindl O. The vascular Architecture of the Keloid: A Scanning Electron Microscope Study on vascular corrosion casts. Altmeyer P et al, Eds. *Wound Healing and Skin Physiology*. Berlin Heidelberg: Springer; 1995. p. 137-151
71. Lametschwandtner A, Staindl O. Zur Angioarchitektur des Keloids [Structure of small vessels in keloids]. *HNO* 1990; 38: 202-207.
72. Lawrence WT. In Search of the Optimal Treatment of Keloids: Report of a Series an a Review of the Literature. London: Little Brown Co; 1991.
73. Lemmen M. Exzision von Keloiden nur in Ausnahmefällen [Excision of keloid is rarely indicated]. *Dt Ärztebl* 1995; 92: B-1466.
74. Marti G. Operationsresultate nach Ohrmuschelanlegeplastiken [Results of ortoplasty in prominent ears]. *HNO* 1976; 24: 134-137.
75. Mattheis S, Siegert R. Techniques in otoplasty. *HNO* 2006; 54 (8): 643-656.
76. Maurer J, Mann W, Welkobosky HJ. Zur Therapie des Othämatoms und des Otseroms [The therapy of hematome and serom of the ear]. *HNO* 1990; 38: 214-216.
77. Monks GH. Operations for correcting the deformity due to prominent ears. *Boston Med Surg* 1891; 124: 84-86.
78. Moser A, Wespi HH. Korrektur abstehender Ohrmuscheln: eine Verlaufskontrolle [Correction of prominent ears. Follow up]. *Aktuelle Probleme der Otorhinolaryngologie* 1991; 95: 97-105.
79. Mündnich K. Die wiederherstellende Ohrmuschelplastik [Plastic reconstruction of the auricle]. In: Sercer A, Mündnich K, Eds. *Plastische Operationen an der Nase und an der Ohrmuschel*. Stuttgart: Thieme; 1962. p. 325-382, 411-451.
80. Mündnich K. Stellungs- und Formanomalien der Ohrmuschel (einschl. Ohrmissbildungen) und ihre operative Behandlung [Anomalies of position and appearance (including deformities) and their operation]. *Arch Ohr-Nas-Kehlk-Heilk* 1962; 180: 395-402.
81. Mustardé JC. Effective formation of antihelix fold without incising the cartilage. In: *Transactions of the International Society of Plastic Surgeons, Second Congress, AB Wallace*. Baltimore: Williams & Wilkens; 1960.
82. Mustardé JC. The correction of prominent ears. Using simple mattress sutures. *Br J Plast Surg* 1963; 16: 170-176.

83. Mustardé JC. The treatment of prominent ears by buried mattress sutures: a ten-year survey. *Plast Reconstr Surg* 1967; 39: 382-386.
84. Nagel F. Fehler bei der Otoplastik - ihre Verhütung nach Korrektur [Failures in otoplasty - prevention and reconstruction]. In: Düben H et al., Eds. Fehler und Gefahren in der plastischen Chirurgie. Stuttgart: Thieme; 1978.
85. Nielsen F, Kristensen S, Crawford M. Prominent Ears: A follow-up study. *J Laryngol Otol* 1985; 95: 221-224.
86. Nolst-Trenite GJ. A Modified Anterior Scoring Technique. *Facial Plastic Surg* 1994; 10: 255-266.
87. Park Ch, Chung S. Reverse-flow postauricular arterial flap for auricular reconstruction. *Ann Plast Surg* 1989; 23: 369.
88. Peker F, Celikoz B. Otoplasty: anterior scoring and posterior rolling technique in adults. *Plast Reconstr Surg* 2000; 105 (2): 504-515.
89. Pierer H. Rekonstruktion und Replantation der Ohrmuschel [Reconstruction and replantation of the auricle]. *Chir Plast Reconstr* 1967; 3: 112-124.
90. Pitanguy I, Flemmings I. Plastische Eingriffe an der Ohrmuschel [Plastic surgery of the external ear]. In: Naumann HH, Eds. Kopf- und Halschirurgie. Band 3. Stuttgart: Thieme; 1976. p. 1-69.
91. Psillakis JM. Prominent ears: evolution of a surgical technique. *Aesthetic Plast Surg* 1979; 3: 147-152.
92. Radonich MA, Bisaccia E, Scarborough D. Reduction of Conchal Enlargement and/or Anterolateral Rotation: Otoplasty by the Cosmetic Dermatologic Surgeon. *Dermatol Surg* 2002; 28 (6): 469-474.
93. Ragnell A. A new method of shaping deformed ears. *Br J Plast Surg* 1951; 4: 202.
94. Rasinger GA, Arnoldner M, Wicke W. Spätergebnisse der Korrektur abstehender Ohrmuscheln [Late results after surgical correction of prominent ears]. *Laryngo-Rhino-Otol* 1983; 62: 328-330.
95. Rhys-Evans PH. Prominent ears and their surgical correction. *J Laryngotol* 1981; 95: 881-892.
96. Rhys-Evans PH. The anterior scoring technique. *Fac Plast Surg* 1985; 2: 93.
97. Robiony M, Costa F, Politi M. Pitanguy's method of protruding ear correction from our own experience: review of 80 cases. *J Oral Maxillofac Surg* 2001; 59 (1): 9-14.
98. Sercer A, Mündnich A. Plastische Operationen an der Nase und an der Ohrmuschel [Plastic operations of nose and external ear]. Stuttgart: Thieme; 1962.
99. Siegert R, Weerda H. Die Technik nach Crikelair und der abstehende Lobulus [The Cricalair technique for correction of the protruding lobulus]. *Laryngo-Rhino-Otol* 1997; 76: 715.
100. Siegert R, Weerda H. The Crikelair Technique for Correction of the Protruding Lobule. *Eur Arch Otorhinolaryngol* 1998; 255: 88.
101. Spira M. Otoplasty: what I do now - a 30-year perspective. *Plast Reconstr Surg* 1999; 104 (3): 834-841.
102. Staindl O. Free grafts in Scar correction. *Facial Plastic Surgery* 1989; 6:14-20.
103. Staindl O. Narben und Narbenkorrektur [Scars and correction of scars]. *HNO* 1983; 31: 183-187.
104. Staindl O. Über Misserfolge und Komplikationen nach Ohrmuschel-anlegeplastiken [Failures and complications after otoplasty]. *Laryngo-Rhino-Otol* 1986; 65: 646-657.
105. Staindl O. Zur Korrektur der abstehenden Ohrmuschel [Correction of protruding ear]. *HNO* 1980; 28: 234-240.
106. Stal S, Spira M. Long-term results in otoplasty. *Fac Plast Surg* 1985; 2: 153-165 .
107. Stenström SJ. A „Natural“ technique for correction of congenitally prominent ears. *Plast Reconstr Surg* 1963; 32: 509-518.
108. Stenström SJ. Cosmetic deformities of the ears. In: Graff WC, Smith JW, Eds. *Plastic surgery: a concise guide to clinical practice*. Boston: Little Brown & Co; 1968. p. 522.
109. Stucker FJ, Vora NM, Lian TS. Otoplasty: an analysis of technique over a 33-year period. *Laryngoscope* 2003; 113 (6): 952-956.
110. Tanzer RC. Reconstruction of the auricle. In: Goldwyn RM, Eds. *The unfavorable result in plastic surgery*. Boston: Little Brown; 1972. p. 147-157.
111. Tanzer RC. The correction of prominent ears. *Plast Reconstr Surg* 1962; 30: 236-246.
112. Tolleth H. Artistic anatomy, dimensions and proportions of the external ear. *Clin Plast Surg* 1978; 5: 337-345.
113. Vecchione TR. Needle scoring of the anterior surface of the cartilage in otoplasty. *Plast Reconstr Surg* 1979; 64: 568.
114. Walter C. Cartilage incision and excision technique. *Fac Plast Surg* 1994; 10: 277-286.
115. Walter C. Revision otoplasty and special problems. *Fac Plast Surg* 1994; 10: 298-308.
116. Weerda H, Siegert R. Complications after Otoplasty and their Treatment. *Eur Arch Otorhinolaryngol* 1998; 255: 88.
117. Weerda H, Siegert R. Complications in otoplastic procedures. *Face* 1998; 1: 169-175
118. Weerda H, Siegert R. Complications in otoplastic surgery and their treatment. *Facial Plast Surg* 1994; 10: 287-297.
119. Weerda H, Siegert R. Die Komplikationen der Otoplastik und ihre Behandlung [Complications in otoplasty and their treatment]. *Laryngo-Rhino-Otol* 1997; 76: 716.
120. Weerda H, Siegert R. Komplikationen der Ohrmuschel-Anlegeplastik und ihre Behandlung [Complications in otoplasty and their treatment]. *Laryngo-Rhino-Otol* 1994; 73: 394-399.
121. Weerda H, Siegert R. Otoplastic Procedures an the Treatment of Complications. In: Bull, Eds. *Aesthetic Facial Surgery*. Reinbek: Einhorn-Press-Verlag; 1999.
122. Weerda H, Siegert R. Rekonstruktion der Ohrmuschel [Reconstruction of the auricle]. In: Kastenbauer ER, Tardy ME, Eds. *Ästhetische und Plastische Chirurgie an Nase, Gesicht und Ohrmuschel*. Stuttgart: Thieme; 1999.
123. Weerda H. Anomalien des äußeren Ohres [Anomalies of the external ear]. In: Naumann HH, Helms J, Herberhold C, Kastenbauer E, Eds. *Otorhinolaryngologie in Klinik und Praxis*. Band 1. Ohr. Stuttgart New York: Thieme-Verlag; 1994. p. 488-499.
124. Weerda H. Chirurgie der Ohrmuschel. Verletzungen, Defekte und Anomalien [Surgery of the auricle. Injuries, defects and anomalies]. Stuttgart: Thieme; 2004.
125. Weerda H. Die Ohrmuschelplastik [Otoplasty]. In: Ramanzadeh R, Eds. *Alloplastische Verfahren und mikrochirurgische Maßnahmen*. Reinbek: Einhorn 1994. p. 543-548.
126. Weerda H. Geschichte der Otoplastik [History of Otoplasty]. *Laryngo-Rhino-Otol* 1997; 76: 715.
127. Weerda H. Hals-, Nasen-, Ohrenheilkunde. 2. Auflage. Stuttgart: Enke; 1994.
128. Weerda H. Kompendium plastisch-rekonstruktiver Eingriffe, 4. Auflage. Hamburg Norderstedt: Ethicon; 1992.

129. Weerda H. Plastic surgery of the ear. In: Kerr AG, Eds. Scott Brown's diseases of the ear, nose and throat. 5th ed. London: Butterworth; 1987. p. 3.
130. Weerda H. Plastic surgery of the ear. In: Kerr AG, Eds. Scott Brown's Otolaryngology, 6th ed. London: Heinemann - Butterworth; 1997. p. 3/8/1-21.
131. Weerda H. Plastisch-rekonstruktive Chirurgie im Gesichtsbereich. Ein Kompendium für Problemlösungen [Plastic reconstructive surgery of the face. Compendium of trouble-shooting]. Stuttgart: Thieme; 1999.
132. Widgerow AD. Revision Otoplasty: The contracted Antihelical fold. *Plast Reconstr Surg* 2002; 110 (3): 827-30.
133. Yugueros P, Friedland JA. Otoplasty: The experience of 100 Consecutive Patients. *Plast Reconstr Surg* 2001; 108 (4): 1045-1053.

**Corresponding author:**

Dr. Vanessa Siedek  
Clinic for Ear, Nose and Throat Medicine, Ludwig Maximilians University Munich, Grosshadern Clinic, Marchioninistraße 15, 81377 Munich, Germany  
vanessa.siedek@med.uni-muenchen.de

**Please cite as**

Staindl O, Siedek V. Complications of auricular correction. *GMS Curr Top Otorhinolaryngol Head Neck Surg*. 2007;6:Doc03.

**This article is freely available from**

<http://www.egms.de/en/journals/cto/2008-6/cto000037.shtml>

**Copyright**

©2008 Staindl et al. This is an Open Access article distributed under the terms of the Creative Commons Attribution License (<http://creativecommons.org/licenses/by-nc-nd/3.0/deed.en>). You are free: to Share – to copy, distribute and transmit the work, provided the original author and source are credited.