

Case Report: A Simple Thoraco - Abdominal Flap to Reconstruct Wide Defect of Radical Mastectomy in Squamous Cell Carcinoma of Breast

Putu Anda Tusta Adiputra^{*}, I Wayan Sudarsa

Division of Surgical Oncology, Surgery Department, Udayana University, Sanglah General Hospital, Denpasar, Bali, Indonesia

Abstract

Citation: Adiputra PAT, Sudarsa IW. Case Report: A Simple Thoraco - Abdominal Flap to Reconstruct Wide Defect of Radical Mastectomy in Squamous Cell Carcinoma of Breast. Open Access Maced J Med Sci. 2019 Apr 30; 7(8):1356-1359. <https://doi.org/10.3889/oamjms.2019.303>

Keywords: Thoraco-abdominal flap; Squamous cell carcinoma; Mastectomy

***Correspondence:** Putu Anda Tusta Adiputra, Division of Surgical Oncology, Surgery Department, Udayana University, Sanglah General Hospital, Denpasar, Bali. E-mail: andatusta@unud.ac.id

Received: 09-Mar-2019; **Revised:** 15-Apr-2019; **Accepted:** 16-Apr-2019; **Online first:** 29-Apr-2019

Copyright: © 2019 Putu Anda Tusta Adiputra, I Wayan Sudarsa. This is an open-access article distributed under the terms of the Creative Commons Attribution-NonCommercial 4.0 International License (CC BY-NC 4.0)

Funding: This research did not receive any financial support

Competing Interests: The authors have declared that no competing interests exist

BACKGROUND: Squamous cell carcinoma (SCC) of the breast is very unusual. Thoraco-abdominal (TA) flap is a simple flap, and it is a rotation advancement fasciocutaneous flap. Here, we present a case of using TA flap for chest wall reconstruction in quick in-quick outpatient.

CASE PRESENTATION: A Russian woman 48 years old presented enlarging lump on her left breast for the last 5 years. She was diagnosed as stage IV low-differentiated breast cancer luminal B and had a history of 4 cycles chemotherapy. Patient getting worsening and no response to chemotherapy. We decided to perform palliative radical mastectomy to improve quality of life. Primary skin closure was not possible due to the wide defect of skin and soft tissue. We decided to use TA flap to cover the defect. Histopathology result was compatible with SCC.

CONCLUSION: TA flap can be the choice in patients with a wide defect of skin and soft tissue after a radical mastectomy. Given its simplicity and shorter operative time, TA flap is an ideal option for quick in-quick outpatient.

Introduction

Squamous cell carcinoma (SCC) of the breast is very unusual. The incidence of primary SCC of the breast was 0.04-0.1% of all breast cancer. In 1908, the SCC of the breast was first time reported, and until 2002, there were 85 cases [1]. SCC of the breast may originate from a neoplasm of the breast skin or spreading of SCC another side of the body. Breast metastasis of SCC may be from skin, cervix, pharynx, stomach, and lung. Pure SCC of the breast can be from the epidermis, the nipple or epithelium of a deep-seated dermoid cyst or metaplasia on chronic inflammation [2].

The wide defect produced during surgery, thoraco-abdominal (TA) flap is a simple flap and

suitable for quick in-quick outpatient. This flap is a rotation advancement fasciocutaneous flap. This flap uses the skin and subcutaneous tissue of the anterior abdominal. Here, we present a case of using TA flap for chest wall reconstruction in a patient with SCC of the breast. This patient was not in her optimum state, so we choose the best action for quick in-quick outpatient.

Case Presentation

A-Russian woman 48 years old presented enlarging lump on her left breast for the last 5 years. Patient neither visited the doctor nor been examined

or treated. On 2014, lump getting bigger and patient lost 7 kg during a month. She was hospitalised in Moscow for follow up examination. CT scan showed a mass in the left breast, lymph node enlargement on the left axilla, and pleural effusion on the left lung. The core biopsy revealed as low-differentiated breast cancer, luminal type-B. MRI brain showed no metastasis.

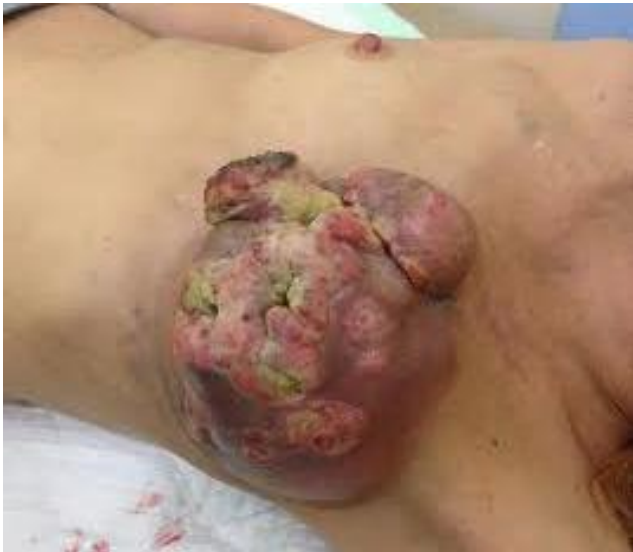

Figure 1: Lump with an ulcer on the left breast

Patients had history 4 cycles of chemotherapy (Adriamycin + Cyclophosphamide 2 cycles and switched to Docetaxel 40 mg/m² + Capecitabine 2000 mg/m² per day, 1-14 days about 2 cycles). There was no response to chemotherapy but follow up on the chest and abdominal CT scan, no fluid in the lung, and no metastatic on the liver. Laboratory finding was within normal limit. The patient then continued her treatment at the place residence in Bali.

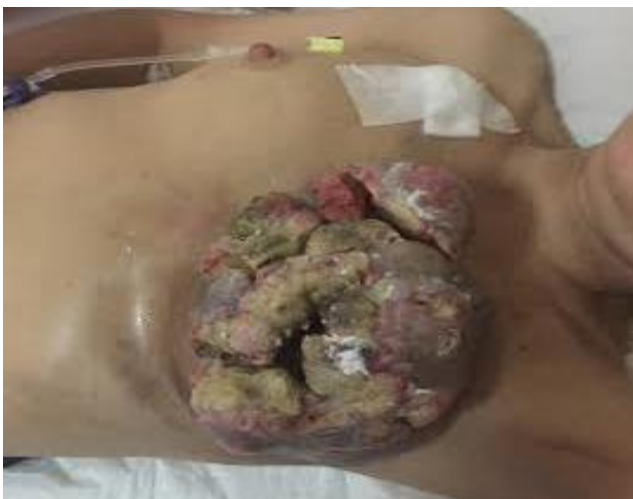

Figure 2: Lump with no response after 6 cycles of chemotherapy

Reevaluation, lump located centrally in the left breast with an ulcer, poorly defined border, measuring about 14 centimetres across, nipple areola complex

was involved without fixation to the chest wall (Figure 1).

Enlargement of the left lymph node was apparent and multiple. So, based on TNM staging, she diagnosed stage IV breast cancer (T4bN2M1). She continued with Docetaxel 65 mg/m² + Capecitabine about 2 cycles.

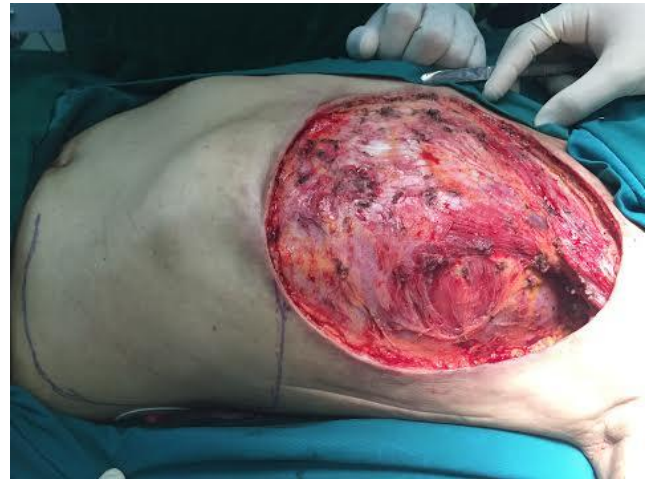

Figure 3: Wide defect of skin and soft tissue after radical mastectomy

Restaging post-chemotherapy course was complicated. She getting worse and no response to chemotherapy was noticed. The wound became smell odour (Figure 2).

Laboratory findings result in anaemia and hypoalbuminemia. We decided to perform palliative radical mastectomy to improve quality of life. Primary skin closure was not possible due to the wide defect of skin and soft tissue (Figure 3).

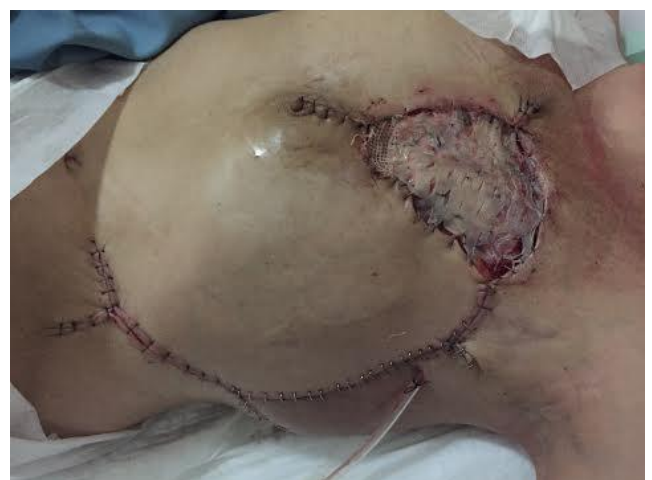

Figure 4: The defect was covered by TA flap and split-thickness skin graft on the medial side

Considering the patient's condition was not in an optimum state, we have to choose simple action for reconstruction. We decided to use thoraco-abdominal (TA) flap to cover the defect and defect on

the medial side we used a split-thickness skin graft from the left thigh (Figure 4).

Histopathology result was compatible with SCC (Figure 5). After the operation, she started three cycles of chemotherapy Gemcitabine 1800 mg, and Carboplatin 600 mg then continue with Tamoxifen 20 mg daily and Goserelin acetate 3.6 mg per month.

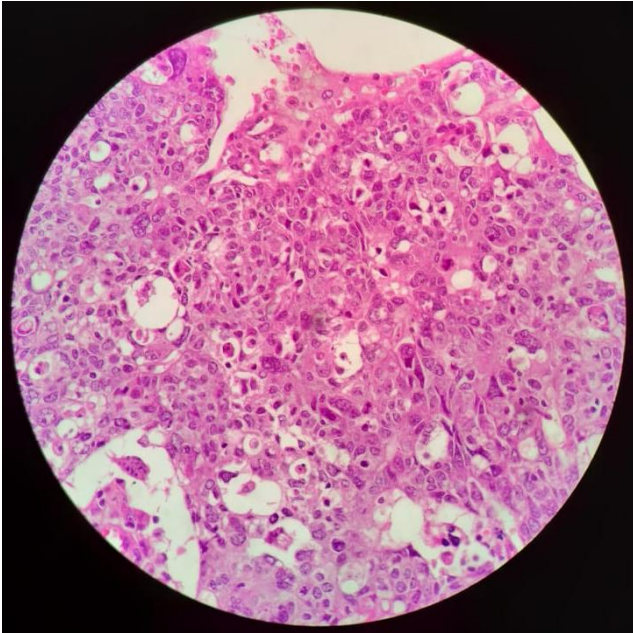


Figure 5: Histopathology result

The TA flap was viable, and there was no complication (Figure 6). The wound was well healed after two months of the operation (Figure 7).

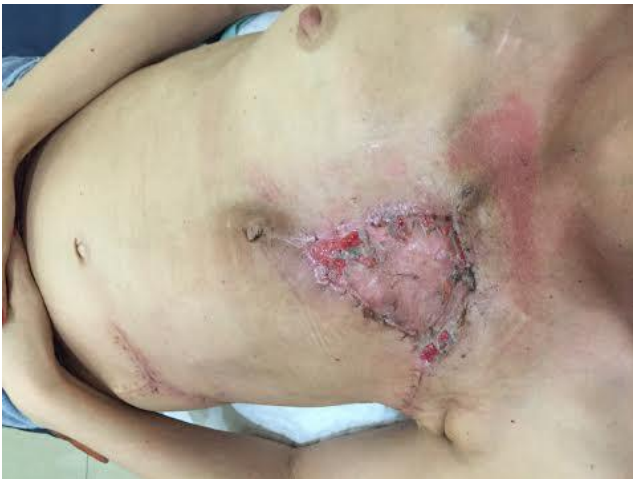

Figure 6: Wound healing after three weeks of operation

Discussion

This patient in the early had diagnosed as low-differentiated breast cancer, luminal type-B and

has the change to be SCC after mastectomy. This is a primary cause of SCC of the breast.

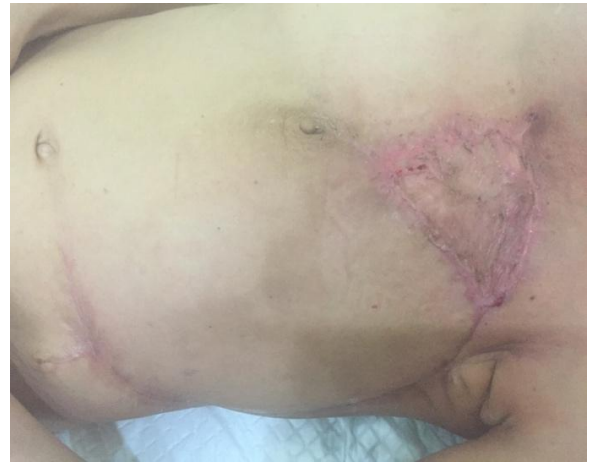

Figure 7: The scar slowly disappeared after two months of operation

SCC of the breast is the tumour of the elderly group [3]. Based on the literature, tumours frequently huge and can expand more than 5 cm in diameter. This case was 48 years old woman and the presented lesion measured 14 x 11 x 8.5 cm and would probably be the first case of this size. In Menes et al., study, SCC was associated with a lower risk of lymph node metastasis at the tumour site and a significant risk of distant metastasis without lymph node involvement [4]. In our case, she had distant metastatic to the lung without involvement malignant metastatic of the lymph node.

The result of histopathology examination on the removed tumour was SCC grade III. No metastatic deposit on 14 lymph nodes observed. Microscopically, the lump is consisting of malignant epithelium, invasive into connective tissue, partially covered by the epidermis. Mitotic index more than 20. No evident of intralymphatic and intravascular invasion. There also some intraductal carcinoma.

Approximately 30% of the patients with SCC of the breast will spread to other organs [5]. The treatment of pure SCC of the breast is unclear. Dejager et al. showed that cisplatin chemotherapy could be thought over in the chemotherapy regimen. In this type of cancer, Weigel et al. recommended the combination treatment using radiotherapy, because SCCs are radiosensitive. The small size of the primary SCCs of the breast could be managed with lumpectomy and axillary dissection followed by radiotherapy [6].

A lump of this patient was 14 cm, and she had a metastatic process on her left lung. The patient had chemotherapy like an adenocarcinoma in the same stage. After chemotherapy 6 cycles, pleural effusion on the lung was disappeared, but the lump had no response to chemotherapy and getting worsen with unstable laboratory result. The patient got anaemia

and hypoalbuminemia at the end of 6 cycles of chemotherapy. Radical mastectomy was performed to excise the lump. Surprisingly, histology of removal tumour after mastectomy showed differences in the result. The results were SCC which might be the reason why the lump did not respond to chemotherapy. Because the wide defect produced during surgery, and considering this patient was not in her optimum state, we have already chosen thoraco-abdominal (TA) flap as a simple flap for this patient.

The TA flap is a simple flap and suitable for quick in-quick outpatient. TA flap is a rotation advancement fasciocutaneous flap. This flap uses the skin and subcutaneous tissue of the anterior abdominal [7]. This flap used a mark of two sets of direct perforating segmental arteries. The medial border was arising from the deep epigastric arcade at the lateral border of the rectus abdominis. The lateral border was arising from the lumbar and subcostal arteries at the level of the anterior border of the latissimus dorsi [8]. Sub fascia anastomoses are present between the medial and lateral perforators. The border of the flap is anterior axillary line laterally for medially based flap and midline medially for the laterally based flap with the horizontal plane at the level of anterior superior iliac spine inferiorly [9]. To cover the defects on the medial side of the TA flap, a split-thickness skin graft from the left thigh was used. We used two vacuum drains in the axilla and under the TA flap. The skin closure used skin stapler and 2-0 nylon suture. This operation was taken 4 hours long.

The prognosis of SCC of breast cancer was still controversial [10]. Several cases showed a slowly clinical presentation and had a good prognosis. But some studies showed SCC of the breast had an aggressive clinical presentation, and the outcome was similar to poorly differentiated breast cancer [4]. In this case, she is still in our routine follow up and started on three cycles adjuvant chemotherapy then continue with hormonal therapy Tamoxifen 20 mg daily and Goserelin acetate 3.6 mg per month. The lung metastasis was relapsed in 13 months follow up after surgery.

In conclusion, pure SCC of the breast is an extremely unusual malignancy, so a primary SCC of the breast is an extraordinary phenomenon. Based on the literature, outcome and appropriate approach for treatment is still controversial. Every new case report would help to determine the right management to this disease.

In this case, we had got different histopathology finding after mastectomy. Learn from here; we should think probability another diagnosis when we accept a new case from the patient who had been treated by a doctor before, moreover without improvement of the disease. For surgery approach,

TA flap can be the choice in patients with a wide defect of skin and soft tissue after a radical mastectomy. In view of its simplicity and shorter operative time, TA flap is an ideal option for quick in-quick outpatient.

Acknowledgement

Authors thanks to the patient and colleagues who take photos during the operation.

References

- Gupta C, Malani AK, Weigand RT, Rangenini G. Pure primary squamous cell carcinoma of the breast: A rare presentation and clinicopathologic comparison with usual ductal carcinoma of the breast. *Pathol Res Pract*. 2006; 6:465-469. <https://doi.org/10.1016/j.prp.2006.01.006> PMID:16497446
- Weigel RJ, Ikeda DM, Nowels KW. Primary squamous cell carcinoma the breast. *South Med J*. 1996; 89:511-515. <https://doi.org/10.1097/00007611-199605000-00013> PMID:8638180
- Behranwala KA, Nasiri N, Abdullah N, Trott PA, Gui GP. Squamous cell carcinoma of the breast: Clinico-pathologic implications and outcome. *Eur J Surg Oncol*. 2003; 29:386-389. <https://doi.org/10.1053/ejso.2002.1422> PMID:12711295
- Gürsel B, Bayrak IK, Cakir S, Yildiz L, Gürsel M, Yücel I. Primary squamous cell carcinoma of the breast: A case report and review of the literature. *Turkish Journal of Cancer*. 2007; 37:114-116.
- Flikweert ER, Hofstee M, Liem MSL. Squamous Cell Carcinoma of the Breast: A Case Report. *World J Surg Oncol*. 2008; 6:135. <https://doi.org/10.1186/1477-7819-6-135> PMID:19099605 PMID:PMC2626594
- Dejager D, Redlich PN, Dayer AM, Davis HL, Komorowski RA. Primary squamous cell carcinoma of the breast: sensitivity to cisplatin-based chemotherapy. *J Surg Oncol*. 1995; 59:199-203. <https://doi.org/10.1002/jso.2930590313> PMID:7609529
- Das DK, Choudhury UC. "Thoraco-Abdominal Flap"- A Simple Flap for Skin and Soft Tissue Cover Following Radical Surgery for Locally Advance Breast Cancer-The Malaysian Experience. *International Journal of Collaborative Research on Internal Medicine & Public Health*; 2013; 5:398-406.
- Matros E, Disa JJ. Uncommon Flaps for Chest Wall Reconstruction. *Semin Plast Surg*. 2011; 25:55-59. <https://doi.org/10.1055/s-0031-1275171> PMID:22294943 PMID:PMC3140228
- Deo SV, Purkayastha J, Shukla NK, Asthana S. Myocutaneous versus thoraco-abdominal flap cover for soft tissue defects following surgery for locally advanced and recurrent breast cancer. *J Surg Oncol*. 2003; 83:31-35. <https://doi.org/10.1002/jso.10236> PMID:12722094
- Pramesh CS, Chaturvedi P, Saklani AP, Badwe RA. Squamous cell carcinoma of breast. *J Postgrad Med* 2001; 47:270-271.