

Acquired diaphragmatic hernia in pediatrics after living donor liver transplantation

Three cases report and review of literature

Kai Wang, MD, PhD, Wei Gao, MD, PhD*, Nan Ma, MD, Xing-Chu Meng, MD, PhD, Wei Zhang, MD, PhD, Chao Sun, MD, Chong Dong, MD, Bin Wu, MD, PhD

Abstract

Rationale: Diaphragmatic hernia (DH) in pediatrics following living donor liver transplantation (LDLT) has been seldom reported in the past.

Patient concerns: We report successful diagnosis and treatment of three pediatric cases with DH secondary to LDLT, discuss the possible etiology, and review the relevant literature.

Diagnoses: The primary disease was biliary atresia and DH was diagnosed by computed tomography scan or x-ray of chest.

Interventions: Laparotomy was performed successfully to repair the DH.

Outcomes: The respiratory and digestive function was gradually recovered in 1 to 2 weeks after repair operation. In 2 to 8 months follow-up, patients were asymptomatic without any respiratory or digestive complications.

Lessons: DH post-LDLT should be recognized as a possible complication when a left lateral segment graft is used. Careful clinical examination and prompt surgery could minimize complications.

Abbreviations: BA = biliary atresia, CT = computed tomography, DH = diaphragmatic hernia, ESLD = end-stage liver diseases, GRWR = graft weight/recipient body weight ratio, LDLT = living donor liver transplantation, LE = laparoscopic exploration, LLS = left lateral segment, LT = liver transplantation, MP = methylprednisolone, Tac = tacrolimus.

Keywords: diaphragmatic hernia, living donor liver transplantation, pediatric

1. Introduction

Since donor shortage became more severe for patients with end-stage liver diseases (ESLD), liver transplantation (LT) with partial grafts, including living donor liver transplantation (LDLT) and split LT, is being paid more attention, due to its advantage of significantly shortening waiting time.^[1] Diaphragmatic hernia (DH) is one of the rare complications occurred in pediatric LT, accompanying with multiple patho-physiological factors.^[2] DH is usually urgent and requires speedy intervention by surgical

treatment. From August 2000 to April 2017, 680 pediatric patients have received LT in our center, and more than half received LDLT. Among which, 3 patients suffered from DH. We, here, report successful diagnosis and treatment of the 3 pediatric cases with DH secondary to LDLT and review the literatures to investigate and analyze the possible etiology.

2. Cases report

In total 680 pediatric patients, 471 patients received partial graft LT, in which 407 patients received LDLT and 64 patients received split LT. In pediatric LDLT, 3 cases were diagnosed of DH. The primary diagnosis in these children were biliary atresia (BA) and all of them were performed LDLT at the age of <1 (Table 1). Two of the 3 patients received Kasai operations pre-LDLT. Case 1, 2, and 3 were 9-month-old male, 6-month-old female, and 2-year-old male, who received LDLT from father, mother, and father at 6-month-old, 5-month-old, and 7-month-old, respectively. All LDLT procedures and the postoperative courses were uneventful.

All subjects signed the Informed Consent Form. The study protocol was approved by the Ethics Committee of the hospital and the study was also conducted in accordance with the principles delineated in the Declaration of Helsinki.

The operative modes of LDLT were piggy-back and the donor grafts types were left lateral segment (LLS). In the construction of outflow tract, the hepatic veins of recipients were modified into triangular type anastomosed to left hepatic vein of donor grafts. The hepatic artery was anastomosed with end to end, and the portal vein of recipients was beveled and interruptedly anasto-

Editor: Mohamed Fahmy.

Ethical approval: All subjects signed the Informed Consent Form. The study protocol was approved by the Ethics Committee of the hospital and the study was also conducted in accordance with the principles delineated in the Declaration of Helsinki.

This study is granted by National Nature Science Foundation of China (No. 81570592).

The authors have no conflicts of interest to disclose.

Key Laboratory of Organ Transplantation of Tianjin, Department of Transplant Surgery, Tianjin First Center Hospital, Tianjin, China.

* Correspondence: Wei Gao, No. 24, Fukang Road, Nankai District, Tianjin 300192, China (e-mail: gao-wei@medmail.com.cn).

Copyright © 2018 the Author(s). Published by Wolters Kluwer Health, Inc. This is an open access article distributed under the Creative Commons Attribution License 4.0 (CCBY), which permits unrestricted use, distribution, and reproduction in any medium, provided the original work is properly cited.

Medicine (2018) 97:15(e0346)

Received: 18 December 2017 / Received in final form: 25 January 2018 /

Accepted: 14 March 2018

<http://dx.doi.org/10.1097/MD.0000000000010346>

Table 1**Demographic data of patients in DH pre-, intra-, and post-LDLT.**

Case	Sex	Age at LDLT	Diagnosis	Previous surgery	BMI	PELD score	Graft type	GRWR	Operation types of LDLT	Total operation time	Abdominal closure	Immunosuppressant
1	M	6 mo	BA	None	19.08 kg/m ²	24	LLS	2.7%	Piggy-back	520 min	Formal	Tac + MP
2	F	5 mo	BA	LE	14.07 kg/m ²	11	LLS	2.5%	Piggy-back	470 min	Formal	Tac + MP#
3	M	7 mo	BA	LE	19.40 kg/m ²	23	LLS	3.0%	Piggy-back	535 min	Formal	Tac + MP#

BA = biliary atresia, BMI = body mass index, F = female, GRWR = graft weight/recipient body weight ratio, LE = laparoscopic exploration, LLS = left lateral segment, M = male, MP = methylprednisolone, PELD = pediatric end-stage liver disease, Tac = tacrolimus, # = Tac combined MP in the first 3 months post-LDLT, then followed Tac monotherapy.

mosed to grafts' portal vein end to end. Roux-en-Y hepaticojejunostomy was performed, no matter whether the recipients had received Kasai operation pre-LDLT or not.

Immunosuppression regimen was tacrolimus (Tac) combined with methylprednisolone (MP) in the first 3 months post-LDLT, then followed by Tac mono-therapy. No complications were found prior to DH.

Three pediatric recipients were diagnosed with DH post-LDLT (Table 2). Case 1 and case 2 were diagnosed with DH in <3 months, whereas DH was found in case 3 at 16 months post-LDLT. The symptoms of DH in case 1 were mainly respiratory distress with emergent cyanosis. In the early stage of DH, the degree of blood oxygen saturation was down to 70%, and could be relieved by oxygen inhalation. However, respiratory distress and cyanosis symptom re-appeared without oxygen therapy. Right DH was confirmed by urgent chest computed tomography (CT) scan. Other symptom in case 1 included mild dyspepsia for >2 weeks. The symptom of DH in case 2 was early stage mild dyspepsia. The patient was diagnosed as reversed stomach by chest x-ray at the beginning and conservative therapy was adopted for several months. Twelve months later, gastrointestinal symptoms deteriorated, accompanied by anepithymia and vomiting, left DH was then diagnosed in the operation. Case 3 recovered successfully in the following year post-LDLT but presented symptoms of digestive obstruction, such as high fever, frequent vomiting, grievous abdominal distention, and pain. When patient was admitted to hospital, CT scan showed right DH.

Three pediatric patients were performed DH repair operations followed by chest CT scan or x-ray diagnosis (Fig. 1). All surgical repairs were performed by laparotomy along the incision of LT. A 2 cm × 2 cm and a 2 cm × 3 cm post-medial defect were found in the right diaphragm in case 1 and case 3, respectively. In case 2, a 2 cm × 2 cm front medial defect was found in the left diaphragm. Defect in case 1 was extended laterally to return the herniated content back into abdomen, while the herniated contents in case 2 and case 3 were easily returned without extending the defect. Herniated contents included partial intestines among all 3

pediatric patients and partial colon in case 1, proximal stomach in case 2, distal stomach and intestinal loop in case 3, respectively. In case 1 and case 2, the bowel looked viable, however, the herniated intestinal loop in case 3 showed obvious sign of ischemic damage, and Roux-en-Y hepaticojejunostomy was re-performed. Defects in all cases were closed by primary closure without mattresses. The 2 right DH patients were each inserted with a chest tube, whereas no tube was placed in the left DH patient.

Postoperative courses were uneventful, and respiratory and digestive function was gradually recovered in 1 to 2 weeks post repair operation for all 3 cases. At 2 to 8 months follow-up, patients were asymptomatic, without any respiratory or digestive complications.

3. Discussion

The most common surgical complications after pediatric LDLT are biliary stricture, biliary leakage, portal vein complications, and hepatic artery thrombosis.^[3] DH post-LT is very rare, however, was mostly found in pediatric recipient. Close to 30 cases (27 cases) of DH post-LT in pediatrics have been reported in recent 10 years (Table 3).^[2,4-11] All reported patients received grafts on the left side, including left lateral segment (92.6%) and left lobe (7.4%). As to the site of DH, it was more frequent to be on the right side (25 cases, 88%), compared with only 1 case on the left side and 1 case on both sides. In our hospital, the morbidity of pediatric DH post-LDLT was 0.74% (3/407), which is similar to that in other transplant centers. Although the incidence of DH is lower than other complications, the effect of DH can be dramatic and should be paid more attention and be disposed in emergency.

The potential risk factors of DH post-pediatric LDLT include surgical trauma during hepatectomy, condition of left lateral grafts, increased pressure of intra-abdomen, thin musculature of the diaphragm, malnutrition, and immunosuppressants administration.^[12] Receiving partial grafts is common, especially for LLS in pediatric LDLT. Majority of reported DH have been left lobe

Table 2**Clinical characteristics of pediatric patients related to DH.**

Case	Chief complains	Period between LDLT and DH	Period between DH and DH repair operations	Site	Operation of DH	Follow-up period post-DH	Prognosis
1	RD	3 mo	In emergency	Right posteromedial	Laparotomy	10 mo	No recurrence
2	GS	1 mo	13 mo later	Left front medial	Laparotomy	9 mo	No recurrence
3	GS	16 mo	In emergency	Right posteromedial	Laparotomy	4 mo	No recurrence

DH = diaphragmatic hernia, GS = gastrointestinal symptoms, LDLT = living donor liver transplantation, RD = respiratory distress.

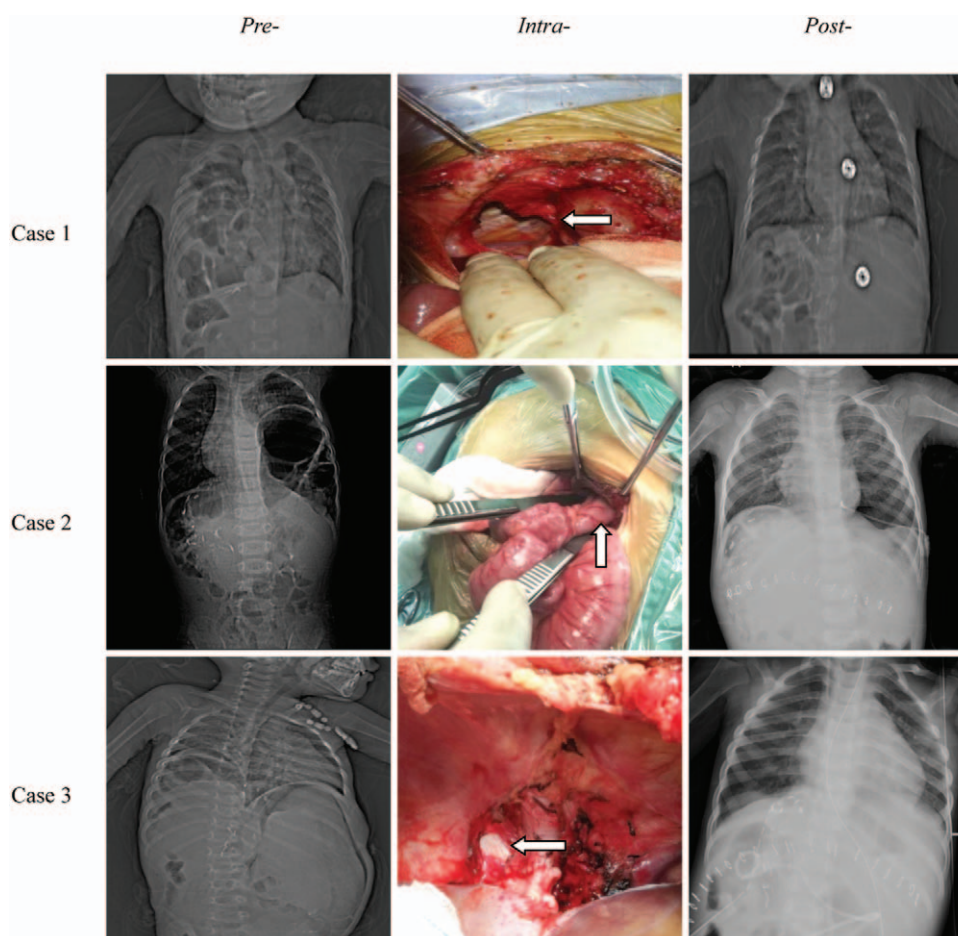


Figure 1. Chest computed tomography scan or x-ray of the patients pre-, intra-, and post-repair operation of DH (case 1 and case 3 were both right DH and case 2 was left DH). 1. Arrows head the position of DH intra-operation. 2. Words on the top of the columns means the time of images. 3. Words on the left of the rows means the order of patients.

or LLS transplantation which resulted in right diaphragm being unprotected and susceptible to overextension. Severe adhesion between diaphragm and diseased liver formed by previous Kasai operations or injury of bare area caused by dissection might have led to delayed necrosis and perforation.^[6,13] Similarly, DH occurred in some cases which were only performed with hepatectomy without LT.^[14,15] Furthermore, pediatric recipients were malnourished in general, mostly suffered with hyperbilirubinemia, and were more prone to be injured with delayed healing. It has been confirmed that immunosuppressants, such as steroid or macrolide immunosuppressants, could impair healing post-LT,^[16] and Rossetto et al^[17] had reported DH post-LT was related with mammalian target of rapamycin. To our experience, surgical trauma in hepatectomy, especially to the bare area, and malnutrition in perioperative period were the main causes of DH.

The most common complaints in DH of pediatric recipients post-LT were respiratory distress, as well as symptoms of gastrointestinal obstruction, including abdominal pain, nausea, and vomiting.^[2,4–11] However, DH was not found until respiratory distress or gastrointestinal obstruction. So it was speculated that the trauma of diaphragm happened more earlier than hernia itself in which the hernia hole was enough to afford

gastro-intestine through it. In our data, the diameter of hernia hole was 2 cm at least. Earl et al^[18] reported an incidence of small bowel obstruction of 3.2% after orthotopic LT in the pediatric population, with diaphragmatic hernias being responsible for nearly half of the cases and lymphoproliferative disease for the remainder. Besides patients' statements, diagnosis of DH is usually confirmed by chest x-ray or CT scan. CT scan can also accurately detect any major vasculature and adhesions in abdomen post-LT.^[9]

As to the therapy of DH, it has been agreed that once DH is identified, operation should be performed immediately. Delayed treatment could result in disorder of cardiac and pulmonary function, loss of bowel, and/or severe abdominal infection. Laparotomy was the routine therapy. In 2015, Lee et al and Yeung et al had reported 3 cases of DH, and 1 case was performed by thoracoscopy.^[10,11] The courses of DH after surgical repairing were mostly uneventful without any surgical complications. Our experience showed that pediatric patients with DH should receive operation in time, even if the symptoms related to DH are mild. As to the approach of operative intervention, we suggest laparotomy to be the primary option, considering possible obstruction of digestive tract and likely adhesions of abdominal tissues post-LDLT.

Table 3
DH in pediatric recipients post-LT reported in literature.

Authors	Year	Patients (n)	Period between LT and DH	Previous surgery	Graft type	GRWR (%)	Chief complains	Period from DH to repair operation	DH location	Content in hernia	Follow-up (m)
Okajima et al ^[4]	2007	1	2 mo	No	LLS	1.35	Abdominal pain, vomiting, respiratory distress	Emergency (5 mo later)	Right postero-lateral	Convoluted ileum	15
Kazimi et al ^[5]	2010	2	3 mo, 14 mo	No	LLS, left lobe	0.94, 0.77	Abdominal pain, nausea, vomiting, respiratory distress, high fever	Emergency, –	Right-side	Small bowel	6, 4 y
Shigeta et al ^[6]	2012	3	42 d, 8 d, 3 mo	2 Kasai	LLS, reduced LLS	3.21, 2.39, 2.57	Respiratory distress, vomiting, bowel obstruction	Emergency, 99 d later	Right postero-lateral, right postero-medial	Small bowel, transverse colon	15, 1 yr, –
Moon et al ^[7]	2012	4	28 d, 7 mo, 46 d, 81 d	2 Kasai	LLS	1.62, 2.52, 1.55, 3.77	Abdominal pain, vomiting, respiratory distress, headache, dizziness, anorexia	1 d, –, 14 d, emergency	Right postero-medial	Colon, part of the small bowel and part of ileum	1 y, 3, 1, –
Lam et al ^[8]	2013	1	3 m	No	Left lobe	–	Abdominal pain, anorexia, respiratory distress	–	Right postero-lateral	Small bowel, a portion of the roux limb	2 y
Cortes et al ^[2]	2014	10	3.864 y (57–5501 d)	–	LLS	3.0±1.22 (1.7–5.0)	Small bowel obstruction	Emergency	Right postero-lateral, with 1 also having a left DH	Small bowel	3.5 y
Dökümcü et al ^[9]	2015	1	10 mo	Laparoscopic cholangiography	LLS	2.1	Tachypnea, respiratory distress	Emergency	Right postero-lateral	Ileal segments, ascending colon	2 y
Yeung et al ^[10]	2015	3	15 mo, 9 mo, 15 mo	1 Kasai	Reduced LLS, LLS	4.4, 2.4, 2.5	Incidental, repeated vomiting, respiratory distress	10 mo later, emergency, –	Right cardiophrenic region, right postero-medial	Large bowel, mesenteric fat, terminal ileum	–
Lee et al ^[11]	2015	3	5 mo, 2 mo, 28 mo	–	LLS	4.6, 4.8, 3.26	Vomiting, decreased activity, high fever, respiratory distress	Emergency	Left medial, right side	Stomach, small bowel	42, 5, 8

DH=diaphragmatic hernia, GRWR=graft weight/recipient body weight ratio, LLS=left lateral segment, LT=liver transplantation.

4. Conclusions

DH post-LDLT is unusual, however, should be recognized as a possible complication when a left lateral segment graft is used. In some cases, DH is found acutely and can even be life-threatening. Diagnosis can easily be made with chest x-ray or CT scan. A high index of suspicion and prompt surgery could minimize complications. When unexplained respiratory or gastrointestinal symptoms after LDLT occurred in pediatric patients, DH should be highlighted in differential diagnosis.

Acknowledgments

The authors thank Dr Haohao Li for providing photographs of repairing operations of DH.

Author contributions

Wei Gao proposed the study. Kai Wang performed research, analyzed the data, and wrote the first draft. Nan Ma, Xing-Chu Meng, Wei Zhang, Chao Sun, Chong Dong, Bin Wu helped to collect the data. All authors contributed to the performance of LDLT, the repairing operations of DH, the design and interpretation of the study and to further drafts. Wei Gao is the guarantor.

Investigation: B. Wu, C. Sun, C. Dong, W. Zhang, X-C. Meng.

Methodology: B. Wu, C. Sun, C. Dong, N. Ma, W. Zhang, X-C. Meng.

Project administration: B. Wu, C. Sun, C. Dong, K. Wang, N. Ma, W. Zhang, X-C. Meng.

Supervision: W. Gao.

Writing - original draft: K. Wang.

References

- [1] Lauterio A, Di Sandro S, Concone G, et al. Current status and perspectives in split liver transplantation. *World J Gastroenterol* 2015;21:11003–15.
- [2] Cortes M, Tapuria N, Khorsandi SE, et al. Diaphragmatic hernia after liver transplantation in children: case series and review of the literature. *Liver Transpl* 2014;20:1429–35.
- [3] Neto JS, Pugliese R, Fonseca EA, et al. Four hundred thirty consecutive pediatric living donor liver transplants: variables associated with posttransplant patient and graft survival. *Liver Transpl* 2012;18:577–84.
- [4] Okajima H, Hayashida S, Iwasaki H, et al. Bowel obstruction due to diaphragmatic hernia in an elder child after pediatric liver transplantation. *Pediatr Transplant* 2007;11:324–6.
- [5] Kazimi M, Ibis C, Alper I, et al. Right-sided diaphragmatic hernia after orthotopic liver transplantation: report of two cases. *Pediatr Transplant* 2010;14:e62–4.
- [6] Shigeta T, Sakamoto S, Kanazawa H, et al. Diaphragmatic hernia in infants following living donor liver transplantation: report of three cases and a review of the literature. *Pediatr Transplant* 2012;16:496–500.
- [7] Moon SB, Jung SM, Kwon CH, et al. Posteromedial diaphragmatic hernia following pediatric liver transplantation. *Pediatr Transplant* 2012;16:E106–9.
- [8] Lam HD, Mejia J, Soltys KA, et al. Right diaphragmatic hernia after liver transplant in pediatrics: a case report and review of the literature. *Pediatr Transplant* 2013;17:E77–80.
- [9] Dökümcü Z, Divarçı E, Erdener A, et al. Acquired right diaphragmatic hernia following pediatric living donor orthotopic liver transplantation. *Pediatr Transplant* 2015;19:E149–51.
- [10] Yeung F, Chung PH, Wong KK, et al. Iatrogenic diaphragmatic hernia in paediatric patients. *Pediatr Surg Int* 2015;31:589–92.
- [11] Lee S, Seo JM, Younes AE, et al. Thoracoscopic approach for repair of diaphragmatic hernia occurring after pediatric liver transplant. *Medicine (Baltimore)* 2015;94:e1376.
- [12] McCabe AJ, Orr JD, Sharif K, et al. Rightsided diaphragmatic hernia in infants after liver transplantation. *J Pediatr Surg* 2005;40:1181–4.
- [13] Suh Y, Lee JH, Jeon H, et al. Late onset iatrogenic diaphragmatic hernia after laparoscopy-assisted total gastrectomy for gastric cancer. *J Gastric Cancer* 2012;12:49–52.
- [14] Vernadakis S, Paul A, Kykalos S, et al. Incarcerated diaphragmatic hernia after right hepatectomy for living donor liver transplantation: case report of an extremely rare late donor complication. *Transplant Proc* 2012;44:2770–2.
- [15] Soufi M, Meillat H, Le Treut YP. Right diaphragmatic iatrogenic hernia after laparoscopic fenestration of a liver cyst: report of a case and review of the literature. *World J Emerg Surg* 2013;8:2.
- [16] Kahn J, Muller H, Iberer F, et al. Incisional hernia following liver transplantation: incidence and predisposing factors. *Clin Transplant* 2007;21:423–6.
- [17] Rossetto A, Bacarani U, Adani GL, et al. Diaphragm rupture in a liver transplant patient under chronic immunosuppressive therapy with sirolimus: rare complication after liver transplantation. *Updates Surg* 2001;63:51–3.
- [18] Earl TM, Wellen JR, Anderson CD, et al. Small bowel obstruction after pediatric liver transplantation: the unusual is the usual. *J Am Coll Surg* 2011;212:62–7.