EJCRIM
European Journal
of Case Reports
in Internal Medicine

PYLORIC BOTULINUM TOXIN FOR DIABETIC GASTROPARESIS: A CASE OF SUSTAINED GLYCAEMIC IMPROVEMENT

Luke Bugeja[1] Lianne Camilleri[2], John Schembri[1]

[1] Department of Gastroenterology and General Medicine, Mater Dei Hospital Msida, Msida, Malta
[2] Diabetes and Endocrinology Division, Department of General Medicine, Mater Dei Hospital Msida, Msida, Malta

Corresponding author's e-mail: luke.a.bugeja@gov.mt

Received: 31/05/2025
Accepted: 09/06/2025
Published: 08/07/2025

Conflicts of Interests: The Authors declare that there are no competing interests.
Patient Consent: Written informed consent was obtained from the patient for the publication of this case report and any accompanying images.
This article is licensed under a Commons Attribution Non-Commercial 4.0 License

How to cite this article: Bugeja L, Camilleri L, Schembri J. Pyloric botulinum toxin for diabetic gastroparesis: a case of sustained glycaemic improvement. *EJCRIM* 2025;**12**:doi:10.12890/2025_005495

ABSTRACT

Introduction: Diabetic gastroparesis is a gastrointestinal motility disorder defined as a delay in gastric emptying time without any mechanical obstruction. This affects about 40% of patients with type 1 diabetes and up to 30% of patients with type 2 diabetes, especially those with long-standing disease, and arises from dysfunction of the autonomic and enteric nervous systems. Unfortunately, it can cause great difficulty in controlling post-meal glucose excursions because food absorption can become unpredictable in this group of patients. Gastroparesis is therefore linked with fluctuations in glycaemic control due to variable nutrient absorption. This may worsen the extent of gastroparesis, making glucose control even more difficult. Treatment with botulinum toxin injections has been described in clinical trials with doubtful efficacy to abating symptoms associated with gastroparesis.

Case presentation: We report a case of how pyloric botulinum toxin injections significantly improved a patient's type 1 diabetic control and gastrointestinal symptoms associated with gastroparesis and is still maintaining improved glucose levels six months after her procedure. Although current data and case studies highlight a potential role for pyloric botulinum toxin injections, no association was found between pyloric botulinum toxin injections and blood glucose control in type 1 diabetics.

Conclusion: This article examines a potential promising association between botulinum toxin injection in the pylorus and enhanced diabetic control in type 1 diabetics.

KEYWORDS

Gastroparesis, type 1 diabetes mellitus, gastric motility disorders

LEARNING POINTS

- *Long-lasting effect:* Despite being a temporary intervention, pyloric botulinum toxin injection provided sustained clinical benefit in this case.
- *Glycaemic impact:* The treatment significantly improved glucose control and symptoms of autonomic neuropathy in a type 1 diabetic patient.
- *Future potential:* Current data lack evidence for glycaemic benefit in type 1 diabetics, highlighting the need for targeted clinical trials.

EFIM
European Federation of Internal Medicine

Publisher
smc
media srl

INTRODUCTION/BACKGROUND

Gastric emptying relies on the well-coordinated smooth muscle contractility of stomach and duodenum. Smooth muscle, extrinsic and intrinsic neurons, glial cells, hormonal elements and the interstitial cells of Cajal play a vital role in this process. Anatomically, the gastric corpus serves as a reservoir, whereas the antrum produces phasic peristaltic waves responsible for gastric emptying.

Diabetic gastroparesis (DGP) is a gastrointestinal motility disorder defined as a delay in gastric emptying time without any mechanical obstruction and affects about 40% of patients with type 1 diabetes and up to 30% of patients with type 2 diabetes, especially those with long-standing disease. DGP may be completely asymptomatic but classically presents with an array of symptoms that may lead to dehydration, and nutritional and dysglycaemic complications if left untreated. Early identification, appropriate blood glucose control and reduction of glucose variability can limit the consequences of this condition. DGP can cause great difficulty in controlling post-meal glucose excursions because of the unpredictability of food absorption. These fluctuations in glucose levels may in turn worsen the extent of gastroparesis.

CASE DESCRIPTION

A 39-year-old female, diagnosed with type 1 diabetes mellitus at 10 years of age, had persistent poor glucose control despite recurrent adjustments in insulin dosage and strict adherence to her dietary plan. Strict monitoring of her glucose levels was carried out using a continuous glucose monitoring (CGM) system which showed consistently erratic blood glucose monitoring values. The reports included were generated by the patient herself, using the Dexcom Clarity device (Dexcom, Inc) *(Fig. 1 and 2)*. Her HBa1c was 8.1% (65 mmol/mol) with a random average serum glucose of 10.30 mmol/l. Along the years, she complained of nausea but denied any bouts of vomiting or early satiety.

A gastric emptying scan was performed with ingestion of a 0.5 to 1.0 mCi of 99mTc-sulfur colloid meal and showed a prolonged lag phase followed by significantly delayed gastric emptying with linear fit estimates T1/2 of 699 minutes (normal 62±11 minutes). Her gastroparesis led to unpredictable responses to mealtime rapid-acting insulin, often presenting with severe hypoglycaemia soon after meals brought about by the mismatch between delayed food absorption and instant insulin action. Various lifestyle, dietary and treatment modifications were attempted, including delaying rapid-acting insulin administration, splitting the doses to provide a staggered effect and changing from rapid-acting insulin to a short-acting insulin to vary the onset, peak effect and duration of insulin.

Despite these modifications, glucose control remained erratic with significant fluctuations in blood glucose monitoring readings with an inability to reach glycaemic targets, aiming for a time in range of 70% from 14 days and accompanied by high A1C measurements and high glucose management indicators. Pharmacological therapies with 5-HT4 receptor activator and dopamine receptor antagonists (metoclopramide), serotonin (5-HT3) receptor antagonists (ondansetron) and D2 agonists (domperidone) also proved ineffective. As a last resort the patient was offered pyloric botulinum toxin (BTX) injection, whereby 100U of BTX was injected into the pylorus in a quadrantic fashion after ruling out gastric pathology with a diagnostic

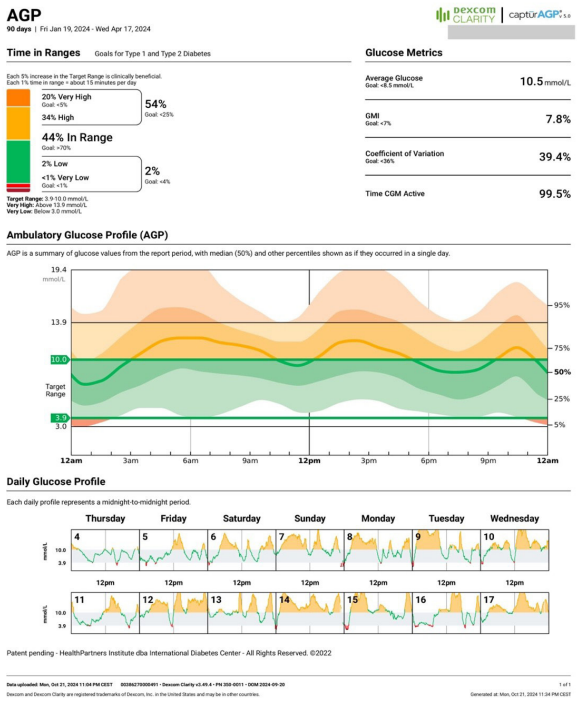

Figure 1. Pre-botulinum toxin injection ambulatory glucose profile.

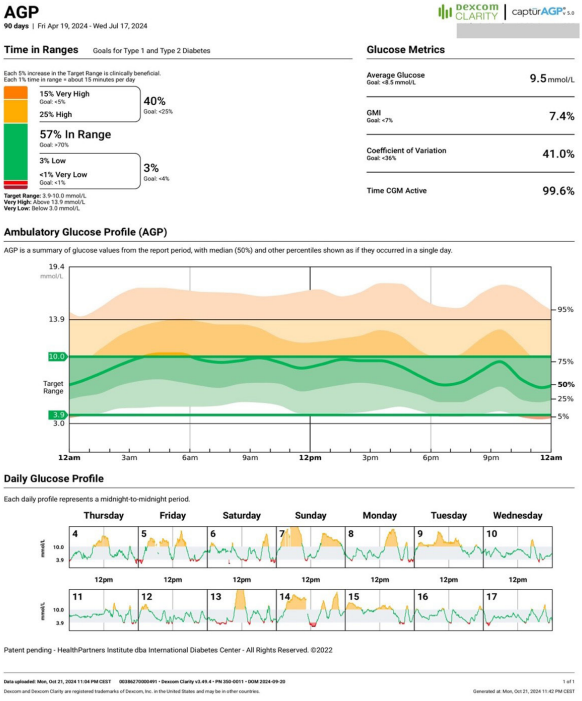

Figure 2. Post-botulinum toxin injection ambulatory glucose profile.

esophagogastric duodenoscopy. The procedure was carried out with no immediate complications.

Within a few weeks of the procedure there was an improvement in both glucose control and symptomatology. Gastric emptying studies carried out four months after the procedure showed only a slight delay in the lag phase followed by a mild delay in gastric emptying with linear fit estimates T1/2 of 100 minutes.

Pre-procedure, her A1C was 7.8% and it went down to 7.4% post-BTX (target of <7% with no hypoglycaemia). However, in recent years CGM has become the standard method for glucose monitoring in patients with type 1 DM as it helps to provide detailed metrics compared to A1C. Examples are glycaemic variability (an indicator of hyper- and hypoglycaemia), time in range, time above and below range as well as the amplitude and the time spent in the excursion apart from mean glucose[1,2].

Comparing these parameters in our patient before and one year after the BTX injection, shows similar CGM (99.5 and 99.6%), co-efficient of variation (39.4 and 41%) and time below range (2 and 3%) with a significant increase in time in range from 44 to 57%, and a reduction in time above range from 54 to 40% *(Fig. 1 and 2)*.

When measuring success in terms of patient outcomes other factors need to be taken into consideration, including adequacy of carbohydrate counting, adherence to insulin and adequacy of administration techniques, possible sites of lipohypertrophy and physical activity[3]. A combination of such factors could explain the suboptimal improvement in A1C of our patient. However, CGM metrics confirmed a significant and sustained improvement in glycaemic control throughout the day.

A measurable outcome with regards to determining the efficacy of the BTX injection was the improvement in gastric emptying scan times with linear fit estimates T1/2 of 699 minutes before to 100 minutes after intervention.

DISCUSSION

DGP is a disorder which may present with classic symptoms including nausea, vomiting, anorexia, weight loss and abdominal discomfort, but may also present with an unpredictable response to mealtime insulin. These responses result from a mismatch between food absorption, which is slowed down in gastroparesis, and insulin absorption, which is unaffected. This phenomenon may present as severe hypoglycaemia soon after meals, leaving patients questioning their unpredictable postprandial glycaemic control. Patients with DGP cannot be treated with glucagon-like peptide 1 (GLP-1) receptor agonists as these drugs will further reduce gastric emptying.

While optimisation of glucose control is crucial in managing DGP this can be a substantial challenge, because food absorption is unreliable and may not match endogenous insulin secretion or exogenous insulin administration. For patients who take mealtime rapid- or short-acting insulin, dosing after meals rather than before meals may be necessary. Because patients with DGP have a slower post-meal rise in blood glucose levels resulting from delayed gastric emptying, administering prandial insulin after meals instead of before can better match the timing of the postprandial glucose excursion. The gold standard investigation for gastroparesis is a four-hour scintigraphy gastric emptying scan with a meal containing radiolabelled solid meal.

Metoclopramide is the only FDA-approved treatment for DGP, but it carries a black box warning due to the risk of tardive dyskinesia, which is a potentially irreversible involuntary movement disorder that can persist even after stopping the drug[4]. Domperidone has similar prokinetic effects with a safer side effect profile since it does not cross the blood–brain barrier, though its benefits often wane after six weeks[5-7].

Studies identified periods of unusually prolonged and intense tonic pyloric contractions, or pylorospasms, via endoscopic manometry in patients with gastroparesis, forming the basis of an emerging hypothesis that the pylorus is a potential therapeutic target in gastroparesis.

Substantial data supporting the use of endoscopic pyloric BTX is lacking and often conflicting. BTX has been explored as a treatment for refractory diabetic gastroparesis, particularly in patients with evidence of pylorospasm. Administered via endoscopic injection into the pyloric sphincter, BTX temporarily relaxes smooth muscle by inhibiting acetylcholine release, potentially improving gastric emptying. While early studies suggested benefits, randomised trials have shown mixed results. Adverse effects are generally mild and transient, but can include abdominal pain, bloating and rare systemic effects such as generalised weakness. However, BTX should generally be avoided in those with neuromuscular disorders, infection or non-pyloric dysfunction.

Our patient did not experience the typical symptoms usually encountered in DGP; however, a gastric emptying scan was performed in view of erratic glucose control and this confirmed poor gastric emptying. A BTX injection was attempted as a last resort after failure of dietary and pharmacological intervention. A repeat gastric emptying scan confirmed a considerable improvement, and our patient remained well, with improvements in her blood glucose measurements up to one year from the procedure. Although a BTX injection is regarded as a temporary solution and usually requires repeat injections for sustained effect, our case demonstrates that a single injection can provide long-lasting effects. One possible explanation is that while its effect is short lasting, the improvement in glycaemic control experienced after the procedure will have a longer lasting effect in a subset of patients with an improvement in their delayed gastric emptying.

Although early open-label studies suggested potential benefit, randomised controlled trials have not demonstrated a significant clinical advantage of BTX over placebo in gastroparesis, and no causal link between pyloric dysfunction and symptoms has been established[8].

CONCLUSION

This case strengthens the claim that a subgroup of gastroparesis patients may be successfully treated with endoscopic pyloric BTX injection, providing evidence that BTX injection can provide substantial and sustained improvement in blood glucose measurements in type 1 diabetes mellitus.

Although endoscopic BTX injection is considered a temporary measure, requiring a repeat dose every six to twelve months, this case shows that BTX injection can have long-lasting benefits. We postulate that the procedure carried out improved the patient's glucose measurements enough to allow her autonomic neuropathy to improve. Although current data and case studies highlight a potential role for pyloric BTX injections, no association was found between pyloric BTX injections and blood glucose control in type 1 diabetics. The discovery of a potential link between pyloric BTX injections and improved control of a subset of type 1 diabetics is an exciting development, which warrants further investigation to determine whether this intervention could offer a new avenue to improve diabetes care.

REFERENCES

1. Wright EE Jr, Morgan K, Fu DK, Wilkins N, Guffey WJ. Time in range: how to measure it, how to report it, and its practical application in clinical decision-making. *J Diabetes Sci Technol* 2021;**15**:120–129. doi: 10.2337/cd20-0042
2. Gupta S, Jain U, Chauhan N. Laboratory diagnosis of HbA1c: a review. *J Nanomed Res* 2017;**5**:00120. doi: 10.15406/jnmr.2017.05.00120
3. Huo L, Deng W, Shaw JE, Magliano DJ, Zhang P, McGuire HC, et al. Factors associated with glycemic control in type 1 diabetes patients in China: a cross-sectional study. *J Diabetes Investig* 2020;**11**:392–401. doi: 10.1111/jdi.13282
4. Kalra S, Sharma A, Priya G. Diabetic gastroparesis. *Diabetes Ther* 2018;**9**:1723–1728. doi: 10.1007/s13300-018-0475-4
5. Davis RH, Clench MH, Mathias JR. Effects of domperidone in patients with chronic unexplained upper gastrointestinal symptoms: a double-blind, placebo-controlled study. *Dig Dis Sci* 1988;**33**:1505–1511. doi: 10.1007/BF01535938
6. Horowitz M, Harding PE, Chatterton BE, Collins PJ, Shearman DJ. Acute and chronic effects of domperidone on gastric emptying in diabetic autonomic neuropathy. *Dig Dis Sci* 1985;**30**:1–9. doi: 10.1007/BF01318363
7. Jones MP, Maganti K. A systematic review of surgical therapy for gastroparesis. *Am J Gastroenterol* 2003;**98**:2122–2129. doi: 10.1111/j.1572-0241.2003.07721.x
8. Pasricha TS, Pasricha PJ. Botulinum toxin injection for treatment of gastroparesis. *Gastrointest Endosc Clin N Am* 2019;**29**:97–106. doi: 10.1016/j.giec.2018.08.007