

Access this article online

Quick Response Code:



Website:
www.e-tjo.org

DOI:
10.4103/tjo.tjo_83_20

Binasal visual field defects caused by temporal posterior subcapsular cataracts

Kelsey Moody Mileski^{1*}, Valerie Biousse^{1,2}, Nancy J. Newman^{1,2,3}

Abstract:

A 55-year-old female presented with binasal visual field defects and normal neuro-ophthalmic examination. Slit-lamp examination demonstrated posterior subcapsular cataracts that were located temporally in the visual axis. Due to the location of the nodal point in the eye, her visual field defect was contralateral to the opacity. Her visual field defects resolved after cataract surgery.

Keywords:

Cataract, ophthalmology, visual field defects

Introduction

The first structures of the eye that light passes through are the refracting components: the cornea and lens. Therefore, it is possible, although not common, to have a visual field defect secondary to a corneal or lens opacity.^[1-4] The presence of a visual field defect requires investigation into the etiology. Understanding where visual information reverses is crucial to attributing the defect to an anterior structure in the eye. Since the nodal point of the eye is at the posterior lens/anterior vitreous, an opacity anterior to this will cause an ipsilateral defect whereas it will be reversed at the nodal point.^[5,6] Although cataracts do not typically cause a visual field defect, there have been several case reports of visual field defects secondary to posterior subcapsular cataracts that resolve after surgery.^[1-3] We report a case supporting this finding.

Case Report

A 55-year-old female was referred to the neuro-ophthalmology unit for visual

field defects. Her past medical and ocular history was unremarkable. She was not on any medications. She was symptomatic for blurry vision in both eyes but denied any other ophthalmic or neurologic symptoms. Physical examination was remarkable for reduced best-corrected visual acuity to 20/30 in the right eye (OD) and 20/40 in the left eye (OS) with normal color vision and pupillary examination. Slit-lamp examination demonstrated temporal posterior subcapsular cataracts in both eyes (OU) [Figure 1]. Her optic disc was normal without evidence of cupping or neuroretinal rim pallor. Her retinal appearance was also normal. Dilated 24-2 Humphrey visual field testing demonstrated nasal depressed points OD and OS [Figure 2]. Due to her normal neuro-ophthalmic examination, it was felt that her cataracts were causing her visual field defects. She was referred for cataract surgery and the visual field defects and symptoms resolved.

Discussion

After light passes into the eye, visual information travels from the retina to the optic nerve. Nasal retinal fibers cross at the

Departments of
¹Ophthalmology,
²Neurology and
³Neurological Surgery,
Emory University School
of Medicine, Atlanta,
GA, USA

*Address for correspondence:

Dr. Kelsey Moody Mileski,
Emory Eye Center, 1365B
Clifton Road, Atlanta, GA
30322, USA.
E-mail: kelsey.leigh.m@
gmail.com

Submission: 30-08-2020
Accepted: 24-11-2020
Published: 28-01-2021

This is an open access journal, and articles are distributed under the terms of the Creative Commons Attribution-NonCommercial-ShareAlike 4.0 License, which allows others to remix, tweak, and build upon the work non-commercially, as long as appropriate credit is given and the new creations are licensed under the identical terms.

For reprints contact: WKHLRPMedknow_reprints@wolterskluwer.com

How to cite this article: Mileski KM, Biousse V, Newman NJ. Binasal visual field defects caused by temporal posterior subcapsular cataracts. Taiwan J Ophthalmol 2021;11:101-3.

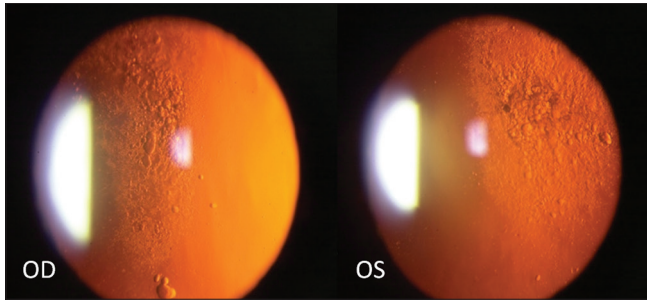


Figure 1: Slit-lamp photograph of posterior subcapsular cataracts in temporal visual axis

optic chiasm, and visual information is now divided into the right and left sides, respectively, until it reaches the occipital lobe where visual information is organized further.^[7] Visual field defects that respect the vertical meridian are often associated with neuro-ophthalmic conditions. However, these defects are classically bitemporal or homonymous, while nasal defects are associated with optic neuropathies, most commonly glaucoma.^[8]

Opacities in the optical media are easily visualized on an ophthalmic examination, however, they are not usually implicated in affecting the visual field. Multiple studies have been performed investigating how lens opacities may impact the visual field with variable results. It is generally agreed upon that a cataract may affect the total mean deviation, but rarely can it cause a change in the pattern standard deviation or visual field index.^[9-11]

Despite this, there have been several case reports that demonstrate cataracts causing visual field defects. Lyne and Phillips^[2] reported two patients with lens opacities that caused nasal field defects. In addition, Rahman *et al.*^[3] reported a 51-year-old patient with a unilateral nasal hemianopic defect secondary to posterior subcapsular cataract. Karp and Fazio^[1] also reported a 56-year old patient with a unilateral nasal hemianopic defect secondary to traumatic posterior subcapsular cataract. In both of these cases, the visual field defect improved after cataract surgery.^[1,3] Lyne and Phillips^[2] also noted that changing the pupil diameter significantly impacted the visual field result, with smaller pupils causing a larger field defect. Pupillary dilation, on the other hand, allowed more light rays to enter around the opacity, improving the defect. With this in mind, if there is a high suspicion for a posterior subcapsular cataract causing a visual field defect, dilating the pupils, and repeating the visual field could be a helpful tool to differentiate posterior subcapsular cataract-derived visual field defects (which should improve or clear with dilation) versus neurogenic visual field defects (which should not be affected by pupillary dilation).

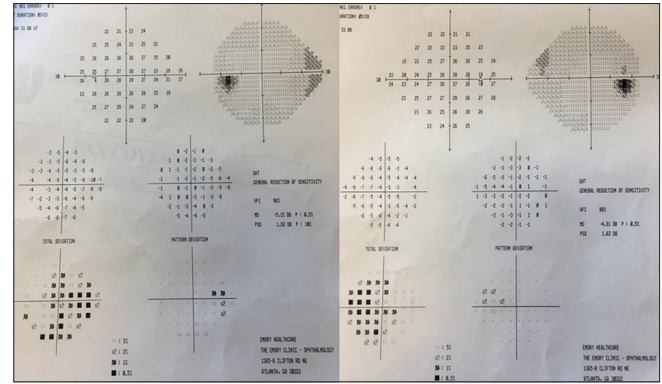


Figure 2: 24-2 Humphrey visual field of binasal visual field defect

Similar to the lens, a corneal opacity can also cause a visual field defect, however, the defect is ipsilateral to the opacity.^[2,4] This is often seen in pterygium, corneal scarring, or occasionally even severe dry eye syndrome. Potentially, a scleral contact lens can be placed on the eye to vault the corneal defect and create a new ocular surface, which may improve the visual field defect. The difference in visual field defect location between the cornea and the lens is due to the location of the nodal point of the eye. There are many mathematical models of the eye, however, the reduced schematic eye is used most often. In this simplified model, the nodal points of the cornea and lens are so close together that they can be combined to a single point approximately 17 mm in front of the retina, approximately at the posterior lens^[6] [Figure 3]. It is at this location where visual information is inverted to the contralateral side.

To the author's knowledge, our case is unique in that it is the only published case of posterior subcapsular cataracts causing bilateral nasal visual field defects. Of note, our patient was dilated prior to her visual field being performed, so it is possible that her visual field defect was denser, which is why she was so symptomatic. Our patient was not worked up for a neuro-ophthalmic etiology prior to her cataract surgery, as her visual field defect was binasal and the rest of her neuro-ophthalmic examination was unremarkable. However, if the visual field defect was temporal, neuro-imaging should be pursued to rule out a chiasmal process.

In conclusion, although cataracts do not typically cause visual field defects, media opacities should be considered when a visual field defect is present. Such visual field defects from posterior subcapsular cataracts are classically opposite to the lesion location, similar to what we see in the optic nerve and retina. This is explained by optics and the anatomical location of the nodal point in the eye.

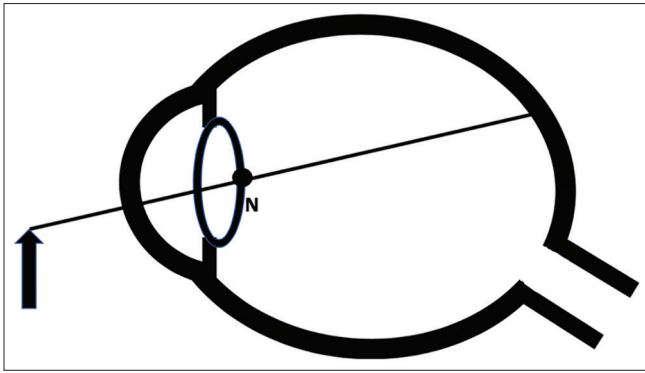


Figure 3: Illustration of the approximate location of the nodal point of the eye at the posterior lens

Declaration of patient consent

The authors certify that they have obtained all appropriate patient consent forms. In the form the patient has given her consent for her de-identified images and other clinical information to be used for teaching and research purposes. The patient understands that her name and initials will not be published and due efforts will be made to conceal the identity, but anonymity cannot be guaranteed.

Financial support and sponsorship

V.B. and N.J.N. are supported in part by NIH/NEI core grant P30-EY06360 (Department of Ophthalmology, Emory University School of Medicine) and by NIH/NINDS (RO1NSO89694).

Conflicts of interest

The authors declare that there are no conflicts of interests of this paper.

References

1. Karp CL, Fazio JR. Traumatic cataract presenting with unilateral nasal hemianopsia. *J Cataract Refract Surg* 1999;25:1302-3.
2. Lyne AJ, Phillips CI. Visual field defects due to opacities in the optical media. *Brit J. Ophthal* 1969;53:119-22.
3. Rahman I, Nambiar A, Spencer AF. Unilateral nasal hemianopsia secondary to posterior sub capsular cataract. *Br J Ophthalmol* 2003;87:1045-6.
4. Phu J, Khuu SK, Yapp M, Assaad N, Hennessy MP, Kalloniatis M, *et al*. The value of visual field testing in the era of advanced imaging: Clinical and psychophysical perspectives. *Clin Exp Optom* 2017;100:313-32.
5. Harris WF. Nodes and nodal points and lines in eyes and other optical systems. *Ophthalmic Physiol Opt* 2010;30:24-42.
6. Gupta, PC, Irsch K, Jackson ML, Mauger TF, Strauss L, *et al*. Editors. 2019-2020 Basic and Clinical Science Course Clinical Optics. American Academy of Ophthalmology; 2019. p. 99-101, 164-8.
7. Rizzo JF. Embryology, anatomy, and physiology of the afferent visual pathway. In: Miller NR, Newman NJ, Bioussé V, Kerrison JB, editors. *Walsh and Hoyt's Clinical Neuro Ophthalmology*. 6th ed., Vol. 1. Baltimore: Lippincott Williams and Wilkins; 2005. p. 1-82.
8. Sadun AA, Agarwal MR. Topical diagnosis of acquired optic nerve disorders. In: Miller NR, Newman NJ, Bioussé V, Kerrison JB, editors. *Walsh and Hoyt's Clinical Neuro Ophthalmology*. 6th ed., Vol. 1. Baltimore: Lippincott Williams and Wilkins; 2005. p. 197-236.
9. Rao HL, Jonnadula GB, Addepalli UK, Senthil S, Garudadri CS. Effect of cataract extraction on visual field index in glaucoma. *J Glaucoma* 2013;22:164-8.
10. Lam BL, Alward WL, Kolder HE. Effect of cataract on automated perimetry. *Ophthalmology* 1991;98:1066-70.
11. Rockwood EJ, Spaeth GL, Piltz-Seymour JR, Berke SJ, Lichter PR, Musch DC, *et al*. The impact of cataract surgery on visual acuity, visual field and quality of life for patients in the CIGTS. *Invest Ophthalmol Vis Sci* 2002;43:289.