

# Randomized clinical trial of intraoperative parathyroid gland angiography with indocyanine green fluorescence predicting parathyroid function after thyroid surgery

J. Vidal Fortuny<sup>1</sup>, S. M. Sadowski<sup>1</sup>, V. Belfontali<sup>1</sup>, S. Guigard<sup>1</sup>, A. Poncet<sup>2</sup>, F. Ris<sup>3</sup> , W. Karenovics<sup>1</sup> and F. Triponez<sup>1</sup> 

<sup>1</sup>Department of Thoracic and Endocrine Surgery and Faculty of Medicine, <sup>2</sup>Department of Clinical Epidemiology, and <sup>3</sup>Department Visceral Surgery, University Hospitals of Geneva, Geneva, Switzerland

Correspondence to: Professor F. Triponez, Department of Thoracic and Endocrine Surgery, University Hospitals of Geneva, 1211 Geneva, Switzerland (e-mail: frederic.triponez@hcuge.ch)

**Background:** Hypoparathyroidism, the most common complication after thyroid surgery, leads to hypocalcaemia and significant medical problems. An RCT was undertaken to determine whether intraoperative parathyroid gland angiography with indocyanine green (ICG) could predict postoperative hypoparathyroidism, and obviate the need for systematic blood tests and oral calcium supplementation.

**Methods:** Between September 2014 and February 2016, patients who had at least one well perfused parathyroid gland on ICG angiography were randomized to receive standard follow-up (measurement of calcium and parathyroid hormone (PTH) on postoperative day (POD) 1 and systematic supplementation with calcium and vitamin D; control group) or no supplementation and no blood test on POD 1 (intervention group). In all patients, calcium and PTH levels were measured 10–15 days after thyroidectomy. The primary endpoint was hypocalcaemia on POD 10–15.

**Results:** A total of 196 patients underwent ICG angiography during thyroid surgery, of whom 146 had at least one well perfused parathyroid gland on ICG angiography and were randomized. None of these patients presented with hypoparathyroidism, including those who did not receive calcium supplementation. The intervention group was statistically non-inferior to the control group (exact 95 per cent c.i. of the difference in proportion of patients with hypocalcaemia –0.053 to 0.053;  $P = 0.012$ ). Eleven of the 50 excluded patients, in whom no well perfused parathyroid gland could be identified by angiography, presented with hypoparathyroidism on POD 1, and six on POD 10–15, which was significantly different from the findings in randomized patients ( $P = 0.007$ ).

**Conclusion:** ICG angiography reliably predicts the vascularization of the parathyroid glands and obviates the need for postoperative measurement of calcium and PTH, and supplementation with calcium in patients with at least one well perfused parathyroid gland. Registration number: NCT02249780 (<http://www.clinicaltrials.gov>).



Paper accepted 8 November 2017

Published online 6 February 2018 in Wiley Online Library ([www.bjs.co.uk](http://www.bjs.co.uk)). DOI: 10.1002/bjs.10783

## Introduction

Temporary hypoparathyroidism leading to hypocalcaemia is the most common complication after total thyroidectomy. Depending on the technical difficulty of the procedure and expertise of the surgeon, this is seen in up to 30 per cent of patients undergoing total thyroidectomy<sup>1,2</sup>. Permanent hypocalcaemia, defined as hypocalcaemia present for more than 6 months after thyroidectomy, is reported in 1–10 per cent of patients<sup>3,4</sup>. Minimizing hypoparathyroidism is important for

quality of life, as postoperative hypocalcaemia may result in prolonged admission to hospital and multiple clinic visits, neuromuscular symptoms, the need for lifelong calcium and vitamin D supplementation, and long-term complications<sup>5,6</sup>. Preservation of the parathyroid glands can be challenging, as normal postoperative parathyroid function is not guaranteed even when the parathyroid glands appear to be well preserved during surgery.

For more than a century, systematic postoperative measurement of calcium and/or parathyroid hormone (PTH)

levels, and/or systematic supplementation with calcium and vitamin D therapy have been common standard management after total thyroidectomy<sup>7–9</sup>. Although capsular dissection techniques and preservation of the surrounding vasculature are used to avoid inadvertent parathyroidectomy or disruption of the parathyroid vasculature<sup>10,11</sup>, reliable tools to both identify and assess parathyroid glands during surgery, and to predict whether a patient will develop hypoparathyroidism, are limited<sup>3,12,13</sup>.

Current methods are based on measurement of calcium<sup>14,15</sup> and PTH<sup>4,16–20</sup> levels at different time points, with early (a few minutes to 12 h after thyroid resection) PTH measurements reliably predicting the absence of hypoparathyroidism<sup>4,16,17</sup>. Other authors<sup>18,21,22</sup> have suggested using quick PTH measurements, which could also help the surgeon decide whether or not to autotransplant a parathyroid gland. In addition, viability scores, based on visual evaluation of the parathyroid glands, have been used to predict postoperative hypoparathyroidism<sup>23</sup>. The study by Ji and colleagues<sup>23</sup>, however, also clearly demonstrated that visual scores are not reliable because, of 111 patients with a global score indicating that at least one parathyroid gland was classified visually as normal, 12 (10.8 per cent) had hypoparathyroidism on postoperative day (POD) 1.

Recently, near-infrared fluorescence imaging has renewed interest in intraoperative parathyroid imaging. Initially used in the detection of macular degeneration<sup>24</sup>, the technique of angiography using indocyanine green (ICG) has also been used to determine the extent of oncological resection<sup>25</sup>, to study hepatic function<sup>26</sup> and to evaluate blood flow in intestinal anastomoses<sup>27</sup>.

Vidal Fortuny and colleagues<sup>28,29</sup> previously reported an initial experience of using ICG to evaluate intraoperative perfusion of parathyroid glands in predicting parathyroid function after thyroidectomy and subtotal parathyroidectomy. These studies demonstrated that having one well perfused parathyroid gland/parathyroid gland remnant was sufficient to avoid hypoparathyroidism. Another study<sup>30</sup> reported similar findings in 23 patients undergoing thyroidectomy. The aim of the present RCT was to determine whether systematic measurement of calcium and PTH, and systematic supplementation of calcium and vitamin D therapy can be omitted in patients with at least one well perfused parathyroid gland identified by ICG angiography after thyroidectomy.

## Methods

The study enrolled patients from September 2014 until February 2016, and was approved by the Ethics Review Board of the University Hospitals of Geneva (HUG

08-2014). The trial was registered at ClinicalTrials.gov (NCT02249780). Written informed consent was obtained from all study participants.

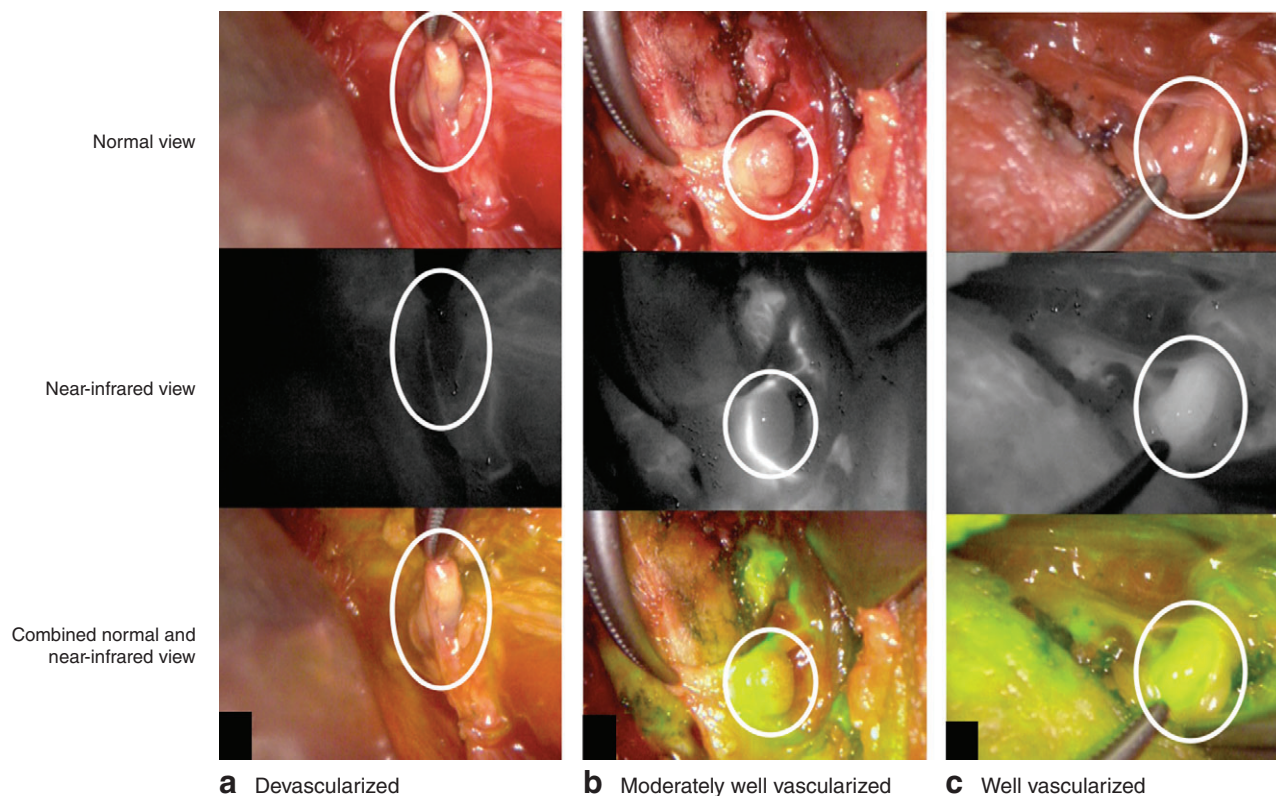
Thyroid surgery was performed by three experienced surgeons, using a standard protocol. The recurrent laryngeal nerve was identified during the procedure using neural monitoring (NIM 3.0®; Medtronic, Dublin, Ireland). No systematic search for parathyroid glands during total thyroidectomy was done and the dissection was performed close to the thyroid gland. Once the thyroid specimen had been removed, it was actively searched for parathyroid glands, which were then prepared for reimplantation if needed. The number of parathyroid glands identified in each patient was recorded.

After the thyroid gland had been removed, intraoperative angiography was performed on the identified parathyroid glands using a near-infrared camera (Pinpoint®; Novadaq, Toronto, Ontario, Canada). ICG (2.5 mg/ml) was prepared as described previously and injected intravenously<sup>29,31</sup>. Repeated doses were allowed until a maximum toxic dose of 5 mg/kg was reached. Approximately 1–2 min later, images were acquired by the near-infrared system and recorded. Each identified parathyroid gland was classified according to the degree of ICG fluorescence: ICG score 0, a black parathyroid gland after the injection of ICG, indicating a non-vascularized gland; ICG score 1, a grey or heterogeneous parathyroid gland, suggesting that the gland is partially vascularized; or ICG score 2, a white parathyroid gland, indicating that the gland is well vascularized (Fig. 1)<sup>29,31</sup>. If there was discordance between surgeons in evaluating ICG fluorescence, the lowest value was taken into account.

Patients with at least one well perfused parathyroid gland (ICG score 2) were considered eligible for randomization. Study inclusion criteria were: adult patients undergoing total thyroidectomy or completion thyroidectomy with an ICG score of 2 in at least one identified parathyroid gland, and a signed informed consent. Exclusion criteria were: concurrent parathyroid disease or combined surgery (thyroidectomy and parathyroidectomy); ICG score below 2 for all identified parathyroid glands; postoperative bleeding requiring reintervention; lack of informed consent; and altered mental status. Randomization was performed by the surgical team after ICG angiography at the end of the surgical procedure, by opening a sealed envelope.

## Follow-up

Patients in the control group had standard follow-up consisting of measurement of calcium and PTH levels on POD 1 and POD 10–15, and systematic oral supplementation with 1 g calcium and 800 units 25-hydroxyvitamin D



**Fig. 1** Representative images of **a** devascularized (indocyanine green (ICG) score 0), **b** moderately well vascularized (ICG score 1) and **c** well vascularized (ICG score 2) parathyroid gland assessed using ICG angiography (*Video S1*, supporting information). Circles indicate the parathyroid gland

twice daily until the first follow-up appointment (POD 10–15). Patients in the intervention group had postoperative clinical follow-up comprising assessment for symptoms of hypocalcaemia, but no blood tests to determine calcium or PTH levels on POD 1, and no oral calcium and vitamin D supplementation. Calcium and PTH levels were measured on POD 10–15 to confirm that levels were normal.

When symptoms of hypocalcaemia developed during the hospital stay, calcium and PTH levels were measured, and supplementation was started (or increased in the control group) until symptoms resolved, without waiting for the results. At discharge, patients were taught to look for hypocalcaemia-related symptoms and advised to contact the surgical team if symptoms occurred.

### Laboratory measurements

The Central Clinical Laboratory of the University Hospitals of Geneva performed all blood analyses. Calcium levels were adjusted according to serum albumin ( $\text{calcium}_{\text{corrected}} = \frac{40 - \text{albumin (g/l)}}{200} + \text{calcium}_{\text{measured}}$ ). The normal range at the authors' institution was 1.1–6.8 pmol/l

**Table 1** Number of parathyroid glands evaluated in each patient

No. of glands evaluated	Control group (n = 73)	Intervention group (n = 73)	Excluded group* (n = 50)	Total (n = 196)
1	13	8	14	35 (17.9)
2	21	24	19	64 (32.7)
3	19	25	8	52 (26.5)
4	20	16	9	45 (23.0)

Values in parentheses are percentages. \*Patients were excluded from the study before randomization if indocyanine green (ICG) angiography showed none of the parathyroid glands to have an ICG score of 2.

for PTH and 2.20–2.52 mmol/l for calcium. Hypocalcaemia was defined by a corrected calcium level of less than 2.00 mmol/l and hypoparathyroidism by a PTH level lower than 1.1 pmol/l.

### Statistical analysis

Because the study aimed to provide proof of concept, a large non-inferiority margin of 7 per cent was adopted, in order to show the safety of stopping blood tests and

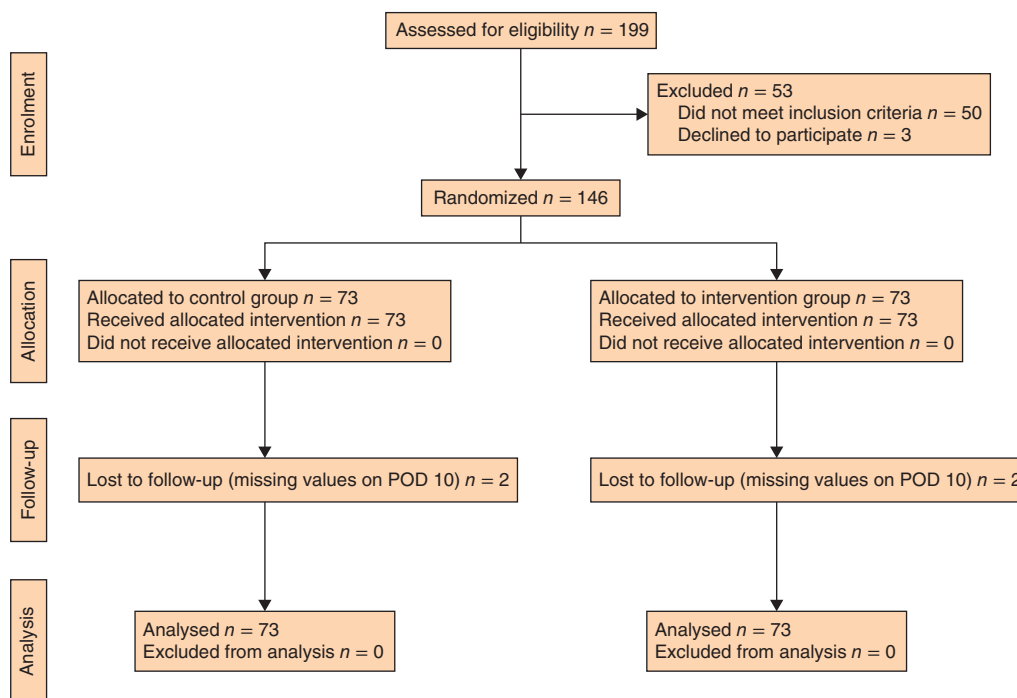


Fig. 2 CONSORT diagram showing randomization and allocation of the study cohort. POD, postoperative day

Table 2 Demographic and clinical characteristics

	Control group (n = 73)	Intervention group (n = 73)	Excluded group† (n = 50)
Age (years)*	50.9(15.4)	53.9(15.9)	50.6(12.1)
Sex ratio (M : F)	11 : 62	11 : 62	17 : 33
ASA score*	1.91(0.43)	1.95(0.45)	1.90(0.46)
Indication for surgery			
Multinodular goitre	41 (56)	33 (45)	30 (60)
Thyroid cancer	17 (23)	30 (41)	15 (30)
Graves' disease	15 (21)	10 (14)	5 (10)
Extent of surgery			
Completion thyroidectomy	5 (7)	11 (15)	5 (10)
Total thyroidectomy	59 (81)	45 (62)	37 (74)
Total thyroidectomy + central neck dissection	6 (8)	15 (21)	2 (4)
Total thyroidectomy + central + lateral neck dissection	3 (4)	2 (3)	6 (12)
Duration of hospital stay (days)*	1.53(1.15)	1.48(0.98)	1.38(0.69)

Values in parentheses are percentages unless indicated otherwise; \*values are mean(s.d.). †Patients were excluded from the study before randomization if indocyanine green (ICG) angiography showed none of the parathyroid glands to have an ICG score of 2.

calcium supplementation without hypocalcaemic episodes. Using exact methods and assuming an expected proportion of failure of 1.5 per cent in both groups, 69 patients per group were needed to obtain a power of at least 80 per cent (calculation performed in StatXact-4 (Cytel, Cambridge, Massachusetts, USA) using a 1-sided test with a type I error risk ( $\alpha$ ) of 0.025).

All results were recorded in a secure database to which only the principal investigator had access; recorded images were stocked for analysis. Continuous data are presented as mean(s.d.), and categorical variables as frequencies

and percentages. The main binary outcome (presence or absence of hypocalcaemia on POD 10) was compared between the two groups using an unconditional exact test of non-inferiority for two independent binomial samples, to assess whether the intervention group was non-inferior to the control group. Paired *t* test was used to compare the calcium and PTH values on POD 1 and POD 10.

Statistical significance was assessed at the two-sided 0.05 level for all analyses. All analyses were performed using R software (R Foundation for Statistical Computing, Vienna,

**Table 3** Comparison of calcium and parathyroid levels between the randomized groups

	Control group (n = 73)	Intervention group (n = 73)	Difference†	P‡
Calcium (mmol/l)*				
POD 1	2.27(0.10)	n.a.		
POD 10	2.31(0.10)‡	2.30(0.11)	0.012 (-0.022, 0.046)	0.480
PTH (pmol/l)*				
POD 1	3.28(1.39)	n.a.		
POD 10	4.44(2.19)‡	4.88(2.05)	-0.441 (-1.144, 0.262)	0.217

\*Values are mean(s.d.); †values in parentheses are 95 per cent confidence intervals. ‡Calcium and parathyroid hormone (PTH) levels were significantly higher on POD 10 than POD 1 in the control group (mean difference in calcium 0.039 (95 per cent c.i. 0.012 to 0.067) mmol/l,  $P = 0.006$ ; mean difference in PTH 1.13 (0.66 to 1.61) pmol/l,  $P < 0.001$ ). POD, postoperative day; n.a., not available. §Paired  $t$  test.

Austria), except the exact test of non-inferiority, which was undertaken using StatXact® version 11 software.

## Results

Between September 2014 and February 2016, 196 patients underwent ICG angiography during total thyroidectomy or completion thyroidectomy, and a total of 499 parathyroid glands were evaluated (mean(s.d.) 2.5(1.0) parathyroid glands per patient) (Table 1). Of the 146 patients who met the inclusion criteria (at least 1 parathyroid gland with an ICG score of 2), 73 were randomized to the intervention group and 73 to the control group (Fig. 2).

The intervention and control groups did not differ with respect to surgical diagnosis and extent of surgery (Table 2). Fifty patients in whom ICG angiography failed to demonstrate at least one well perfused parathyroid gland were excluded from the randomized part of the study, but did not otherwise differ from included patients with respect to surgical diagnosis, surgical procedure, findings at pathology or other demographic characteristics (Table 2).

### Randomized patients

Hypocalcaemia (calcium level below 2.00 mmol/l) was not observed in either group. The intervention group was statistically non-inferior to the control group as the higher boundary of the confidence interval of the difference in hypocalcaemia proportion was lower than 0.07 (exact 95 per cent c.i. of difference -0.053 to 0.053;  $P = 0.012$ ). There was no difference in calcium or PTH levels between the groups on POD 10 (Table 3). No hypoparathyroidism (PTH level less than 1.1 pmol/l) was observed in either group.

As completion thyroidectomy can be considered a confounding factor, with the parathyroid glands on the side operated first having more time to recover, the data were reanalysed after exclusion of 16 patients who underwent completion thyroidectomy (11 in the intervention group and 5 in the control group). This did not change the result of non-inferiority of the intervention (exact 95 per cent c.i. of difference -0.062 to 0.062;  $P = 0.020$ ).

Two patients in the intervention group experienced typical symptoms of hypocalcaemia but had PTH levels in the normal range on POD 10, without calcium supplementation. One had a calcium level of 2.05 mmol/l, PTH level of 3.7 pmol/l and mild finger paraesthesia, which rapidly improved after oral calcium supplementation (dose 1 g). The other patient also experienced finger paraesthesia, with calcium and PTH values of 2.29 mmol/l and 5.2 pmol/l respectively. The symptoms improved a few minutes after oral calcium supplementation (1 g). For patients in the control group, standard oral supplementation kept calcium levels within normal limits; higher doses or additional active vitamin D were never needed.

### Non-randomized patients

ICG angiography failed to demonstrate at least one well perfused parathyroid gland in 50 patients, who were therefore not included in the randomized part of the study. Eleven of the 50 patients presented with hypoparathyroidism on POD 1, and six on POD 10; this was significantly different from the findings in randomized patients ( $P = 0.007$ ). Two of the 11 patients presented with symptomatic hypocalcaemia, despite systematic calcium supplementation, and needed intravenous calcium supplementation for 24 h. One patient still had hypoparathyroidism at 6 months; the other patient had normal calcium and PTH levels without calcium supplements at 6 months.

## Discussion

This RCT studied the value of ICG angiography of the parathyroid glands during thyroid surgery in predicting postoperative hypoparathyroidism. The findings indicate that ICG angiography is a good predictor of the absence of hypoparathyroidism after thyroidectomy, in contrast to visual evaluation of the parathyroid glands<sup>23,32,33</sup>. In this consecutive series of 196 patients, a well vascularized parathyroid gland could be identified in 146 (74.5 per cent) and none of the subsequently randomized patients presented with hypocalcaemia. Therefore, calcium and/or PTH measurements may no longer be necessary in patients with at least one well perfused parathyroid gland, as demonstrated by ICG angiography after thyroidectomy.

Postoperative hypoparathyroidism is the most common complication of total thyroidectomy<sup>3</sup>, and patients are at risk of developing permanent hypoparathyroidism. In severe cases this can lead to cerebral, vascular, ocular and renal damage, and to a significant reduction in quality of life<sup>6,34–36</sup>. For more than a century, hypocalcaemia symptoms have been monitored carefully and measurements of calcium (and often PTH) levels used as standard of care after total thyroidectomy. Unlike ICG angiography, none of the currently used methods (serial calcium measurements<sup>14</sup>, PTH measurement a few hours after thyroidectomy<sup>9,37</sup> or even intraoperative PTH measurements<sup>19,20</sup>) can predict the absence of hypoparathyroidism immediately after thyroid resection.

Most thyroid centres use a combination of postoperative calcium and/or PTH measurements, with calcium (and sometimes vitamin D) supplementation given either systematically to prevent symptomatic hypocalcaemia, or on demand according to calcium level and/or symptoms. The protocol differs between centres, mainly depending on the length of hospital stay, the prevalence of hypocalcaemia and the personal preferences of each surgeon<sup>3,4</sup>. Before the present study, the standard protocol at the authors' institution included determination of corrected calcium level and PTH on POD 1, and systematic supplementation with calcium and 25-hydroxyvitamin D.

ICG fluorescence is one of the most recent breakthroughs in the field of intraoperative imaging and, as the present results show, modifies perioperative surgical management. First, it might prevent hypoparathyroidism by limiting trauma to the parathyroid glands during surgery, with the surgeon dissecting the parathyroid gland vasculature more thoroughly and carefully, and eventually leaving a thyroid remnant to preserve the parathyroid glands<sup>11</sup>. Second, ICG fluorescence allows each gland to be evaluated separately, and does not limit evaluation to overall parathyroid gland function. Another advantage of ICG fluorescence is the change in management of parathyroid glands to be reimplanted. In this study, 37 parathyroid glands were autotransplanted in 34 patients; 14 could not be preserved *in situ* or were found in the specimen after resection, and 23 were autotransplanted based on ICG results indicating absence of perfusion.

A difficulty with ICG angiography is identifying parathyroid glands with certainty. Even experienced thyroid surgeons might misinterpret other anatomical structures for a parathyroid gland. In experienced hands, however, the rate of correct identification of a structure as a parathyroid gland should exceed 95 per cent<sup>38</sup>, and the results of the present study also suggest that a systematic biopsy is not necessary to confirm that the structure identified is

indeed a parathyroid gland. In less experienced hands, it would be valuable to have a tool to help detect and identify parathyroid glands. New reports on parathyroid gland autofluorescence<sup>39,40</sup> envisage use of a combination of autofluorescence to identify the parathyroid glands, followed by ICG angiography to confirm their vascularization. However, the equipment used in the present study cannot currently detect parathyroid gland autofluorescence, as it is unable to stimulate and detect a precise wavelength. Because all four parathyroid glands were not identified, which is not unusual in standard thyroidectomy, the vascularization and function of the unidentified parathyroid glands remain unknown. Consequently, a direct correlation between ICG scores (of individual parathyroid glands) and PTH levels could not be shown in this study. In another study<sup>31</sup> of patients undergoing subtotal parathyroidectomy, the ICG score of the parathyroid remnant correlated with postoperative function, and thus PTH secretion could be attributed directly to the parathyroid remnant. Another limitation is the subjective nature of visual and ICG scores. Fluorescence was not quantifiable with the fluorescence equipment used; instead, shades of grey of the parathyroid gland were compared visually with those of the surrounding vessels and tissues<sup>41</sup>. Unfortunately, the Novadaq camera system used in this study does not give a quantitative/numerical score but a qualitative one, in colour shades. Other options, such as pixel/colour analysing computer programs, could be used in the future to score the angiography results objectively. The randomized design should, however, reduce the bias of non-quantifiable fluorescence to a minimum. The follow-up of 10–15 days appeared sufficient for assessing both immediate postoperative parathyroid function and the absence of long-term/delayed hypoparathyroidism as patients with good postoperative function will not develop late hypoparathyroidism.

This prospective RCT has demonstrated that finding one well perfused parathyroid gland using ICG angiography is a reliable way of predicting the absence of postoperative hypoparathyroidism. Total thyroidectomy can be performed safely without systematic calcium/PTH measurement, without systematic calcium supplementation, and with no risk of hypocalcaemia in patients with at least one well vascularized parathyroid gland. The use of this tool could contribute to the development of same day/ambulatory surgery. The next step is to use ICG angiography to not only predict but also prevent post-thyroidectomy hypoparathyroidism. Because of its unique ability to guarantee the function of individual parathyroid glands<sup>31</sup>, ICG angiography can be performed after the first lobe of the thyroid has been resected, and

the extent of resection of the second side of the thyroid can be adapted accordingly; a near-total or subtotal thyroidectomy can be performed for the second side for benign thyroid disease (and even for low-grade thyroid cancer, according to recent recommendations<sup>42</sup>) if ICG angiography cannot demonstrate a well vascularized parathyroid gland after resection of the first side. This future area of research could significantly help decrease the rate of postoperative hypoparathyroidism.

### Acknowledgements

J.V.F. and S.M.S. contributed equally to this work and are joint first authors. The authors thank P. Derish for helpful editorial comments. This study was funded entirely by the Department of Thoracic and Endocrine Surgery, University Hospitals of Geneva.

*Disclosure:* The authors declare no conflict of interest.

### References

- Puzziello A, Rosato L, Innaro N, Orlando G, Avenia N, Perigli G *et al.* Hypocalcemia following thyroid surgery: incidence and risk factors. A longitudinal multicenter study comprising 2631 patients. *Endocrine* 2014; **47**: 537–542.
- Zambudio AR, Rodríguez J, Riquelme J, Soria T, Canteras M, Parrilla P. Prospective study of postoperative complications after total thyroidectomy for multinodular goiters by surgeons with experience in endocrine surgery. *Ann Surg* 2004; **240**: 18–25.
- Edafe O, Antakia R, Laskar N, Uttley L, Balasubramanian SP. Systematic review and meta-analysis of predictors of post-thyroidectomy hypocalcaemia. *Br J Surg* 2014; **101**: 307–320.
- Lorente-Poch L, Sancho JJ, Muñoz-Nova JL, Sánchez-Velázquez P, Sitges-Serra A. Defining the syndromes of parathyroid failure after total thyroidectomy. *Gland Surg* 2015; **4**: 82–90.
- Underbjerg L, Sikjaer T, Mosekilde L, Rejnmark L. Cardiovascular and renal complications to postsurgical hypoparathyroidism: a Danish nationwide controlled historic follow-up study. *J Bone Miner Res* 2013; **28**: 2277–2285.
- Shoback D. Clinical practice. Hypoparathyroidism. *N Engl J Med* 2008; **359**: 391–403.
- Genser L, Tresallet C, Godiris-Petit G, Li Sun Fui S, Salepcioglu H, Royer C *et al.* Randomized controlled trial of alfacalcidol supplementation for the reduction of hypocalcemia after total thyroidectomy. *Am J Surg* 2014; **207**: 39–45.
- Abboud B, Sleilaty G, Zeineddine S, Braidy C, Aouad R, Tohme C *et al.* Is therapy with calcium and vitamin D and parathyroid autotransplantation useful in total thyroidectomy for preventing hypocalcemia? *Head Neck* 2008; **30**: 1148–1154.
- Hermann M, Ott J, Promberger R, Kober F, Karik M, Freissmuth M. Kinetics of serum parathyroid hormone during and after thyroid surgery. *Br J Surg* 2008; **95**: 1480–1487.
- Bliss RD, Gauger PG, Delbridge LW. Surgeon's approach to the thyroid gland: surgical anatomy and the importance of technique. *World J Surg* 2000; **24**: 891–897.
- Park I, Rhu J, Woo JW, Choi JH, Kim JS, Kim JH. Preserving parathyroid gland vasculature to reduce post-thyroidectomy hypocalcemia. *World J Surg* 2016; **40**: 1382–1389.
- Almquist M, Hallgrímsson P, Nordenström E, Bergenfelz A. Prediction of permanent hypoparathyroidism after total thyroidectomy. *World J Surg* 2014; **38**: 2613–2620.
- Julian MT, Balibrea JM, Granada ML, Moreno P, Alastrué A, Puig-Domingo M *et al.* Intact parathyroid hormone measurement at 24 hours after thyroid surgery as predictor of parathyroid function at long term. *Am J Surg* 2013; **206**: 783–789.
- Adams J, Andersen P, Everts E, Cohen J. Early postoperative calcium levels as predictors of hypocalcemia. *Laryngoscope* 1998; **108**: 1829–1831.
- Marohn MR, LaCivita KA. Evaluation of total/near-total thyroidectomy in a short-stay hospitalization: safe and cost-effective. *Surgery* 1995; **118**: 943–947.
- Terris DJ, Snyder S, Carneiro-Pla D, Inabnet WB 3rd, Kandil E, Orloff L *et al.*; American Thyroid Association Surgical Affairs Committee Writing Task Force. American Thyroid Association statement on outpatient thyroidectomy. *Thyroid* 2013; **23**: 1193–1202.
- Cmilansky P, Mrozova L. Hypocalcemia – the most common complication after total thyroidectomy. *Bratisl Lek Listy* 2014; **115**: 175–178.
- Lo CY, Luk JM, Tam SC. Applicability of intraoperative parathyroid hormone assay during thyroidectomy. *Ann Surg* 2002; **236**: 564–569.
- Lang BH, Yih PC, Ng KK. A prospective evaluation of quick intraoperative parathyroid hormone assay at the time of skin closure in predicting clinically relevant hypocalcemia after thyroidectomy. *World J Surg* 2012; **36**: 1300–1306.
- Gupta S, Chaudhary P, Durga CK, Naskar D. Validation of intra-operative parathyroid hormone and its decline as early predictors of hypoparathyroidism after total thyroidectomy: a prospective cohort study. *Int J Surg* 2015; **18**: 150–153.
- Lo CY, Lam KY. Routine parathyroid autotransplantation during thyroidectomy. *Surgery* 2001; **129**: 318–323.
- Barczyński M, Cichoń S, Konturek A, Cichon W. Applicability of intraoperative parathyroid hormone assay during total thyroidectomy as a guide for the surgeon to selective parathyroid tissue autotransplantation. *World J Surg* 2008; **32**: 822–828.
- Ji YB, Song CM, Sung ES, Jeong JH, Lee CB, Tae K. Postoperative hypoparathyroidism and the viability of the parathyroid glands during thyroidectomy. *Clin Exp Otorhinolaryngol* 2017; **10**: 265–271.

- 24 de Boer E, Harlaar NJ, Taruttis A, Nagengast WB, Rosenthal EL, Ntziachristos V *et al.* Optical innovations in surgery. *Br J Surg* 2015; **102**: e56–e72.
- 25 Ishizawa T, Fukushima N, Shibahara J, Masuda K, Tamura S, Aoki T *et al.* Real-time identification of liver cancers by using indocyanine green fluorescent imaging. *Cancer* 2009; **115**: 2491–2504.
- 26 Halle BM, Poulsen TD, Pedersen HP. Indocyanine green plasma disappearance rate as dynamic liver function test in critically ill patients. *Acta Anaesthesiol Scand* 2014; **58**: 1214–1219.
- 27 Ris F, Hompes R, Lindsey I, Cunningham C, Mortensen NJ, Cahill RA. Near infra-red laparoscopic assessment of the adequacy of blood perfusion of intestinal anastomosis – a video vignette. *Colorectal Dis* 2014; **16**: 646–647.
- 28 Vidal Fortuny J, Karenovics W, Triponez F, Sadowski S. Innovative surgical techniques around the world: intra-operative indocyanine green angiography of the parathyroid gland. *World J Surg* 2016; **40**: 2378–2381.
- 29 Vidal Fortuny J, Belfontali V, Sadowski S, Karenovics W, Guigard S, Triponez F. Parathyroid gland angiography with indocyanine green fluorescence to predict parathyroid function after thyroid surgery. *Br J Surg* 2016; **103**: 537–543.
- 30 Zaidi N, Bucak E, Yazici P, Soundararajan S, Okoh A, Yigitbas H *et al.* The feasibility of indocyanine green fluorescence imaging for identifying and assessing the perfusion of parathyroid glands during total thyroidectomy. *J Surg Oncol* 2016; **113**: 775–778.
- 31 Vidal Fortuny J, Sadowski SM, Belfontali V, Karenovics W, Guigard S, Triponez F. Indocyanine green angiography in subtotal parathyroidectomy: technique for the function of the parathyroid remnant. *J Am Coll Surg* 2016; **223**: e43–e49.
- 32 Promberger R, Ott J, Kober F, Mikola B, Karik M, Freissmuth M *et al.* Intra- and postoperative parathyroid hormone-kinetics do not advocate for autotransplantation of discolored parathyroid glands during thyroidectomy. *Thyroid* 2010; **20**: 1371–1375.
- 33 Kuhel WI, Carew JF. Parathyroid biopsy to facilitate the preservation of functional parathyroid tissue during thyroidectomy. *Head Neck* 1999; **21**: 442–446.
- 34 Thomusch O, Machens A, Sekulla C, Ukkat J, Brauckhoff M, Dralle H. The impact of surgical technique on postoperative hypoparathyroidism in bilateral thyroid surgery: a multivariate analysis of 5846 consecutive patients. *Surgery* 2003; **133**: 180–185.
- 35 Zarnegar R, Brunaud L, Clark OH. Prevention, evaluation, and management of complications following thyroidectomy for thyroid carcinoma. *Endocrinol Metab Clin North Am* 2003; **32**: 483–502.
- 36 Arlt W, Fremerey C, Callies F, Reincke M, Schneider P, Timmermann W *et al.* Well-being, mood and calcium homeostasis in patients with hypoparathyroidism receiving standard treatment with calcium and vitamin D. *Eur J Endocrinol* 2002; **146**: 215–222.
- 37 Lombardi CP, Raffaelli M, Princi P, Dobrinja C, Carozza C, Di Stasio E *et al.* Parathyroid hormone levels 4 hours after surgery do not accurately predict post-thyroidectomy hypocalcemia. *Surgery* 2006; **140**: 1016–1023.
- 38 Lang BH, Wong CK, Hung HT, Wong KP, Mak KL, Au KB. Indocyanine green fluorescence angiography for quantitative evaluation of *in situ* parathyroid gland perfusion and function after total thyroidectomy. *Surgery* 2017; **161**: 87–95.
- 39 De Leeuw F, Breuskin I, Abbaci M, Casiraghi O, Mirghani H, Ben Lakhdar A *et al.* Intraoperative near-infrared imaging for parathyroid gland identification by auto-fluorescence: a feasibility study. *World J Surg* 2016; **40**: 2131–2138.
- 40 McWade MA, Sanders ME, Broome JT, Solorzano CC, Mahadevan-Jansen A. Establishing the clinical utility of autofluorescence spectroscopy for parathyroid detection. *Surgery* 2016; **159**: 193–202.
- 41 Vidal Fortuny J, Guigard S, Diaper J, Karenovics W, Triponez F. Subtotal parathyroidectomy under indocyanine green angiography. *J VideoEndocrinology* 2015. <https://doi.org/10.1089/ve.2015.0056> [accessed 18 December 2017].
- 42 Haugen BR, Alexander EK, Bible KC, Doherty GM, Mandel SJ, Nikiforov YE *et al.* 2015 American Thyroid Association management guidelines for adult patients with thyroid nodules and differentiated thyroid cancer: the American Thyroid Association Guidelines Task Force on Thyroid Nodules and Differentiated Thyroid Cancer. *Thyroid* 2016; **26**: 1–133.

### Supporting information

Additional supporting information can be found online in the supporting information tab for this article.