

Verrucous sarcoidosis associated with human papillomavirus infection: A case report

Michael Noparstak, BA,^a Brianna McDaniel, DO,^b Joy King, MD,^c Robert T. Brodell, MD,^{c,d,e} Peter Rady, MD, PhD,^f Ramya Killipara, MD,^g and Stephen Tyring, MD, PhD^h
Fort Lauderdale, Florida; Blacksburg, Virginia; Jackson, Mississippi; Rochester, New York; and Houston, Texas

Key words: cutaneous sarcoidosis; human papillomavirus; immunocompromised district; sarcoidosis; verrucous sarcoidosis; verruca vulgaris.

Verrucous sarcoidosis (VS) is a rare variant of cutaneous sarcoidosis that most often appears on the lower extremities. It could represent a localized hypertrophic response over an area with underlying noncaseating sarcoidal granulomas or a response secondary to a viral wart overlying a sarcoidal plaque. A case of annular VS on the face is reported in the setting of widespread background cutaneous papular and plaque sarcoidosis.

CASE REPORT

A 51-year old African-American woman with a history of pulmonary sarcoidosis for more than a decade presented for evaluation of a facial rash. The rash had been present for several years and failed to respond to hydrocortisone 2.5% cream twice daily during this period. A laceration on the nasal bridge induced by blunt trauma from the nose pad of her eyeglasses occurred immediately before the appearance of expanding verrucous papillomatous changes in this area. She had no personal or family history of warts.

An annular plaque with verrucous surface features and central clearing was present on the bridge of the nose (Fig 1, A and B). Numerous skin-colored to violaceous papules and plaques, all demonstrating a smooth surface, were distributed on the forehead, temples, chin, and cheeks (Fig 1, A and B).

Abbreviations used:

HPV: human papillomavirus
 PCR: polymerase chain reaction
 VS: verrucous sarcoidosis

A 4-mm punch biopsy specimen from a dermal plaque on the right cheek showed sarcoidal granulomas. Periodic acid-Schiff and Acid-Fast Bacilli stains showed no offending organisms, and no polarizable foreign material was present. A 4-mm punch biopsy from the verrucous lesion on the bridge of the nose demonstrated hyperkeratosis, acanthosis, hypergranulosis, and papillomatosis with parakeratosis overlying digitate projections of epithelium. Mild vacuolization of the granular layer was noted between the projections. Sarcoidal granulomas, composed of histiocytes including scattered multinucleated giant cells, were present in the underlying dermis surrounded by a few scattered lymphocytes (Fig 2, A and B).

Sections from the punch biopsy of the verrucous lesion were sent for DNA quality assessment by β -globin reference gene polymerase chain reaction (PCR). DNA quality assessment was positive, and human papillomavirus (HPV) typing by PCR using the nested primer system was performed.¹ HPV-PCR product was detected by the nested

Nova Southeastern University, Fort Lauderdale^a; VCOM/Lewis-Gale Hospital Montgomery, Blacksburg^b; Departments of Pathology^c and Dermatology,^d University of Mississippi Medical Center; Department of Dermatology, University of Rochester School of Medicine and Dentistry,^e University of Texas Medical School, Houston^f; Center for Clinical Studies, Houston^g; and University of Texas Health Science Center & Center for Clinical Studies, Houston.^h

Funding sources: None.

Conflicts of interest: Robert Brodell, MD has received honoraria from presentations for Allergan, Galderma, and PharmaDerm, a division of Nycomed US Inc. Consultant fees have been received from Galderma Laboratories, L.P. Clinical trials have

been performed for Genentech and Janssen Biotech, Inc. The other authors declared no conflicts of interest.

Correspondence to: Robert T. Brodell, MD, Department of Dermatology, University of Mississippi Medical Center, 2500 North State Street, Jackson, MS 39216. E-mail: rbrodell@umc.edu.

JAAD Case Reports 2015;1:247-50.

2352-5126

© 2015 by the American Academy of Dermatology, Inc. Published by Elsevier, Inc. This is an open access article under the CC BY-NC-ND license (<http://creativecommons.org/licenses/by-nc-nd/4.0/>).

<http://dx.doi.org/10.1016/j.jidcr.2015.05.006>

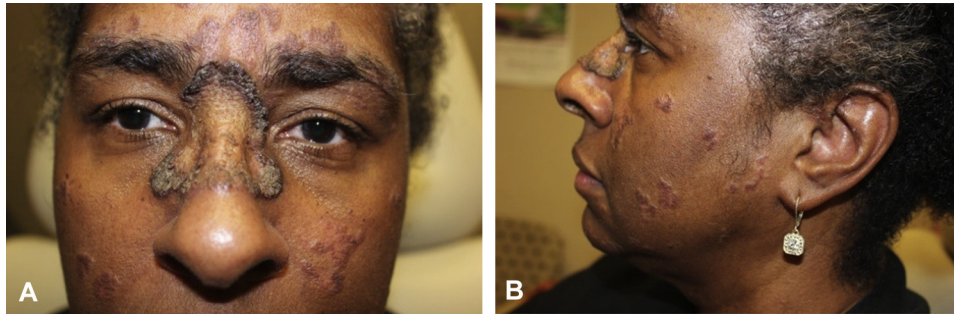


Fig 1. **A**, An annular verrucous plaque with central clearing slowly expanded over several years after blunt trauma to the bridge of the nose. **B**, Scattered 1- to 8-mm hyperpigmented dermal papules and plaques without scaling on the cheeks.

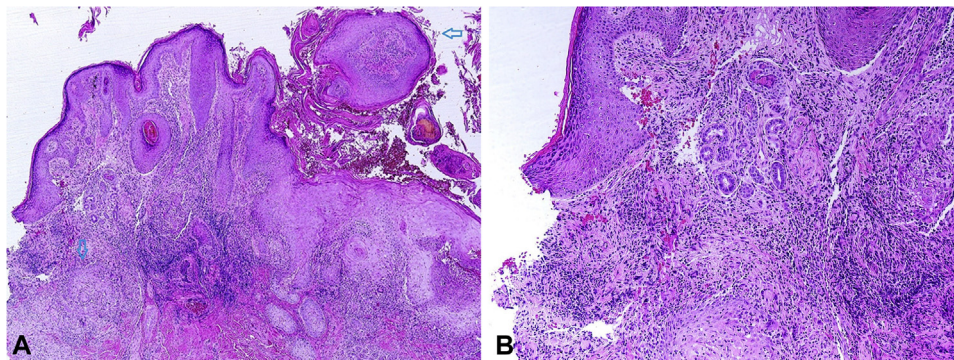


Fig 2. **A**, Epidermis shows papillomatous architecture with hyperkeratosis and acanthosis. Parakeratosis overlies digitate projections (*left pointing arrow*) of epithelium. Hypergranulosis with vacuolization presents between the projections. A sarcoidal granuloma (*downward arrow*) is noted in the upper dermis. **B**, Sarcoidal granulomas with multinucleated giant cells are surrounded by a sprinkling of lymphocytes. (**A** and **B**, Hematoxylin-eosin stain; original magnifications: **A**, $\times 40$; **B**, $\times 100$.)

forslund antonsson primer (FAP) system in DNA extracted from the tissue sample, and the HPV-PCR product obtained from the sample was cloned and sequenced. The National Center for Biotechnology Information Basic Local Alignment Search Tool (NCBI BLAST) analysis of the sequence information obtained from the clones found the presence of HPV type candidate FA14 (Fig 3, A-C).

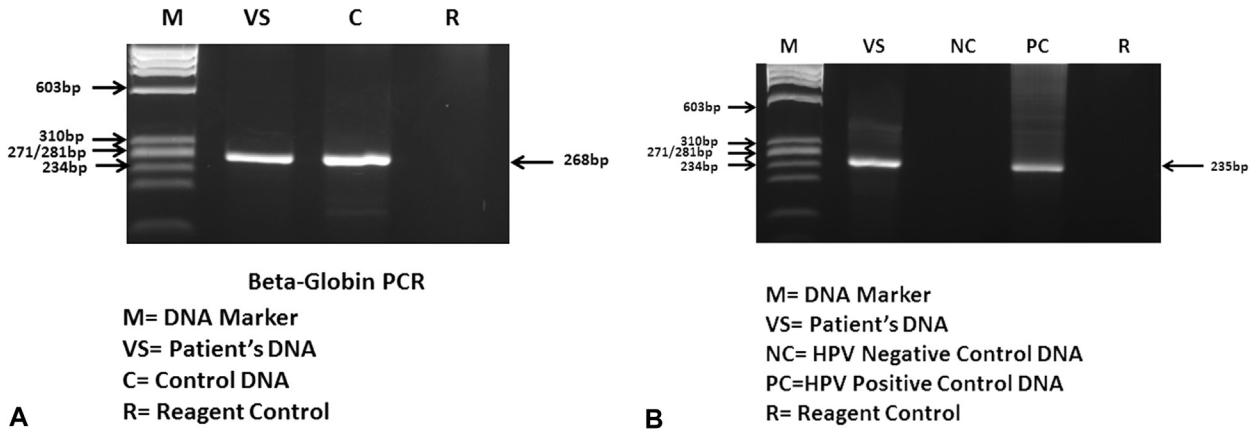
Imiquimod 5% cream 3 times a week was initiated but then discontinued because of severe irritation after 2 weeks. The cutaneous sarcoidosis was treated with hydroxychloroquine, 200 mg orally twice a day. Three months later, the patient returned after being lost to follow-up. The original annular verrucous lesion expanded, and 2 new annular verrucous lesions appeared overlying areas in which previous sarcoidal papules and plaques had been present (Fig 4, A-C). Despite the new and expanding verrucous lesions, the background smooth-surfaced sarcoidal papules and plaques had improved 80% to 90% since her previous visit. Treatment with imiquimod 5% cream was restarted

once weekly to verrucous areas, and hydroxychloroquine was continued.

DISCUSSION

Sarcoidosis is known as one of the great imitators, with skin findings occurring in 20% to 35% of cases. In some cases, skin lesions are the only manifestation of sarcoidosis.^{2,3} These cutaneous findings are classified as specific when they are associated with cutaneous granulomas (Table D). The maculopapular form is the most common specific dermatologic manifestation of sarcoidosis.³ Nonspecific dermatologic manifestations of sarcoidosis are not associated with granulomas (see Table I).^{3,4} Erythema nodosum is the most common nonspecific dermatologic manifestation of sarcoidosis.^{3,4}

VS is a rare, specific form of cutaneous sarcoidosis usually occurring in association with severe pulmonary disease.^{4,5} It most commonly affects the lower extremities.^{4,6} The differential diagnoses for verrucous sarcoidosis include verruca vulgaris, hypertrophic lichen planus, prurigo nodularis, and



Alignments

Human papillomavirus isolate FA14 major capsid protein L1 gene, partial cds
Sequence ID: gb|AF217656.1|AF217656 Length: 434 Number of Matches: 1
Range 1: 84 to 318

Score	Expect	Identities	Gaps	Strand	Frame
401 bits(217)	2e-108()	229/235(97%)	0/235(0%)	Plus/Minus	

Features:

Query	1	ACATTGGAGTTGTTGGGGTCAAATGAAATATTTTGTCTATCATCCTTAGAGGAGTTCC	60
Sbjct	318	ACATTGCAACTGCTTGGGGTCAAATGAAATATTTTGTCTATCATCCTTAGAGGAGTTCC	259
Query	61	TATATGTATTGCCATTTTCTGTATCATTAAACCTTATTAACAGTGGATGACCACTGCTGC	120
Sbjct	258	TATATGTATTGCCATTTTCTGTATCATTAAACCTTATTAACAGTGGATGACCACTGCTGC	199
Query	121	CTATTCCATAAAGGTTGGCCCTGCCTATTTCTATGCCTTCAAACCCATACTAATCTTT	180
Sbjct	198	CTATTCCATAAAGGTTGGCCCTGCCTATTTCTATGCCTTCAAACCCATACTAATCTTT	139
Query	181	CTTGTGTCAGGTTATATACTGACATGTCAGCTAACGCAAACCGATTGGATCTGG	235
Sbjct	138	CTTGTGTCAGGTTATATACTGACATGTCAGCTAACGCAAACCTATTAGGATCTGG	84

Fig 3. A, The patient's DNA was positive with β -globin PCR assay. B, The patient's sample was positive with FAP-nested PCR assay designed primarily for the detection of cutaneous HPVs. C, National Center for Biotechnology Information Basic Local Alignment Search Tool analysis of DNA sequence information obtained from the 235 base pair-sized HPV-PCR product found the presence of FA14 HPV isolate in the patient's sample.

infectious processes such as blastomycosis and mycobacterial diseases.^{2,4}

The pathophysiologic basis of VS is not clear. The verrucous epidermal response seen on histopathology could represent an alteration in cutaneous response to persistent mechanical irritation and, therefore, characterizes a type of hypertrophic localized neurodermatitis.⁷ A similar mechanism has been proposed for the epidermal change in psoriasiform sarcoidosis.⁸ The patient in this case did not complain of pruritus and denied rubbing the lesions. Furthermore, HPV was identified in this case supporting viral etiology of the verrucous hyperplasia.

Second, the HPV could serve as a sarcoidal priming antigen initiating the underlying cutaneous

sarcoidosis.⁹⁻¹¹ Of course, in this case, most facial cutaneous sarcoidal papules and plaques were not associated with overlying verrucous change. It is unlikely that 2 priming antigens were present.

A third explanation appears to be the most likely. The verrucous change may have been initiated by local inoculation of HPV after eyeglass trauma. The HPV then preferentially spread and rapidly grew in previously formed sarcoidal plaques. These plaques may represent immunocompromised districts.¹² First, the granulomatous inflammatory process in the dermis may suppress immune mechanisms in the epidermis potentiating the growth of the virus. Second, the immunosuppressive effects of topical steroid treatment may have played a role in viral propagation and spread. This explanation is

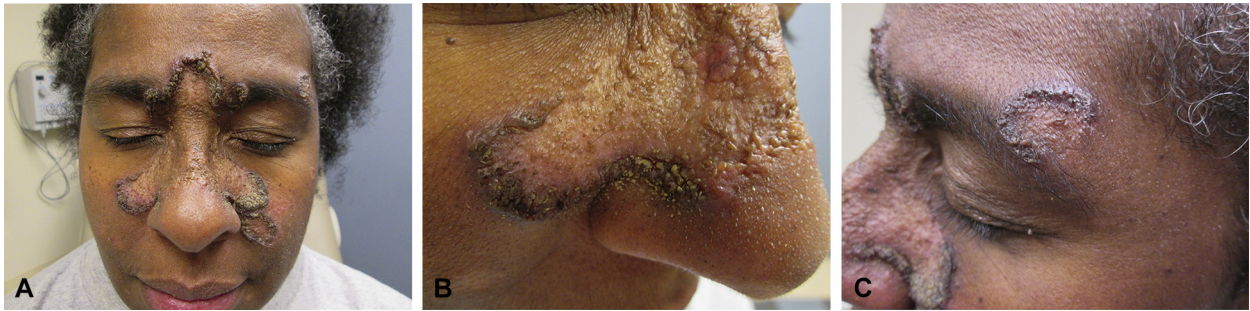

Fig 4. **A**, Expansion of the original annular verrucous lesion. Two newer-appearing annular verrucous lesions, one just lateral to the left nasolabial fold and the other superior to the left lateral eyebrow arose in pre-existing sarcoidal plaques. Note the improvement in the background cutaneous sarcoidosis papules and plaques. (Compare with Fig 1, A and B.) **B**, Close-up view of the annular verrucous lesion along the right nasal sidewall. **C**, Close-up view of the annular verrucous lesion superior to the left lateral eyebrow.

Table I. Dermatologic findings in sarcoidosis

Specific manifestations	Nonspecific manifestations
Maculopapular	Erythema nodosum
Plaque	Calcifications
Nodular	Prurigo
Annular	Erythema multiforme
Lupus pernio	Nail clubbing
Cicatrical/scar	Sweet's syndrome
Scarring alopecia	
Ulcerative	
Ichthyosiform	
Erythrodermic	
Subcutaneous	
Morpheaform	
Mucosal	
Verrucous	
Psoriasiform	
Lichenoid	
Angioliupoid	
Nail dystrophy	

supported by the occurrence of new warts only in areas overlying previous cutaneous sarcoidal granulomas without interval trauma at these sites.

A limitation of the positive HPV tissue sample is the finding of HPV FA14 in healthy skin and in the skin of immunocompromised renal transplant patients.¹³ On the other hand, the clinical appearance, expansive growth, and Hematoxylin-eosin stain findings support the viral etiology of these verrucous lesions. To the best of our knowledge, this is the first time HPV has been confirmed in verrucous sarcoidosis. Studies should be performed to determine if this is an unusual finding or if HPV is present in many cases of verrucous sarcoidosis. In addition to better understanding the pathophysiologic basis of this condition, the presence of HPV-associated verrucous

sarcoidosis in some patients would lead to more focused prevention and treatment options.

REFERENCES

1. Forslund O, Ly H, Higgins G. Improved detection of cutaneous human papillomavirus DNA by single tube nested 'hanging droplet' PCR. *J Virol Methods*. 2003;110(2):129-136.
2. Tchernev G, Patterson JW, Nenoff P, Horn LC. Sarcoidosis of the skin— a dermatological puzzle: important differential diagnostic aspects and guidelines for clinical and histopathological recognition. *J Eur Acad Dermatol Venereol*. 2010;24(2):125-137.
3. Lodha S, Sanchez M, Prystowsky S. Sarcoidosis of the skin: a review for the pulmonologist. *Chest*. 2009;136(2):583-596.
4. DeFelice T, Fischer M, Kamino H, Cohen D, Latkowski JA. Verrucous and macular sarcoidosis. *Dermatol Online J*. 2012;18(12):10.
5. Corradin MT, Forcione M, Fiorentino R, Bordignon M, Alaibac M, Belloni-Fortina A. Verrucous cutaneous sarcoidosis in an adolescent with dark skin. *Eur J Dermatol*. 2010;20(5):659-660.
6. Irgang S. Verrucous and papillomatous types of sarcoid; report of a case. *Arch Derm Syphilol*. 1950;62(1):105-108.
7. Shaffer B, Beerman H. Lichen simplex chronicus and its variants; a discussion of certain psychodynamic mechanisms and clinical and histopathologic correlations. *AMA Arch Derm Syphilol*. 1951;64(3):340-351.
8. Murphy GF, Herzberg AJ. Psoriasiform dermatitis. In: Murphy GF, Herzberg AJ, eds. *Dermatopathology*. Philadelphia: WB Saunders and Co; 1996:49-50.
9. Okamoto H. Epidermal changes in cutaneous lesions of sarcoidosis. *Am J Dermatopathol*. 1999;21(3):229-233.
10. Martin AG, Kleinhenz ME, Elmetts CA. Immunohistologic identification of antigen-presenting cells in cutaneous sarcoidosis. *J Invest Dermatol*. 1986;86(6):625-629.
11. Mahony J, Helms SE, Brodell RT. The sarcoidal granuloma: a unifying hypothesis for an enigmatic response. *Clin Dermatol*. 2014;32(5):654-659.
12. Lo Schiavo A, Ruocco E, Gambardella A, O'Leary RE, Gee S. Granulomatous dysimmune reactions (sarcoidosis, granuloma annulare, and others) on differently injured skin areas. *Clin Dermatol*. 2014;32(5):646-653.
13. Hazard K, Karlsson A, Andersson K, Ekberg H, Dillner J, Forslund O. Cutaneous human papillomaviruses persist on healthy skin. *J Invest Dermatol*. 2007;127(1):116-119.