

R E V I E W

MRI of popliteo-meniscal fasciculi of the knee: a pictorial review

Marcello Zappia¹, Alfonso Reginelli², Vito Chianca³, Michela Carfora¹, Francesco Di Pietto⁴, Germano Iannella⁵, Pier Paolo Mariani⁵, Mariano Di Salvatore⁶, Silvia Bartollino¹, Nicola Maggialetti¹, Salvatore Cappabianca², Luca Brunese¹

¹ Department of Medicine and Health Science "V. Tiberio", University of Molise, Campobasso, Italy; ² Department of Internal and Experimental Medicine, Magrassi-Lanzara, Institute of Radiology, Second University of Naples, Naples, Italy; ³ Department of Advanced Biomedical Sciences, Federico II University, Napoli, Italy; ⁴ Department of Radiology, Cardarelli Hospital, Naples, Italy; ⁵ Villa Stuart Sport Clinic, FIFA medical Centre of Excellence, Rome, Italy; ⁶ Division of Musculoskeletal Oncology Surgery, National Cancer Institute "G. Pascale", Naples, Italy

Summary. The popliteomeniscal fascicles (PMFs) provide the attachment of the lateral meniscus to the popliteus musculotendinous region, forming the floor and the roof the popliteal hiatus. In the second half of 1900's, some anatomic studies claim the important function of the PMF as stabilizers of the lateral meniscus; these anatomical structures work in conjunction with the popliteus musculotendinous unit to prevent excessive lateral meniscal movement and possible meniscus subluxation. A correct diagnosis of the PMFs pathology is crucial to establish the suitable surgical treatment for each patient. MRI is a well-established imaging technique in the musculoskeletal system and the frequency of recognition of normal PMF in the normal knees is high in almost all MRI studies. At day, the gold standard for diagnosis is the arthroscopic evaluation that allows the direct visualization of the popliteo-meniscal ligaments at popliteal hiatus and evaluation of lateral meniscal movements. For this reason if unstable condition of meniscus was suspected, arthroscopic observation with probing into the popliteo-meniscal fascicle area is essential for the identification of the fascicle tears. Despite many treatments have being proposed in literature since now there is high recurrence of knee locking after repair and it is fundamental to develop new surgical techniques in order to achieve better outcome. (www.actabiomedica.it)

Key words: MRI knee; knee ligaments; knee: posterolateral corner

Introduction

The popliteomeniscal fascicles (PMFs) provide the attachment of the lateral meniscus to the popliteus musculotendinous region, forming the floor and the roof of the popliteal hiatus.

In the second half of 1900's, some anatomic studies claim the important function of the PMF as stabilizers of the lateral meniscus; these anatomical structures work in conjunction with the popliteus musculotendinous unit to prevent excessive lateral meniscal

movement and possible meniscus subluxation (1-5). More recently it is underlined the role of PMFs for posterolateral stability. Tear of MPFs is the more common lesion involved in the 80% of patients with grade III of posterolateral injuries associated with anterior cruciate ligament (ACL) insufficiency (6-10).

Congenital absence or isolated injuries of the PMFs can result in micro or gross instability of the meniscus producing snapping or locking of the knee (11-15); tear or insufficiency of PMFs associated with ACL tear increases the knee laxity in as many as 25%

of patients. Both types of lesions often are difficult to recognize clinically (16-19). Therefore, a correct diagnosis of the PMFs pathology is crucial to establish the suitable surgical treatment for each patient.

Normal Anatomy

The popliteus is a thin and flat muscle that forms part of the floor of the popliteal space. Its tendon inserts on the lateral epicondyle, just anteroinferior to the proximal attachment of the lateral collateral ligament and passes posteriorly to the posterior horn of the lateral meniscus. The popliteus tendon is considered as intra-capsular but extra-articular and extra-synovial.

The popliteo-meniscal fascicles are posterolateral meniscocapsular structures that from body and posterior horn of the lateral meniscus blend inferiorly into the popliteus musculotendinous unit and allow the tendon to pass from an intra-articular to an extra-articular compartment (20-25).

However in literature there is still debate about the number of popliteomeniscal bands (26), most studies described at least two different fascicles: an antero-inferior and postero-superior (2, 27-30). Cohn and Mains described that the superior border of the popliteal hiatus defined the superior popliteo-meniscal ligament while the inferior border defined the inferior PMF (1).

The anteroinferior PMF arises from the body of the lateral meniscus, courses in a postero-inferior direction to form the floor of the popliteal hiatus, and then blends with the musculotendinous unit of the popliteus muscle; the lateral aspect of the anteroinferior PMF fuses with the popliteofibular ligament forming a conjoint attachment to the fibula (31-35) (Fig. 1a-b).

The posterosuperior PMF fascicle arises from the posterosuperior edge of the posterior horn of the lateral meniscus just medial to the popliteus tendon and it blends to the posterior capsule and the popliteus tendon; it forms the roof of the popliteal hiatus (Fig. 2) (31).

Sussmann et al. reported that the anteroinferior fascicle shows greater control over lateral meniscal mobility compared with the posterosuperior fascicle and they suggested that, during embryologic devel-

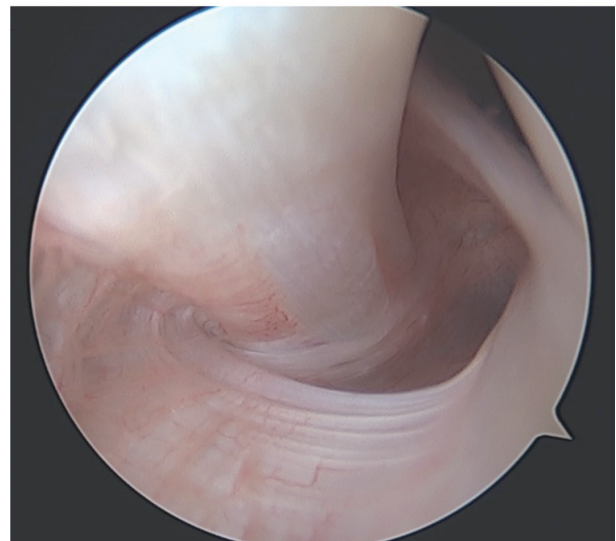
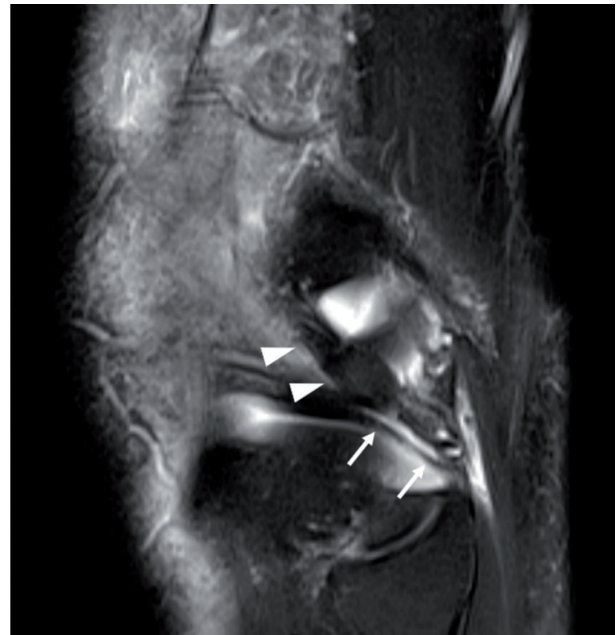

Figure 1 a-b. MR sagittal proton density weighted with fat saturation (PDw fat sat) sequence (a) and arthroscopy (b) of normal popliteal hiatus with popliteal tendon (arrowheads) and antero-inferior PMF (arrows)

opment, the fascicle provided a vascular supply to the lateral meniscus near to the popliteal hiatus where the meniscus was free of capsular attachment (36).

Several authors reported the presence of a third fascicle (2, 37-41), the postero-inferior PMF, which extends in the medial direction from the medial aponeurotic extension of the popliteus and attaches to the lower margin of the posterior horn of the lateral

meniscus immediately under the ligament of Wrisberg (Fig. 2) (31, 42, 43).

MRI is a well-established imaging technique in the musculoskeletal system and the frequency of recognition of normal PMF in the normal knees is high in almost all MRI studies (27, 31, 44-46).

In 1999 Johnson and De Smet reviewed sagittal MR images of 66 consecutive patients who had no evidence of injury to the lateral compartment and founded that PMFs were seen in 64 of the 66 patients with only 3% of knees with absent of PMFs (15, 45, 47-50).

Subsequently Sakai et al founded the anteroinferior PMF in 94.1% and the posterosuperior PMF in 88.2% of subjects; they recommended suitable parameters for better depicting the popliteomeniscal ligaments; in particular they suggested that the optimal parameters for the depiction of the PMF on MRI are proton-density weighting oblique-coronal images and 45° or 50° slice angle with the posterior tibial condyle for depicting both fasciculi at the same time (27, 51-55).

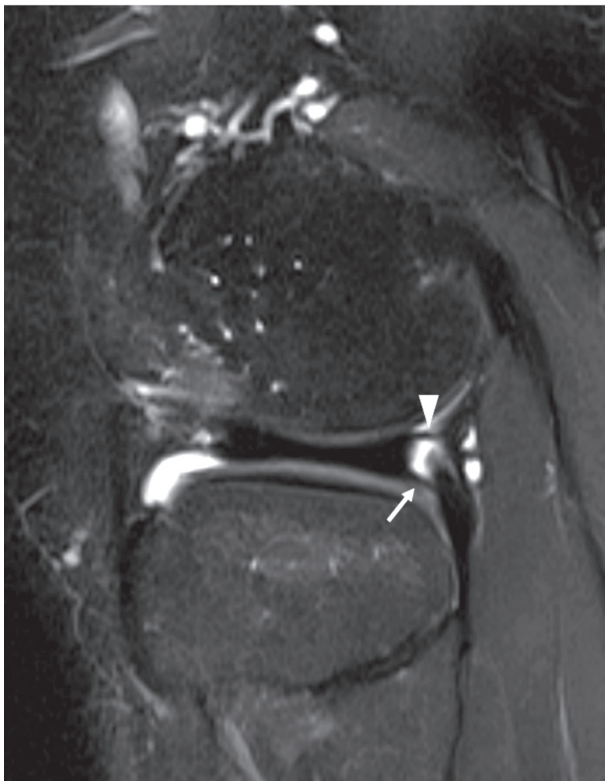

Figure 2. MR sagittal PDw fat sat sequence of normal posterosuperior (arrowhead) and postero-inferior PMFs (arrow)

In 2008, Peduto et al. performed MR arthrographic examination of 10 cadaveric knees and identified the anteroinferior and posterosuperior PMFs in all 10 knees and postero-inferior PMF in 4 of the knees; they stated that the posterosuperior popliteomeniscal fascicle was uniform in thickness, while the anteroinferior popliteomeniscal fascicle was variable in thickness (31, 56-58).

The so called “Wrisberg variant” is the third of the three lateral meniscal variant described by Watanabe and Takeda in their classification and it is characterized by the absence of the PMFs as well as meniscotibial coronary ligament and the meniscofemoral ligament of Wrisberg or Humphrey represent as the only posterior stabilizing structure (59)

Pathologic conditions

PMFs Congenital Absence (Wrisberg variant of lateral meniscus)

The “Wrisberg variant” of lateral meniscus is characterized by congenital absence of PMF fascicles and meniscotibial coronary ligament (12, 59, 60). This anatomic condition predisposes the posterior horn to hypermobility with locked or recurrent subluxation of lateral meniscus leading to knee locking or snapping in a young patient (61-64) (Fig. 3).

It is important to differentiate this snapping cause from the other’s one, like subluxations of the biceps femoris (65), discoid lateral meniscus (66), popliteus (67) and semitendinosus snapping (68).

The MRI of nondisplaced discoid Wrisberg variant of lateral meniscus shows the absence of PMF and coronary ligament, with a floating meniscus appearance and fluid signal line behind the posterior horn of meniscus (12, 69, 70) (Figs.4 a-c).

Even if Wrisberg variant of lateral meniscus be part of classification of discoid meniscus, Wrisberg meniscus may or may not have discoid morphology. In fact the absence of PMF is often associate with normal C-shape morphology of meniscus (12, 59, 71) (Fig. 5).

Some authors hypothesize that a trauma of the popliteomeniscal fascicles could lead to an unstable meniscus mimicking a Wrisberg variant, a so-called

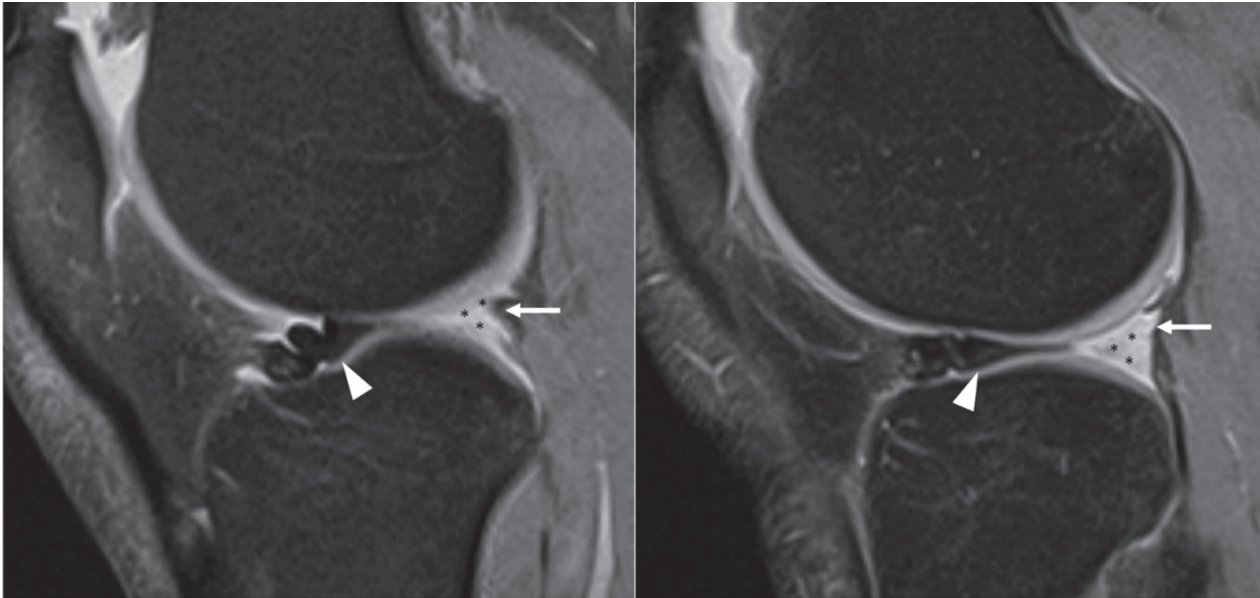


Figure 3. Two MR sagittal PDw fat sat consecutive sequences of lateral meniscal instability. The posterior horn of lateral meniscus is dislocated anteriorly (arrowhead) and its anatomic region is replaced by fluid signal (asterisks). Note the PMFs torn (arrow). MR sagittal PDw fat sat sequence of normal postero-superior (arrowhead) and postero-inferior PMFs (arrow)

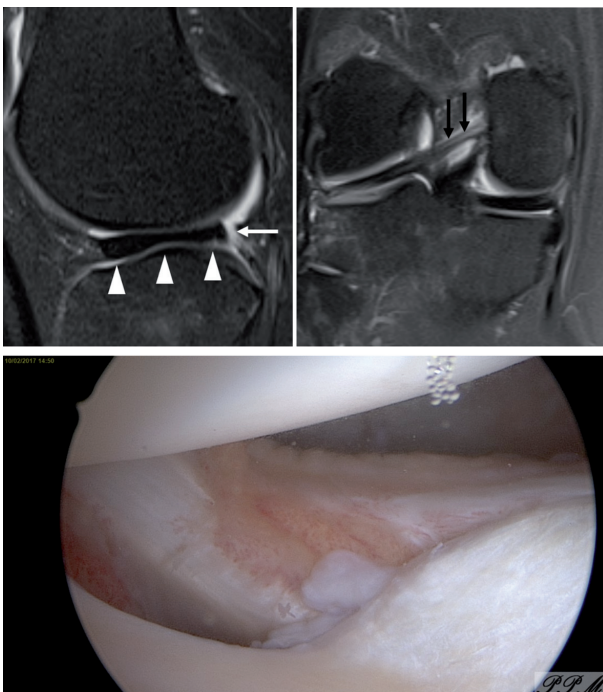


Figure 4 a-c. MR sagittal (a) and coronal (b) PDw fat sat sequences and arthroscopy (c) of Wrisberg variant of discoid lateral meniscus. The lateral meniscus shows discoid morphology (arrowheads), congenitally absent PMFs (with arrow) and it was stabilized only by the Wrisberg ligament (black arrows)

post-traumatic Wrisberg variant (61). Arthroscopic criteria have not been described that would distinguish a true Wrisberg variant meniscus from a traumatic injury to the posterior capsule (12) but the young age, the clinical presentation and the non-traumatic history of the patient can help to understand the origin of abnormality of PMFs.

If the patients could voluntarily lock and unlock his knee, the sagittal and coronal MRI sequences acquired before and after the pathologic movements showed the lateral meniscus in its anatomic position in the unlocked-knee position and the anteriorly flipped posterior horn lateral meniscus in the locked-knee position (62, 72) (Fig. 6).

PMFs tears

The PMFs have a crucial role as a stabilizers of the knee, avoiding the instability of the lateral meniscus during flexion and extension of the knee (11, 16, 37, 73).

Tears of PMFs could be an isolated consequence of trauma, but they have been observed at arthroscopic surgery in high percentage of knee injuries with anterior cruciate ligament tear and associated injuries of

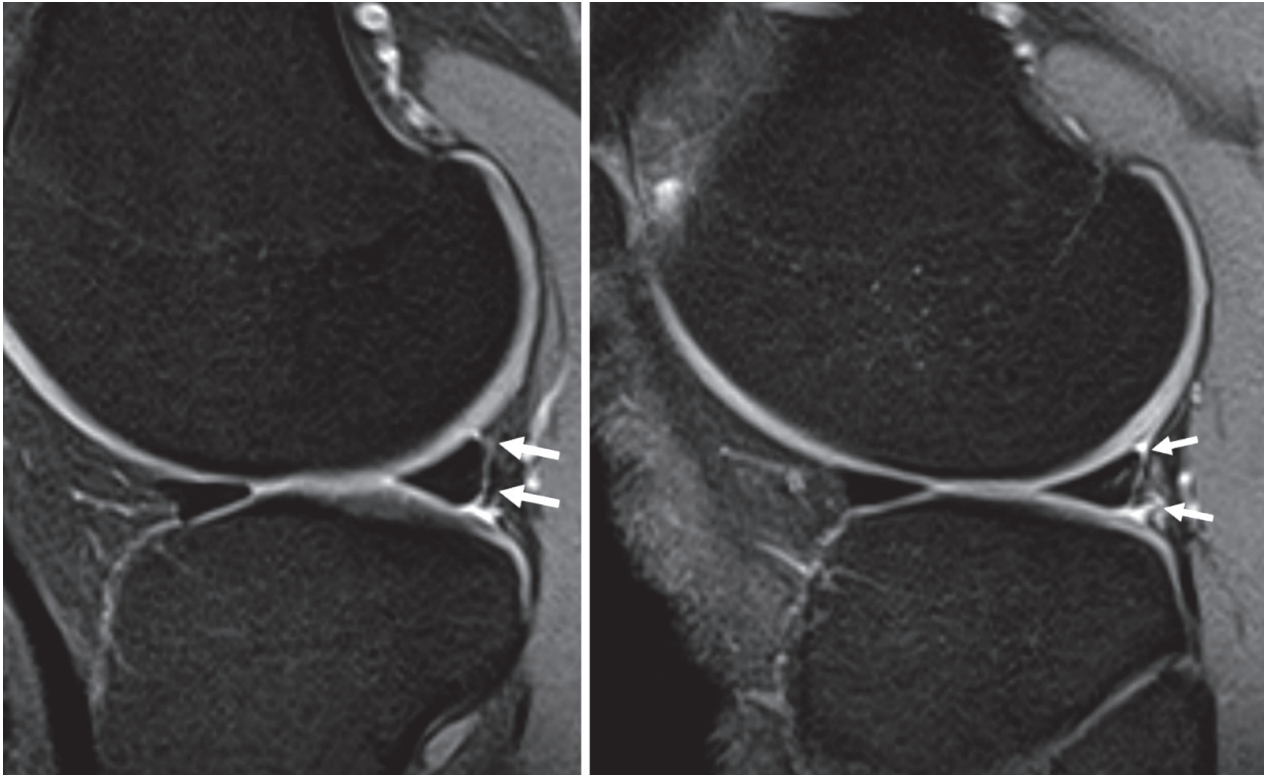


Figure 5. Two MR sagittal PDw fat sat consecutive sequences of Wrisberg variant of lateral meniscus with congenital absence of PMFs (with arrow) but normal C-morphology

the postero-lateral complex (74, 75); the mechanisms of injury may involve a single traumatic event or sub-acute onset after repeated microtraumas (2).

Although a popliteo-meniscal fascicle tear often cause vague mechanical symptoms, their tears may be associated with a postero-lateral instability and/or knee snapping sensation due to subluxation of the lateral meniscus (63, 69, 76).

Even if few articles have been published articles on the semiotic signs and diagnostic accuracy of MRI in detection of acute and chronic PMFs injury in non-subluxated meniscus, the absence of the continue linear structures referable to PMFs and a water-signal interposed between the posterior horn of lateral meniscus and joint capsule should be considered pathologic (75, 77) (Fig. 7).

Using the 3D isotropic proton density sequence, Ahn et al found sensitivity and specificity of 58% and 92% for PMF injury (77).

However, the presence of hemarthrosis, which is a common finding in patients with acute tears of the anterior cruciate ligament with particularly related risk of popliteo-meniscal fascicle tears, would be used as contrast media for better depict the anatomical structures (27) (Fig. 8a-b).

Suganuma et al, evaluated 238 knee MRI exams and founded abnormal iPMF in 40% and 26% respectively in healthy group; the percentages of abnormality in contralateral knee of group with recurrent subluxation of the lateral meniscus (RSLM) were 100% and 29% respectively while in knee joint with RSLM were 100% and 100%. They finally stated that a significantly high incidence of abnormal sPMFs was found not only in RSLM joint but also in contralateral knees (44).

When the popliteo-meniscal fascicles are disrupted, the normal peripheral hoop tension of the lateral meniscus is lost, and consequently the lateral meniscus could be displaced medially into the joint (78) (Fig. 9).

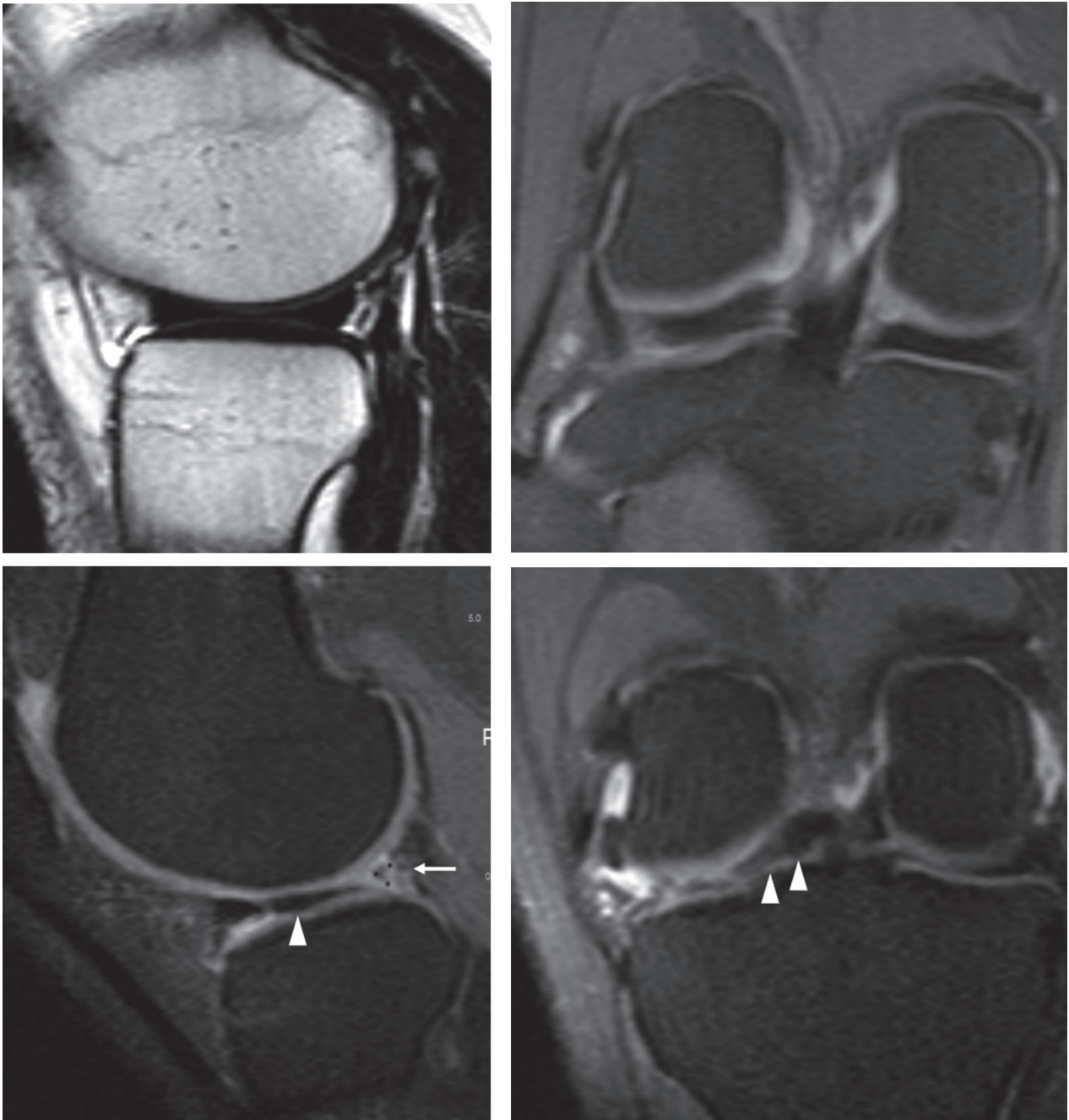


Figure 6 a-d. MR sagittal T2w (a) and coronal PDw fat sat (b) sequences of Wrisberg variant of lateral meniscus with knee in routine position show the normal position of the meniscus. After a movement that has locked the knee, the MR sagittal PDw fat sat (c) and coronal PDw fat sat (d) sequences show the antero-medial dislocation of posterior horn of lateral meniscus

Arthroscopy and Treatments

At day, the gold standard for diagnosis is the arthroscopic evaluation that allows the direct visualiza-

tion of the popliteo-meniscal ligaments at popliteal hiatus and evaluation of lateral meniscal movements (2). For this reason if unstable condition of meniscus was suspected, arthroscopic observation with probing

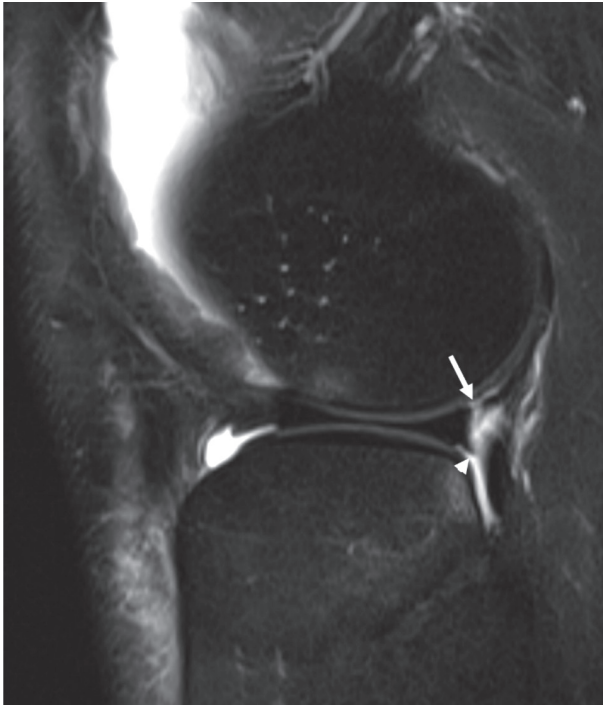


Figure 7. MR sagittal PDw fat sat sequences of postero-superior (arrow) and postero-inferior (arrowhead) PMFs tear

into the popliteo-meniscal fascicle area is essential for the identification of the fascicle tears (79).

In case of PMFs tears, in symptomatic patients, surgery represents the treatment of choice (80). Some different treatments have been reported in literature: meniscectomy, coronary ligament and meniscocapsular repair, and thermal shrinkage of the posterolateral capsule (11, 44, 81). However, 11% to 33% of patients who undergo coronary ligament and meniscocapsular repair or RFE of the posterolateral capsule have high recurrence of knee locking, whereby new surgical techniques are being developed in recent years (76, 82).

Conclusions

Popliteomeniscal fasciculi could be absent or a tear could occur in association with acute anterior cruciate ligament injury and diagnosis is crucial to treat the consequently hypermobility or locking of the meniscus. Even if other studies are required to standardize and validate the semiotic signs, the MRI represents a valid method to help in the PMF abnormalities.

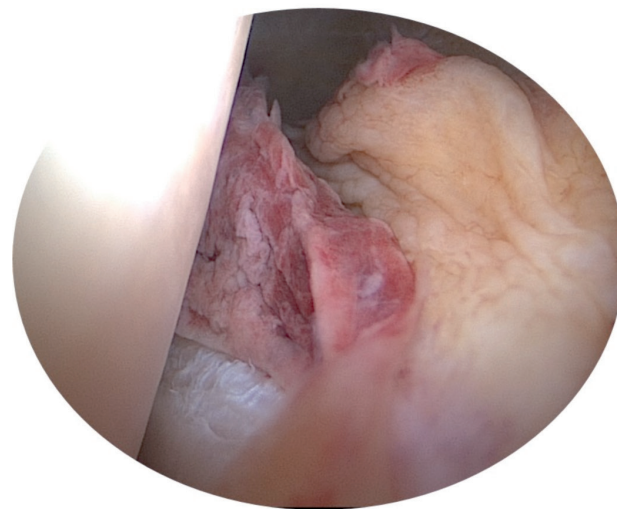
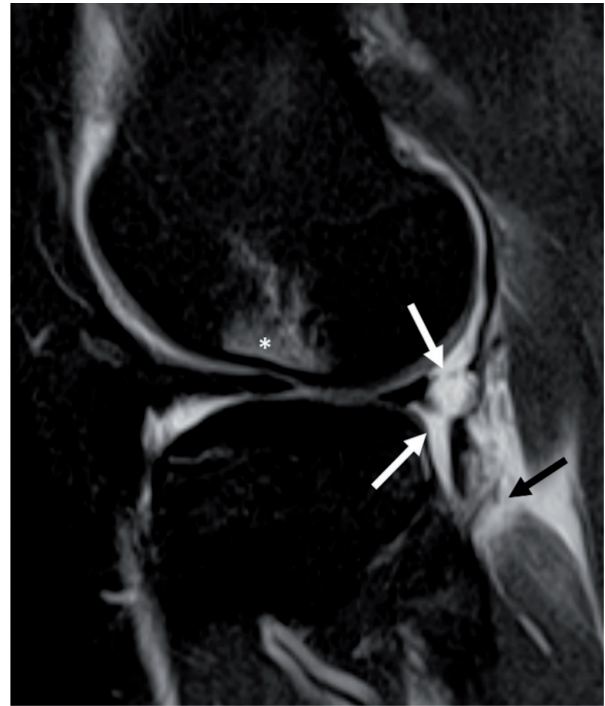


Figure 8 a-b. MR sagittal PDw fat sat sequence (a) and arthroscopy (b) of acute tear of PMFs. The joint effusion help to delineate the lesion of PMFs (white arrows) and lesion of popliteal musculotendinous junction (black arrow)

Despite many treatments have being proposed in literature since now there is high recurrence of knee locking after repair and it is fundamental to develop new surgical techniques in order to achieve better outcome.

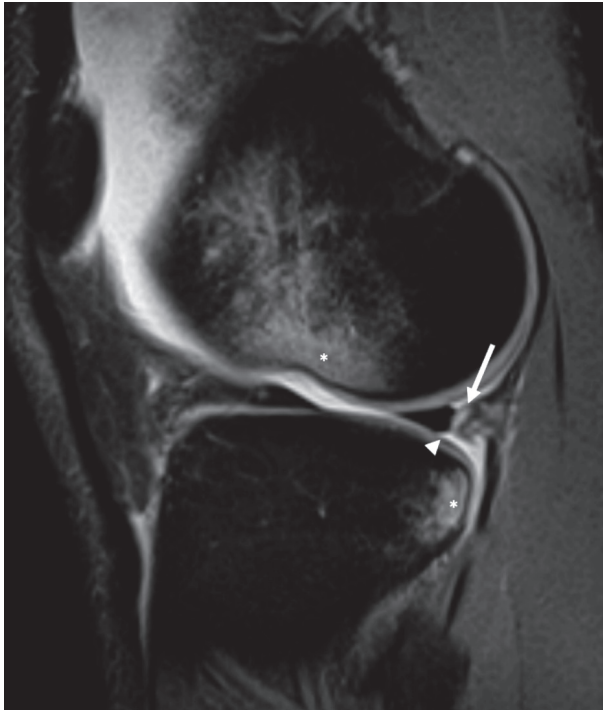


Figure 9. MR sagittal PDw fat sat sequence of acute tear of PMFs (arrow) with little antero-medial displacement of posterior horn of lateral meniscus (arrowhead)

References

1. Cohn AK, Mains DB. Popliteal hiatus of the lateral meniscus Anatomy and measurement at dissection of 10 specimens. *The American journal of sports medicine* 1979; 7: 221-226.
2. Staubli HU, Birrer S. The popliteus tendon and its fascicles at the popliteal hiatus: gross anatomy and functional arthroscopic evaluation with and without anterior cruciate ligament deficiency. *Arthroscopy* 1990; 6: 209-20.
3. De Filippo M, Corsi A, Evaristi L, Bertoldi C, Sverzellati N, Averna R, Crotti P, Bini G, Tamburrini O, Zompatori M, Rossi C. Critical issues in radiology requests and reports. *Radiol Med* 2011; 116: 152-62.
4. De Filippo M, Rovani C, Sudberry JJ, Rossi F, Pogliacomi F, Zompatori M. Magnetic resonance imaging comparison of intra-articular cavernous synovial hemangioma and cystic synovial hyperplasia of the knee. *Acta Radiol* 2006; 47: 581-4.
5. De Filippo M, Pogliacomi F, Bertellini A, Araoz PA, Averna R, Sverzellati N, Ingegnoli A, Corradi M, Costantino C, Zompatori M. MDCT arthrography of the wrist: diagnostic accuracy and indications. *Eur J Radiol* 2010; 74: 221-5.
6. LaPrade RF. Arthroscopic evaluation of the lateral compartment of knees with grade 3 posterolateral knee complex injuries. *The American journal of sports medicine* 1997; 25: 596-602.
7. De Filippo M, Bertellini A, Sverzellati N, Pogliacomi F, Costantino C, Vitale M, Zappia M, Corradi D, Garlaschi G, Zompatori M. Multidetector computed tomography arthrography of the shoulder: diagnostic accuracy and indications. *Acta Radiol* 2008; 49: 540-9.
8. Pinto F, Miele V, Scaglione M, Pinto A. The use of contrast-enhanced ultrasound in blunt abdominal trauma: Advantages and limitations. *Acta Radiol* 2014; 55: 776-784.
9. Miele V, Di Giampietro I. Diagnostic imaging in emergency. *Salute Soc* 2014; 127-141.
10. Miele V, Di Giampietro I, Ianniello S, Pinto F, Trinci M. Diagnostic imaging in pediatric polytrauma management. *Radiol Med* 2014; 120: 33-49.
11. Simonian PT, Sussmann PS, van Trommel M, Wickiewicz TL, Warren RF. Popliteomeniscal fasciculi and lateral meniscal stability. *The American journal of sports medicine* 1997; 25: 849-853.
12. Yue BW, Gupta AK, Moorman CT, 3rd, Garrett WE, Helms CA. Wrisberg variant of the discoid lateral meniscus with flipped meniscal fragments simulating bucket-handle tear: MRI and arthroscopic correlation. *Skeletal Radiol* 2011; 40: 1089-94.
13. Grassi R, Lombardi G, Reginelli A, Capasso F, Romano F, Floriani I, Colacurci N. Coccygeal movement: assessment with dynamic MRI. *Eur J Radiol* 2007; 61: 473-9.
14. Pinto A, Pinto F, Faggian A, Rubino G, Caranci F, Macarini L, Genovese EA, Brunese L. Sources of error in emergency ultrasonography. *Critical Ultrasound Journal* 2013; 5 (suppl.1): 1-5.
15. Reginelli A, Zappia M, Barile A, Brunese L. Strategies of imaging after orthopedic surgery. *Musculoskeletal Surg* 2017; 101:
16. LaPrade RF. Arthroscopic evaluation of the lateral compartment of knees with grade 3 posterolateral knee complex injuries. *Am J Sports Med* 1997; 25: 596-602.
17. Nurzynska D, DiMeglio F, Castaldo C, Latino F, Romano V, Miraglia R, Guerra G, Brunese L, Montagnani S. Flat-foot in children: Anatomy of decision making. *Ital J Anat Embryol*. 2012; 117: 98-106.
18. Pinto A, Brunese L, Pinto F, Reali R, Daniele S, Romano L. The Concept of Error and Malpractice in Radiology. *Semin. Ultrasound CT MRI* 2012; 33: 275-279.
19. Cappabianca S, Colella G, Pezzullo MG, Russo A, Iaselli F, Brunese L, Rotondo A. Lipomatous lesions of the head and neck region: Imaging findings in comparison with histological type. *Radiol Med* 2008; 113: 758-770.
20. Jadhav SP, More SR, Riascos RF, Lemos DF, Swischuk LE. Comprehensive review of the anatomy, function, and imaging of the popliteus and associated pathologic conditions. *Radiographics* 2014; 34: 496-513.
21. Zappia M, Castagna A, Barile A, Chianca V, Brunese L, Pouliart N. Imaging of the coracoglenoid ligament: a third ligament in the rotator interval of the shoulder. *Skelet Radiol* 2017; 46: 1101-1111.
22. Zappia M, Carfora M, Romano AM, Reginelli A, Brunese L, Rotondo A, Castagna A. Sonography of chondral print on humeral head. *Skelet Radiol* 2016; 45: 35-40.

23. Cuomo G, Zappia M, Iudici M, Abignano G, Rotondo A, Valentini G. The origin of tendon friction rubs in patients with systemic sclerosis: a sonographic explanation. *Arthritis Rheum* 2012; 64: 1291-3.
24. Zappia M, Cuomo G, Martino MT, Reginelli A, Brunese L. The effect of foot position on Power Doppler Ultrasound grading of Achilles enthesitis. *Rheumatol Int* 2016; 36: 871-874.
25. Russo A, Capasso R, Varelli C, Laporta A, Carbone M, D'Agosto G, Giovine S, Zappia M, Reginelli A. MR imaging evaluation of the postoperative meniscus. *Musculoskelet Surg* 2017; 101: 37-42.
26. Diamantopoulos A, Tokis A, Tzurbakis M, Patsopoulos I, Georgoulis A. The posterolateral corner of the knee: evaluation under microsurgical dissection. *Arthroscopy: The Journal of Arthroscopic & Related Surgery* 2005; 21: 826-833.
27. Sakai H, Sasho T, Wada Y-i, Sano S, Iwasaki J-i, Morita F, Moriya H. MRI of the popliteomeniscal fasciculi. *American Journal of Roentgenology* 2006; 186: 460-466.
28. Filippou G, Adinolfi A, Cimmino MA, Scire CA, Carta S, Lorenzini S, Santoro P, Sconfienza LM, Bertoldi I, Picerno V, Di Sabatino V, Ferrata P, Galeazzi M, Frediani B. Diagnostic accuracy of ultrasound, conventional radiography and synovial fluid analysis in the diagnosis of calcium pyrophosphate dihydrate crystal deposition disease. *Clin Exp Rheumatol* 2016; 34: 254-60.
29. Ferrero G, Fabbro E, Orlandi D, Martini C, Lacelli F, Serafini G, Silvestri E, Sconfienza LM. Ultrasound-guided injection of platelet-rich plasma in chronic Achilles and patellar tendinopathy. *J Ultrasound* 2012; 15: 260-6.
30. Klauser AS, Tagliafico A, Allen GM, Boutry N, Campbell R, Court-Payen M, Grainger A, Guerini H, McNally E, O'Connor PJ, Ostlere S, Petroons P, Reijnierse M, Sconfienza LM, Silvestri E, Wilson DJ, Martinoli C. Clinical indications for musculoskeletal ultrasound: a Delphi-based consensus paper of the European Society of Musculoskeletal Radiology. *Eur Radiol* 2012; 22: 1140-8.
31. Peduto AJ, Nguyen A, Trudell DJ, Resnick DL. Popliteomeniscal fascicles: anatomic considerations using MR arthrography in cadavers. *American Journal of Roentgenology* 2008; 190: 442-448.
32. Aliprandi A, Sconfienza LM, Randelli P, Bandirali M, Tritella S, Di Leo G, Sardanelli F. Magnetic resonance imaging of the knee after medial unicompartmental arthroplasty. *Eur J Radiol* 2011; 80: e416-21.
33. Cappabianca S, Iaselli F, Negro A, Basile A, Reginelli A, Grassi R, Rotondo A. Magnetic resonance imaging in the evaluation of anatomical risk factors for pediatric obstructive sleep apnoea-hypopnoea: a pilot study. *Int J Pediatr Otorhinolaryngol* 2013; 77: 69-75.
34. Valentini G, Marcoccia A, Cuomo G, Vettori S, Iudici M, Bondanini F, Santoriello C, Ciani A, Cozzolino D, De Matteis GM, Cappabianca S, Vitelli F, Spano A. Early systemic sclerosis: analysis of the disease course in patients with marker autoantibody and/or capillaroscopic positivity. *Arthritis Care Res (Hoboken)* 2014; 66: 1520-7.
35. Cappabianca S, Colella G, Russo A, Pezzullo M, Reginelli A, Iaselli F, Rotondo A. Maxillofacial fibrous dysplasia: personal experience with gadolinium-enhanced magnetic resonance imaging. *Radiol Med* 2008; 113: 1198-210.
36. Sussmann PS, Simonian PT, Wickiewicz TL, Warren RF. Development of the popliteomeniscal fasciculi in the fetal human knee joint. *Arthroscopy* 2001; 17: 14-8.
37. Terry GC, LaPrade RF. The posterolateral aspect of the knee: anatomy and surgical approach. *The American Journal of Sports Medicine* 1996; 24: 732-739.
38. LaPrade RF, Konowalchuk BK. Popliteomeniscal Fascicle Tears Causing Symptomatic Lateral Compartment Knee Pain Diagnosis by the Figure-4 Test and Treatment by Open Repair. *The American journal of sports medicine* 2005; 33: 1231-1236.
39. Briganti F, Delehaye L, Leone G, Sicignano C, Buono G, Marseglia M, Caranci F, Tortora F, Maiuri F. Flow diverter device for the treatment of small middle cerebral artery aneurysms. *J Neurointervent Surg* 2016; 8: 287-294.
40. Caranci F, Briganti F, La Porta M, Antinolfi G, Cesarano E, Fonio P, Brunese L, Coppolino F. Magnetic resonance imaging in brachial plexus injury. *Musculoskelet Surg* 2013; 97 (suppl 2): S181-S190.
41. Di Zazzo E, Porcile C, Bartollino S, Monchamont B. Critical Function of PRDM2 in the Neoplastic Growth of Testicular Germ Cell Tumors. *Biology (Basel)* 2016; 5:
42. Mangano K, Vergalito F, Mammana S, Mariano A, De Pasquale R, Meloscia A, Bartollino S, Guerra G, Nicoletti F, Di Marco R. Evaluation of hyaluronic acid-P40 conjugated cream in a mouse model of dermatitis induced by oxazolone. *Exp Ther Med* 2017; 14: 2439-2444.
43. Potenza DM, Guerra G, Avanzato D, Poletto V, Pareek S, Guido D, Gallanti A, Rosti V, Munaron L, Tanzi F, Moccia F. Hydrogen sulphide triggers VEGF-induced intracellular Ca(2)(+) signals in human endothelial cells but not in their immature progenitors. *Cell Calcium* 2014; 56: 225-34.
44. Saganuma J, Mochizuki R, Inoue Y, Yamabe E, Ueda Y, Kanauchi T. Magnetic resonance imaging and arthroscopic findings of the popliteomeniscal fascicles with and without recurrent subluxation of the lateral meniscus. *Arthroscopy: The Journal of Arthroscopic & Related Surgery* 2012; 28: 507-516.
45. Johnson RL, De Smet AA. MR visualization of the popliteomeniscal fascicles. *Skeletal radiology* 1999; 28: 561-566.
46. Munshi M, Pretterklieber ML, Kwak S, Antonio GE, Trudell DJ, Resnick D. MR imaging, MR arthrography, and specimen correlation of the posterolateral corner of the knee: an anatomic study. *American Journal of Roentgenology* 2003; 180: 1095-1101.
47. Barile A, Arrigoni F, Bruno F, Guglielmi G, Zappia M, Reginelli A, Ruscitti P, Cipriani P, Giacomelli R, Brunese L, Masciocchi C. Computed Tomography and MR Imaging in Rheumatoid Arthritis. *Radiol Clin North Am* 2017;
48. Di Pietto F, Chianca V, de Ritis R, Cesarano E, Reginelli A, Barile A, Zappia M, Ginolfi L. Postoperative imaging in arthroscopic hip surgery. *Musculoskeletal Surg* 2017; 101: 43-49.

49. de Filippo M, Azzali E, Pesce A, Saba L, Mostardi M, Borgia D, Barile A, Capasso R, de Palmi F, Caravaggio F. CT arthrography for evaluation of autologous chondrocyte and chondral-inductor scaffold implantation in the osteochondral lesions of the talus. *Acta Biomedica* 2016; 87: 51-56.
50. Mariani S, La Marra A, Arrigoni F, Necozone S, Splendiani A, Di Cesare E, Barile A, Masciocchi C. Dynamic measurement of patello-femoral joint alignment using weight-bearing magnetic resonance imaging (WB-MRI). *Eur J Radiol* 2015; 84: 2571-2578.
51. Barile A, Conti L, Lanni G, Calvisi V, Masciocchi C. Evaluation of medial meniscus tears and meniscal stability: Weight-bearing MRI vs arthroscopy. *Eur J Radiol* 2013; 82: 633-639.
52. Masciocchi C, Lanni G, Conti L, Conchiglia A, Fascetti E, Flamini S, Coletti G, Barile A. Soft-tissue inflammatory myofibroblastic tumors (IMTs) of the limbs: Potential and limits of diagnostic imaging. *Skelet Radiol* 2012; 41: 643-649.
53. Masciocchi C, Conti L, D'Orazio F, Conchiglia A, Lanni G, Barile A. Errors in musculoskeletal MRI, Errors in Radiology, Springer-Verlag Milan 2012, pp. 209-217.
54. Salvati F, Rossi F, Limbucci N, Pistoia ML, Barile A, Masciocchi C. Mucoid metaplastic-degeneration of anterior cruciate ligament. *J Sports Med Phys Fitness* 2008; 48: 483-487.
55. Barile A, Regis G, Masi R, Maggiori M, Gallo A, Faletti C, Masciocchi C. Musculoskeletal tumours: Preliminary experience with perfusion MRI. *Radiol Med* 2007; 112: 550-561.
56. Ripani M, Continenza MA, Cacchio A, Barile A, Parisi A, De Paulis F. The ischiatic region: normal and MRI anatomy. *J Sports Med Phys Fitness* 2006; 46: 468-75.
57. Masciocchi C, Barile A, Lelli S, Calvisi V. Magnetic resonance imaging (MRI) and arthro-MRI in the evaluation of the chondral pathology of the knee joint. *Radiol Med* 2004; 108: 149-58.
58. Barile A, Sabatini M, Iannesi F, Di Cesare E, Splendiani A, Calvisi V, Masciocchi C. Pigmented villonodular synovitis (PVNS) of the knee joint: magnetic resonance imaging (MRI) using standard and dynamic paramagnetic contrast media. Report of 52 cases surgically and histologically controlled. *Radiol Med* 2004; 107: 356-66.
59. Watanabe M, Takeda S. Arthroscopy of the knee joint. Disorders of the knee. Lippincott, Philadelphia 1974; 45:
60. Kim Y-G, Ihn J-C, Park S-K, Kyung H-S. An arthroscopic analysis of lateral meniscal variants and a comparison with MRI findings. *Knee Surgery, Sports Traumatology, Arthroscopy* 2006; 14: 20-26.
61. Simonian PT, Sussmann PS, Wickiewicz TL, Potter HG, van Trommel M, Weiland-Holland S, Warren RF. Popliteomeniscal fasciculi and the unstable lateral meniscus: clinical correlation and magnetic resonance diagnosis. *Arthroscopy: The Journal of Arthroscopic & Related Surgery* 1997; 13: 590-596.
62. Moser MW, Dugas J, Hartzell J, Thornton DD. Case Report: A Hypermobile Wrisberg Variant Lateral Discoid Meniscus Seen on MRI. *Clinical orthopaedics and related research* 2007; 456: 264-267.
63. Park JH, Ro KH, Lee DH. Snapping knee caused by a popliteomeniscal fascicle tear of the lateral meniscus in a professional Taekwondo athlete. *Orthopedics* 2012; 35: e1104-e1107.
64. Garofalo R, Kombot C, Borens O, Djahangiri A, Mouhsine E. Locking knee caused by subluxation of the posterior horn of the lateral meniscus. *Knee Surgery, Sports Traumatology, Arthroscopy* 2005; 13: 569-571.
65. Date H, Hayakawa K, Nakagawa K, Yamada H. Snapping knee due to the biceps femoris tendon treated with repositioning of the anomalous tibial insertion. *Knee Surgery, Sports Traumatology, Arthroscopy* 2012; 20: 1581-1583.
66. Lee D-H, Kim T-H, Kim J-M, Bin S-I. Results of subtotal/total or partial meniscectomy for discoid lateral meniscus in children. *Arthroscopy: The Journal of Arthroscopic & Related Surgery* 2009; 25: 496-503.
67. Bernhardson AS, LaPrade RF. Snapping biceps femoris tendon treated with an anatomic repair. *Knee Surgery, Sports Traumatology, Arthroscopy* 2010; 18: 1110-1112.
68. Guney H, Kaya D, Yilgor C, Cilli M, Aritan S, Yuksel I, Doral MN. Semitendinosus snapping: analysis of movement, electromyographic activities, muscle strength and endurance, motor control and joint position sense. *Muscles, ligaments and tendons journal* 2013; 3: 166.
69. Singh K, Helms CA, Jacobs MT, Higgins LD. MRI appearance of Wrisberg variant of discoid lateral meniscus. *American Journal of Roentgenology* 2006; 187: 384-387.
70. Bikkina RS, Tujo CA, Schraner AB, Major NM. The "floating" meniscus: MRI in knee trauma and implications for surgery. *American Journal of Roentgenology* 2005; 184: 200-204.
71. Kaplan EB. Discoid Lateral Meniscus of the Knee Joint: Nature, Mechanism, and Operative Treatment. *JBJS* 1962; 44: 811.
72. Lyle N, Sampson M, Barrett D. MRI of intermittent meniscal dislocation in the knee. *The British journal of radiology* 2009; 82: 374-379.
73. Sta H-U, Birrer S. The popliteus tendon and its fascicles at the popliteal hiatus: gross anatomy and functional arthroscopic evaluation with and without anterior cruciate ligament deficiency. *Arthroscopy: The Journal of Arthroscopic & Related Surgery* 1990; 6: 209-220.
74. Camarillo M, Johnson DL. Popliteomeniscal fascicle tears. *Orthopedics* 2014; 37: 187-190.
75. Temponi EF, de Carvalho Junior LH, Saithna A, Thaunat M, Sonnery-Cottet B. Incidence and MRI characterization of the spectrum of posterolateral corner injuries occurring in association with ACL rupture. *Skeletal Radiol* 2017;
76. Ohtoshi K, Kimura M, Kobayashi Y, Higuchi H, Kikuchi S. Arthroscopic thermal shrinkage for hypermobile lateral meniscus. *The American journal of sports medicine* 2004; 32: 1297-1301.
77. Ahn SJ, Jeong YM, Lee BG, Sim JA, Choi HY, Kim JH,

- Lee SW. Using three-dimensional isotropic SPACE MRI to detect posterolateral corner injury of the knee. *Acta radiologica* (Stockholm, Sweden: 1987) 2016; 57: 1251-60.
78. Kimura M, Shirakura K, Hasegawa A, Kobayashi Y, Udagawa E. Anatomy and pathophysiology of the popliteal tendon area in the lateral meniscus: 2. Clinical investigation. *Arthroscopy: The Journal of Arthroscopic & Related Surgery* 1992; 8: 424-427.
79. Shin H-K, Lee H-S, Lee Y-K, Bae K-C, Cho C-H, Lee K-J. Popliteomeniscal fascicle tear: diagnosis and operative technique. *Arthroscopy Techniques* 2012; 1: e101-e106.
80. George M, Wall EJ. Locked knee caused by meniscal subluxation: magnetic resonance imaging and arthroscopic verification. *Arthroscopy: The Journal of Arthroscopic & Related Surgery* 2003; 19: 885-888.
81. Higuchi H, Kimura M, Kobayashi A, Hatayama K, Takagishi K. A novel treatment of hypermobile lateral meniscus with monopolar radiofrequency energy. *Arthroscopy: The Journal of Arthroscopic & Related Surgery* 2004; 20: 1-5.
82. Suganuma J, Inoue Y, Tani H, Sugiki T, Sassa T, Shibata R. Reconstruction of the Popliteomeniscal Fascicles for Treatment of Recurrent Subluxation of the Lateral Meniscus. *Arthroscopy techniques* 2017; 6: e283-e290.

Received: 15 September 2017

Accepted: 20 December 2017

Correspondence:

Marcello Zappia, MD, PhD,

Department of Medicine and Health Science "V. Tiberio",

University of Molise, Campobasso, Italy

E-mail: marcellozappia1@tin.it