

Zollinger-Ellison syndrome: Revelation of the gastrinoma triangle

Rong-Hsin Yang, MD, and Yum-Kung Chu, MD

Zollinger-Ellison syndrome is a complex condition in which one or more tumors form in the patient's pancreas or upper duodenum. These tumors, called gastrinomas, secrete excessive amounts of gastrin, and almost all develop ulcers. The vast majority of gastrinomas are present within the "gastrinoma triangle," which is composed of the porta hepatis, duodenal sweep, and pancreatic head. As surgery remains the treatment of choice, localization of the primary lesion is often challenging but essential. We present a 50-year-old man with a tentative diagnosis of Zollinger-Ellison syndrome. His In-111 pentetate scan, fused onto a Tc-99m abdomen image, revealed an avid lesion adjacent to the duodenal loop. Operative resection was performed, and a primary pancreatic gastrinoma was diagnosed by immunohistochemical staining. The neuroendocrine tumors have somatostatin receptors upon them. Therefore, a pentetate scan, using In-111 radiolabelled somatostatin analogues, is the current technique of choice. This dual-isotope display permits a visual perception of anatomic landmarks around the lesion.

Introduction

Zollinger-Ellison syndrome is a rare disorder caused by a tumor called a gastrinoma. The tumor secretes the hormone gastrin, which causes excess production of gastric acid, leading to severe recurrent ulcers of the esophagus, stomach, duodenum, and jejunum. The rarity of the syndrome may render the diagnosis difficult to make, especially since most radiologists are not aware of this entity. About 85% to 90% of gastrinomas are present within the "gastrinoma triangle." When the Zollinger-Ellison syndrome is suspected, physicians have to try to identify the tumor in the pancreas or the bowel. An In-111 pentetate scan is the current technique of choice. However, even using the

technique of SPECT/CT, the location may be missed or masked by peripheral anatomic structures in the gastrinoma triangle. We hope to raise awareness of the disease and of a dual-isotope display as the method to identify the gastrinoma in the gastrinoma triangle.

Case report

A 50-year-old man was admitted because of abdominal cramps, vomiting, and watery diarrhea with up to 10 bowel movements. His medical history included 10 years of peptic ulcer disease, abdominal pain, and diarrhea, leading to a presumptive diagnosis of irritable bowel disease. A year earlier, he had an episode of upper gastrointestinal bleeding. For the prevention of relapsing peptic ulcer, he had been taking Nexium® (esomeprazole, a proton-pump inhibitor) thereafter. Esophagogastroduodenal endoscopy (performed for investigation of the gastric symptoms) revealed diffuse erosive esophagitis and duodenal ulcer, and absence of *Helicobacter pylori* infection. Colonoscopy was reported as normal. A gallium-67 scan, made for a tumor survey, failed to exhibit active lesions. His baseline gastrin levels were measured at 900 pg/mL, with an increase to more than 1200 pg/mL after an IV secretin test. Further laboratory evaluation excluded multiple endocrine neoplasia type 1 syndrome.

Citation: Yang RH, Chu YK. Zollinger-Ellison syndrome: Revelation of the gastrinoma triangle. *Radiology Case Reports*. (Online) 2015;10(1):827.

Copyright: © 2015 The Authors. This is an open-access article distributed under the terms of the Creative Commons Attribution-NonCommercial-NoDerivs 2.5 License, which permits reproduction and distribution, provided the original work is properly cited. Commercial use and derivative works are not permitted.

The authors are all in the Department of Nuclear Medicine, Taipei Veterans General Hospital and National Yang-Ming University School of Medicine, Taipei, Taiwan. Contact Dr. Chu at ykchu@vghtpe.gov.tw.

Competing Interests: The authors have declared that no competing interests exist.

DOI: 10.2484/rcr.v10i1.827

Zollinger-Ellison syndrome: Revelation of the gastrinoma triangle

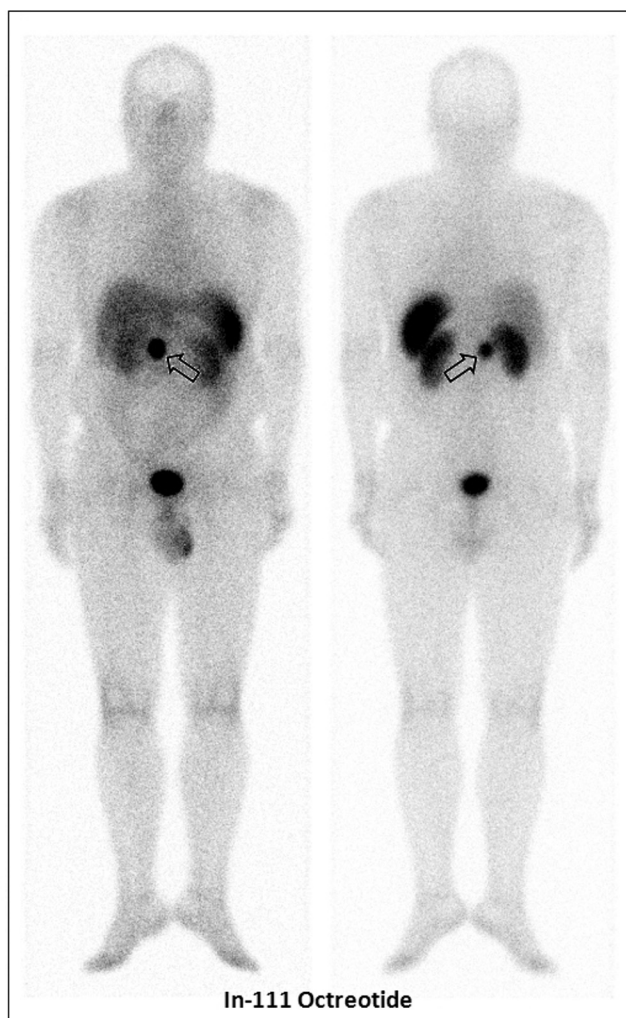


Figure 1. An In-111 pentetretotide scan showed an avid focus at the epigastrium (open arrow), besides physiologic uptake in the kidneys and the spleen.

A further approach to investigating the etiology of the hypergastrinemia (an In-111 pentetretotide scan) showed an avid focus at the epigastrium (Fig. 1, open arrow), besides physiologic uptake in the kidneys and the spleen. For ease of lesion mapping, the patient was asked to drink a mouthful of water with Tc-99m pertechnetate added. Dual-isotope planar images were acquired simultaneously, centering on the two In-111 photopeaks (170 & 245 keV) and on the Tc-99m photopeak (140-keV). The Tc-99m abdomen images were displayed to be the background maps (Fig. 2, A & B). The In-111 image was superimposed onto a Tc-99m image (Fig. 2, C & D), which showed that the pathologic focus was next to the duodenum and inside the gastrinoma triangle (1). Subsequent CT revealed a 2.7×2.4-cm, lobulated, enhancing lesion at the pancreas head (Fig. 3). Operative resection was performed. Pathological examination revealed a gastrin-producing neuroendocrine tumor. The

tumor cells were immunoreactive with chromogranin-A, synaptophysin, and gastrin. The patient's serum gastrin level returned to normal (60 pg/ml) at 6-week followup, consistent with a surgical cure of Zollinger-Ellison syndrome.

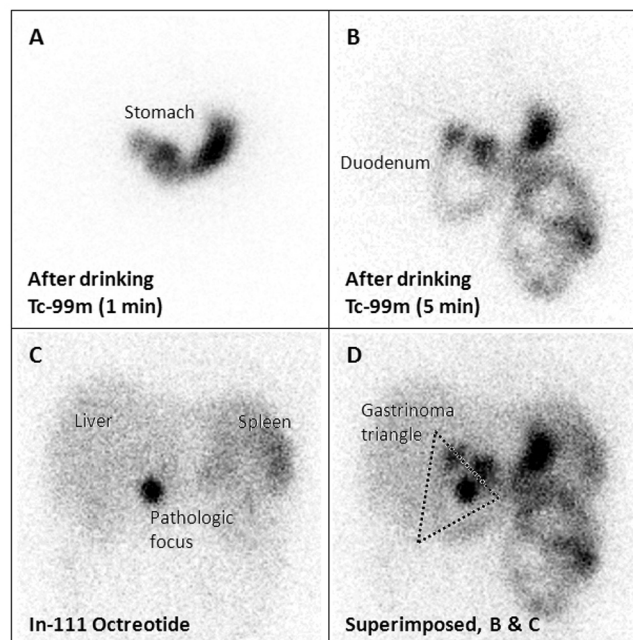


Figure 2. Pentetreotide imaging plus abdomen scintigrams. The patient was asked to drink a mouthful of water with Tc-99m pertechnetate added. Dual-isotope planar images were acquired simultaneously, centering on the In-111 photopeaks and on the Tc-99m photopeak. The Tc-99m abdomen images were displayed to be the background maps (A and B). The In-111 image was superimposed onto a Tc-99m image (C and D), which showed that the pathologic focus was next to the duodenum and inside the gastrinoma triangle.

Discussion

Gastrinomas are an integral part of the Zollinger-Ellison syndrome (1, 2). The tumors produce large amounts of gastrin, triggering gastric acid hypersecretion, refractory peptic ulcers, and diarrhea. Recent data suggest that 65% of gastrinomas are malignant, and up to 30% to 40% of patients will have evident metastatic disease at initial presentation (3-5), requiring accurate preoperative localization of the tumor (6). Gastrinomas are postulated to originate from stem cells of the ventral pancreatic bud (7), as a result of aberration of neuroendocrine cells during normal embryonic rotation of the ventral pancreas (7, 8). Consequently, 85% to 90% of gastrinomas lie within the gastrinoma triangle (9), comprising the porta hepatis, duodenal sweep, and pancreatic head (Fig. 3).

Zollinger-Ellison syndrome: Revelation of the gastrinoma triangle

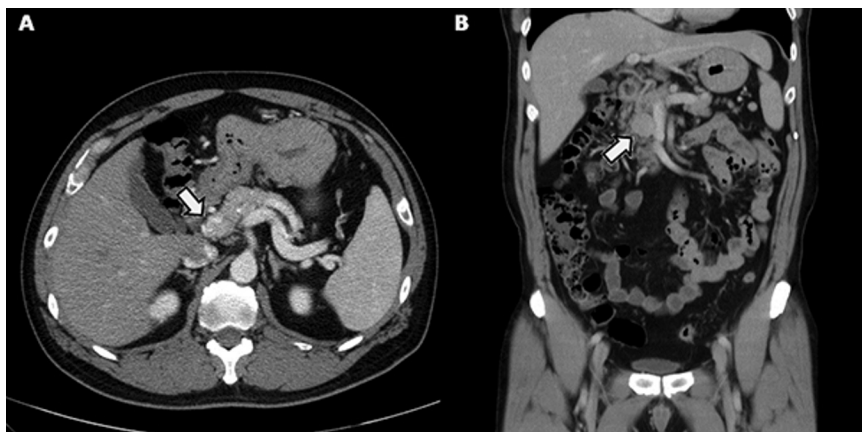


Figure 3. Abdomen CT axial (A) and coronal (B) images showing a 2.7×2.4-cm, lobulated, enhancing lesion at the pancreas head (open arrow).

Functioning neuroendocrine tumors are characterized by presenting symptoms and signs in their early stages, while the lesions are small. Precise localization of small foci is difficult. Somatostatin receptors are found on 80% of gastrinomas. Therefore, a pentetretotide scan, which uses an analog of somatostatin, has successfully localized these neoplasms (primary or nodal metastases) in up to 78% to 86% of cases (10-12). Gibril et al. studied 80 patients and found that CT, MRI, or angiography identified extrahepatic gastrinomas in 28% to 31% of patients, and ultrasound detected extrahepatic tumors in 9% of patients (13). The role of pentetretotide scan is not just for localization of primary lesions, but also for screening of metastases, and monitoring therapeutic response (13).

In the current era of multimodality imaging, SPECT/CT plays an important role in localizing small lesions. One major drawback of SPECT/CT imaging is additive ionizing radiation from the CT procedure. The estimated radiation dose of CT from SPECT/CT is variable because of the many factors involved. Briefly, for one SPECT bed position, the effective dose to the chest and abdomen is around 4 mSv. In case of a CT for a two-bed SPECT/CT, the appropriate effective dose values are added together (14). Besides, the artifacts caused by any movement of the patient or bowel movement would reduce the sensitivity, especially for small pancreatic tumors. Combining Tc-99m MDP and In-111 pentetretotide studies into a single display, which showed more information, has previously been suggested (15). Similarly, our technique does not increase time consumption or significant radiation delivered to the patient, and can be easily implemented on any nuclear medicine workstation with minimal data acquisition. It is a rather straightforward display that permits a visual perception of anatomic landmarks around the lesion.

References

1. Zollinger RM, Ellison EH. Primary peptic ulceration of the jejunum associated with islet cell tumours of the pancreas. *Ann Surg*. 1955 Oct;142(4): 709-23. [PubMed]
2. Stabile BE. Gastrinoma before Zollinger and Ellison. *Am J Surg*. 1997 Sep;174(3):232-6. [PubMed]
3. Creutzfeldt W, Arnold R, Creutzfeldt C, Track NS. Pathomorphologic, biochemical and diagnostic aspects of gastrinomas (Zollinger-Ellison syndrome). *Hum Pathol*. 1975 Jan ;6(1):47-76. [PubMed]
4. Norton JA, Fraker DL, Alexander HR, et al. Surgery increases survival in patients with gastrinoma. *Ann Surg* 2006 Sep; 244(3):410-19. [PubMed]
5. Norton JA, Jensen RT. Role of surgery in Zollinger-Ellison syndrome. *J Am Coll Surg* 2007 Oct;205(4 Suppl):S34-S37. [PubMed]
6. Modlin IM, Lawton GP. Duodenal gastrinoma: the solution to the pancreatic paradox (editorial). *J Clin Gastroenterol*. 1994 Oct;19(3):184-8. [PubMed]
7. Passaro E, Jr, Howard TJ, Sawicki MP, Watt PC, Stabile BE. The origin of sporadic gastrinomas within the gastrinoma triangle: a theory. *Arch Surg*. 1998 Jan; 133(1): 13-17. [PubMed]
8. Herrmann ME, Ciesla MC, Chefec G, DeJong SA, Yong SL. Primary nodal gastrinomas. *Arch Pathol Lab Med*. 2000 Jun;124(6): 832-5. [PubMed]
9. Stabile BE, Morrow DJ, Passaro E, Jr. The gastrinoma triangle: operative implications. *Am J Surg*. 1984 Jan; 147(1): 25-31. [PubMed]
10. McInerney GF, Carmalt H, MaGee M, Allman K, van der Wall H. Detection of multiple hepatic metastases of gastrinoma not apparent on CT by In-111 octreotide scintigraphy. *Clin Nucl Med*. 1996 Sep;21(9):730-1. [PubMed]
11. Kisker O, Bartsch D, Weinel RJ, et al. The value of somatostatin-receptor scintigraphy in newly diagnosed endocrine gastroenteropancreatic tumors. *J Am Coll Surg* 1997 May; 184(5):487-92. [PubMed]

Zollinger-Ellison syndrome: Revelation of the gastrinoma triangle

12. Gibril F, Reynolds JC, Doppman JL, et al. Somatostatin receptor scintigraphy: its sensitivity compared with that of other imaging methods in detecting primary and metastatic gastrinomas. A prospective study. *Ann Intern Med.* 1996 Jul;125(1):26–34. [\[PubMed\]](#)
13. Gibril F, Jense RT. Comparative analysis of diagnostic techniques for localization of gastrointestinal neuroendocrine tumors. *Yale J Biol Med.* 1997 Sep-Dec;70(5-6): 509-22. [\[PubMed\]](#)
14. International Atomic Energy Agency (IAEA). Clinical Applications of SPECT/CT: New Hybrid Nuclear Medicine Imaging System. IAEA TECDOC-1597; 2008. ISBN, 6612775319 (ebk).
15. Le Duc-Pennec A, Thol C, Cavarec M, et al. Octreotide imaging plus bone scintigrams to optimally localize gastroenteropancreatic neuroendocrine tumors. *Clin Nucl Med* 2003 Jan;28(1):5-8. [\[PubMed\]](#)