

Adenomatoid odontogenic tumor with dentigerous cyst: Report of a rare case with review of literature

VIKRAMJEET SINGH, SUNDER GOYAL, SOHEYL SHEIKH¹, P. SHAMBULINGAPPA¹, BALWINDER SINGH¹, RAVINDER SINGH¹

Abstract

Adenomatoid odontogenic tumor (AOT) is a benign lesion derived from the complex system of dental lamina or its remnant. It is categorized into three variants (follicular, extrafollicular, and peripheral). We present a rare case of AOT arising from a dentigerous cyst around the unerupted canine in a 28-year-old female. We believe that this case is an odontogenic cyst with neoplastic development, containing both epithelial and mesenchymal components. As more cases accumulate, we will be able to study these rare lesions further whether the AOTs derived from an odontogenic cyst could represent a distinct “hybrid” variant separate to the three variants described thus far.

Keywords: Adenomatoid odontogenic tumor, dentigerous cyst, hybrid

Introduction

Adenomatoid odontogenic tumor (AOT) is an uncommon benign epithelial lesion of odontogenic origin. It was first described by Dreibaldt in 1907 as pseudoameloameloblastoma.^[1] But Staphne in 1948 first recognized this as a distinct pathological entity.^[2]

AOT constitutes about 2–3% of all odontogenic tumors.^[2,3] Philipsen *et al.* subdivided this condition into three groups referred to as follicular, extrafollicular, and peripheral.^[4] These variants have common histologic characteristics, which indicate a common origin, this being derived from the complex system of dental lamina or its remnants. The follicular and extrafollicular variants account for 96% of all AOT and 71% of these are follicular variant.^[5] The follicular variant is associated with the crown and often part of the root of an impacted or unerupted tooth. The majority of the cases, constituting of about 88%, are diagnosed in the second and third decades of life. But a case

of odontogenic cyst with neoplastic development in a 15-year-old male has been reported in the literature.^[6] The incidence is higher in males than in females at the rate of 9:1. This tumor has a predilection for the anterior maxilla.^[2,3]

The tumor may be partly cystic, and in some cases the solid lesion may be present as masses in the wall of a large cyst. The epithelial lining of the odontogenic cyst may transform into an odontogenic neoplasm – like an ameloblastoma or AOT. While most of AOT arises in anterior maxilla, it can rarely also originate in the wall of a dentigerous cyst of the maxillary antrum and very rarely in posterior maxilla with an impacted second molar.^[7,8]

Here we report a case of a large follicular AOT or which could be a possible “hybrid” variant apart from three types already established in the literature. It is associated with a dentigerous cyst in the anterior maxilla in association with an impacted canine. This is a very rare occurrence. It was mistaken for dentigerous cyst both clinically and radiographically.

Case Report

A 28-year-old female reported to the hospital with a chief complaint of a swelling of the right cheek associated with pain since 4 months [Figure 1]. The pain was dull in intensity and intermittent in nature. The patient was moderately built and moderately nourished. There were no signs of pallor, icterus, cyanosis, clubbing, and koilonychias. All her vital signs were within normal limits. On inspection, the swelling extended medio-laterally from the lateral wall of the nose to 2 cm in front of the ear and supero-inferiorly from the infra-orbital margin to the corner of mouth. On intraoral examination, there was a firm well-defined swelling extending from the upper right central incisor to the first molar of the same side obliterating the right buccal vestibule. The swelling was nontender. The overlying mucosa was normal in color. The right maxillary canine was missing. A lymph node was palpated in the right submandibular region. None

Department of General Surgery, M.M. Institute of Medical Sciences and Research, ¹Oral Medicine and Radiology, M.M. College of Dental Sciences and Research, Mullana, Ambala, Haryana, India

Correspondence: Dr. Sunder Goyal, Department of General Surgery, M.M. Institute of Medical Sciences and Research, Mullana, Ambala, Haryana, India.
E-mail: dr.balwindersingh@rediffmail.com

Access this article online	
Quick Response Code: 	Website: www.contempclindent.org
	DOI: 10.4103/0976-237X.101106

of the teeth were tender on percussion. Electric pulp vitality testing elicited a positive response. The patient was subjected to radiological examination for this lesion. An intraoral periapical and panoramic radiograph showed an impacted maxillary right canine with an irregular corticated border demarcated radiolucency around the crown.

Because of the irregularity in radiolucency, a computed tomography scan was advised. This showed a large lesion of the right maxillary side measuring 4.9 cm × 3.1 cm in dimension. There was expansion and thinning of the bony sinus wall. The lesion seemed to be pushing the inferior wall of the sinus. An unerupted maxillary canine was seen near the medial wall [Figures 2 and 3].

Diagnostic aspiration was performed and a straw-colored fluid was aspirated.

Upon the basis of the clinical and radiographic findings, a diagnosis of dentigerous cyst was given. The differential diagnosis included AOT and odontogenic keratocyst.

A small bony window was made within the portion of the labial plate that corresponded to the upper right central incisor. The mass was enucleated completely along with the embedded canine. The specimen was subjected for histopathological examination.

The histopathological examination revealed proliferation of fusiform cells, arranged as large islands and solid sheets, with structures similar to ducts, lined by low cylindrical or cubic cells [Figure 4]. In some places, amorphous calcified material was present [Figure 5]. The presence of a cystic lesion coated by a stratified pavement epithelium, formed by few cell layers showing a continuity with the neoplastic foci aforementioned, and a connective fibrous capsule was also seen [Figure 6]. All these findings suggested a follicular type of AOT arising out of a dentigerous cyst.

Discussion

AOT was first recognized as a distinct pathological entity

by Stafne in 1948. There are three variants of AOT based on clinical and radiological features as follows:

- The follicular type which has a central lesion associated with an embedded tooth.
- The extrafollicular type which has a central lesion and no connection with the tooth.
- The peripheral variety.

Both types of central intraosseous tumors produce a corticated radiolucency, sometimes with radiopaque specks. The follicular type is usually initially diagnosed as a dentigerous or follicular cyst. The extrafollicular type usually presents as a unilocular, well-defined radiolucency found between, above or superimposed on the roots of erupted teeth and often resemble a residual, radicular, globulomaxillary or a lateral periodontal cyst. The peripheral type usually presents as a gingival swelling, located palatally or lingually relative to the involved tooth.

It has been reported that some odontogenic cysts occur in association with odontogenic tumors or epithelial lining from the cyst may transform into odontogenic neoplasm like ameloblastoma or AOT.^[9] Because neoplastic and hamartomatous lesions can occur at any stage of odontogenesis, odontogenic tumors with combined features of epithelial and mesenchymal components may arise within the odontogenic cyst.

In this case, adenoameloblastoma and dentigerous cyst were found in the same lesion. Clinical, radiographic, and macroscopic findings in the case were consistent with earlier descriptions of the lesion in the literature. As previously mentioned AOTs are usually solid but are occasionally cystic. Our case was of the cystic variety as its growth was in the walls of the dentigerous cyst.

Very few cases of AOT arising in association with a dentigerous cyst have been described. A systematic search of the English language medical literature results showed only eight such cases in maxilla.^[7] The clinical characteristics of these eight cases and the current case are summarized in Table 1. The common symptom among these nine cases

Table 1: List of cases recorded so far

Reference	Age/sex	Race	Radiographic	Feature	Site
Valderrama	16/F	Phillipino	Unilocular radiolucency	Tooth 14 crown surrounded	Maxilla
Walter <i>et al.</i>	8/M	Nigerian	Unilocular radiolucency	Tooth 13 crown surrounded	Maxilla sinus
Tajima <i>et al.</i>	15/M	Japanese	Radiopaque mass	Unerupted 28	Maxilla
Garcia <i>et al.</i>	12/M	Spanish	Unilocular radiolucency	Tooth 23 crown surrounded	Maxilla
Takahashi <i>et al.</i>	22/M	Japanese	Unilocular radiolucency	Tooth 28 crown surrounded	Maxilla
Bravo <i>et al.</i>	14/M	Not stated	Unilocular radiolucency	Tooth 23 crown surrounded	Maxilla
Chen <i>et al.</i>	18/M	Chinese	Unilocular radiolucency	Tooth 23 crown surrounded	Maxilla
Sandhu <i>et al.</i>	25/F	Indian	Unilocular radiolucency	Tooth 13 crown surrounded	Maxilla sinus
Our case	28/F	Indian	Unilocular radiolucency	Tooth 13	Maxilla

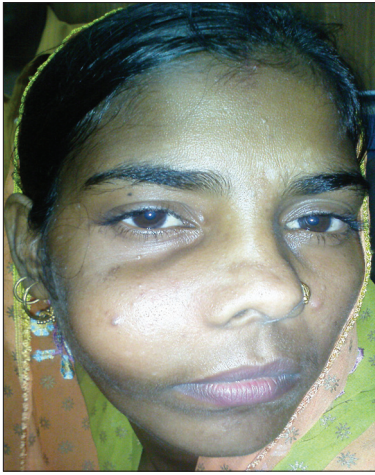

Figure 1: Showing swelling of the right cheek

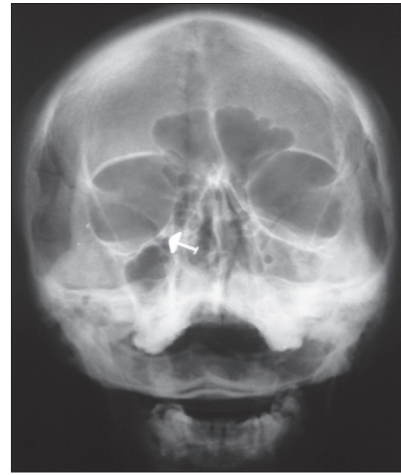

Figure 2: PNS view showing lesion extension

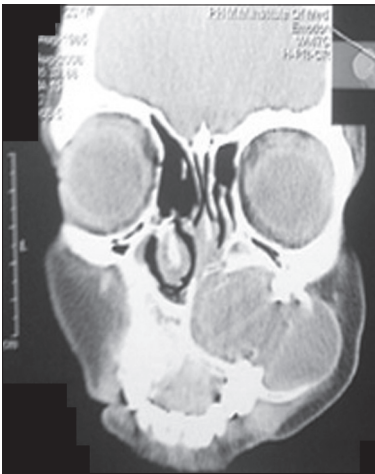

Figure 3: CT scan showing lesion pushing the inferior wall of the sinus

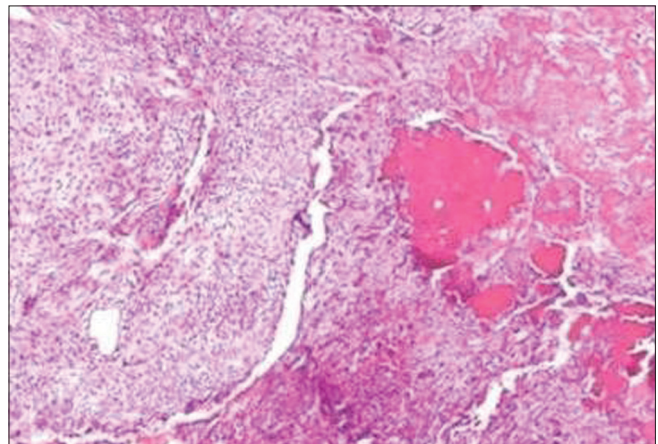


Figure 4: The tumor consisted of solid nodules of various sizes. Within these, cuboidal or columnar epithelial cells formed nests or rosette-like structures

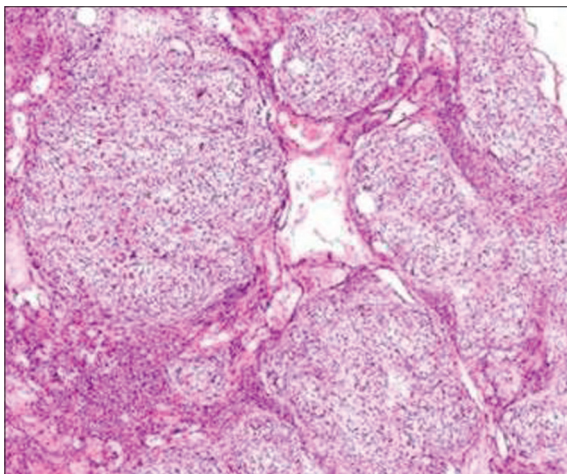


Figure 5: Foci of aggregates of eosinophilic hyaline droplet material and calcification material present

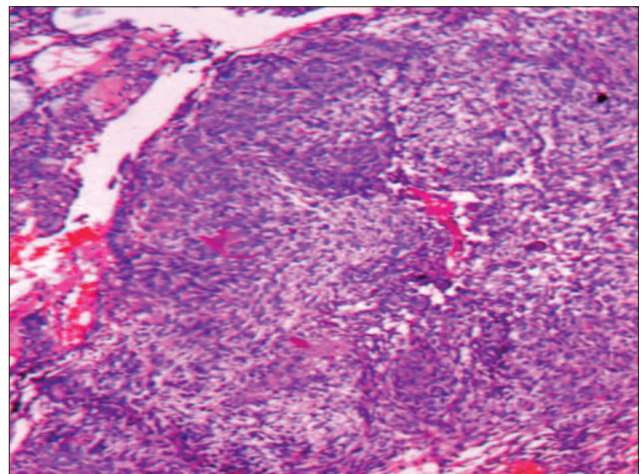


Figure 6: Slide cystic lesion coated by a stratified pavement epithelium

was a maxillary swelling that was either painless or painful. Seven cases involved the maxillary canine. The remaining two involved were the first premolar and the third molar.

Two of them including the present case were from Indian origin, four from East Asians, and one each from Hispanic, Caucasian, and African origin.^[7]

Garcia-Pola *et al.* described the proliferation of an adenomatoid odontogenic cyst in the epithelial border of a dentigerous cyst.^[9]

The structure of the cyst in this case and its insertion around the crown of an unerupted tooth were typical of a dentigerous cyst. When the pathogenesis of AOT is considered, the origin of this tumor is controversial. Some believe that they originate from the odontogenic epithelium of a dentigerous cyst. Therefore, the hypothesis that follicular AOTs arise from the reduced enamel epithelium that lines the follicles of unerupted teeth is fairly conclusive. This is further supported by both morphological and immunocytochemical evidence. According to this hypothesis, the lesions grow next to or into a nearby dental follicle leading to the “envelopmental theory.”

Given that the number of reported cases to date is very less and that the stimulus acting on the cell rests of the dental lamina in the epithelium of an odontogenic cyst is not known, we were unable to speculate whether an AOT arising from an odontogenic cyst could represent a distinct “hybrid” variant completely separate from the three variants described thus far. This single case report cannot answer this question. However, further investigation into this possibility can take place as more cases of AOT arising from an odontogenic cyst are reported.

It is interesting to speculate whether this lesion had the potential of developing into a more aggressive odontogenic neoplasm. Odontogenic cysts showing aggressive growth with neoplastic potential have been reported by Eversole *et al.*, Vander Waal *et al.*, and by Waldron and Mustoe.

Whether a lesion of the type shown in this case has the potential to develop into a frank AOT is unknown. Whether origin of the follicular variant occurs before or after cystic expansion is yet to be fully explained. If the tumor grows after cystic expansion, then this makes certain its origin from a dentigerous cyst, and several such case reports have been published. If it occurs before cystic expansion, then the tumor tissue will fill the follicular space and the AOT will present as a solid tumor. It is reasonable to assume that, given enough time, even those originating from a cyst may grow and fill the lumen completely. It cannot be ruled out that the dentigerous cyst with an impacted canine developed first followed by development of AOT in the cyst wall.

Radiologically, it should be differentiated from dentigerous cyst, which most frequently occurs as a pericoronal radiolucency in the jaws. Dentigerous cyst encloses only the coronal portion of the impacted tooth, whereas AOT shows radiolucency usually surrounding both the coronal and radicular aspects of the involved tooth. But in cases where AOT grows from dentigerous cyst like in this case, the radiographs are inconclusive. However, the irregularity in the wall of cyst may indicate the development of AOT as seen in this case.

This case emphasizes the importance of interpreting the clinical and radiologic features in conjunction with the histopathological features appearance as one might occasionally find it difficult to separate these two entities, based on histopathological features alone.

AOTs and dentigerous cysts are both benign, encapsulated lesions and conservative surgical enucleation or curettage is the treatment of choice.^[7] Encouragingly, the prognosis for a dentigerous cyst is good, and recurrences are very rare after complete removal of the lesion. Similarly, there have been no reports of aggressive behavior on the part of AOT and recurrences are very rare.^[10]

Conclusion

To conclude, while histopathological features are usually considered the gold standard for diagnosis of most lesions, it is not so in our present case. Further, it would be an important point to note that investigations into the possibility of fourth type of a “hybrid” kind of AOT, apart from the already established three types of AOT are required. This can be possible only if more similar cases are reported in the literature.

References

1. Lucas RB. Pathology of tumors of oral tissues. 4th ed. Edinburgh, Scotland: Churchill Livingstone; 1984. p. 66.
2. Stafne EC. Epithelial tumor associated with developmental cysts of the maxilla. A report of three cases. *Oral Surg Oral Med Oral Pathol* 1948;1:887-94.
3. Dayi E, Gurbuz G, Bilge OM, Ciftcioglu MA. Adenomatoid odontogenic tumour (adenoameloblastoma). Case report and review of the literature. *Aust Dent J* 1997;42:315-8.
4. Philipsen HP, Reichart PA, Zhang PA, Nikai H, Yu QX. Adenomatoid odontogenic tumor: Biologic profile based on 499 cases. *J. Oral Pathol Med* 1991;20:149-58.
5. Philipsen HP, Reichart PA. Adenomatoid odontogenic tumour: Facts and figures. *Oral Oncol* 1998;35:125-31.
6. Chen Y-K, Hwanq I-Y, Chen J-Y, Wang W-C, Lin L-M. Adenomatoid odontogenic tumor arising from a dentigerous cyst-A case report. *Int J Pediatr Otorhinolaryngol* 2007;2:257-63.
7. Sandhu SV, Narang RS, Jawanda M, Rai S. Adenomatoid odontogenic tumor associated with dentigerous cyst of the maxillary antrum: A rare entity. *J Oral Maxillofac Pathol* 2010;14:24-8
8. John JB, John RR. Adenomatoid tumor associated with dentigerous cyst in posterior maxilla: A case report and review of literature. *J Oral Maxillofac Pathol* 2010;14: 59-62.
9. Garcia-Pola Vallejo M, Gonzalez Garcia M, Lopez-Arranz JS, Herrero Zapatero A. Adenomatoid odontogenic tumor arising in a dental cyst: Report of unusual case. *J Clin Pediatr Dent* 1998;23:55-8.
10. Zeitoun IM, Dhanrajani PJ, Mosadomi HA. Adenomatoid odontogenic tumor arising in a calcifying odontogenic cyst. *J Oral Maxillofac Surg* 1996;54:634-7.

How to cite this article: Singh V, Goyal S, Sheikh S, Shambulingappa P, Singh B, Singh R. Adenomatoid odontogenic tumor with dentigerous cyst: Report of a rare case with review of literature. *Contemp Clin Dent* 2012;3:S244-7.

Source of Support: Nil. **Conflict of Interest:** None declared.