

Received: 2017.11.25
Accepted: 2017.12.12
Published: 2017.12.29

Clinical Outcome of Total Knee Arthroplasty Performed Using Patient-Specific Cutting Guides

Authors' Contribution:
Study Design A
Data Collection B
Statistical Analysis C
Data Interpretation D
Manuscript Preparation E
Literature Search F
Funds Collection G

ABCDEFG **Murat Çalbiyik**

Department of Orthopedics and Traumatology, Hitit University, Faculty of Medicine, Corum, Turkey

Corresponding Author: Murat Calbiyik, e-mail: drmuratcalbiyik@hotmail.com
Source of support: Departmental sources

Background: Patient-specific instruments have recently gained attention for ensuring the accuracy of osteotomy and correct alignment in total knee arthroplasty (TKA). We aimed to report our experience with TKA performed by using CT-based 3D model of cutting guides in our clinic.





Material/Methods: A total of 36 patients (mean age, 67.58±8.46 years; 24 females, 12 males) who underwent TKA with 3D patient-specific cutting guides in our clinic were included in the study. Differences between preoperatively planned bone resections and actual bone resections were calculated. Femoral and tibial component angles were measured on radiographs of the knee. The change in knee pain was evaluated by patients on a 10-point visual analog scale (VAS). Patients were followed up for 6 months postoperatively.

Results: The actual bone resection was 0.5-1.5 mm higher than the planned resection for all sides, being statistically significant for posterior lateral and distal medial sides (1.1±1.3 mm and 1.5±0.9 mm, respectively; p<0.05). On postoperative radiographs, coronal tibial component angle was 88.8°±0.9° and coronal femoral component angle was 95.2°±1.6°, showing good postoperative alignment. The VAS pain score of patients significantly decreased from preoperative 3.9±0.8 to 1.1±0.9 at 6 months after the operation. One patient developed superficial tissue infection on postoperative follow-up, which was effectively treated. No other pathology was detected in the postoperative period.

Conclusions: Patient-specific cutting guides can provide intraoperative guidance for better placement of the implant in TKA and increase the accuracy of osteotomy and postoperative alignment.

MeSH Keywords: **Arthroplasty, Replacement, Knee • Knee Dislocation • Osteotomy**

Full-text PDF: <https://www.medscimonit.com/abstract/index/idArt/908213>

 2316  3  3  18



Background

Total knee arthroplasty (TKA) is the only treatment option for the end-stage knee osteoarthritis, and other diseases and conditions leading to disability of the knee. The accurate alignment of implant components has been considered as the most important factor determining long-term outcome of TKA [1,2]. Patient-specific implants and instruments including cutting guides individualized per patient have recently gained attention for ensuring the accuracy of osteotomy and correct alignment during partial knee arthroplasty or TKA [3–6]. Recent developments in three-dimensional (3D) laser printing technology have led to the production of various patient-specific guides used in orthopedic surgery such as cutting guides for osteotomy in TKA [7,8]. In this technology, bone cutting for TKA are made by using guides designed individually from preoperative 3D images obtained using computed tomography (CT) or magnetic resonance (MR) imaging [9]. Based on preoperative 3D imaging, patient-specific guides allow making accurate bone cuts and precise positioning of all components of the implant in all planes, thus providing knee alignment, which is necessary for the success of TKA [5,9].

Although patient-specific instruments have been used for TKA to be more efficient and cost-effective, many studies have shown controversial and inconsistent results on the efficiency and accuracy of TKA performed by using patient-specific cutting guides, mostly due to various 3D guide construction techniques or outcome measures that were used in the studies [1]. As most of the individual clinical studies reported the superiority of patient-specific instrumentation over conventional methods for providing limb alignment [2,10], meta-analyses failed to show significant difference between the 2 techniques [1,11]. In order to increase decisive evidence on the benefits and disadvantages of this innovative technique, more clinical studies are needed.

In this study, we report our experience with TKA performed by using CT-based 3D model of cutting guides for precise osteotomy.

Material and Methods

A total of 36 patients with end-stage knee osteoarthritis who had been scheduled for TKA by using patient-specific cutting guides in our clinic between September 2013 and September 2015 were included in the study. The exclusion criteria were body mass index over 30 kg/m², genu valgus deformity, diabetes mellitus, previous infection or surgical intervention in the knee, post-traumatic osteoarthritis, rheumatoid arthritis, and osteoarthritis resulting from connective tissue disease.

The study was approved by the Institutional Ethics Committee and conducted in accordance with the Helsinki Declaration. All patients gave written consent before any study procedure.

Construction of patient-specific cutting guides

The 3D CT images of the hip, knee, and ankle joints at 2 mm, 0.625 mm, and 1 mm slice thickness, respectively, were obtained using CT Optima CT660 (GE Healthcare Chalfont St. Giles, England) for 3D modelling (Akgün Pacs Imaging, Version 3B 4.1.1.1, Ankara, Turkey) of cutting guides according to the patient's knee anatomy, which was constructed from PA 1102 polyamide by a 3D printer (EOSINT P760, Gor Group, Turkey). The patient's varus valgus and tibial slope angles were created, and cuts were planned considering the size of prosthesis according to which cutting guides was constructed. The cutting guides were prepared along with schematic diagrams showing bone cutting amount and angles, and used in surgery after sterilization. Figure 1 presents a schematic diagram showing the use of cutting guides for bone cutting before the placement of the prosthesis.

Surgical procedure and outcome measures

Surgery was performed by using these individualized cutting guides without using an intramedullary guide or opening canal for the femoral guide (Figure 2). Cefazolin was applied once at 1 g 2 h before the operation and twice postoperatively. The anterior median parapatellar incision was made without using a tourniquet, and by using cutting guides, first the tibia and then the femur were prepared by cutting the tibia and femur plateaus, respectively (Figure 2). The prosthesis was fixed with an antibiotic cement, and after the hemorrhage control the joint was closed without inserting a Hemovac drain. All operations were performed by the same surgeon.

Preoperative planning for resections of femoral component and tibial component frontal and sagittal angles was performed with PA 1102 polyamide by a 3D printer (EOSINT P760, Gor Group, Turkey), and intraoperative bone measurements were performed from outside to outside with a calibrated electronic caliper (Mitutoyo Digital Caliper, Japan) with an error of 0.02 mm. Postoperative measurements were performed on anteroposterior and lateral radiographs on PACS (Akgün Pacs Imaging, Version 3B 4.1.1.1, Ankara, Turkey).

Differences between preoperatively planned and intraoperative bone resections at medial tibial plateau (MTP), lateral tibial plateau (LTP), and distal medial (DM), distal lateral (DL), posterior medial (PM), posterior lateral (PL) of tibial plateau, and between preoperative and postoperative measurements of posterior tibial slope (PTS), sagittal femoral component angle (sFCA), and change in joint line (JL), and were calculated.




Figure 1. A schematic diagram showing the use of cutting guides for bone cutting before the placement of prosthesis.

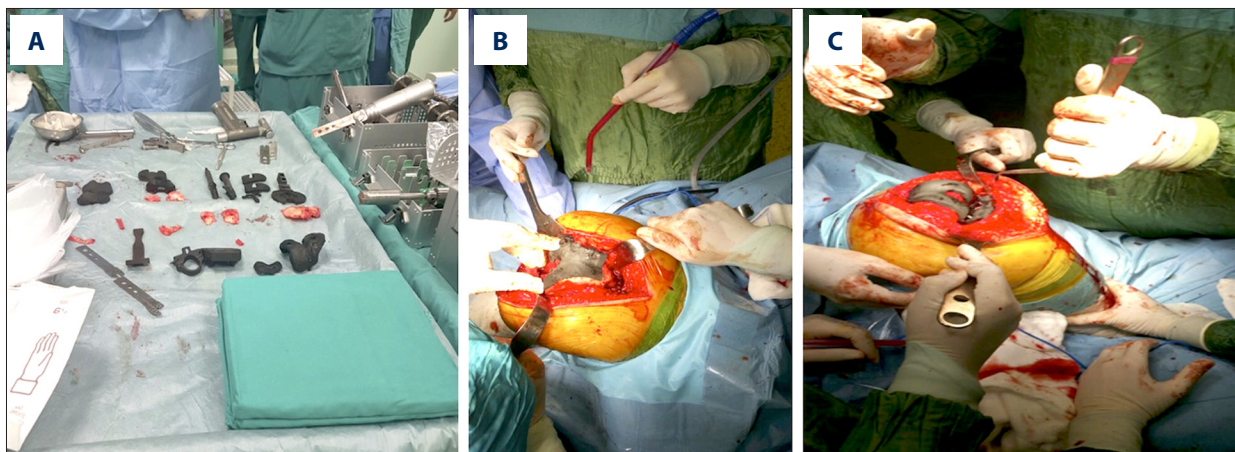


Figure 2. Intraoperative images of total knee arthroplasty performed by using patient-specific cutting guides (A) for cutting tibia and femur plateau (B) before fixation of the prosthesis (C).

To evaluate postoperative alignment, the coronal tibial component angle (cTCA), coronal femoral component angle (cFCA), and coronal ankle knee (CAK) angle were measured on antero-posterior and lateral radiographs of the knee.

As a perioperative blood management protocol, erythrocyte suspension was given to patients if intraoperative blood loss was higher than 20% of total blood volume, or hemoglobin level <8 g/dl (<10 g/dl for patients with major chronic disease and <12 g/dl for ventilator-dependent patients). For pain management, intravenous patient-controlled analgesia with 450 mg tramadol in 150 ml 0.9% NaCl was applied for 48 h following surgery. The loading dose of intravenous tramadol was 20 mg as part of a total dose of 450 mg. If the visual analog scale (VAS) score was over 4, acetaminophen was administered orally at a dose of 1000 mg every 6 h for 9 days. For gastrointestinal prophylaxis, 40 mg of pantoprazole was given daily.

Patients were followed up for 6 months after the surgery. Intraoperative blood transfusion and postoperative infections were recorded. The change in knee pain was evaluated by patients on a 10-point VAS. In order to evaluate the hematologic status of patients and implant infection, serum hemoglobin,

white blood cell, erythrocyte sedimentation rate (ESR), and C-reactive protein (CRP) levels were measured during the study.

Statistical analysis

SPSS software (SPSS Inc., version 22.0, Chicago, IL, USA) was used for the statistical analysis. Study data were summarized by descriptive statistics, which were mean, standard deviation, median, and range. The Shapiro-Wilk test was used to test the conformity of data to normal distribution. Since data on VAS pain score, serum levels of hemoglobin, white blood cell, ESR, and CRP were normally distributed, the significance of change in these variables with surgery was tested by repeated-measures ANOVA. The Wilcoxon signed rank test was applied to evaluate the significance of differences between the planned and actual measurements. Statistical level of significance was predefined as $p < 0.05$.

Results

The mean age of patients was 67.58 ± 8.46 years (range, 47–84 years). Of 36 patients, 24 (66.7%) were female and 12 (33.3%)

Table 1. Serum levels of hemoglobin, white blood cell, erythrocyte sedimentation rate, and C-reactive protein during the study (n=36).

	Preoperative	Early postoperative	Postoperative 2 nd week	Postoperative 3 rd month	p*
Hemoglobin (g/dL)	12.34±1.27	11.79±1.74	10.62±1.67	10.51±1.30	<0.001
White blood cell (10 ⁹ cells/L)	9.71±1.73	9.24±2.90	9.60±3.19	9.82±3.29	0.835
Erythrocyte sedimentation rate (mm/h)	–	13.86±10.90	26.22±20.81	30.11±19.87	<0.001
C-reactive protein (mg/L)	–	5.83±3.51	7.89±9.34	13.76±22.95	<0.001

Data are given as mean ± standard deviation. * Repeated measures ANOVA.

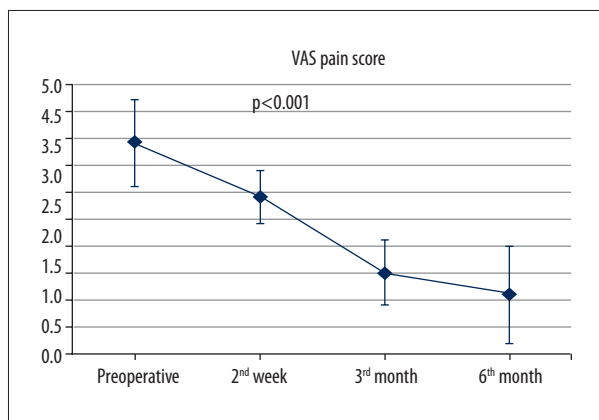


Figure 3. The mean VAS pain score of 36 study patients during the study. The vertical lines represent standard deviations. p value was obtained by repeated-measures ANOVA.

were male. The mean blood transfusion amount during the operation was 0.69±0.75 units. Body mass index of the patients 28.3±1.2 kg/m² (range, 25.1–29.8 kg/m²).

The preoperative hemoglobin and white blood cell count, which were 12.34±1.27 mg/dL and 9.71±1.73 10⁹ cells/L, respectively, decreased after the operation. As white blood cell count returned to the preoperative level 3 months after the operation, hemoglobin remained low (Table 1). Although ESR and CRP levels continued to increase during the first 3 months after the operation as a body reaction to prosthesis (Table 1), only 1 patient developed superficial tissue infection on postoperative follow-up, which was effectively treated. No other pathology or neurological deficit was detected in the postoperative period.

The VAS pain score of patients significantly decreased from 3.9±0.8 preoperatively to 1.1±0.9 at 6 months after the operation (p<0.001), indicating that TKA was effective in relieving knee pain (Figure 3).

The discrepancies between the planned and actual radiographic measurements and resection thicknesses are given in

Table 2. Although there was no significant difference between the planned and actual measurements of PTS (p=0.286), LTP (p=0.091), DL (p=0.154), and PM (p=0.110), the actual measurement was significantly higher than the planned measurement for sFCA (mean difference, 4.5°±0.3°, p=0.003), JL (mean difference, 1.0±0.2 mm, p=0.003), and MTP (mean difference, 2.3±1.4 mm, p=0.003) (Table 2). The actual bone resection was 0.5-1.5 mm higher on average than the planned resection for all sides (Table 2), but the difference between the planned and actual bone resection was significantly higher only for PL and DM sides (1.1±1.3 mm and 1.5±0.9 mm, respectively; p<0.05, Table 2).

On postoperative radiographic evaluation, cTCA was 88.8°±0.9°, cFCA was 95.2°±1.6°, and CAK was 6.2°±0.3°, showing good mechanical and anatomical alignment (Table 3).

Discussion

Component malalignment resulting from inaccuracy of osteotomy is among the major obstacles of TKA. Careful preoperative planning is crucial to reduce the risk of component malalignment and to obtain the best outcome of TKA. Patient-specific cutting guides have been developed for preoperative planning of bone resection during TKA. These guides are based on 3D CT or MR images of knee and main joints of the patient, taking into account particular anatomical structure, all the deformities, and osteophytes of the patient [5]. The suggested benefits of patient-specific guides are better component alignment, longer duration of implant, reduced requirement for revision surgery, shorter operative time, less blood loss, and decreased overall cost of TKA [5,6]. In the present study, we present our experience with TKA performed using a CT-based 3D model of cutting guides. The findings of this pilot study indicate that patient-specific cutting guides can provide intraoperative guidance for easy placement of the implant in TKA, and increase the accuracy of osteotomy and postoperative alignment without any intra- or postoperative complications.

Table 2. Comparison of preoperatively planned resection thicknesses and radiographic measurements with that of actual measurements obtained intraoperative resection thicknesses and postoperative radiographic measurements.

	Planned measurement	Actual measurement	Difference between actual and planned measurements		p*
	Mean ±SD	Mean ±SD	Mean ±SD	Median (range)	
Posterior tibial slope (PTS, °)	87.0±0.0	85.9±2.3	-1.0±2.3	-0.8 (-4.5-2.4)	0.286
Sagittal femoral component angle (sFCA, °)	1.0±0.0	5.4±0.3	4.5±0.3	4.3 (3.7-5.1)	0.003
Joint line change (JL, mm)	0.0±0.0	1.0±0.2	1.0±0.2	1.0 (0.7-1.3)	0.003
Bone resections (mm)					
Medial tibial plato (MTP, mm)	6.9±0.8	9.2±0.9	2.3±1.4	2.2 (0.5-4.5)	0.003
Lateral tibial plato (LTP, mm)	8.4±0.3	9.4±2.3	1.0±2.5	1.0 (-5.0-4.5)	0.091
Distal medial (DM)	7.3±0.4	8.5±1.1	1.1±1.3	1.4 (-1.5-2.3)	0.029
Distal lateral (DL)	8.2±0.4	8.7±0.9	0.5±0.9	0.5 (-1.5-1.9)	0.154
Posterior medial (PM)	8.6±0.3	9.9±3.2	1.3±3.4	2.6 (-7-4.3)	0.110
Posterior lateral (PL)	5.3±0.3	6.8±0.8	1.5±0.9	1.5 (0.5-3.5)	0.003

SD – standard deviation. * Wilcoxon signed rank test.

Table 3. Descriptives of postoperative radiographic measurements.

	Mean ±SD (range)	
Coronal tibial component angle (cTCA, °)	88.8±0.9	(86.9-89.9)
Coronal femoral component angle (cFCA, °)	95.2±1.6	(92.6-97.7)
Coronal ankle knee (CAK, °)	6.2±0.3	(5.6-6.7)

SD – standard deviation.

In previous studies on the accuracy of osteotomy provided by patient-specific cutting guides in TKA, the acceptable difference between planned and actual bone cuts has been reported as 1.5 mm or less [12]. The difference between the planned and actual thickness of resected bone for osteotomy has been reported to range between 0.5 and 2 mm when using patient-specific 3D cutting guides [13,14]. In an 81-knee series, Levy et al. [12] showed that this difference was within acceptable limits for about 80% of femur cuts and 70% of tibial cuts, indicating that patient-specific cutting guide has only moderate accuracy. Kievit et al. [14] studied the accuracy of osteotomy when patient-specific instrumentation was used for TKA in cadavers and found high similarity between planned and actual osteotomy planes. In a recent study by Okada et al. [13], 57.8% of 45 knees operated on with MRI-based patient-specific instrumentation required intraoperative correction. In our series, the actual bone resection was 0.5-1.5 mm higher than

the planned resection for all sides, being statistically significant for PL and DM sides (1.1±1.3 mm and 1.5±0.9 mm, respectively). Thus, our findings indicate that osteotomy error was within acceptable limits for all planes, showing the high accuracy of 3D patient-specific cutting guides.

Since previous studies used many radiographic angles to evaluate the efficacy of patient-specific cutting guides on component alignment [1], it is difficult to compare our results with those of previous studies. Colombelli et al. [2] and Nabavi et al. [15] reported that patient-specific cutting guides provided the desired 180° of hip-knee-ankle angle in over 90% of patients. Seon et al. [16] also reported accurate alignments provided by patient-specific guides without intraoperative complication in 38 knees, noting that severe varus deformity and osteophytes may interfere with seating of the guides. In a recent randomized controlled study on 50 patients comparing patient-specific and conventional instruments for the accuracy of component positioning in TKA [10], patient-specific guides provided more accurate component positioning and prediction of component sizing. Schotanus et al. [17] reported that patient-specific cutting guides increases alignment of the femur component in partial to TKA revision surgery. On the other hand, in a recent meta-analysis involving 2866 knees operated on with patient-specific instruments and 2956 knees with conventional instruments from 44 clinical studies, it was reported that patient-specific instrumentation improved the accuracy of femoral component alignment and global mechanical alignment, but increased tibial component malalignment [18]. In another recent meta-analysis comparing 538 cases of patient-specific

and 549 cases of conventional instrumentation for TKA, patient-specific cutting guides had no superiority in the sagittal positioning of either the tibial or femoral components, and even worse sagittal plane tibial component positioning [11]. In the present study, cTCA was $88.8^{\circ} \pm 0.9^{\circ}$ and cFCA was $95.2^{\circ} \pm 1.6^{\circ}$ on postoperative radiographs, showing good postoperative mechanical and anatomical alignment, particularly for the femoral component.

As previously shown in the literature, the need for blood transfusion during TKA was minimal (0.69 ± 0.75 units) in our study. Thienpont et al. [18] indicated that patient-specific instrumentation significantly decreased the blood loss in TKA. As an indication of good clinical outcome of TKA, VAS pain scores of our patients significantly decreased from 3.9 ± 0.8 preoperatively to 1.1 ± 0.9 at 6 months after the operation. There were also no noticeable complications during follow-up.

Although we did not analyze the cost-effectiveness of patient-specific cutting guides in this study, based on our clinical experience, we suggest that in spite of costs of instrument manufacturing and MRI/CT, this instrument is cost-effective due to decreased operation time and better placement of the implant

in TKA, decreasing the need for repair surgery. Further studies are needed on the cost-effectiveness of patient-specific cutting guides.

The main limitations of the present study are its small sample size and noncomparative design, which prevents us from reaching a more decisive conclusion on the advantages and disadvantages of using patient-specific cutting guides during TKA. Additionally, we were able to follow patients for only 6 months, which limits the evaluation of long-term clinical outcomes of TKA. On the basis of our findings, further large-scale studies with longer follow-up comparing patient-specific cutting guides and conventional methods are needed to reach a more definitive conclusion on the efficiency of 3D patient-specific cutting guides for TKA.

Conclusions

Patient-specific cutting guides can provide intraoperative guidance for better placement of implants in TKA and increase the accuracy of osteotomy and postoperative alignment. However, preoperative planning for the instrument should be performed with caution to decrease the need for intraoperative correction.

References:

1. Rodrigues AST, Gutierrez MAP: Patient-specific instrumentation in total knee arthroplasty. Should we adopt it? *Rev Bras Ortop*, 2016; 52: 242–50
2. Colombelli A, Belluati A, Rizqallah Y et al: Patient specific instrumentation in total knee arthroplasty. *Acta Biomed*, 2017; 88: 45–47
3. Hafez MA, Chelule KL, Seedhom BB, Sherman KP: Computer-assisted total knee arthroplasty using patient-specific templating. *Clin Orthop Relat Res*, 2006; 444: 184–92
4. Steinert AF, Beckmann J, Holzapfel BM et al: Bicompartamental individualized knee replacement: Use of patient-specific implants and instruments (iDuo™). *Oper Orthop Traumatol*, 2017; 29: 51–58
5. Mattei L, Pellegrino P, Calò M et al: Patient specific instrumentation in total knee arthroplasty: A state of the art. *Ann Transl Med*, 2016; 4: 126
6. Jang T, Lee K: A novel registration method for computer-assisted total knee arthroplasty using a patient-specific registration guide. *Surg Innov*, 2014; 21: 80–89
7. Chen H, Guo K, Yang H et al: Thoracic pedicle screw placement guide plate produced by three-dimensional (3-D) laser printing. *Med Sci Monit*, 2016; 22: 1682–86
8. Tack P, Victor J, Gemmel P, Annemans L: 3D-printing techniques in a medical setting: A systematic literature review. *Biomed Eng Online*, 2016; 15: 115
9. Dell'Osso G, Celli F, Bottai V et al: Single-use instrumentation technologies in knee arthroplasty: State of the art. *Surg Technol Int*, 2016; 28: 243–46
10. De Vloo R, Pellikaan P, Dhollander A, Vander Sloten J: Three-dimensional analysis of accuracy of component positioning in total knee arthroplasty with patient specific and conventional instruments: A randomized controlled trial. *Knee*, 2017; 24(6): 1469–77
11. Alcelik I, Blomfield M, Öztürk C et al: A comparison of short term radiological alignment outcomes of the patient specific and standard instrumentation for primary total knee arthroplasty: A systematic review and meta-analysis. *Acta Orthop Traumatol Turc*, 2017; 51: 215–22
12. Levy YD, An VVG, Shean CJW et al: The accuracy of bony resection from patient-specific guides during total knee arthroplasty. *Knee Surg Sports Traumatol Arthrosc*, 2017; 25: 1678–85
13. Okada Y, Teramoto A, Suzuki T et al: Preoperative corrections are required for planning of patient-specific instrumentation in total knee arthroplasty. *Knee*, 2017; 24(6): 1492–97
14. Kievit AJ, Dobbe JGG, Streekstra GJ et al: Predicted osteotomy planes are accurate when using patient-specific instrumentation for total knee arthroplasty in cadavers: A descriptive analysis. *Knee Surg Sports Traumatol Arthrosc*, 2017 [Epub ahead of print]
15. Nabavi A, Olwill CM, Do M et al: Patient-specific instrumentation for total knee arthroplasty. *J Orthop Surg (Hong Kong)*, 2017; 25: 2309499016684754
16. Seon JK, Park HW, Yoo SH, Song EK: Assessing the accuracy of patient-specific guides for total knee arthroplasty. *Knee Surg Sports Traumatol Arthrosc*, 2016; 24: 3678–83
17. Schotanus MGM, Thijs E, Boonen B et al: Revision of partial knee to total knee arthroplasty with use of patient-specific instruments results in acceptable femoral rotation. *Knee Surg Sports Traumatol Arthrosc*, 2017 [Epub ahead of print]
18. Thienpont E, Schwab PE, Fennema P: Efficacy of patient-specific instruments in total knee arthroplasty: A systematic review and meta-analysis. *J Bone Joint Surg Am*, 2017; 99: 521–30