

ANATOMICAL PATHOLOGY

Immunohistochemistry with the anti-BRAF V600E (VE1) antibody: impact of pre-analytical conditions and concordance with DNA sequencing in colorectal and papillary thyroid carcinoma

KATERINA DVORAK¹, BIRTE AGGELER¹, JOHN PALTING¹, PENNY MCKELVIE²,
ANDREW RUSZKIEWICZ³ AND PAUL WARING⁴

¹Ventana Medical Systems Inc., Roche, Tucson, AZ, USA; ²Department of Pathology, St Vincent's Hospital, Melbourne, Vic, ³Centre for Cancer Biology, University of South Australia, and Department of Anatomical Pathology, SA Pathology, Adelaide, SA, and ⁴Department of Pathology, University of Melbourne, Melbourne, Vic, Australia

Summary

The most common of all activating *BRAF* mutations (T1799A) leads to a substitution of valine (V) to glutamic acid (E) at the position 600 of the amino acid sequence. The major goal of this study was to compare detection of the *BRAF* V600E mutation by DNA sequencing with immunohistochemistry (IHC) using the anti-BRAF V600E (VE1) antibody. Archival formalin fixed, paraffin embedded tissues from 352 patients with colon adenocarcinoma ($n=279$) and papillary thyroid carcinoma ($n=73$) were evaluated for the *BRAF* V600E mutation by sequencing and IHC. The discordant cases were re-evaluated by repeat IHC, SNaPshot and next-generation sequencing (NGS). Furthermore, the effect of pre-analytical variables on the utility of this antibody was evaluated in two xenograft mouse models. After resolving 15 initially discordant cases, 212 cases were negative for the *BRAF* V600E mutation by IHC. Of these, 210 cases (99.1%) were also negative by sequencing and two cases (0.9%) remained discordant. Of the 140 cases that were IHC positive for *BRAF* V600E, 138 cases were confirmed by sequencing (98.6%) and two cases remained discordant (1.4%). Overall, the negative predictive value was 99.1%, positive predictive value 98.6%, sensitivity 98.6%, specificity 99.1% and overall percentage agreement 98.9% (348/352 cases). Tissue fixation studies indicated that tissues should be fixed for 12–24 h within 2 h of tissue collection with 10% neutral buffered formalin.

Key words: BRAF V600E, colon cancer, DNA sequencing, immunohistochemistry, thyroid cancer.

Received 28 February, revised 28 April, accepted 1 May 2014

INTRODUCTION

The *BRAF* gene, located on chromosome 7q34, encodes a cytoplasmic serine-threonine kinase. This kinase initiates the activation of the mitogen-activated protein kinase (MAPK) signalling pathway.¹ The oncogenic mutations in the kinase region of *BRAF* gene result in constitutive activation of the MAPK signalling pathway, leading to increased cell proliferation, resistance to apoptosis and tumour progression.¹ *BRAF* mutations are considered to be driver mutations and are usually found in tumours that are wild-type for *KRAS* and *NRAS*.

The majority of the *BRAF* mutations occur at amino acid V600, with the V600E mutation being most prevalent. The *BRAF* V600E mutation is caused by transversion T→A at nucleotide 1799 (T1799A) and results in a substitution of valine (V) to glutamic acid (E) at the position 600 of the amino acid sequence.¹ Other mutations such as V600K, V600M, V600R, V600D and V600G are less common.² The *BRAF* V600E mutation is detected in approximately 8% of all solid tumours, including 45% of papillary thyroid carcinomas, 40–60% of melanomas, 5–15% of colorectal adenocarcinomas, 35% of serous low grade and borderline ovarian carcinomas, 1–3% of non-small cell lung cancers, and 5–7% of cholangiocarcinomas.^{3,4} Furthermore, the *BRAF* V600E mutation is found in 100% of hairy cell leukaemia,⁵ 54% Erdheim–Chester disease, 38% of Langerhans cell histiocytoses⁶ and 60% of pleomorphic xanthoastrocytomas.⁷ Notably, the *BRAF* V600E mutation is also present in benign precursor lesions such as colonic serrated adenomas,⁸ suggesting that it is a common driver mutation, with additional oncogenic events likely required for transformation to malignancy or for progression from low to high tumour grade.

The *BRAF* V600E mutation is an important predictive and prognostic biomarker. The *BRAF* inhibitors vemurafenib and dabrafenib both specifically target mutated *BRAF* at position V600 and have been approved for use in patients with metastatic melanoma.^{9,10} There is also preclinical and clinical evidence that the *BRAF* V600E mutation is a negative predictor of benefit from epidermal growth factor receptor inhibitor therapy in advanced colorectal cancer.¹¹ In microsatellite unstable colorectal cancer (CRC), the *BRAF* V600E mutation is typically observed in sporadic tumours and not in hereditary non-polyposis colorectal cancer (HNPCC)/Lynch syndrome.^{11–14} In this setting, *BRAF* V600E mutation status is used to triage patients for germline mismatch repair (MMR) gene testing to differentiate *MLH1*-deficient sporadic colorectal cancer from HNPCC/Lynch syndrome caused by germ-line *MLH1* mutations.^{12–14} *BRAF* V600E mutation status is also an adverse prognostic biomarker in patients with stage IV CRC, particularly those with MMR proficient tumours.^{15–17} In fact, Toon *et al.* suggested that the routine assessment of the MMR and *BRAF* V600E mutational status should be performed at the same time on all colorectal carcinomas to identify not only the patients with Lynch syndrome in MMR deficient

group, but also to identify the MMR proficient/BRAF V600E group with poor prognosis.¹⁷ Additionally, the presence of BRAF V600E mutation is also significantly associated with increased cancer-related mortality in patients with papillary thyroid cancer in univariate analysis but less so in multivariate analysis.¹⁸ The BRAF V600E mutation independently predicts central compartment lymph node metastasis and is linked with a higher rate of tumour recurrence, tumour related mortality and aggressiveness.^{19–22}

A common approach for the detection of BRAF mutations is sequencing of tumour DNA. Various DNA-based methods have been employed, including techniques such as Sanger sequencing, pyro-sequencing and high resolution melting analysis to scan for unspecified mutations, and allele-specific methods such as SNaPshot, designed to only detect specific mutations. While these methods are typically able to detect a mutant allele in a background of 5–20-fold excess of wild-type alleles, IHC allows direct visualisation of the mutant protein in the tumour cells at single-cell resolution.

The anti-BRAF V600E (VE1 clone) antibody is a mutation-specific mouse monoclonal antibody that was raised against a synthetic peptide representing the BRAF V600E mutated amino acid sequence from amino acids 596 to 606 (GLA-TEKSRWSG).^{23,24} The primary goal of this study was to compare the performance of the anti-BRAF V600E (VE1) antibody by IHC with DNA sequencing in patient samples of colorectal cancer and papillary thyroid cancer. Because of the critical importance of pre-analytical standardisation, we also evaluated the effect of relevant variables such as fixation delay, the use of different fixatives and the duration of fixation on the detection of BRAF V600E expression in xenograft models.

MATERIALS AND METHODS

Cell lines and chemicals

The human A2058 melanoma cell line and LS411N colon cancer cell line were obtained from American Type Culture Collection (ATCC; USA). Both cell lines carry BRAF V600E mutations (<http://cancer.sanger.ac.uk/cancergenome/projects/cosmic/>). The A2058 cells were cultured in Dulbecco's Modified Eagle's Medium (DMEM, ATCC) supplemented with 10% fetal bovine serum (HyClone, USA) and 1% penicillin-streptomycin (Mediatech, USA) at 37°C in 5% CO₂. The LS411N cells were cultured in RPMI-1640 medium (ATCC) supplemented with 10% fetal bovine serum and 1% penicillin-streptomycin at 37°C in 5% CO₂. All other chemicals were of the highest purity available.

Tumour specimens

A total of 352 formalin fixed, paraffin embedded (FFPE) tissues were investigated in the present study including 279 colorectal adenocarcinoma (CRC) cases and 73 papillary thyroid carcinoma (PTC) cases. Two hundred and thirty-eight consecutive colon cancer samples were provided as tissue microarrays (TMA) arranged as triplicate 1.7 mm cores, whereas the 73 thyroid cancer cases and 41 colon adenocarcinomas were provided as whole tissue sections. The tissue samples were obtained from the Ventana Medical Systems tissue bank (Tucson, USA), SA Pathology, (Adelaide, Australia) and St Vincent's Hospital (Melbourne, Australia; 27 of the thyroid cancer cases from St Vincent's Hospital have been previously published).²² All cases were provided in accordance with approval granted by the institutional Human Research Ethics Committees.

Xenografts

All animal studies were conducted in accordance with the Guidance for the Care and Use of Laboratory Animals (National Institutes of Health, Bethesda, USA) and approved by the Institutional Animal Care and Use Committee. Two xenograft models (A2058 melanoma and LS411N colorectal carcinoma cell lines) were selected to evaluate potential variations in staining intensity with different fixation conditions. A total of 10×10^6 A2058 cells or LS411N cells were implanted subcutaneously into the right flank of SCID mice. When the

tumour size reached about 300 mm³, tumours were excised, divided into smaller pieces and placed in different fixatives for various time periods or kept without fixative (ischaemia) for 0.5–24 h as described below.

BRAF immunohistochemistry

An immunohistochemical method using the anti-BRAF V600E (VE1) antibody was developed at Ventana Medical Systems. Sections (5 µm) were cut from the FFPE blocks. Testing was performed using the anti-BRAF V600E (VE1) antibody (Ventana Medical Systems) on the Benchmark XT platform with Cell Conditioning 1 for 64 min, pre-peroxidase inhibition and primary antibody incubation for 16 min at 37°C. The OptiView DAB IHC Detection Kit (Ventana Medical Systems) was used to detect BRAF V600E protein expression. Tissues were counterstained with Hematoxylin II and Bluing Reagent for 4 min. To measure the level of non-specific background signal, each tissue was also stained with a mouse monoclonal antibody (MOPC-21) [Negative Control (Monoclonal), Ventana Medical Systems]. This antibody is not directed against any known epitope present in human tissue.

The pathologists scoring the BRAF V600E IHC were blinded to the DNA mutation status at the time of interpretation of the IHC status. IHC was considered positive if there was unequivocal diffuse cytoplasmic staining with the VE1 antibody in >85% of tumour cells. The intensity of staining of BRAF expression in tumour cells was recorded on a 0–3 scale. Strong cytoplasmic staining was scored as 3, medium cytoplasmic staining as 2, weak cytoplasmic staining as 1 and the absence of staining was scored as 0. Scores of 1–3 represented positive staining, while scores less than 1 were considered negative staining. Nuclear staining in normal colonic epithelial cells and tumour cells was sometimes observed, although the significance of this is not understood and such cases were not considered as positive for BRAF V600E mutation.

Fixation studies

The effect of different fixatives, fixation time and delay to fixation was evaluated in this study. Five fixation times for each of six common fixatives were tested. The selected fixation times represent the lower and upper ranges used in clinical histopathology practice and the selected fixatives represent common fixatives used globally in clinical histopathology. A2058 xenografts and LS411N xenograft tissues were fixed at room temperature for 1 h, 6 h, 12 h, 24 h and 72 h with each of the following fixatives prior to dehydration and embedding in paraffin: 10% neutral buffered formalin (10% NBF; J. T. Baker Chemicals, USA), zinc formalin (Anatech, USA), alcohol formalin acetic acid (AFA; Electron Microscopy Sciences, USA), 95% alcohol, Prefer (glyoxal, alcohol; Anatech) and Z-5 (formalin, zinc, alcohol; Anatech).

Furthermore, the effect of fixation delay (cold ischaemia) was evaluated. In this experiment, A2058 and LS411N xenograft tissues were kept on the bench at room temperature for 30 mins, 1 h, 2 h, 6 h, and 24 h before fixation with 10% NBF for 24 h. After fixation and processing, 5 µm sections were cut from the xenografts and stained with the anti-BRAF V600E (VE1) mouse monoclonal antibody on the Benchmark XT platform with the same protocol used for human tissues. Signal intensity scores (SI) were compared to a nominal reference fixation protocol (10% NBF at room temperature for 24 h), since this is recommended in standard practice. Due to cross-reactivity of the mouse monoclonal VE1 antibody in mouse tissues, staining was only assessed in the human tumour cells in the xenograft samples.

BRAF V600E sequencing

BRAF Sanger sequencing and competitive polymerase chain reaction (C-PCR)
Genomic DNA was extracted from 10–20 µm thick whole tissue sections from 352 FFPE samples using the QIAamp FFPE Tissue Kit (Qiagen, USA) according to the manufacturer's instructions. Tissue from the same tumour block was used for both DNA extraction and the BRAF V600E IHC on all cases. Mutation analysis was initially performed on macrodissected tumour tissue by dideoxy (Sanger) sequencing for all cases except for 27 papillary thyroid cancer cases from St Vincent's Hospital, which were tested by C-PCR using the Seeplex BRAF V600E ACE Detection Kit (Seegene, South Korea) as previously described.²² Sanger sequencing primers were designed to amplify the region of exon 15 containing the V600 nucleotide. Three sets of primers were used including: (1) BRAF-ex15F-TGCTTGCTCTGATAGGAAATG, BRAF-ex15R-AGCATCTCAGGGCCAAAAT; (2) BRAF-ex15F-ATGCTTGCTCTGATAGGAAA, BRAF-ex15R-TGGATCCAGACAACACTGTTC; and (3) BRAF-ex15F-TTCATAATGCTTGCTCTGATAGG; BRAF-ex15R-AGTAAC TCAGCAGCATCTCAGG. These generated product sizes of 226 bp, 166 bp and

246bp, respectively. Both forward and reverse strands were sequenced on an Applied Biosystems 3730xl DNA Analyzer or ABI3130xl Genetic Analyzer and analysed using Sequence Scanner v1.0 software (Applied Biosystems, USA) or GeneMapper v4 software (Applied Biosystems).

BRAF SNaPshot assay

The region encompassing nucleotides 1798, 1799 and 1800 of the *BRAF* gene was amplified by polymerase chain reaction (PCR) using the third primer pair described above and the presence of a mutation was detected using a commercially available SNaPshot kit (Life Technologies, USA). A detection primer [BRAF-600DET- (C)₅TGATTTTGGTCTAGCTACAG] with non-specific 5' sequences was specifically designed to hybridise immediately adjacent to the mutation sites and to give different fragment lengths so that the various mutations would be separated. The primer was hybridised to the PCR product and a primer extension reaction incorporating all four fluorescently labelled dideoxynucleotides allowed the nucleotides at positions 1798, 1799 and 1800 to be determined after analysing the labelled products on an ABI PRISM 3130xl genetic analyser (Applied Biosystems). An estimate of mutation load (sensitivity) was determined by measuring the area under the mutant peak and comparing to the wild-type peak.

Next generation sequencing

Deep sequencing of the region of BRAF exon 15 containing the V600 locus was performed with a customised targeted next generation sequencing (NGS) method. To ensure diverse coverage of the exon, 100 ng of DNA was amplified with the following three pairs of primers to amplify 210 bp amplicons: BRAF-V600 F1 - CTACACCTCAGATATATTCTT, BRAF-V600 R1 - TTCTTACC ATCCACAAAATGG; BRAF-V600 F2 - TACACCTCAGATATATTCTT, BRAF-V600 R2 - CCTCAATTCCTACCATCCAC; BRAF-V600 F3 - ACCTC AGATATATTCTTCATG, BRAF-V600 R3 - AGCCTCAATTCCTTACC ATCC. A second round amplification used Illumina Truseq primer-adapters (Illumina, USA) to add dual bar codes and produced 270 bp fragments for sequencing. The bar coded amplicons were multiplexed into a single pool and were sequenced using the 2 × 150 bp configuration on an Illumina MiSeq as per the manufacturer's instructions. The FASTQ files were imported into CLC Genomics Server 5.5.2 (CLC Bio, Denmark), trimmed and mapped against the reference sequence (NG_007873) for the human BRAF gene exon 15.

Statistical analysis

The overall percent agreement (OPA) rate between IHC using the anti-BRAF V600E (VE1) antibody and sequencing was calculated as the total number of concordant cases divided by the total number of evaluated cases. Assuming that DNA sequencing is the gold standard for the detection of the BRAF V600E mutation, sensitivity was calculated as a proportion of the positive cases which were correctly identified by IHC among all positive cases in DNA sequencing. Specificity was calculated as the proportion of negatives cases which are correctly identified by IHC among all negative cases in DNA sequencing. Negative predictive value was calculated as a proportion of negative cases correctly diagnosed as negative for BRAF V600E mutation by IHC. Positive predictive value was calculated as a proportion of positive cases correctly diagnosed as negative for BRAF V600E mutation by IHC. Analyses were performed using SAS version 9.3 software (SAS, USA).

RESULTS

Anti-BRAF V600E (VE1) immunohistochemistry

All 352 cases were examined for presence of BRAF V600E mutation by IHC using the anti-BRAF V600E (VE1) antibody on the automated Ventana Benchmark XT platform. Initially, 143 cases were positive (89 CRC and 54 PTC) and 209 cases were negative (190 CRC and 19 PTC) for BRAF V600E expression. Representative images are shown in Fig. 1.

Of these 352 cases, 15 cases were discordant with the initial Sanger sequencing results. For the 10 discordant cases, repeat IHC confirmed the initial positive IHC results in five cases (3 CRC, 2 PTC) and the initial negative IHC results in five cases (2 CRC, 3 PTC).

Of the five remaining discordant cases, repeat IHC resolved two PTC cases (whole tissue sections), both 1+, which were

re-scored 0. Since no staining was detected in these tissues, repeat sequencing was not required. Two CRC cases from TMAs initially scored as 1+ were re-scored as 0 after repeat IHC on a whole tissue section. In one case, high background staining was observed including cytoplasmic staining of the normal colonic mucosa. In the other case, all three TMA cores originated from a focal area of 1+ staining occupying ~10% of an otherwise negative tumour. One CRC case initially scored as 0 on all three TMA cores was re-scored as 2+ when IHC was repeated on the whole tissue section. The three tissue cores from this case had all been selected from a negative area within a heterogeneously stained tumour. These data suggest that the discordance between the two IHC assays was the result of sampling bias. All these three TMA cases were re-sequenced using DNA from whole tissue sections to confirm the BRAF mutation status. Overall, IHC discrepancies between whole tissue sections and TMAs occurred in three of 238 TMAs.

In summary, following repeat IHC to resolve discrepancies, five cases were re-scored (4 cases from 1+ to 0, 1 case from 0 to 2+), 140 cases were confirmed to be positive by IHC (88 CRC and 52 PTC) and 212 cases were confirmed to be negative by IHC (191 CRC and 21 PTC).

DNA sequencing

A total of 325 cases were examined for presence of the BRAF V600E mutation by Sanger sequencing and 27 cases by C-PCR. Initially, 140 cases were positive (87 CRC and 53 PTC) and 212 cases were negative (192 CRC and 20 PTC) for the BRAF c.T1799A mutation. No mutations other than BRAF c.T1799A were detected. Representative images are shown in Fig. 2.

Sanger sequencing was repeated and BRAF SNaPshot and/or NGS were performed on DNA extracted from whole tissue sections from the 13 cases that were discordant with the IHC results. There was perfect concordance between the repeat Sanger sequencing and SNaPshot results. Of these 13 cases, the initial BRAF c.T1799A mutation was confirmed in two cases and the initial wild-type (WT) status confirmed in three cases. Four cases (3 CRC and 1 PTC) that were initially c.T1799A mutant were found to be WT by repeated Sanger and SNaPshot sequencing and four cases (2 CRC and 2 PTC) that were initially WT were found to contain c.T1799A mutations. Four initially discordant cases had non-amplifiable DNA and could not be resequenced by repeated Sanger and SNaPshot sequencing. Next generation sequencing, amplifying shorter amplicons than Sanger sequencing, resolved these non-amplifiable cases.

Overall, 140 cases (86 CRC and 54 PTC) were positive for the BRAF c.T1799A mutation and 212 cases were WT (193 CRC and 19 PTC). Although the reasons for the four false positive initial Sanger sequencing results are not known, in two cases the reported allele frequencies were 5% and 9%, well below the level of detection for Sanger sequencing, suggesting these were interpretation errors. Likewise, the reasons for the two false negative Sanger sequencing results are not known but likely the result of low tumour purity or insufficient tumour cells for DNA extraction.

DNA sequencing and IHC concordance

Overall, out of the 15 initially discordant cases, 11 cases were resolved by repeating the IHC using whole tissue slides and/or by sequencing using more sensitive methods. These measures

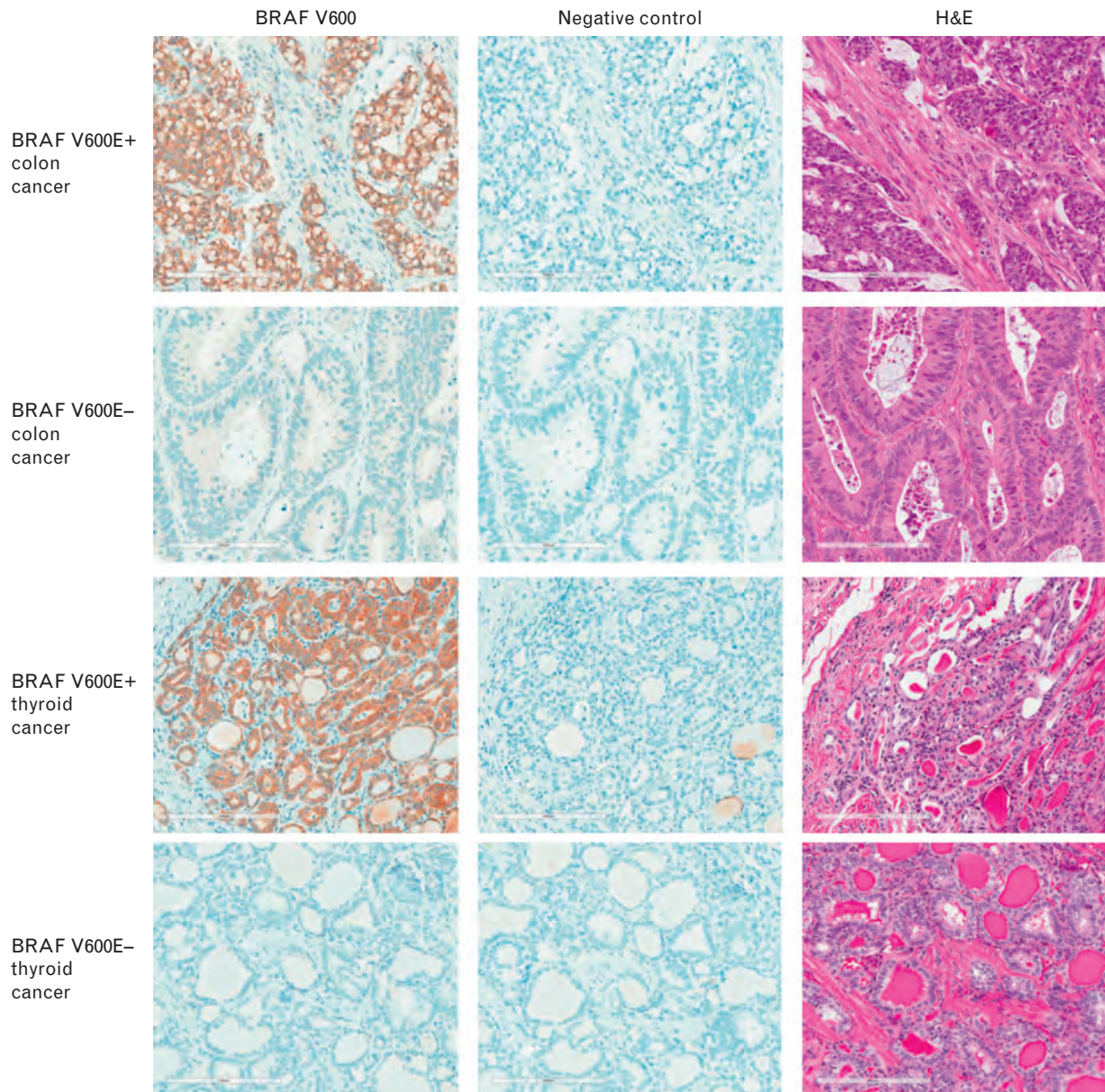


Fig. 1 Representative images of colon cancer and thyroid cancer tissues positive/negative for BRAF V600E mutation stained with the anti-BRAF V600E (VE1) mouse monoclonal antibody, negative mouse monoclonal control and H&E. Scale bar = 200 μ m.

effectively overcame analytical errors due to heterogeneously stained tumours and low tumour purity.

However, there were four residual discordant cases that could not be resolved with the methods and tissue samples available. Two CRC cases were clearly BRAF V600E positive by IHC (2+ in 85% and 100% of tumour cells) with no *BRAF* c.T1799A mutation detected by SNaPshot or NGS, which have limits of detection of 3% and 1%, respectively. These were regarded as IHC false positives. Two PTC cases were clearly negative by IHC on three different occasions but both had *BRAF* c.T1799A mutations detected by Sanger sequencing and NGS. These were regarded as IHC false negatives.

In summary, assuming the sequence status is the gold standard, the IHC assay using the anti-BRAF V600E (VE1) antibody had 98.6% positive predictive value, 99.1% negative predictive value, 98.6% sensitivity, and 99.1% specificity. The overall percentage agreement across all cases was

98.9% (348/352 cases). The summary of the data is shown in Tables 1 and 2.

The effect of fixation conditions

The results from the fixation studies clearly show that fixation with 10% neutral buffered formalin (NBF) for 12, 24 or 72 h are the optimal fixation conditions for immunohistochemical determination of the BRAF V600E mutation using the BRAF V600E (VE1) antibody (Table 3). Fixation with 10% NBF for less than 12 h resulted in a weaker BRAF V600E signal compared to longer fixation times (12–72 h) in our xenograft models. Fixation with zinc formalin for less than 12 h or more than 72 h resulted in weaker signal and a granular staining pattern compared to recommended fixation times (12–24 h). When the xenograft tissues were fixed with other fixatives such as 95% EtOH, Z-5, AFA, or Prefer, the BRAF V600E staining was significantly compromised compared to 10% NBF for 12 and

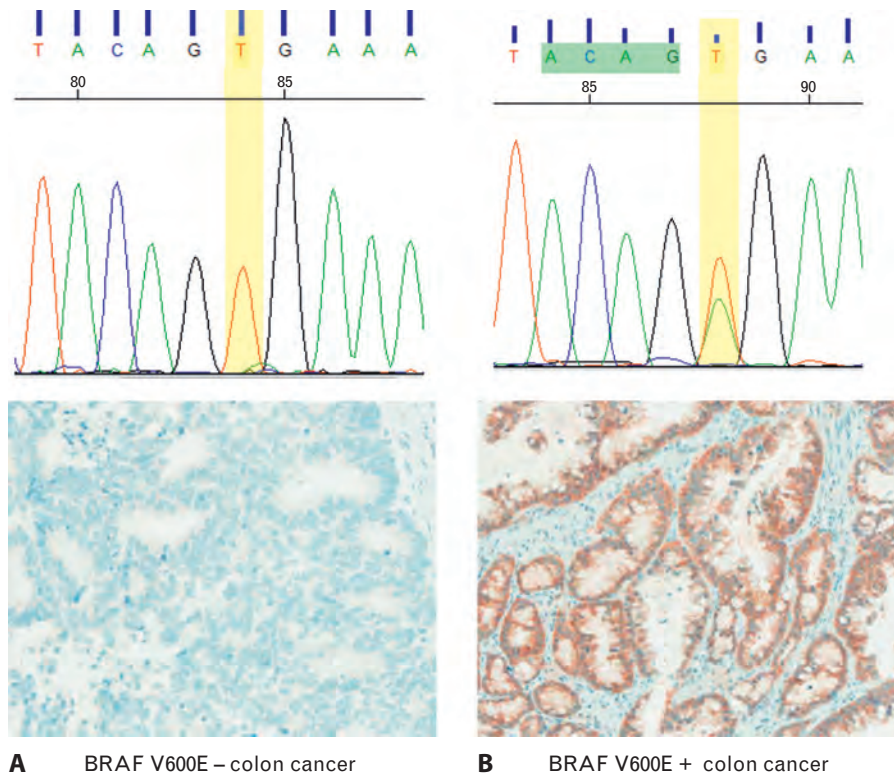


Fig. 2 Mutation analysis of BRAF gene in colon cancer tissues. Example of sequencing electropherogram with BRAF codon wild-type (A) and V600E heterozygous (B). The corresponding images of tissues stained with anti-BRAF V600E (VE1) mouse monoclonal antibody are included. Brown colour indicates positive staining with anti-BRAF V600E (VE1) antibody.

24 h, regardless of fixation time (Table 3). In addition, atypical staining patterns were observed in the cytoplasm of the xenograft tissues fixed with Prefer and Z-5 (granular or membranous staining pattern, Table 3). Staining was weak in the tissues fixed with AFA and no staining was detected in the tissues fixed with 95% EtOH. These results were consistent in both xenograft models.

The effect of delayed fixation on BRAF V600E expression was also studied. Xenograft tissues were left on the bench at room temperature for various time periods prior to fixation with 10% NBF for 24 h (Table 4). The results from this study show that the intensity of BRAF V600E protein staining is not significantly degraded after a fixation delay of up to 2 h in LS411N and A2058 xenografts. However, the A2058 xenografts showed abnormal membranous staining after a 6 h delay

in fixation and the LS411N xenografts showed patchy staining after 24 h of delay to fixation.

In summary, these data suggest that 95% EtOH, AFA, Z-5 and Prefer should not be used as fixatives for anti-BRAF V600E (VE1) immunohistochemistry. In addition, tissues should be fixed within 2 h following tissue collection.

DISCUSSION

Oncogenic mutations in the *BRAF* gene are considered driver mutations in a variety of human cancers such as thyroid cancer, melanoma, colon cancer, ovarian cancer, non-small-cell lung cancer and hairy cell leukaemia. More than 70 different mutations in the *BRAF* gene have been identified; however, the most prevalent mutation is the V600E mutation, in which

Table 1 Summary of the results of the BRAF V600E mutation status in colon cancer (n = 279) and thyroid papillary carcinoma (n = 73) cases

BRAF V600E results	BRAF V600E sequence positive	BRAF V600E sequence negative	Total
Initial results*			
IHC positive	134	9	143
IHC negative	6	203	209
Total	140	212	352
Final results†			
IHC positive	138	2	140
IHC negative	2	210	212
Total	140	212	352

* Initial IHC using whole tissue section (n = 114) and TMAs (n = 238) and DNA sequencing [Sanger sequencing (n = 325), C-PCR (n = 27)].

† Final sequencing data for all cases [IHC on whole tissue sections (n = 120) and TMAs (n = 238); DNA sequencing - Sanger sequencing (n = 325), C-PCR (n = 27), SNaPshot (n = 9), next generation sequencing (n = 13)].
IHC, immunohistochemistry; TMAs, tissue microarrays.

Table 2 Sensitivity, specificity, predictive values and overall agreement for determination of the BRAF V600E mutation status using IHC and DNA sequencing in colon cancer and thyroid papillary carcinoma after initial DNA sequencing and IHC and discrepancy resolution

	Initial IHC vs initial sequencing	Final IHC vs final sequencing
Sensitivity (%)	95.7	98.6
Specificity (%)	95.8	99.1
Negative predictive value (%)	97.1	99.1
Positive predictive value (%)	93.7	98.6
Overall agreement (%)	95.7	98.9

thymine is substituted with adenine at nucleotide 1799.²⁵ This leads to replacement of valine (V) for glutamate (E) at position 600 of the amino acid sequence. BRAF V600E mutated cancers are generally more aggressive and are associated with poorer prognosis.²⁶ Therefore, BRAF V600E is an attractive therapeutic target with several small molecule inhibitors either on the market or in clinical development.

Given the clinical importance of detecting the BRAF V600 mutations in human tumour samples, there is a critical need for V600-specific assays that are accurate, robust, easy to use and interpret, widely available and affordable. The Cobas 4800 BRAF Mutation Test (Roche Molecular Diagnostics, USA) is approved by the United States Food and Drug Administration as an *in vitro* diagnostic device for use as an aid in selecting patients with advanced or metastatic melanoma and papillary thyroid carcinoma whose tumours harbour the BRAF V600E mutation. This assay is more sensitive than Sanger sequencing and can detect V600E mutations at >5% allele frequency in FFPE tissues.^{27,28} However, there is currently no approved assay for the detection of BRAF mutations in other tumour types that harbour the V600E mutation. While various methods have been devised including Sanger sequencing, pyrosequencing, high resolution melt analysis and SNaPshot analysis, these techniques require tumour tissue to be sent to a molecular pathology laboratory for analysis, are dependent upon having high quality DNA, and require a sufficient proportion of tumour cells compared to wild-type cells in the sample. In contrast to

Table 4 BRAF V600E staining intensity scores for A2058 and LS411N xenografts fixed with 10% NBF after delay for various time periods

Delay to fixation	Xenograft	
	A2058	LS411N
0 h	3	3
1 h	3	3
2 h	3	3
6 h	3	2*
24 h	2.5	2.5

A2058 and LS411N xenografts were left on the bench at room temperature for 0.5, 1, 2, 6, or 24 h prior to fixation in 10% NBF for 24 h. The xenograft tissues were stained with anti-BRAF V600E (VE1) antibody on a BenchMark XT.

* Abnormal signal distribution (membranous).
NBF, neutral buffered formalin.

molecular testing, IHC is routinely available in most anatomical pathology laboratories, is cheaper than all current sequencing methods, has a rapid turn-around time, and is not dependent upon DNA quality or proportion of tumour cells in a sample. Furthermore, IHC allows *in situ* assessment of the level of expression of the mutant protein within the tumour cells at single cell resolution, providing confidence that correct cellular elements have been assessed.

In this paper we present one of largest validation studies regarding the detection of the BRAF V600E mutation in thyroid and colon cancer samples using immunohistochemistry with the anti-BRAF V600E (VE1) mouse monoclonal antibody. Based on initial IHC and Sanger sequencing results, there was high concordance with sequencing with an overall percentage disagreement across all cases of 4.26% (15/352 cases). Eleven of the 15 initially discordant cases were resolved by repeat IHC (4 cases), repeat Sanger sequencing (5 cases) or NGS (2 cases). There were four residual discordant cases that could not be resolved with the methods employed and remaining available tissue samples. Assuming DNA sequencing is the gold standard, there were two IHC false positives (both CRC) and two IHC false negatives (both PTC).

Two cases in our cohort were negative by IHC but positive by sequencing. Such IHC false negative results probably arise

Table 3 BRAF V600E signal intensity scores (SI) for A2058 and LS411N xenografts fixed using different fixatives for various time-points

Fixative time (h)	10% NBF		Prefer		95% alcohol		AFA		Zinc formalin		Z-5 fixative	
	Anti-BRAF V600E (VE1)		Anti-BRAF V600E (VE1)		Anti-BRAF V600E (VE1)		Anti-BRAF V600E (VE1)		Anti-BRAF V600E (VE1)		Anti-BRAF V600E (VE1)	
	A2058 (SI)	LS411N (SI)	A2058 (SI)	LS411N (SI)	A2058 (SI)	LS411N (SI)	A2058 (SI)	LS411N (SI)	A2058 (SI)	LS411N (SI)	A2058 (SI)	LS411N (SI)
1	0.5	2	0.5	0.5	0	0	0	0	0.5	0	1	1
6	2	2.5	1*	1	0	0	1	1	2	2	2	1.5*
12†	3	3	2*	2*	0	0	1	1	3	3	1‡	1.5*
24†	3	3	2*	2*	0	0	0.5	0	3	3	1.5	2*
72	3	3	2.5*	2*	0	0	0.5	1	2*	2.5	1.5	2*

A2058 and LS411N xenografts were fixed at room temperature for 1, 6, 12, 24 or 72 h with different fixatives and stained with anti-BRAF V600E (VE1) antibody on a BenchMark XT.

* Granular staining pattern.

† Gold standard.

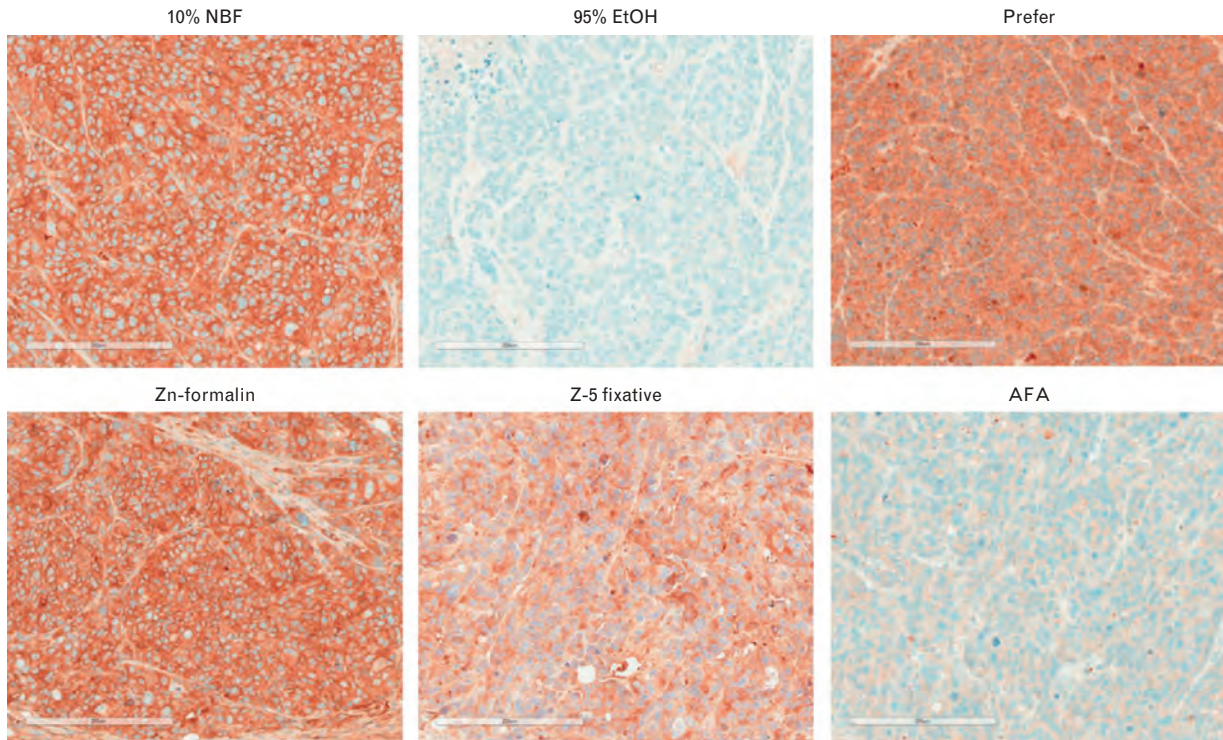
‡ Abnormal signal distribution (membranous).

AFA, alcohol formalin acetic acid; NBF, neutral buffered formalin.

from the loss of expression of the mutant antigen. Tissue ischaemia, for example in areas surrounding necrotic areas, has been shown to reduce BRAF V600E protein expression and is a potential source of false negative IHC results, particularly on small biopsies of metastatic tumours.²³ It is also possible

that additional mutations may prevent translation of the mRNA into the functional protein. Another reason for the lack of staining or heterogeneous staining could be due to suboptimal fixation conditions. Using two different xenograft models, we have shown that optimal detection of the BRAF V600E mutant

LS411N



A2058

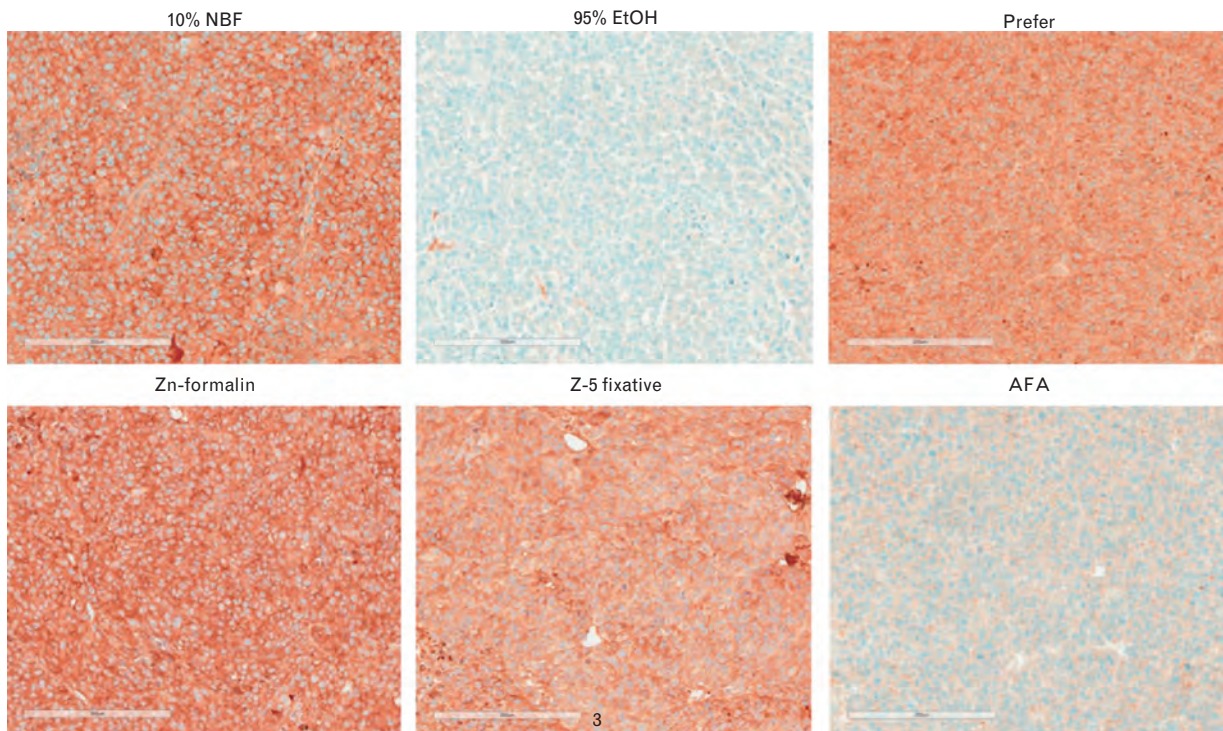


Fig. 3 Representative images of LS411N and A2058 xenograft tissues stained with anti-BRAF V600E (VE1) mouse monoclonal antibody after fixation with different fixatives for 24 h. Scale bar = 200 µm.

protein by immunohistochemistry requires optimal tissue fixation with 10% neutral buffered formalin (NBF) for 12–24 h within 2 h of tissue collection. Other fixatives, fixation for less than 6 h or more than 72 h, or delay in fixation for more than 6 h may negatively affect the staining pattern and signal intensity of BRAF V600E (Tables 3 and 4). Significantly decreased or absent staining in a known BRAF V600E mutant cell line was found in the samples from two xenograft models fixed with inappropriate fixative solutions (Fig. 3). This highlights the importance of correct fixation procedures in clinical practice.

Two of our cases were positive by IHC but negative by sequencing. Such IHC false positives are more difficult to explain. It is likely that tumours with uniform, unequivocal staining with the anti-BRAF V600E (VE1) antibody in reality represent BRAF c.T1799A mutant tumours and false negative sequencing results rather than false positive IHC results. This arises not infrequently with Sanger sequencing due to an excess of wild type allele compared to the mutant allele when only the minority of cells in the sample submitted for sequencing are from tumour areas. Such false negative sequencing results can be avoided by using more sensitive or allele-specific methods. However, as shown in our cases, even deep sequencing using NGS did not detect a mutation in DNA extracted from the sample.

The anti-BRAF V600E (VE1) antibody provided the correct result compared to Sanger sequencing in 337 of 352 cases in our series (95.7% agreement). However, our series was confounded by TMA sampling bias in molecularly heterogeneous tumour samples and by the known insensitivity of Sanger sequencing. When these discordant cases were re-tested using whole tissue sections and/or more sensitive sequencing methods, the anti-BRAF V600E (VE1) antibody gave the correct result in 348 of 352 cases (98.9% agreement). The latter figure is likely to more faithfully reflect clinical practice. This study demonstrates that IHC using the anti-BRAF V600E (VE1) antibody with the VENTANA OptiView DAB Detection system and BenchMark XT platform is a highly specific and sensitive method for the detection of BRAF V600E in colon cancer and papillary thyroid carcinoma (Tables 1 and 2).

Our data are in general agreement with other studies evaluating the anti-BRAF V600E (VE1) antibody in colon cancer^{12–14,29–32} and papillary thyroid cancer.^{24,33–35} Six of these 11 published studies showed 100% sensitivity and specificity when compared to DNA-based methods.^{14,24,30–32,35} Of the five remaining studies, four showed specificity and sensitivity in the range of 90–99% and 89–96%, respectively. One study was a clear outlier with a sensitivity of 71% and specificity of 74%.²⁹ While the majority of the published studies^{12–14,24,30–32,34,35} used automated immunostainers (Ventana Benchmark XT, ULTRA or NexES, Leica Bond Max) and either no retrieval or alkaline retrieval, the study by Adackapara *et al.* used a manual method and acidic retrieval.²⁹ Therefore, it is most likely that methodological differences used in that study were responsible for the anomalous results.

Interpretation of anti-BRAF V600E (VE1) immunohistochemical staining was straightforward in the majority of cases. The staining was exclusively cytoplasmic and present uniformly throughout the tumour. The staining intensity was moderate to strong and occasionally weak, but it was invariably above background levels. Faint weak staining, any type of isolated nuclear staining, weak staining of single interspersed cells, or staining of monocytes or macrophages were scored as

negative. Unexplained staining was sometimes seen in the smooth muscle and nuclei of normal epithelial cells.^{13,14,29,30} This staining should not be confused with positive cytoplasmic staining of tumour cells.

Importantly, IHC with the anti-BRAF V600E (VE1) antibody should be validated in different tumour types. Recent studies indicate that even strong positive immunostaining with the anti-BRAF V600E (VE1) antibody in pituitary adenoma does not indicate the presence of BRAF V600E mutation.^{36,37} Furthermore, because the antibody does not detect the V600K, V600R, V600D or V600M mutations, the anti-BRAF V600E (VE1) antibody should be used with caution in cancers that may harbour different V600 mutations than V600E, such as melanoma, where such mutations can comprise up to 30% of all V600 mutations.^{2,38,39}

In summary, the results from this study demonstrated high concordance between DNA sequencing and IHC using the anti-BRAF V600E (VE1) antibody for detection of the BRAF V600E mutation in colorectal cancer and papillary thyroid cancer in FFPE tissues. In addition, we have shown that the appropriate tissue fixation protocol is critical for the evaluation of BRAF V600E mutation status by immunohistochemistry. Importantly, these data suggest that IHC with the anti-BRAF V600E (VE1) antibody performed on the Benchmark XT automated immunostainer is a highly sensitive and specific detection method for determination of BRAF V600E mutation status. Advantages of this novel method include (1) high analytical sensitivity due to single cell resolution, (2) robust performance when the manufacturer's instructions are followed, (3) ease and consistency of interpretation, (4) widespread availability, (5) rapid turn-around time, (6) low assay failure rate, and (7) lower cost than DNA sequencing.

Acknowledgements: The authors would like to thank the following individuals for their technical contributions in performing assays on the discordant cases and valuable discussions: Irma Gresshoff, Barney Rudzki, Leakhena Leas, Kym Pham, Eric Walk, June Clements, Tricia Bal and Stacey Stanislaw.

Conflicts of interest and sources of funding: Katerina Dvorak and John Palting are currently employed by Ventana Medical Systems Inc. Birte Aggeler is a former employee of Ventana Medical Systems Inc. Paul Waring received research funding from Ventana Medical Systems Inc. to support this study. He is also a former consultant for Roche and former employee of Genentech, a Roche company. Dr Penny McKelvie and Dr Andrew Ruszkiewicz report no conflicts of interest.

Address for correspondence: Dr K. Dvorak, 1910 E. Innovation Park Drive, Ventana Medical Systems Inc., Tucson, AZ, USA. E-mail: katerina.dvorak@ventana.roche.com

References

1. Cantwell-Dorris ER, O'Leary JJ, Sheils OM. BRAFV600E: implications for carcinogenesis and molecular therapy. *Mol Cancer Ther* 2011; 10: 385–94.
2. Rubinstein JC, Sznol M, Pavlick AC, *et al.* Incidence of the V600K mutation among melanoma patients with BRAF mutations, and potential therapeutic response to the specific BRAF inhibitor PLX4032. *J Transl Med* 2010; 8: 67.
3. Pakneshan S, Salajegheh A, Smith RA, Lam AK. Clinicopathological relevance of BRAF mutations in human cancer. *Pathology* 2013; 45: 346–56.
4. Grisham RN, Iyer G, Garg K, *et al.* BRAF mutation is associated with early stage disease and improved outcome in patients with low-grade serous ovarian cancer. *Cancer* 2013; 119: 548–54.

5. Tiacci E, Trifonov V, Schiavoni G, *et al.* BRAF mutations in hairy-cell leukemia. *N Engl J Med* 2011; 364: 2305–15.
6. Haroche J, Charlotte F, Arnaud L, *et al.* High prevalence of BRAF V600E mutations in Erdheim-Chester disease but not in other non-Langerhans cell histiocytoses. *Blood* 2012; 120: 2700–3.
7. Dias-Santagata D, Lam Q, Vernovsky K, *et al.* BRAF V600E mutations are common in pleomorphic xanthoastrocytoma: diagnostic and therapeutic implications. *PLoS One* 2011; 6: e17948.
8. Mesteri I, Bayer G, Meyer J, *et al.* Improved molecular classification of serrated lesions of the colon by immunohistochemical detection of BRAF V600E. *Mod Pathol* 2014; 27: 135–44.
9. Chapman PB, Hauschild A, Robert C, *et al.* Improved survival with vemurafenib in melanoma with BRAF V600E mutation. *N Engl J Med* 2011; 364: 2507–16.
10. Hauschild A, Grob JJ, Demidov LV, *et al.* Dabrafenib in BRAF-mutated metastatic melanoma: a multicentre, open-label, phase 3 randomised controlled trial. *Lancet* 2012; 380: 358–65.
11. Xu Q, Xu AT, Zhu MM, Tong JL, Xu XT, Ran ZH. Predictive and prognostic roles of BRAF mutation in patients with metastatic colorectal cancer treated with anti-epidermal growth factor receptor monoclonal antibodies: a meta-analysis. *J Dig Dis* 2013; 14: 409–16.
12. Capper D, Voigt A, Bozukova G, *et al.* BRAF V600E-specific immunohistochemistry for the exclusion of Lynch syndrome in MSI-H colorectal cancer. *Int J Cancer* 2013; 133: 1624–30.
13. Toon CW, Walsh MD, Chou A, *et al.* BRAF V600E immunohistochemistry facilitates universal screening of colorectal cancers for Lynch syndrome. *Am J Surg Pathol* 2013; 37: 1592–602.
14. Thiel A, Heinonen M, Kantonen J, *et al.* BRAF mutation in sporadic colorectal cancer and Lynch syndrome. *Virchows Arch* 2013; 463: 613–21.
15. Day F, Singh S, Shanmugam K, *et al.* A mutant BRAF V600E-specific immunohistochemistry assay: Correlation with molecular mutation status and clinical outcome in colorectal cancer. *Target Oncol* 2014; 9: (in press).
16. Tie J, Gibbs P, Lipton L, *et al.* Optimizing targeted therapeutic development: analysis of a colorectal cancer patient population with the BRAF(V600E) mutation. *Int J Cancer* 2011; 128: 2075–84.
17. Toon CW, Chou A, Desilva K, *et al.* BRAF V600E immunohistochemistry in conjunction with mismatch repair status predicts survival in patients with colorectal cancer. *Mod Pathol* 2013; 27: 644–50.
18. Xing M, Alzahrani AS, Carson KA, *et al.* Association between BRAF V600E mutation and mortality in patients with papillary thyroid cancer. *JAMA* 2013; 309: 1493–501.
19. Elisei R, Viola D, Torregrossa L, *et al.* The BRAF(V600E) mutation is an independent, poor prognostic factor for the outcome of patients with low-risk intrathyroid papillary thyroid carcinoma: single-institution results from a large cohort study. *J Clin Endocrinol Metab* 2012; 97: 4390–8.
20. Howell GM, Nikiforova MN, Carty SE, *et al.* BRAF V600E mutation independently predicts central compartment lymph node metastasis in patients with papillary thyroid cancer. *Ann Surg Oncol* 2013; 20: 47–52.
21. Kim SJ, Lee KE, Myong JP, *et al.* BRAF V600E mutation is associated with tumor aggressiveness in papillary thyroid cancer. *World J Surg* 2012; 36: 310–7.
22. McKelvie PA, Chan F, Yu Y, *et al.* The prognostic significance of the BRAF V600E mutation in papillary thyroid carcinoma detected by mutation-specific immunohistochemistry. *Pathology* 2013; 45: 637–44.
23. Capper D, Berghoff AS, Magerle M, *et al.* Immunohistochemical testing of BRAF V600E status in 1,120 tumor tissue samples of patients with brain metastases. *Acta Neuropathol* 2012; 123: 223–33.
24. Capper D, Preusser M, Habel A, *et al.* Assessment of BRAF V600E mutation status by immunohistochemistry with a mutation-specific monoclonal antibody. *Acta Neuropathol* 2011; 122: 11–9.
25. Davies H, Bignell GR, Cox C, *et al.* Mutations of the BRAF gene in human cancer. *Nature* 2002; 417: 949–54.
26. Ziai J, Hui P. BRAF mutation testing in clinical practice. *Expert Rev Mol Diagn* 2012; 12: 127–38.
27. Ahn S, Lee J, Sung JY, *et al.* Comparison of three BRAF mutation tests in formalin-fixed paraffin embedded clinical samples. *Korean J Pathol* 2013; 47: 348–54.
28. Anderson S, Bloom KJ, Vallera DU, *et al.* Multisite analytic performance studies of a real-time polymerase chain reaction assay for the detection of BRAF V600E mutations in formalin-fixed, paraffin-embedded tissue specimens of malignant melanoma. *Arch Pathol Lab Med* 2012; 136: 1385–91.
29. Adackapara CA, Sholl LM, Barletta JA, Hornick JL. Immunohistochemistry using the BRAF V600E mutation-specific monoclonal antibody VE1 is not a useful surrogate for genotyping in colorectal adenocarcinoma. *Histopathology* 2013; 63: 187–93.
30. Affolter K, Samowitz W, Tripp S, Bronner MP. BRAF V600E mutation detection by immunohistochemistry in colorectal carcinoma. *Genes Chromosomes Cancer* 2013; 52: 748–52.
31. Desai J, Day F, Muranyi A, *et al.* A highly sensitive immunohistochemical assay to detect BRAF V600E mutations in patients with colorectal cancer. *Ann Oncol* 2012; 23: 383–1383.
32. Sinicrope FA, Smyrk TC, Tougeron D, *et al.* Mutation-specific antibody detects mutant BRAF(V600E) protein expression in human colon carcinomas. *Cancer* 2013; 119: 2765–70.
33. Bullock M, O'Neill C, Chou A, *et al.* Utilization of a MAB for BRAF(V600E) detection in papillary thyroid carcinoma. *Endocr Relat Cancer* 2012; 19: 779–84.
34. Zagzag J, Pollack A, Dultz L, *et al.* Clinical utility of immunohistochemistry for the detection of the BRAF V600E mutation in papillary thyroid carcinoma. *Surgery* 2013; 154: 1199–204.
35. Koperek O, Kornauth C, Capper D, *et al.* Immunohistochemical detection of the BRAF V600E-mutated protein in papillary thyroid carcinoma. *Am J Surg Pathol* 2012; 36: 844–50.
36. Sperveslage J, Gierke M, Capper D, *et al.* VE1 immunohistochemistry in pituitary adenomas is not associated with BRAF V600E mutation. *Acta Neuropathol* 2013; 125: 911–2.
37. Farzin M, Toon CW, Clarkson A, Sioson L, Gill AJ. BRAF V600E mutation specific immunohistochemistry with clone VE1 is not reliable in pituitary adenomas. *Pathology* 2014; 46: 79–80.
38. Long GV, Menzies AM, Nagrial AM, *et al.* Prognostic and clinicopathologic associations of oncogenic BRAF in metastatic melanoma. *J Clin Oncol* 2011; 29: 1239–46.
39. Long GV, Wilmott JS, Capper D, *et al.* Immunohistochemistry is highly sensitive and specific for the detection of V600E BRAF mutation in melanoma. *Am J Surg Pathol* 2013; 37: 61–5.