

CASE IMAGE

A corneal stroma circular ring captured by smartphone adaptor slit lamp camera after small incision lenticule extraction

Qi-Bin Xu 

Department of Ophthalmology, Zhejiang Hospital of Integrated Traditional Chinese and Western Medicine, Hangzhou Red-Cross Hospital, Hangzhou, China

Correspondence

Qi-Bin Xu, Department of Ophthalmology, Zhejiang Hospital of Integrated Traditional Chinese and Western Medicine, Hangzhou Red-Cross Hospital, 208 Huancheng Road East, Hangzhou, 310003 Zhejiang Province, China.
Email: hzyeyes@126.com

Key Clinical Message

A corneal stroma circular ring has captured by smartphone adaptor slit lamp camera after smile for 1 week.

KEYWORDS

circular ring, corneal stroma, slit lamp, small incision lenticule extraction, smartphone

1 | INTRODUCTION

Smartphones have been widely used in ophthalmology. Many researchers recommend different methods such as using 2x zoom on Nokia 7 Plus with slit lamp illumination or smartphone clipped with magnifying lens or smartphone-based intraocular lens microscope to acquire anterior segment images.^{1,2} Smartphone adaptor can also be a convenient, economical, and recordable helper.³ The following image (Figure 1) was taken by smartphone adaptor slit lamp camera (Figure 2B) providing diffuse illumination with frosted glass plate (Figure 2A). A 23-year-old woman whose manifest refraction was $-4.25 -0.75 \times 50$ in the left eye had undergone SMILE to correct refractive errors. A corneal stroma circular ring (Figure 1) has been captured by smartphone adaptor slit lamp camera after SMILE for 1 week.

DECLARATION OF PATIENT CONSENT

The authors certify that they have obtained all appropriate patient consent forms. In the form, the patient(s) has/

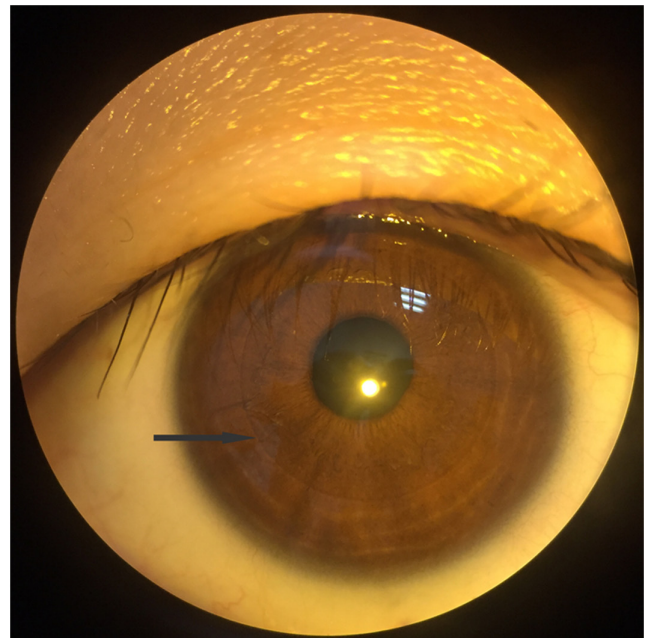


FIGURE 1 A corneal stroma ring captured by smartphone slit lamp camera after SMILE.

have given his/her/their consent for his/her/their images and other clinical information to be reported in the journal. The patients understand that their names and initials

This is an open access article under the terms of the [Creative Commons Attribution-NonCommercial-NoDerivs](https://creativecommons.org/licenses/by-nc-nd/4.0/) License, which permits use and distribution in any medium, provided the original work is properly cited, the use is non-commercial and no modifications or adaptations are made.

© 2024 The Authors. *Clinical Case Reports* published by John Wiley & Sons Ltd.

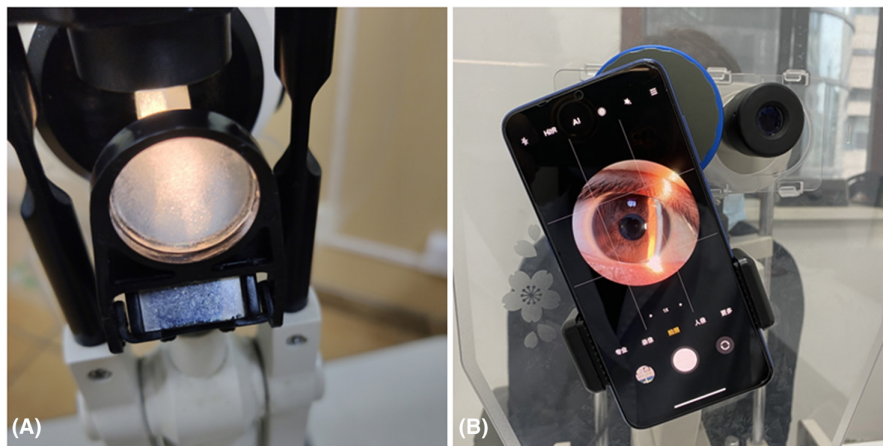


FIGURE 2 (A) Slit lamp providing diffuse illumination with frosted glass plate. (B) Smartphone adaptor slit lamp camera to capture anterior segment image.

will not be published and due efforts will be made to conceal their identity, but anonymity cannot be guaranteed.

AUTHOR CONTRIBUTIONS

Qi-Bin Xu: Data curation; resources; software; writing – original draft; writing – review and editing.

ACKNOWLEDGMENTS

Not applicable.

FUNDING INFORMATION

Nil.

CONFLICT OF INTEREST STATEMENT

There are no conflicts of interest.

DATA AVAILABILITY STATEMENT

All relevant data are within the manuscript and its Additional files.

ORCID

Qi-Bin Xu  <https://orcid.org/0000-0002-5062-3279>

REFERENCES

1. Aswin PR. Smartphone anterior segment photography with slit lamp assisted illumination. *Indian J Ophthalmol.* 2020;68:2249.
2. Chandrakanth P, Chandrakanth KS. Smartphone-based intraocular lens microscope. *Indian J Ophthalmol.* 2020;68:2213-2215.
3. Akkara JD, Kuriakose A. How-to guide for smartphone slit lamp imaging. *Kerala J Ophthalmol.* 2019;31:64-71.

How to cite this article: Xu Q-B. A corneal stroma circular ring captured by smartphone adaptor slit lamp camera after small incision lenticule extraction. *Clin Case Rep.* 2024;12:e8690. doi:[10.1002/ccr3.8690](https://doi.org/10.1002/ccr3.8690)