



## Case Report

# Recurrent Cholangitis by Biliary Stasis Due to Non-Obstructive Afferent Loop Syndrome After Pylorus-Preserving Pancreatoduodenectomy: Report of a Case

Yukihiro Sanada<sup>1,2</sup>, Naoya Yamada<sup>1,2</sup>, Masanobu Taguchi<sup>1</sup>, Kazue Morishima<sup>1</sup>, Naoya Kasahara<sup>1</sup>, Yuji Kaneda<sup>1</sup>, Atsushi Miki<sup>1</sup>, Yasunao Ishiguro<sup>1</sup>, Akira Kuroguchi<sup>1</sup>, Kazuhiro Endo<sup>1</sup>, Masaru Koizumi<sup>1</sup>, Hideki Sasanuma<sup>1</sup>, Takehito Fujiwara<sup>1</sup>, Yasunaru Sakuma<sup>1</sup>, Atsushi Shimizu<sup>1</sup>, Masanobu Hyodo<sup>1</sup>, Naohiro Sata<sup>1</sup>, Yoshikazu Yasuda<sup>1</sup>

<sup>1</sup>*Department of Surgery, Jichi Medical University, Shimotsuke, Japan*

<sup>2</sup>*Department of Transplant Surgery, Jichi Medical University, Shimotsuke, Japan*

We report a 71-year-old man who had undergone pylorus-preserving pancreatoduodenectomy (PPPD) using PPPD-IV reconstruction for cholangiocarcinoma. For 6 years thereafter, he had suffered recurrent cholangitis, and also a right liver abscess (S5/8), which required percutaneous drainage at 9 years after PPPD. At 16 years after PPPD, he had been admitted to the other hospital because of acute purulent cholangitis. Although medical treatment resolved the cholangitis, the patient was referred to our hospital because of dilatation of the intrahepatic biliary duct (B2). Peroral double-balloon enteroscopy revealed that the diameter of the hepaticojejunostomy anastomosis was 12 mm, and cholangiography detected intrahepatic stones. Lithotripsy was performed using a basket catheter. At 1 year after lithotripsy procedure, the patient is doing well. Hepatobiliary scintigraphy at 60 minutes after intravenous injection demonstrated that deposit of the tracer still remained in the upper afferent loop jejunum. Therefore, we considered that the recurrent cholangitis, liver abscess, and intrahepatic lithiasis have been caused by biliary stasis due to nonobstructive afferent loop syndrome. Biliary retention due to nonobstructive afferent loop syndrome may cause recurrent cholangitis or liver abscess after hepaticojejunostomy, and double-balloon enteroscopy and

---

Reprint requests: Yukihiro Sanada, PhD, MD, Department of Transplant Surgery, Jichi Medical University, 3311-1 Yakushiji, Shimotsuke City, Tochigi 329-0498, Japan.

Tel.: +81 285 58 7069; Fax: +81 285 58 7069; E-mail: yuki371@jichi.ac.jp

## hepatobiliary scintigraphy are useful for the diagnosis of nonobstructive afferent loop syndrome.

*Key words:* Nonobstructive afferent loop syndrome – Biliary stasis – Hepaticojejunostomy – Hepatobiliary scintigraphy – Double-balloon enteroscopy

It has been reported that cholangitis occurs in between 6.7% and 14.3% of postoperative pancreatoduodenectomy (PD).<sup>1</sup> Most cases of cholangitis originate due to biliary stasis, which is broadly caused by either anastomotic or nonanastomotic stenosis. In many cases, anastomotic stenosis is accompanied by intrahepatic biliary duct dilatation and obstructive jaundice, making early diagnosis and treatment possible.<sup>2-3</sup> On the other hand, nonanastomotic stenosis, including those of afferent loop syndrome, is performed as a conservative treatment for unexplained fever and cholangitis. However, in many cases, the cause remains unidentified, thereby causing this condition to repeat itself. Since cholangitis can at times be fatal, it is therefore important to identify the cause.

It has been reported that afferent loop syndrome occurs in around 13% of postoperative PD patients.<sup>4</sup> Afferent loop syndrome is generally caused by mechanical occlusion due to the recurrence or metastasis of cancer,<sup>4-6</sup> adhesion,<sup>7-8</sup> torsion,<sup>9</sup> internal hernia,<sup>10</sup> enterolithiasis,<sup>11-12</sup> etc., and thereafter, leads to a syndrome associated with acute abdominal symptom or acute cholangitis. On the other hand, nonobstructive afferent loop syndrome may also be caused by biliary stasis due to jejunal motility failure or the length of the blind end or jejunum, and thereafter, leads to acute cholangitis, liver abscess, and the formation of enterolithiasis and intrahepatic stones. Nonobstructive afferent loop syndrome occurs in around 37% of all of the afferent loop syndrome,<sup>12-13</sup> but few cases have actually been reported.

We herein report a rare case in which the patient experienced recurrent cholangitis and liver abscess by biliary stasis due to nonobstructive afferent loop syndrome after pylorus-preserving pancreatoduodenectomy (PPPD) for cholangiocarcinoma.

### Case Report

Patient: 71-year-old male.

Main symptoms: fever, vomiting, and clouding of consciousness.

Medical history: The patient with cholangiocarcinoma (tub2) underwent PPPD-IV (afferent loop jejunum length: 40 cm) in June 1995. The patient's postoperative condition was good. In March and December 2001, he had suffered recurrent cholangitis, and in February 2004, he was treated by percutaneous drainage for liver abscess on the right liver (S5/8, 2.5cm). In October 2011, he was admitted to the hospital, suffering from cholangitis with clouding of consciousness; and antibiotic treatment was performed. He was referred to our department for a suspicion of recurrent cholangitis and intrahepatic lithiasis being caused by hepaticojejunostomy anastomotic stenosis.

Laboratory data: Table 1.

Abdominal computed tomography (CT): Pneumobilia with B2 duct dilatation was detected (Fig. 1a). Recurrence and metastasis of cholangiocarcinoma was not detected.

Biliary magnetic resonance imaging: B2 duct was dilated in comparison to other intrahepatic biliary ducts (Fig. 1b).

Progress after admission: In January 2012, the patient underwent a peroral double-balloon enteroscopy (DBE). The diameter of hepaticojejunostomy anastomosis was 12 mm, and there were no signs of anastomotic stenosis or recurrence of cholangiocarcinoma (Fig. 2a). On the cholangiography via DBE, the intrahepatic stones was identified in B2 duct (Fig. 2b), and thereafter, lithotripsy using a basket catheter was carried out (Fig. 3a). The right intrahepatic biliary duct was normal. The jejunography after lithotripsy showed no intrahepatic stones and no dilatation of intrahepatic biliary ducts (Fig. 3b). The bacterial culture in the afferent loop jejunum was *Escherichia coli*, *Citrobacter freundii*, and *Enterococcus casseliflavus*. The patient's course after lithotripsy procedure was good, and the patient was discharged from the hospital 3 days after the lithotripsy procedure. The patient is doing well 2 years after the lithotripsy procedure and has not experienced recurrence of the cholangitis and intrahepatic lithiasis. Hepatobiliary scintigraphy during an outpatient visit showed stasis in the upper afferent loop jejunum

Table 1 Laboratory data on admission

Peripheral blood			Blood chemistry		
WBC	$5.2 \times 10^3$	/ $\mu$ L	CRP	0.02	mg/dL
RBC	$402 \times 10^4$	/ $\mu$ L	Albumin	3.6	g/dL
Hb	13.3	g/dL	Total bilirubin	0.47	mg/dL
Plt	$14.1 \times 10^4$	/ $\mu$ L	AST	32	mU/mL
			ALT	17	mU/mL
Tumor markers			LDH	189	mU/mL
CEA	4.8	ng/mL	ALP	272	mU/mL
CA19-9	12	U/mL	$\gamma$ -GTP	23	mU/mL

Fig. 1 Computed tomography (a) and magnetic resonance imaging (b) on admission showed dilatation of the intrahepatic biliary duct (B2).

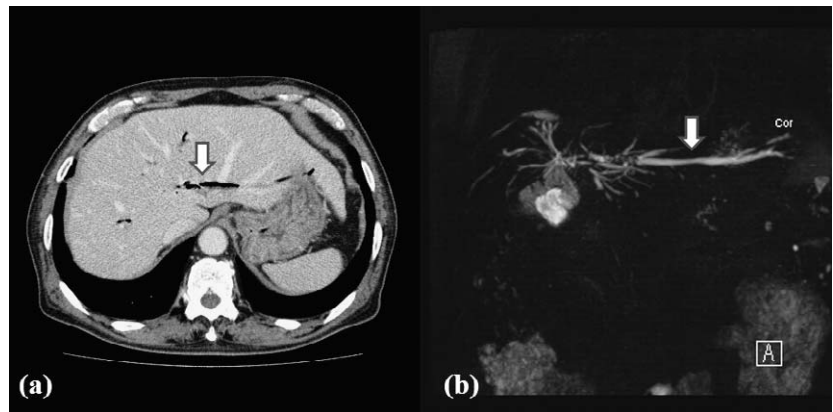


Fig. 2 Peroral double-balloon enteroscopy showed that the diameter of the hepaticojejunostomy anastomosis was 12 mm (a), and cholangiography detected intrahepatic lithiasis (b).

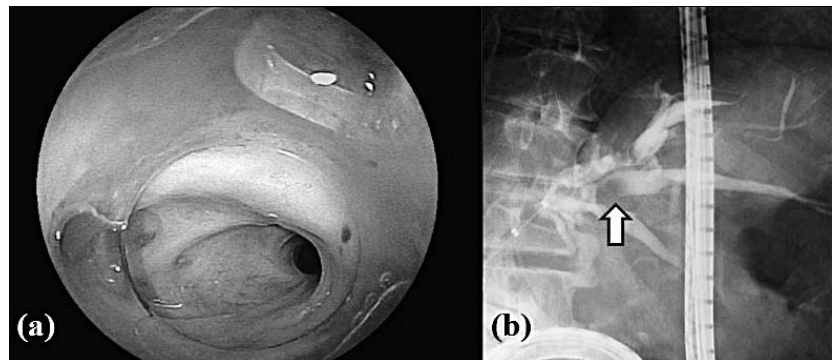
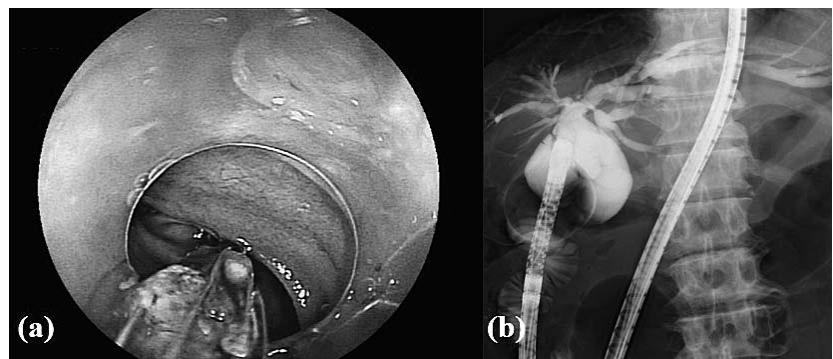
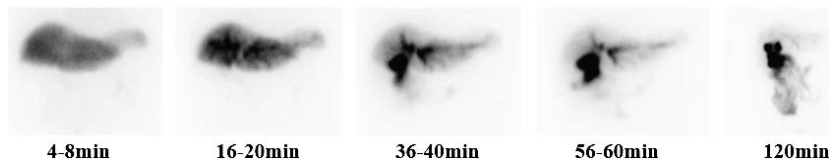


Fig. 3 Lithotripsy using a basket catheter was performed under double-balloon enteroscopy (a). Cholangiography confirmed the removal of the intrahepatic lithiasis (b).





**Fig. 4** Hepatobiliary scintigraphy at 60 minutes after intravenous injection demonstrated that deposit of the tracer still remained in the upper afferent loop jejunum.

60 minutes after the procedure, and a delay in elimination (Fig. 4). Therefore, the patient was diagnosed as retrograde cholangitis; liver abscess and intrahepatic lithiasis were related to biliary stasis due to nonobstructive afferent loop syndrome.

## Discussion

It has been reported that afferent loop syndrome caused by mechanical obstruction occurs in around 13% of postoperative PD cases,<sup>4-11</sup> but some cases of nonobstructive afferent loop syndrome caused by biliary stasis due to jejunal motility failure or the length of the blind end and jejunum have also been reported. Nonobstructive afferent loop syndrome leads to retrograde cholangitis, liver abscess, and the formation of enterolithiasis or intrahepatic lithiasis, and occurs in around 37% of all of the afferent loop syndrome cases.<sup>12-14</sup> It is thought that sump syndrome after hepaticojejunostomy presents the same pathology as nonobstructive afferent loop syndrome.<sup>15-17</sup>

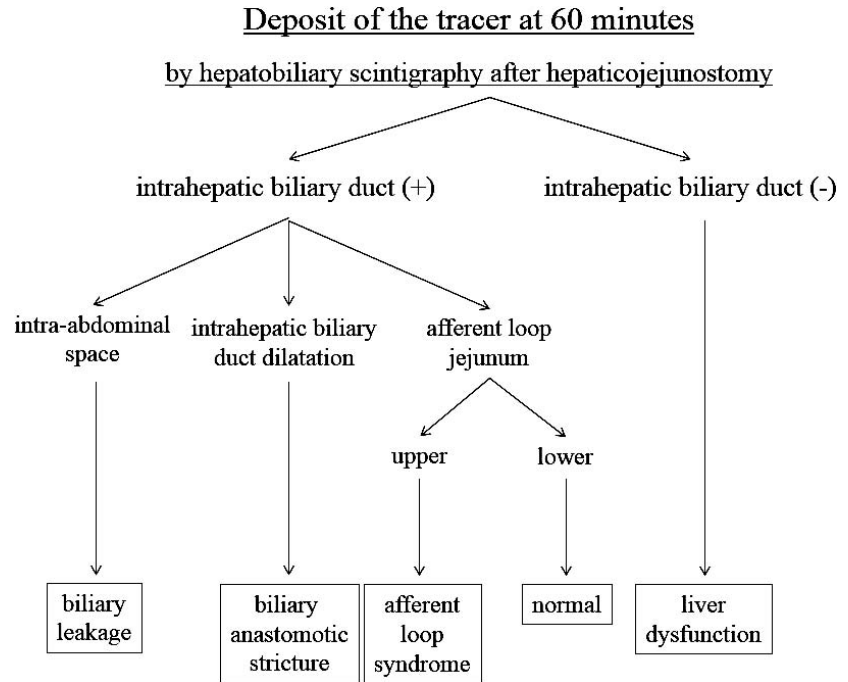
A diagnosis of nonobstructive afferent loop syndrome requires direct observation of afferent loop jejunum via endoscopy, and direct cholangiography and jejunography, in order to rule out hepaticojejunostomy anastomotic stenosis and jejunal stenosis. Since DBE was developed recently, enabling observation of the entire small intestine, and its effectiveness on small intestinal diseases has become widely recognized,<sup>18</sup> it is now possible to reach hepaticojejunostomy anastomotic sites as well, and the effectiveness of interventional radiology using DBE has been reported.<sup>19-27</sup> In this case, direct observation using DBE ruled out the hepaticojejunostomy anastomotic stenosis and the afferent loop jejunum stenosis.

Hepatobiliary scintigraphy allows a confirmation not only of dilatation of the intrahepatic biliary duct and the afferent loop jejunum caused by anastomotic stenosis or jejunal stenosis, it also allows an observation of biliary stasis due to jejunal motility failure or the length of the blind end and jejunum such as delay in excretion to the jejunum.<sup>28</sup>

The deposit of the tracer at 60 minutes after intravenous injection is considered normal more than 80% of the tracer excretes from intrahepatic biliary duct to the lower afferent loop jejunum.<sup>29-30</sup> If excretion of the tracer to the intrahepatic biliary ducts has not taken place within 60 minutes, a diagnosis of liver dysfunction is given,<sup>30-32</sup> and if stasis of the tracer occurs in the intrahepatic biliary duct, it is thought to be caused by hepaticojejunostomy anastomotic stenosis.<sup>29-30</sup> On the other hand, if stasis of the tracer occurs in the upper afferent loop jejunum, it is thought to be caused by afferent loop syndrome. We established the diagnostic method of cholangitis after hepaticojejunostomy using hepatobiliary scintigraphy on Fig. 5. However, hepaticojejunostomy anastomotic stenosis cannot diagnose hepatobiliary scintigraphy alone, and therefore, it is necessary to perform a direct observation using endoscopy. Moreover, it is necessary to perform further accumulation of hepatobiliary scintigraphy after hepaticojejunostomy to confirm our present findings.

Since nonobstructive afferent loop syndrome may improve by conservative treatment alone in many cases, the cause is often not identified, thus resulting in many patients suffering repeated cholangitis. However, there have been reports that nonobstructive afferent loop syndrome was cured by administration of enterokinetic adjusting agents, extension of the afferent loop jejunum,<sup>33</sup> creation of an antireflux valve to the afferent loop jejunum,<sup>34</sup> or revision of the biliary reconstruction. Therefore, the diagnosis of nonobstructive afferent loop syndrome and the indication of surgical interventions should be considered in refractory cholangitis cases. On the diagnosis of nonobstructive afferent loop syndrome, our diagnosis method using hepatobiliary scintigraphy is effective (see Fig. 5).

In conclusion, biliary retention due to nonobstructive afferent loop syndrome may cause recurrent cholangitis or liver abscess after hepaticojejunostomy, and DBE and hepatobiliary scintigraphy are useful for the diagnosis of nonobstructive afferent loop syndrome.



**Fig. 5** The diagnostic method of cholangitis after hepaticojejunostomy, using hepatobiliary scintigraphy.

## Acknowledgments

There were no funding sources for this article. There are no commercial organizations to report. This manuscript has no conflict of interest to disclose as described by the *International Surgery* journal. The authors wish to thank Yukihiro Sanada for study design, acquisition of data, analysis and interpretation of data, and drafting of the manuscript; Masanobu Taguchi, Kazue Morishima, Naoya Kasahara, Yuji Kaneda, Atsushi Miki, Yasunao Ishiguro, Akira Kuroguchi, Kazuhiro Endo, Masaru Koizumi, Hideki Sasanuma, Takehito Fujiwara, Yasunaru Sakuma, Atsushi Shimizu, and Masanobu Hyodo for acquisition of data; and Naohiro Sata and Yoshikazu Yasuda for critical revision of the manuscript for important intellectual content.

## References

1. Yamaguchi K, Tanaka M, Chijiwa K, Nagakawa T, Imamura M, Takada T. Early and late complications of pylorus-preserving pancreaticoduodenectomy in Japan 1998. *J Hepatobiliary Pancreat Surg* 1999;6(3):303–311
2. Ammori BJ, Joseph S, Attia M, Lodge JP. Biliary strictures complicating pancreaticoduodenectomy. *Int J Pancreatol* 2000; 28(1):15–21; discussion 21–22
3. House MG, Cameron JL, Schulick RD, Campbell KA, Sauter PK, Coleman J *et al.* Incidence and outcome of biliary strictures after pancreaticoduodenectomy. *Ann Surg* 2006;243(5):571–6; discussion 576–578
4. Pannala R, Brandabur JJ, Gan SI, Gluck M, Irani S, Patterson DJ *et al.* Afferent limb syndrome and delayed GI problems after pancreaticoduodenectomy for pancreatic cancer: single-center, 14-year experience. *Gastrointest Endosc* 2011;74(2):295–302
5. Kim JK, Park CH, Huh JH, Park JY, Park SW, Song SY *et al.* Endoscopic management of afferent loop syndrome after a pylorus preserving pancreatoduodenectomy presenting with obstructive jaundice and ascending cholangitis. *Clin Endosc* 2011;44(1):59–64
6. Aimoto T, Uchida E, Nakamura Y, Katsuno A, Chou K, Tajiri T *et al.* Malignant afferent loop obstruction following pancreaticoduodenectomy: report of two cases. *J Nippon Med Sch* 2006; 73(4):226–230
7. Spiliotis J, Karnabatidis D, Vaxevanidou A, Datsis AC, Rogdakis A, Zacharis G *et al.* Acute cholangitis due to afferent loop syndrome after a Whipple procedure: a case report. *Cases J* 2009;2:6339
8. Shimamura K, Otani T, Yamazaki T, Kuwabara S, Katayanagi N, Yamamoto M *et al.* Jejunal loop obstruction by a gallstone from hepaticojejunostomy-induced acute cholangitis: report of a case. *Surg Today* 2006;36(8):737–740
9. Tan WS, Chung AY, Low AS, Cheah FK, Ong SC. Enterolith formation in the roux limb hepaticojejunostomy. *Dig Dis Sci* 2007;52(11):3214–3216
10. Kawakami M, Mukaiya M, Kimura Y, Hata F, Katsuramaki T, Sasaki K *et al.* Obstructive jaundice due to internal herniation: a case report and review of the literature. *Hepatogastroenterology* 2002;49(46):1030–1032

11. Tien YW, Lee PH, Chang KJ. Enterolith: an unusual cause of afferent loop obstruction. *Am J Gastroenterol* 1999;**94**(5):1391–1392
12. Kim SH, Jeong S, Lee DH, Yoo SS, Lee KY. Percutaneous cholangioscopic lithotripsy for afferent loop syndrome caused by enterolith development after Roux-en-Y hepaticojejunostomy: a case report. *Clin Endosc* 2013;**46**(6):679–682
13. Lee MC, Bui JT, Knuttinen MG, Gaba RC, Scott Helton W, Owens CA. Enterolith causing afferent loop obstruction: a case report and literature review. *Cardiovasc Intervent Radiol* 2009;**32**(5):1091–1096
14. Kiyohara T, Shinomura Y, Isozaki K, Nakahara M, Tsutsui S, Nishibayashi H *et al.* A decreased number of c-kit-expressing cells in a patient with afferent loop syndrome. *J Gastroenterol* 2003;**38**(4):390–394
15. Marangoni G, Ali A, Faraj W, Heaton N, Rela M. Clinical features and treatment of sump syndrome following hepaticojejunostomy. *Hepatobiliary Pancreat Dis Int* 2011;**10**(3):261–264
16. Morrissey PE, Burns GA, Cohn SM. Sump syndrome complicating Roux-en-Y hepaticojejunostomy: case report and review of the literature. *Surgery* 1996;**119**(4):403–405
17. Collard JM, Romagnoli R. Roux-en-Y jejunal loop and bile reflux. *Am J Surg* 2000;**179**(4):298–303
18. Yamamoto H, Sekine Y, Sato Y, Higashizawa T, Miyata T, Lino S *et al.* Total enteroscopy with a nonsurgical steerable double-balloon method. *Gastrointest Endosc* 2001;**53**:216–220
19. Yamamoto H, Sekine Y, Sato Y, Higashizawa T, Miyata T, Iino S *et al.* Double-balloon enteroscopy through a Roux-en-Y anastomosis for EMR of an early carcinoma in the afferent duodenal limb. *Gastrointest Endosc* 2001;**53**(2):216–220
20. Ryozaawa S, Iwamoto S, Iwano H, Ishigaki N, Taba K, Sakaida I. ERCP using double-balloon endoscopes in patients with Roux-en-Y anastomosis. *J Hepatobiliary Pancreat Surg* 2009;**16**(5):613–617
21. Mönkemüller K, Fry LC, Bellutti M, Neumann H, Malfertheiner P. ERCP with double balloon enteroscope in patients with Roux-en-Y anastomosis. *Surg Endosc* 2009;**23**(9):1961–1967
22. Chahal P, Baron TH, Poterucha JJ, Rosen CB. Endoscopic retrograde cholangiography in post-orthotopic liver transplantation with Roux-en-Y biliary reconstruction. *Liver Transpl* 2007;**13**(8):1168–1173
23. Koornstra JJ. Double balloon enteroscopy for endoscopic retrograde cholangiopancreatography after Roux-en-Y reconstruction: case series and review of the literature. *Neth J Med* 2008;**66**(7):275–279
24. Nishimura N, Yamamoto H, Yano T, Hayashi Y, Arashiro M, Miyata T *et al.* Safety and efficacy of double-balloon enteroscopy in pediatric patients. *Gastrointest Endosc* 2010;**71**(2):287–294
25. Haruta H, Yamamoto H, Mizuta K, Kita Y, Uno T, Egami S *et al.* A case of successful enteroscopic balloon dilatation for late anastomotic stricture of choledochojejunostomy after living donor liver transplantation. *Liver Transpl* 2005;**11**(12):1608–1610
26. Kawano Y, Mizuta K, Hishikawa S, Egami S, Fujiwara T, Hyodo M *et al.* Rendezvous penetration method using double-balloon endoscopy for complete anastomosis obstruction of hepaticojejunostomy after pediatric living donor liver transplantation. *Liver Transpl* 2008;**14**(3):385–387
27. Sanada Y, Mizuta K, Yano T, Hatanaka W, Okada N, Wakiya T *et al.* Double-balloon enteroscopy for bilioenteric anastomotic stricture after pediatric living donor liver transplantation. *Transpl Int* 2011;**24**(1):85–90
28. Muthukrishnan A, Shanthly N, Kumar S. Afferent loop syndrome: the role of Tc-99m mebrofenin hepatobiliary scintigraphy. *Clin Nucl Med* 2000;**25**(6):492–494
29. Concannon RC, Howman-Giles R, Shun A, Stormon MO. Hepatobiliary scintigraphy for the assessment of biliary strictures after pediatric liver transplantation. *Pediatr Transplant* 2009;**13**(8):977–983
30. Fukuda A, Sakamoto S, Shigeta T, Kakiuchi T, Matsuno N, Tanaka H *et al.* Hepatobiliary scintigraphy for the assessment of biliary stricture after pediatric living donor liver transplantation for hepaticojejunostomy reconstruction: the value of the excretion rate at 60 min. *Pediatr Transplant* 2011;**15**(6):594–600
31. Al Sofayan MS, Ibrahim A, Helmy A, Al Saghier MI, Al Sebayed MI, Abozied MM. Nuclear imaging of the liver: is there a diagnostic role of HIDA in posttransplantation? *Transplant Proc* 2009;**41**(1):201–207
32. Young SA, Sfakianakis GN, Pyrsopoulos N, Nishida S. Hepatobiliary scintigraphy in liver transplant patients: the “blind end sign” and its differentiation from bile leak. *Clin Nucl Med* 2003;**28**(8):638–642
33. Vrochides D, Fischer SA, Soares G, Morrissey PE. Successful treatment of recurrent cholangitis complicating liver transplantation by Roux-en-Y limb lengthening. *Transpl Infect Dis* 2007;**9**(4):327–331
34. Orlando G, Blairvacq JS, Otte JB, Goffette P, Ciccarelli O, Sempoux C *et al.* Successful treatment of recurrent cholangitis after adult liver transplantation with a Tsuchida antireflux valve. *Transplantation* 2004;**77**(8):1307–1308

© 2014 Sanada et al.; licensee The International College of Surgeons. This is an Open Access article distributed under the terms of the Creative Commons Attribution Non-commercial License which permits use, distribution, and reproduction in any medium, provided the original work is properly cited, the use is non-commercial and is otherwise in compliance with the license. See: <http://creativecommons.org/licenses/by-nc/3.0>