



## Case report

# Manifestation of a solitary retinal astrocytic hamartoma in a patient with Best macular dystrophy

Stanford C. Taylor<sup>a</sup>, Huber M. Vasconcelos Jr.<sup>a,b</sup>, Paul Yang<sup>a,\*</sup><sup>a</sup> Casey Eye Institute at Oregon Health & Science University, United States<sup>b</sup> Department of Ophthalmology and Visual Sciences, Federal University of Sao Paulo (UNIFESP), Brazil

## ARTICLE INFO

## Keywords:

Retinal astrocytoma  
Best macular dystrophy

## ABSTRACT

**Purpose:** To report the case of an adolescent male with a history of Best macular dystrophy and retinal astrocytic hamartoma.**Observations:** A 15 year old male with a history of Best macular dystrophy who had been followed by ophthalmology for 9 years was noted to have progressive enlargement of a superonasal peripapillary retinal lesion. Imaging and exam are consistent with a diagnosis of retinal astrocytic hamartoma. There were no extraocular signs or symptoms that were diagnostic of a phakomatosis. Genetic testing was positive for a mutation in *BEST1*, but not *TSC1* or *TSC2*.**Conclusions and Importance:** Retinal astrocytic hamartoma is an unusual association with Best macular dystrophy, and this case highlights the balanced approach needed to navigate a potentially complex work-up.

## 1. Introduction

Best macular dystrophy describes a relatively uncommon autosomal dominant retinal disorder with an estimated prevalence of 1.5–20 cases per 100,000 individuals.<sup>1,2</sup> It is characterized by vitelliform lesions of the central maculae that often develop retinal pigment epithelium (RPE) hyperpigmentation and atrophy over time. While extramacular vitelliform lesions can occur in a multifocal variant of Best dystrophy, other non-macular retinal lesions have not been associated with this genotype. Here, we report a case of an adolescent male with Best macular dystrophy who also developed a solitary retinal astrocytic hamartoma. This report was carried out with approval from the Institutional Review Board (IRB) at the Oregon Health & Science University, is Health Insurance Portability and Accountability Act (HIPAA) compliant, and the patient and his family provided written consent for publication.

## 2. Case

A 6 year old male with a history of amblyopia in the left eye initially presented to our eye clinic in 2009 for evaluation of vitelliform lesions in both maculae. Genetic testing revealed a previously described disease-causing mutation in *BEST1*, namely Tyr227Cys (EPP = 3).<sup>3,4</sup> Examination of family members concluded the father was a Best non-

penetrant gene carrier. The patient has since been followed routinely for hereditary Best macular dystrophy and, while the macular sub-retinal pigment epithelium (RPE) deposits have slowly progressed, the patient has maintained a best corrected visual acuity of 20/20 and 20/25 in the right and left eyes, respectively.

Beginning in 2013, a peripapillary white and patchy superficial retinal lesion began to be noted superonasal to the optic nerve. Over the ensuing four years, it was noted to slowly increase in size, and the peripheral retina developed a tapetal sheen (Fig. 1). Optical Coherence Tomography (OCT) of the lesion in 2018 demonstrated a hyperreflective thickening of the inner retinal layers with a moth-eaten appearance and posterior shadowing (Fig. 2A–B). Fluorescein angiography showed early filling of the small lacey vessels within the lesion (Fig. 2C) with pronounced residual hyperfluorescence in the late phases, and no defined feeder vessel. OCT angiography showed vascular flow consistent with a disorganized capillary network within the lesion, which recapitulates the findings on fluorescein angiography (Fig. 2D). Combined with the ophthalmoscopic appearance, multimodal imaging of the lesion was consistent with a retinal astrocytic hamartoma.<sup>5–7</sup>

To assess for a potential underlying genetic syndrome associated with the astrocytic hamartoma, the patient was referred to medical genetics where a systemic work-up was performed. Family history was negative for any phakomatoses. No pathognomonic cutaneous findings of tuberous sclerosis complex or neurofibromatosis type 2 were found

\* Corresponding author. Casey Eye Institute at Oregon Health &amp; Science University, 3375 SW Terwilliger Blvd, Portland, OR, 97239, United States.

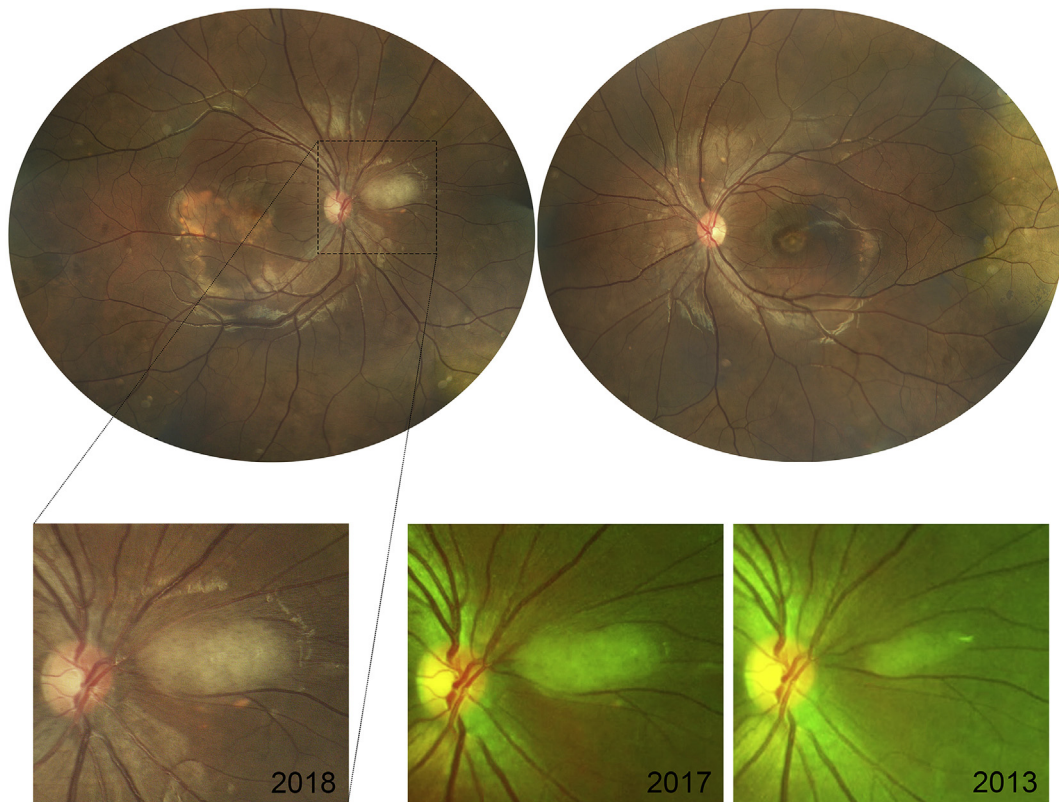
E-mail address: [YangP@ohsu.edu](mailto:YangP@ohsu.edu) (P. Yang).<https://doi.org/10.1016/j.ajoc.2018.12.009>

Received 7 August 2018; Received in revised form 4 December 2018; Accepted 10 December 2018

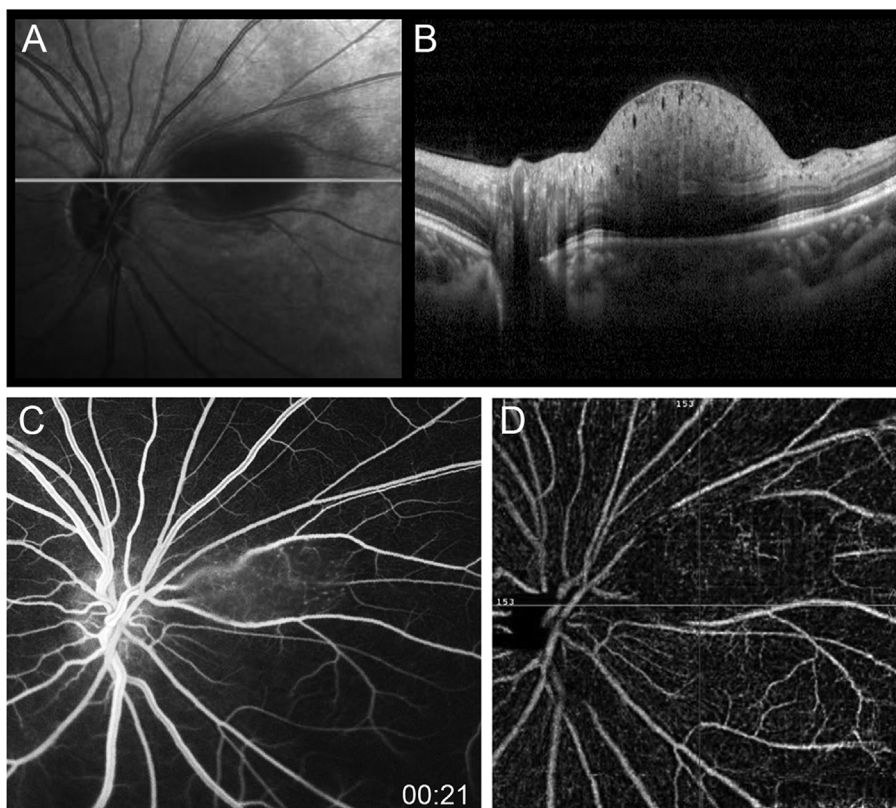
Available online 11 December 2018

2451-9936/© 2018 The Authors. Published by Elsevier Inc. This is an open access article under the CC BY-NC-ND license

<http://creativecommons.org/licenses/by-nc-nd/4.0/>.



**Fig. 1.** Fundus photography of the patient at 15 years old. (Top) Right eye color fundus photo showing a macular scrambled vitelliform lesion, a nasal peripapillary white and patchy superficial retinal lesion, and tapetal sheen with multiple mid-peripheral hyper-pigmented patches. Left eye showing similar findings, but without a peripapillary lesion. (Bottom/Inset) Magnified view of the peripapillary lesion with longitudinal images documenting the growth of the lesion over the past 5 years. There is a small inferior vitelliform deposit that developed one year ago.



**Fig. 2.** (A) Infrared image of the optic nerve and nasal peripapillary lesion with a horizontal line indicating the plane of the displayed OCT image. (B) Thickening of the nerve fiber layer on SD-OCT, with mass-effect and scattered pinpoint optically empty spaces within the lesion. (C) Fluorescein angiography showing early filling of the small vasculature within the lesion. (D) OCT angiography demonstrating intralésional vascular flow of small vessels, as well as blocking of the underlying retinal vasculature by the lesion.

on physical exam. There were two café-au-lait macules 1 cm in size, one on each hip, which were too few in number to be of diagnostic value. Molecular testing for *TSC1* and *TSC2* was negative. As there were no extraocular signs or symptoms that were diagnostic of a phakomatosis and negative genetic screening, MRI brain and abdomen were suggested, but not yet recommended at this time by medical genetics. He is currently being observed by ophthalmic and medical genetics on an annual basis.

### 3. Discussion

Astrocytic retinal hamartomas represent a rare retinal condition and are usually associated with phakomatoses, with 71% percent of lesions in one series being associated with tuberous sclerosis or neurofibromatosis.<sup>8</sup> Retinal astrocytic hamartomas have rarely been associated with inherited retinal degenerations (e.g. retinitis pigmentosa and Leber's congenital amaurosis),<sup>9,10</sup> and its association with Best disease in our case is highly unusual. Only one case of an 11 year old with a combined clinical diagnosis of both Best disease and tuberous sclerosis complex was recently reported.<sup>11</sup> In contrast, our patient had no extraocular stigmata of tuberous sclerosis complex or neurofibromatosis 2, however symptoms may not manifest until later in life. Given the solitary and peripapillary nature of the astrocytic lesion in our patient, it may also be possible that this is a sporadic lesion that is not associated with a phakomatosis.<sup>8,12</sup> This case illustrates the need to proceed with a balanced approach when working-up patients potentially presenting with unusual combinations of inherited disorders.

### 4. Conclusion

Retinal astrocytic hamartomas have previously been documented in patients with retinal dystrophies, including retinitis pigmentosa and Leber's congenital amaurosis. Here, we present a rare case of a retinal astrocytic hamartoma in a child with Best macular dystrophy.

#### Patient consent

Consent to publish this case report has been obtained from the patients legal guardian in writing.

#### Funding

- NIH K08EY026650 (PY)
- Foundation Fighting Blindness Career Development Award CD-

NMT-0714-0648 (PY)

Supported by grant P30 EY010572 from the National Institutes of Health (Bethesda, MD), and by unrestricted departmental funding from Research to Prevent Blindness (New York, NY).”Conflicts of Interest: The following authors have no financial disclosures: SCT, HV, PY.

#### Authorship

All authors attest that they meet the current ICMJE criteria for Authorship.

#### Acknowledgements

None.

#### Appendix A. Supplementary data

Supplementary data to this article can be found online at <https://doi.org/10.1016/j.ajoc.2018.12.009>.

#### References

1. Bitner H, Schatz P, Mizrahi-Meisssonier L, Sharon D, Rosenberg T. Frequency, genotype, and clinical spectrum of best vitelliform macular dystrophy: data from a national center in Denmark. *Am J Ophthalmol*. 2012;154:403–412 e4.
2. Nordstrom S. Hereditary macular degeneration—a population survey in the country of Vsterbotten, Sweden. *Hereditas*. 1974;78:41–62.
3. Davidson AE, Millar ID, Urquhart JE, et al. Missense mutations in a retinal pigment epithelium protein, bestrophin-1, cause retinitis pigmentosa. *Am J Hum Genet*. 2009;85:581–592.
4. Marquardt A, Stohr H, Passmore LA, Kramer F, Rivera A, Weber BH. Mutations in a novel gene, VMD2, encoding a protein of unknown properties cause juvenile-onset vitelliform macular dystrophy (Best's disease). *Hum Mol Genet*. 1998;7:1517–1525.
5. Williams R, Taylor D. Tuberous sclerosis. *Surv Ophthalmol*. 1985;30:143–154.
6. Shields CL, Benevides R, Materin MA, Shields JA. Optical coherence tomography of retinal astrocytic hamartoma in 15 cases. *Ophthalmology*. 2006;113:1553–1557.
7. Yung M, Iafe N, Sarraf D. Optical coherence tomography angiography of a retinal astrocytic hamartoma. *Can J Ophthalmol*. 2016;51:e62–e64.
8. Ulbright TM, Fulling KH, Helveston EM. Astrocytic tumors of the retina. Differentiation of sporadic tumors from phakomatosis-associated tumors. *Arch Pathol Lab Med*. 1984;108:160–163.
9. Bec P, Mathis A, Adam P, Maillard P, Alberge Y. Retinitis pigmentosa associated with astrocytic hamartomas of the optic disc. *Ophthalmologica*. 1984;189:135–138.
10. Ambiya V, Kuppermann BD, Narayanan R. Retinal astrocytic hamartoma in a patient with Leber's congenital amaurosis. *BMJ Case Rep*. 2015;2015.
11. Dhama A, Devi PV, Bhende M. Tuberous sclerosis complex with Best's vitelliform macular dystrophy: a combined presentation. *Indian J Ophthalmol*. 2018;66:295–296.
12. Reeser FH, Aaberg TM, Van Horn DL. Astrocytic hamartoma of the retina not associated with tuberous sclerosis. *Am J Ophthalmol*. 1978;86:688–698.