



NOTE

Internal Medicine

Argyrophilic nucleolar organizer regions staining for cytology smears in dogs and cats

Yu FURUSAWA¹⁾, Masashi TAKAHASHI¹⁾, Mariko SHIMA-SAWA²⁾,
Osamu YAMATO²⁾ and Akira YABUKI^{1,2)*}¹⁾Kagoshima University Veterinary Teaching Hospital, Joint Faculty of Veterinary Medicine, Kagoshima University, 1-21-24 Korimoto, Kagoshima 890-0065, Japan²⁾Laboratory of Veterinary Clinical Pathology, Joint Faculty of Veterinary Medicine, Kagoshima University, 1-21-24 Korimoto, Kagoshima 890-0065, Japan

ABSTRACT. The argyrophilic nucleolar organizer regions (AgNORs) are cellular proliferation markers, crucial for predicting the clinical course and aggressiveness of tumors. The purpose of this study was to establish an easy and practical AgNOR staining method in the cytology of dogs and cats. Air-dried cytological slides were prepared from dogs (n=14) and cats (n=12). Acetone, formalin, ethanol and methanol were tested as fixatives for AgNOR staining. Subsequently, various methods of Romanowsky-based counterstains were tested before and after AgNOR staining. Clear and strong AgNOR spots were observed with all fixatives, and post-May–Grünwald staining was the best counterstaining method. The established method showed clear AgNOR spots even in the long-term storage samples and Romanowsky-stained ones.

KEY WORDS: air-dried smear, argyrophilic nucleolar organizer region, counterstain, cytology, fixation

J. Vet. Med. Sci.

82(9): 1267–1270, 2020

doi: 10.1292/jvms.20-0271

Received: 11 May 2020

Accepted: 27 June 2020

Advanced Epub:

8 July 2020

Nucleolar organizer regions (NORs) are segments containing genes for coding the ribosomal RNA that denote the area of nucleoli formation. They can be visualized by staining their associated proteins with colloidal silver. Argyrophilic NOR (AgNOR) staining is the representative method for detection of NORs in tissue sections [4, 9, 11] and is useful for histopathological prediction of tumor activity [2].

The AgNOR stain can be applied for cytological smears and may be a useful cytological tool to predict the prognosis of malignant tumors in both humans [5, 6, 10, 14] and dogs [1, 7, 8, 15, 16]. The AgNORs in tumor cells were assessed without counterstaining in the previous studies; however, in the cytology of dogs and cats, it is often difficult to accurately interpret the results of AgNOR staining because the tumor and non-tumor cells, such as inflammatory cells, are mixed in a disorderly fashion on the smear. Therefore, to utilize the AgNOR stain in veterinary cytology, an easy and practical AgNOR staining method is required that would retain the cytomorphology for identification of cells while detecting clear AgNORs to evaluate tumor malignancy. In the present study, the optimal AgNOR stain, which was combined with the Romanowsky stain, was established and tested in various settings of cytological samples prepared from dogs and cats.

The present experiments were performed in accordance with the Guidelines for Veterinary Clinical Research of Kagoshima University, Japan (No. KVH190001). Smear slides (fine-needle biopsy, sediment smears from effusions, etc.) were prepared from dogs (n=17) and cats (n=13) with a lymphoproliferative disease diagnosed through histopathology or cytology. The May–Grünwald–Giemsa stain was used for the cytological diagnosis of the samples.

As trial fixatives for AgNOR stain, acetone (1 min, 4°C), 10% neutral-buffered formaldehyde (NBF; 5 min, room temperature), 95% ethanol (5 min, room temperature), and 100% methanol (1 min, 5 min, and 10 min, room temperature) were used, and slides were fixed after thorough drying with cold air. AgNOR staining was performed in accordance with the general protocol [3]. After fixation, slides were briefly washed with distilled water and subsequently incubated with a working solution for 30 min at room temperature in dark. The working solution consisted of one part of 2% gelatin/1% formic acid and two parts of 50% silver nitrate, which were mixed just before use. After incubation, the slides were briefly washed with distilled water.

For counterstaining, a single staining procedure with the May–Grünwald stain (Merck, Darmstadt, Germany), single staining procedure with the Giemsa stain (Merck), and double staining procedure with the May–Grünwald–Giemsa stain were performed. The May–Grünwald stain was diluted two-folds in a 1/150 mol/l phosphate buffer (pH 6.4), while the Giemsa stain was diluted ten-folds in the same buffer. Staining times for the May–Grünwald and Giemsa stains were set at 1, 3, 5, and 10 min. For the double staining procedure, the slides were stained with the May–Grünwald stain for 3 min and subsequently with the Giemsa stain

*Correspondence to: Yabuki, A.: yabu@vet.kagoshima-u.ac.jp

©2020 The Japanese Society of Veterinary Science

This is an open-access article distributed under the terms of the Creative Commons Attribution Non-Commercial No Derivatives (by-nc-nd) License. (CC-BY-NC-ND 4.0: <https://creativecommons.org/licenses/by-nc-nd/4.0/>)

for 10–20 min. This counterstaining procedure was performed before and after AgNOR staining.

The established AgNOR stain was applied for the freeze-stocked samples. The slides were stored at -30°C without fixation after air-drying. The duration of stocking varied from 1 month to 3 years. After removing the slides from the freezer, they were thoroughly air-dried and stained with the established AgNORs stain. In addition, the slides that had been mounted after May–Grünwald–Giemsa staining were stained with the established AgNORs stain. These slides had been stored in a closed box at room temperature and selected from the stock stored for 1 month to 10 years. After removing the coverslips by shaking with xylene, smears were decolorized while exchanging with methanol. Subsequently, the smears were stained with the established AgNORs stain.

As a result, clear and strong AgNOR spots were observed after AgNOR staining with all tested fixatives, and no remarkable differences were seen among the fixatives (Fig. 1). With methanol fixation, different fixation times were tested, and clear AgNOR spots were observed even with the shortest fixation duration of 1 min. These findings were the same for all the samples tested. Since the air-dried and methanol-fixed smears are commonly used for cytology in the veterinary field, methanol was found to be the best fixative for AgNORs. In addition, availability of other fixatives was thought to be meaningful because our recent studies demonstrated that acetone and NBF were optimal fixatives for immunocytochemistry of cytokeratin/vimentin [12] and CD antigens [13], respectively. Since the smear slide used for fluorescence immunocytochemistry can be reused for other stains [12, 13], the established AgNOR stain could possibly be utilized in combination with fluorescence immunocytochemistry.

The optimal counterstaining procedure was explored using smears fixed with methanol. The best results were obtained by short staining with the May–Grünwald stain after AgNOR staining. Staining for 1 and 3 min resulted in good-quality visualization of the cell morphology and clear AgNOR spots of the nuclei (Fig. 2A). In longer 5- and 10-min staining with the May–Grünwald stain, AgNOR spots were difficult to identify in the darkly stained nuclei (Fig. 2B). When the Wright stain (Muto Pure Chemicals, Tokyo, Japan) was used instead of the May–Grünwald stain for some samples, the AgNOR spots could not be visualized clearly because the nuclei were stained darker even for 1 min staining. In Giemsa staining after AgNOR staining, AgNOR spots of the nuclei were unclear despite the short staining time of 1 and 3 min (Fig. 2C). This defective Giemsa staining was observed for reagents from different manufacturers (Muto Pure Chemicals). May–Grünwald–Giemsa staining after AgNOR staining also failed to identify the clear AgNOR spots in the darkly stained nuclei (Fig. 2D). When these stains were applied before the AgNOR stain, the staining intensity of the cytoplasm was very weak, and the cell morphology was difficult to identify even using the double staining procedure with the May–Grünwald–Giemsa stain. These findings were the same for the samples tested, and no differences between dogs and cats were observed. From these findings, a single and short staining procedure with the May–Grünwald stain was regarded as the best counterstaining method to the AgNOR stain. The May–Grünwald stain yields high-quality staining of the cytoplasm and cytoplasmic granules but is not used alone, usually because nuclei are difficult to be stained, making it a suitable counterstain for the AgNOR stain. However, the order of staining has to be correct since May–Grünwald-stained substances are decolorized with AgNOR staining.

Table 1 shows the established AgNOR staining methods. In the freeze-stock samples, this method helped detect clear AgNOR spots of the nuclei with good-quality visualization of the cell morphology obtained from the tested samples, despite a storing time of 3 years (Fig. 3A). Among the samples stored after May–Grünwald–Giemsa staining, the established AgNOR stain helped successfully detect AgNOR spots for the samples that had been stored for less than 1 year (Fig. 3B). The AgNOR spots were clear in the newer samples but could not be detected in the old samples stored for over 1 year. These findings suggested that the established AgNOR stain would also be useful for a retrospective cytological study to clarify the relationship between the quantity of AgNOR and the prognosis of the neoplastic disease.

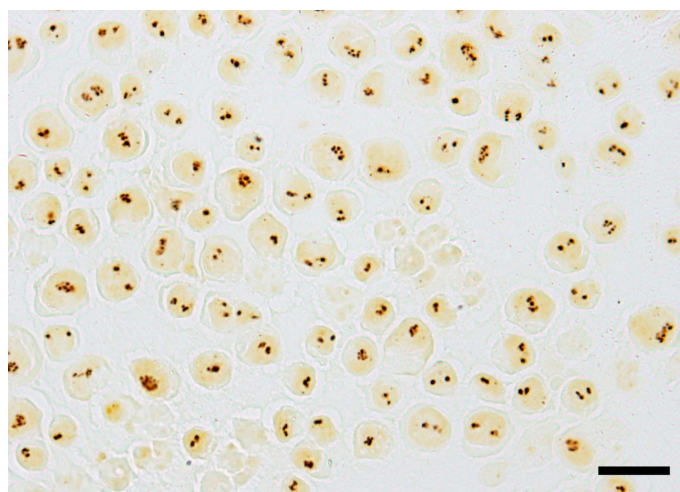


Fig. 1. Argyrophilic nucleolar organizer region staining for the smear fixed with 100% methanol for 1 min. The smear was prepared from the pleural effusion of a cat with mediastinal lymphoma. Bar: 15 μm .

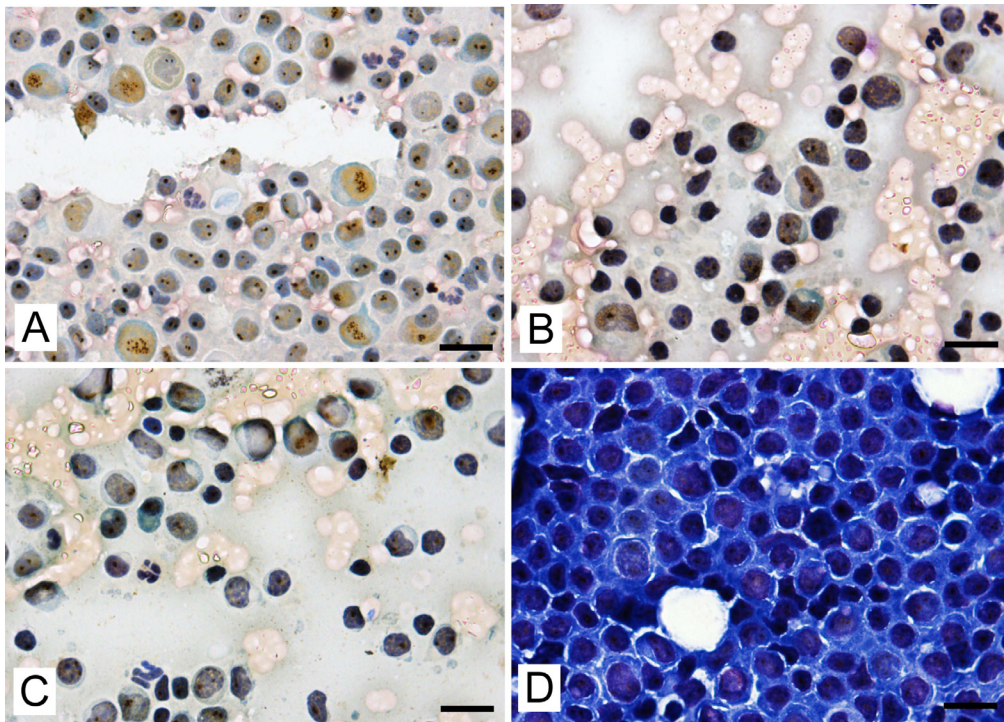


Fig. 2. Findings of the different counterstaining methods after the argyrophilic nucleolar organizer region staining. May–Grünwald staining for 3 (A) and 5 min (B), Giemsa staining for 1 min (C), and May–Grünwald–Giemsa staining in the standard manner (D). A–C: smears from a reactive hyperplastic lymph node of a cat. D: smear from a neoplastic lymph node (lymphoma) of a dog. Bars: 15 μ m.

Table 1. Protocol for the established argyrophilic nucleolar organizer region staining method

Air-drying	Thoroughly
Fixation with 100% methanol	1 min
Staining with a fresh AgNOR solution	30 min
Washing with distilled water	In brief
Counterstaining with the May–Grünwald stain	1–3 min
Washing with distilled water	In brief
Air-drying	
Application of a coverslip	

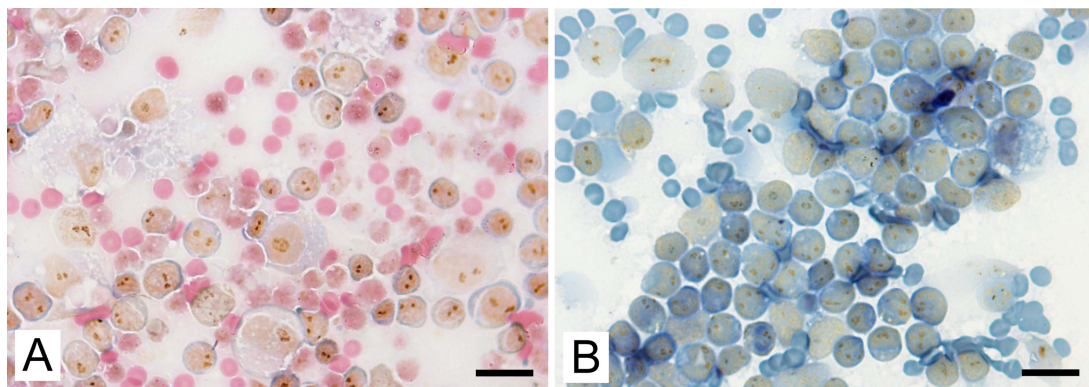


Fig. 3. Findings of the established argyrophilic nucleolar organizer region staining applied for long-term preservation samples. A: smear from the pleural effusion of a cat with mediastinal lymphoma that was directly stocked in the freezer (-30°C) for 3 years after air-drying. B: smear from a reactive hyperplastic lymph node of a cat that was stained with the May–Grünwald–Giemsa stain and stocked in a dark box at room temperature for 1 year. Bars: 15 μ m.

CONFLICT OF INTERESTS. The authors declare that they have no competing interests.

REFERENCES

1. Bauer, N. B., Zervos, D. and Moritz, A. 2007. Argyrophilic nucleolar organizing regions and Ki67 equally reflect proliferation in fine needle aspirates of normal, hyperplastic, inflamed, and neoplastic canine lymph nodes (n = 101). *J. Vet. Intern. Med.* **21**: 928–935. [[Medline](#)]
2. Caldeira, P. C., Aguiar, M. C. F., Mesquita, R. A. and do Carmo, M. A. V. 2011. Oral leukoplakias with different degrees of dysplasia: comparative study of hMLH1, p53, and AgNOR. *J. Oral Pathol. Med.* **40**: 305–311. [[Medline](#)] [[CrossRef](#)]
3. Crocker, J. and Nar, P. 1987. Nucleolar organizer regions in lymphomas. *J. Pathol.* **151**: 111–118. [[Medline](#)] [[CrossRef](#)]
4. Elangovan, T., Mani, N. J. and Malathi, N. 2008. Argyrophilic nucleolar organizer regions in inflammatory, premalignant, and malignant oral lesions: a quantitative and qualitative assessment. *Indian J. Dent. Res.* **19**: 141–146. [[Medline](#)] [[CrossRef](#)]
5. Ferreira, S. J., Machado, M. Â. N., de Lima, A. A. S., Johann, A. C. B. R., Grégio, A. M. T. and Azevedo-Alanis, L. R. 2017. Identification of AgNORs and cytopathological changes in oral lichen planus lesions. *Acta Histochem.* **119**: 32–38. [[Medline](#)] [[CrossRef](#)]
6. Jajodia, E., Raphael, V., Shunyu, N. B., Ralte, S., Pala, S. and Jitani, A. K. 2017. Brush cytology and AgNOR in the diagnosis of oral squamous cell carcinoma. *Acta Cytol.* **61**: 62–70. [[Medline](#)] [[CrossRef](#)]
7. Kiupel, M. and Camus, M. 2019. Diagnosis and prognosis of canine cutaneous mast cell tumors. *Vet. Clin. North Am. Small Anim. Pract.* **49**: 819–836. [[Medline](#)] [[CrossRef](#)]
8. Kravis, L. D., Vail, D. M., Kisseberth, W. C., Ogilvie, G. K. and Volk, L. M. 1996. Frequency of argyrophilic nucleolar organizer regions in fine-needle aspirates and biopsy specimens from mast cell tumors in dogs. *J. Am. Vet. Med. Assoc.* **209**: 1418–1420. [[Medline](#)]
9. Ploton, D., Menager, M., Jeannesson, P., Himber, G., Pigeon, F. and Adnet, J. J. 1986. Improvement in the staining and in the visualization of the argyrophilic proteins of the nucleolar organizer region at the optical level. *Histochem. J.* **18**: 5–14. [[Medline](#)] [[CrossRef](#)]
10. Rao, D. S., Ali, I. M. and Annigeri, R. G. 2017. Evaluation of diagnostic value of AgNOR and PAP in early detection of dysplastic changes in leukoplakia and lichen planus - a preliminary case-control study. *J. Oral Pathol. Med.* **46**: 56–60. [[Medline](#)] [[CrossRef](#)]
11. Rüschoff, J., Plate, K., Bittinger, A. and Thomas, C. 1989. Nucleolar organizer regions (NORs). Basic concepts and practical application in tumor pathology. *Pathol. Res. Pract.* **185**: 878–885. [[Medline](#)] [[CrossRef](#)]
12. Sawa, M., Yabuki, A., Kohyama, M., Miyoshi, N. and Yamato, O. 2018. Rapid multiple immunofluorescent staining for the simultaneous detection of cytokeratin and vimentin in the cytology of canine tumors. *Vet. Clin. Pathol.* **47**: 326–332. [[Medline](#)] [[CrossRef](#)]
13. Sawa, M., Yabuki, A., Setoguchi, A. and Yamato, O. 2015. Development and application of multiple immunofluorescence staining for diagnostic cytology of canine and feline lymphoma. *Vet. Clin. Pathol.* **44**: 580–585. [[Medline](#)] [[CrossRef](#)]
14. Srivastava, A. N., Misra, J. S., Singh, U., Khan, M. and Raza, S. 2019. AgNOR pleomorphic count as a tumor marker in cervical carcinogenesis and feasibility of its introduction in cervical cancer screening programs to discriminate high-risk cases of squamous intraepithelial lesions of the cervix. *Acta Cytol.* **63**: 371–378. [[Medline](#)] [[CrossRef](#)]
15. Vail, D. M., Kravis, L. D., Kisseberth, W. C., Ogilvie, G. K. and Volk, L. M. 1997. Application of rapid CD3 immunophenotype analysis and argyrophilic nucleolar organizer region (AgNOR) frequency to fine needle aspirate specimens from dogs with lymphoma. *Vet. Clin. Pathol.* **26**: 66–69. [[Medline](#)] [[CrossRef](#)]
16. Vajdovich, P., Psáder, R., Tóth, Z. A. and Perge, E. 2004. Use of the argyrophilic nucleolar region method for cytologic and histologic examination of the lymph nodes in dogs. *Vet. Pathol.* **41**: 338–345. [[Medline](#)] [[CrossRef](#)]