



Since January 2020 Elsevier has created a COVID-19 resource centre with free information in English and Mandarin on the novel coronavirus COVID-19. The COVID-19 resource centre is hosted on Elsevier Connect, the company's public news and information website.

Elsevier hereby grants permission to make all its COVID-19-related research that is available on the COVID-19 resource centre - including this research content - immediately available in PubMed Central and other publicly funded repositories, such as the WHO COVID database with rights for unrestricted research re-use and analyses in any form or by any means with acknowledgement of the original source. These permissions are granted for free by Elsevier for as long as the COVID-19 resource centre remains active.



INTERNATIONAL MEDICAL REVIEW ON DOWN SYNDROME

www.elsevier.es/sd



CASE REPORTS

Community-acquired pneumonia in adults with Down syndrome. Three clinical cases and a review of the literature

J. A. Hermida Pérez^{a,b,*} and J. S. Hernandez Guerra^c

^aCommunity and Family Medicine, Universidad de Las Palmas de Gran Canaria, Gran Canaria, Spain

^bEmergency Department of Los Llanos de Aridane, Santa Cruz de Tenerife, Spain

^cSpecialist in Community and Family Medicine, Health Centre of Villa de Mazo, Santa Cruz de Tenerife, Spain

Received on May 4, 2010; accepted on June 1, 2010

KEYWORDS

Adult pneumonia;
Down syndrome

Abstract

John Langdon Down first described this genetic disorder known today as Down syndrome (DS), due to a trisomy of chromosome 21. The frequent appearance of respiratory infections in DS is attributed to structural and functional anomalies of the respiratory system, the presence of congenital heart malformations and IgG deficits.

We present three clinical cases of adult DS patients with community-acquired pneumonia, and a review of the literature regarding: epidemiology, prevalence, symptomatology, laboratory and radiographic findings, morbidity, mortality, clinical evolution and the importance of prevention of pneumonia in DS patients. These patients presented symptoms of acute infection of the lower respiratory tract: high fever, scanty productive cough with or without sputum, pleuritic chest pain, dyspnea, fatigue, myalgia, and other atypical symptoms. Chest radiography showed focal inflammatory condensation in the affected lung and bilateral alveolo-interstitial infiltrate. Laboratory tests showed increased values of leukocytes and C-reactive protein, deficiency of IgG and low lymphocyte CD4+.

Patients with DS are highly susceptible to lower and higher respiratory tract infection. Community physicians should take exceptional precautions on detecting respiratory symptoms in these patients, since they may result in pneumonia and bronchopneumonia. Presentation may be atypical and the complications may even lead to mortality.

© 2010 Fundació Catalana Síndrome de Down. Published by Elsevier España, S.L. All rights reserved.

*Author for correspondence.

E-mail: hermidana@yahoo.es (J. A. Hermida Pérez).

PALABRAS CLAVE

Neumonía en adultos;
Síndrome de Down

Neumonía adquirida en la comunidad en pacientes adultos con síndrome de Down. Presentación de tres casos clínicos y revisión de la literatura

Resumen

John Langdon Down fue el primero en describir el cuadro clínico de esta alteración genética caracterizada por trisomía del cromosoma 21, también conocida como síndrome de Down (SD). La frecuente aparición de infecciones respiratorias en el SD se atribuye a numerosas anomalías estructurales y funcionales, a la presencia de malformaciones congénitas cardíacas y a déficits de IgG.

Se presentan tres casos clínicos de pacientes adultos con SD que padecieron una neumonía adquirida en la comunidad y se realiza una revisión bibliográfica considerando los aspectos epidemiológicos, la prevalencia, el cuadro clínico, los datos de laboratorio y los radiológicos, la morbimortalidad, la evolución y la importancia de la prevención. Estos pacientes pueden presentar síntomas de infección aguda del aparato respiratorio bajo, como fiebre alta, tos con o sin expectoración, dolor torácico por irritación pleural, disnea, fatiga, mialgias, así como otros síntomas atípicos. La radiografía de tórax puede mostrar un foco de condensación inflamatoria en un pulmón, o un infiltrado alveolointersticial bilateral. La analítica de sangre puede mostrar leucocitosis, aumento de la proteína C reactiva, deficiencia de IgG y de los linfocitos CD4+.

Los pacientes con SD son altamente susceptibles a padecer infecciones respiratorias del tracto superior como del inferior. Los médicos deben tener especial precaución ante la presencia de síntomas respiratorios en estos pacientes, ya que en muchas ocasiones pueden desarrollar neumonías y bronconeumonías que se presentan de forma atípica y con complicaciones que se acompañan de alta mortalidad.

© 2010 Fundació Catalana Síndrome de Down. Publicado por Elsevier España, S.L. Todos los derechos reservados.

Introduction

Down syndrome (DS) is named after Dr. John Langdon Down who first described it¹ and is the most frequent cause of mild-moderate mental retardation as well as other medical problems. It occurs in 1 out of every 800 births, in all races and socioeconomic levels. DS is due to a chromosomal abnormality caused by an error in cell division that results in the presence of a third chromosome, constituting a trisomy of chromosome 21.

Community-acquired pneumonia (CAP)

CAP is defined as an infection of the alveoli, distal airways and lung interstitium that occurs outside the hospital. It is clinically characterised by fever, chills, cough, pleuritic chest pain, expectoration and minimal lung opacity on chest x-ray. CAP presents in five different patterns: lobar pneumonia (covers a pulmonary lobe), bronchopneumonia (scattered areas of consolidation over several lobes), interstitial pneumonia (with inflammation in the interstitium, including the alveolar wall and connective tissue surrounding the bronchovascular tree) and miliary pneumonia (numerous small lesions originating from haematogenous spread)².

CAP diagnosis

The most frequent symptoms of CAP include cough, fever, chills, fatigue, dyspnea and pleuritic chest pain. Depending

on the causative pathogen, the patient may have persistent and/or dry cough, with or without expectoration. Other symptoms may include headache and myalgia. Certain aetiologic agents, such as *Legionella*, produce gastrointestinal symptoms.

At physical examination, the patient may present with dull chest percussion, crepitant rales during auscultation, bronchophony, egophony and fremitus. The patient may also be tachypneic³.

No characteristic radiographic patterns have been shown that forecast the aetiology of pneumonia. However, some studies suggest that differences can be established, for example, pneumonias with homogeneous consolidation are less common in infections of *Mycoplasma pneumoniae*, *Chlamydia pneumoniae* and respiratory viruses. Additionally, multilobar pneumonia and the presence of pleural effusion are more frequent in bacteremic pneumococcal infection⁴.

Aetiopathogenesis of CAP**Causative pathogens and routes of entry**

These are represented by *Streptococcus pneumoniae* (approximately 50% of all CAP cases that require hospitalisation) as well as by *Haemophilus influenzae*, *Staphylococcus aureus*, *M. pneumoniae*, *C. pneumoniae*, *Moraxella catarrhalis*, Gram-negative aerobic bacteria, as well as anaerobic organisms and Gram-negative bacilli (*Mycobacterium tuberculosis*), aerosolised pathogens

(*Legionella*), and pathogens disseminated haematogenically (*S. aureus* from endocarditis) or disseminated by contiguity with other organs. Viral agents such as influenza virus, adenovirus, respiratory syncytial virus and other rare microorganisms such as: Hantavirus, Nipah virus, Hendra virus, Metapneumovirus, acute respiratory distress syndrome virus, and non-viral microorganisms: fungal (*Pneumocystis*) agents acquired for bioterrorism (anthrax), Q fever, tularemia, plague, etc.⁵.

Aetiopathogenic factors of CAP include micro and macro aspirations of oropharyngeal secretions colonised with pathogenic microorganisms (*S. pneumoniae*, *H. influenzae*), especially in patients with central nervous system disorders, consciousness alterations (alcoholism, drug addiction through parenteral administration), anaesthetized endotracheal intubation, the virulence of the germ (encapsulated organisms, which include *S. pneumoniae*, *H. influenzae*, *Neisseria meningitidis*), the host's condition: immunosuppression, multiple myeloma, nephrotic syndrome, noting that pneumococcal CAP is particularly common among HIV-positive patients².

Patients with DS are very likely to respiratory tract infections, particularly during the first two years of life although they can also suffer such infections at older ages. Among the determining factors are their immune deficiencies⁶.

The presentation of our three clinical cases aims to aware health professionals who treat patients with DS of the importance of being alert to the respiratory infection profiles in these patients, given the high risk of developing pneumonia and its associated high mortality/morbidity rate.

Clinical observations

Case 1

Male, 44 years old, with DS and epilepsy. He visited the emergency service due to respiratory difficulty, fever, coughing and pain in the right hemithorax, 5 days after onset of symptoms. The physical examination revealed an anxious patient with dry skin and mucous; cardiac auscultation: tachycardia, systolic murmur grade II/IV more audible in the mitral area; respiratory auscultation: decreased respiratory sounds at the base of the right lung, with crepitations at that level, no cyanosis, and no tachypnea. Vital signs: blood pressure (BP), 110/60 mmHg; heart rate (HR), 112/min; O₂Sat, 95%; temperature, 38,2 °C; cardiac output (CO), 109 mg/dl. In chest X-rays, the AP and lateral views revealed a condensation focus in the right lower lung lobe compatible with right basal pneumonia (Figure 1). He was referred to a hospital where he was admitted. The blood test showed leukocytosis of $13.7 \cdot 10^3/\mu\text{l}$ with 78% polymorphonuclear neutrophils, 13% lymphocytes, 6% monocytes, 1% eosinophils; haemoglobin, 14.1 g/dl; platelets: $359 \cdot 10^3/\mu\text{l}$; globular sedimentation rate (VSG), 44 mm; C-reactive protein (CRP), 1.2 mg/dl; negative tuberculin test, sputum culture for bacteria, negative BAAR and fungi; immunoglobulins: IgG, 632.0 mg/dL, with normal IgA and IgM, normal CD4+ lymphocyte count, negative serology for *Mycoplasma pneumoniae*, *Chlamydia psittaci*,

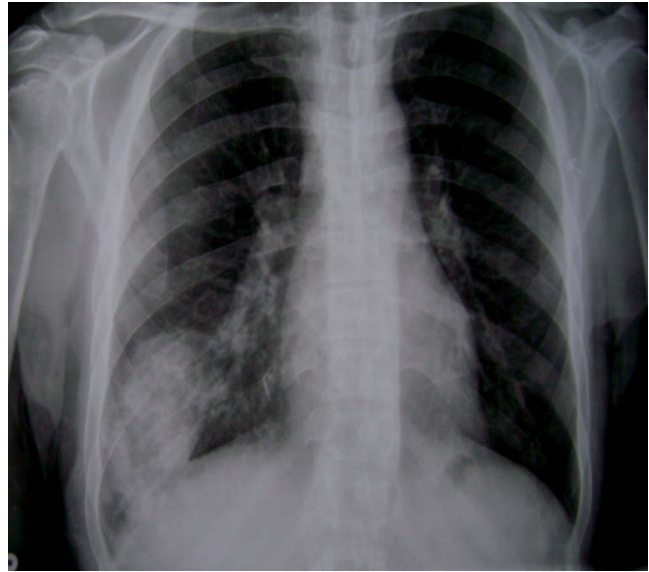


Figure 1 Case 1. Antero-posterior chest X-ray: image of inflammatory condensation in the lower lobe of the right lung consistent with right basal pneumonia.

Chlamydia pneumoniae and *Coxiella burnetti*. After 12 days of hospitalisation and treatment with wide spectrum antibiotics, the patient was discharged and referred to his family doctor.

Case 2

Male, 47 years old, DS, hypothyroidism, hepatic steatosis, hypercholesterolemia, frequent episodes of psychomotor agitation, previous history of bronchitis and pneumonia. He visited the emergency service for cough with yellow expectoration, high fever and dyspnea after having outpatient treatment for 10 days with azithromycin 500 mg/24 h/4 days, moxifloxacin 400 mg/24 h/6 days, acetylcysteine 600 mg/24 h, bronchodilators and inhaled corticosteroids for respiratory infection, without improvement. Physical examination showed tachypnea, no cyanosis, somewhat dry skin and mucous, soft abdomen, no tenderness during palpation, no visceromegalies, no tumours, no signs of peritoneal irritation; cardiac auscultation: tachycardia; respiratory auscultation: subcrepitant rales and dispersed hoarse rales. Constants: BP, 80/42 mmHg; HR, 109/min; respiratory frequency (RF), 28/min; temperature, 39.5 °C; O₂Sat, 91%; BG, 114 mg/dl. In the AP and lateral chest x-ray: bilateral alveolar-interstitial infiltrates, more pronounced in the right lung, with inflammatory lesions in the lower and middle lobes (Figure 2). The electrocardiogram showed sinus tachycardia. The patient was admitted to hospital where he remained for 10 days. Blood analysis: leukocytes, $13.7 \cdot 10^3/\mu\text{l}$; haemoglobin, 15.4 g/dl; platelets, $359 \cdot 10^3/\mu\text{l}$; VSG, 48 mm; CRP, 1.15 mg/dL; coagulogram and normal D-dimer; Na, 118 mmol/l; arterial blood gases: FiO₂, 0.4; pH, 7.40; PCO₂, 38; PO₂, 65; CO₃H, 24; O₂Sat, 93%. Negative tuberculin test, sputum culture for bacteria, negative BAAR and fungi; immunoglobulins: IgM and reduced IgG; IgM, 55.7 mg/dl

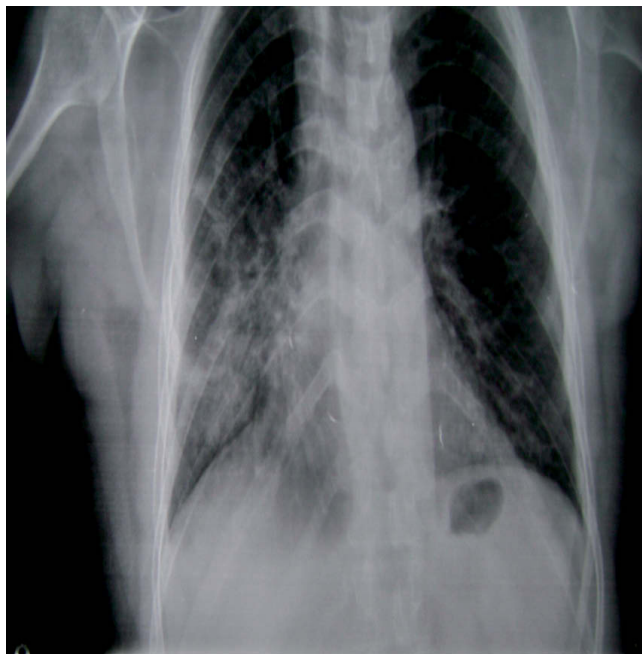

Figure 2 Case 2. Antero-posterior chest X-ray: bilateral alveolar-interstitial infiltrates, more pronounced in the right lung, with inflammatory lesions in the lower and middle lobes.

(60-280); IgG, 714.0 mg/dl (800-1,800); lowered CD4+ lymphocytes, serology for *Mycoplasma pneumoniae*, *Chlamydia psittaci*, *Chlamydia pneumoniae* and *Coxiella burnetii* IgM negative.

The patient was diagnosed with CAP, respiratory failure and hyponatremia. A broad-spectrum antifungal antibiotic treatment was indicated, which evolved favourably resulting in the patient's discharge after 10 days.

Case 3

Male, 45 years of age, with DS and hypercholesterolemia. He visited the emergency service reporting general malaise, arthralgia, myalgia, cephalgia, productive cough, high fever and chills. Physical examination showed good skin and mucous colour, good hydration, hyperemic pharynx, soft abdomen, not tender, no visceromegalies, no peritoneal reaction, respiratory auscultation: slightly decreased vesicular murmur in both lungs, no rales; cardiac auscultation: tachycardia. Vital signs: BP, 100/60; HR, 115/min; O₂ Sat, 94%; BG, 104 mg/dl; temperature, 39 °C. AP and lateral chest x-ray: condensation in the periphery of the middle lobe of the left lung (Figure 3). He is admitted to hospital, where a blood test was taken: leukocytes, 12.3 10³/μl; VSG, 36 mm; CRP, 1.8; coagulogram and D-dimer, normal; Na, 137 mmol/l; arterial blood gases: FiO₂, 0.4; pH, 7.32; PCO₂, 31; PO₂, 65; CO₃H, 24; O₂ Sat, 93%; normal urine analysis; negative tuberculin test. Sputum culture for bacteria, BAAR and fungi: negative. Negative serial blood cultures. Evaluation of immunoglobulin (IgM, IgG and IgA) was normal. Normal CD+ lymphocytes. Negative serology for *Mycoplasma pneumoniae*, *Chlamydia psittaci*, *Chlamydia pneumoniae* and *Coxiella burnetii*. The patient was diagnosed with CAP. After treatment with wide spectrum antibiotics, the

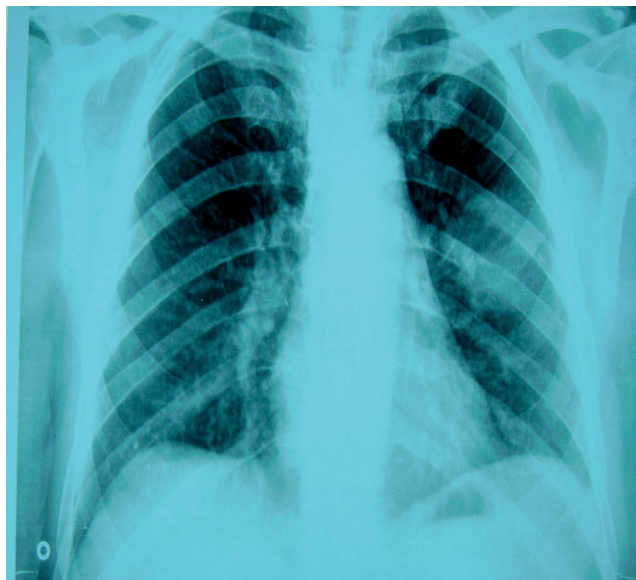

Figure 3 Case 3. Antero-posterior chest x-ray: image of condensation in the periphery of the middle lobe of the left lung.

patient had a favourable clinical evolution and was discharged and referred to his family doctor.

Discussion

Prevalence of CAP in patients with DS

Pirez et al⁷ studied 697 children hospitalised with CAP and observed that DS was one of the associated conditions (12 children, 1.72%), surpassed by neurological diseases that impact the respiratory function (29 children, 4.16%) and congenital heart defects (22 children, 3.15%).

In another study involving 109 patients with DS, it was observed that respiratory infections affected 61 patients (55.96%), upper respiratory tract infections occurred more often in children under 1 year, associating with congenital heart defects in 34 patients (31.42%), 19 patients (31.15%) suffered from bronchopneumonia, 6 (9.83%) from bronchitis and 2 (3.30%) from pneumonia⁸.

Diagnosis of CAP in patients with DS

In the general population, a patient that complains of fever (>37.8 °C), cough, sputum production, tachypnea (>25 breaths/min), myalgia and night sweats, in the absence of odynophagia and rhinorrhea, would most likely have CAP². This clinical predictor model has a sensitivity of 91% and a specificity of 40%. If we analyse the clinical features from such patients, this model could include populations with DS⁹.

A study conducted in 19 Canadian hospitals for a 6 month period is representative of the usefulness of blood culture for diagnosis of pneumonia. The percentage of positive blood cultures was only 6.2% and the authors observed no influence on the severity of the CAP. Another prospective study showed

that blood cultures were positive in 10.5% of patients with CAP. After analysing different outcomes, the various clinical guidelines recommend blood cultures for patients hospitalised with CAP, but not in outpatients, which results were negative. Hence its value has been questioned¹⁰.

CAP due to *Mycoplasma pneumoniae* is associated with high morbidity and mortality in patients with DS, as shown in cases reported by Orlicek et al¹¹. These authors describe clinical and radiological features of CAP in three children affected with DS and who developed high fever, productive cough, chills, irritability and tachypnea. The chest x-ray showed bilateral infiltrates and the patients developed respiratory distress, which required hospital admission. Laboratory studies showed infection by *Mycoplasma pneumoniae*. Mycoplasma infection in these children may be serious because patients with DS have immune disorders. With children that have DS and who suffer from pneumonia, one must consider this microorganism as a possible aetiological agent. Corretger et al⁶ published a case of a patient with DS who developed severe pneumonia with *Mycoplasma pneumoniae* as the aetiological agent.

There are also reports in the literature of pneumonia cases caused by *Bordetella bronchiseptica* in patients with DS. This germ is responsible for tracheobronchitis, bronchopneumonia, rhinitis and otitis media in animals. It colonises the animals' upper respiratory tract and oropharynx, rarely infecting humans, and may cause subacute endocarditis and mild pertussis in children. It has also been described in immunocompromised patients as a cause of sepsis peritonitis, bronchitis and pneumonia¹².

Patients with DS who have immune deficiencies tend to develop pneumonia from unusual microorganisms^{6,7,12}, including viral agents. One study describes a case of pneumonia caused by human coronavirus (HCoVs)-OC43 in a child with DS and leukaemia who developed fever and leukopaenia. Both the recently discovered HCoVs NL63 or HKU1 and the prototype HCoV-OC43 and HCoV-229E strains are considered respiratory pathogens in immunocompromised paediatric patients with cancer¹³.

These patients may also develop fungal pneumonia, according to the publication of a case with pneumonia and pleural effusion caused by *Aspergillus* in a two-year-old Japanese child with DS¹⁴.

Evaluation of the factors associated with recurrent pneumonia and respiratory infections in patients with DS

Immunosuppression

Ribeiro et al¹⁵ studied patients with DS who suffered from recurrent respiratory infections, evaluating the epidemiological, clinical and laboratory aspects as well as the immune status of these patients. They examined the distribution by gender (1.6 male:1 female) and the age distribution (from 1 year to 12 years and 10 months). Congenital cardiopathies were present in 62.2% of the patients, who developed recurrent pneumonia. The immunologic evaluation showed 2 cases with IgG2 deficiency, 2 with CD4+ lymphocyte deficiency, 5 cases had reduced function of NK cells and 22 of the 36 cases analysed (61.1%) were positive for cytomegalovirus. The authors

concluded that the deficiency of the immune response must be taken into account patients with DS, as it makes them more vulnerable to infections as compared to the general population.

Other authors found deficits in serum immunoglobulins, namely IgG¹⁶.

Structural and functional abnormalities of the respiratory system

The frequent occurrence of respiratory infections is due to the presence of structural and functional abnormalities in the respiratory system, which is typical in children with DS, including: reduction of the anteroposterior diameter of the nasopharynx, which inhibits adequate drainage¹⁷, poor development of the sinuses and nasal mucosa; decreased ciliary activity for keeping the nasal mucosa clean, as well as the MHC presence, which predisposes the child to pulmonary vascular congestion with subsequent bronchial congestion¹⁷.

Cardiac diseases

Congenital cardiac disease are considered a risk factor of respiratory infections in patients with DS (7, 8). Approximately 40% of newborns present with congenital cardiac disease. During adolescence and early adulthood, heart valve defects may appear, the most common of which is the mitral valve prolapse¹⁸, which occurred in one of our patients (Case 2).

Oropharyngeal aspiration

Weit et al¹⁹ stated that pneumonia is significantly associated with bronchial asthma, gastroesophageal reflux, DS, history of lower respiratory infections, productive cough, and supplemental oxygen therapy. In this study, the authors concluded that the effect of oropharyngeal aspiration in the development of pneumonia should be considered a risk factor.

Foreign body aspiration

A case was published of a 39-year-old male patient with DS who was admitted to hospital due to lower left lobe pneumonia with 2 months evolution, resistant to wide-spectrum antibiotic treatment. After CT scan, bronchoscopy and biopsy for suspected bronchial carcinoma, a diagnosis was achieved of a foreign body in the distal left main bronchus²⁰.

Other causes

Along with the previously mentioned factors, the mental retardation and craniofacial dysmorphism that these patients have increase their likelihood to respiratory infections²¹.

Mortality and morbidity

Dyce Gordon et al⁸, in their study of respiratory infections in children with DS (n = 93), reported 16 deaths (14.67%), which mostly occurred during the first years of life and were caused by bronchopneumonia associated with congenital heart disease. No published series were found on pneumonias in adult patients with DS.

Differential diagnosis

Patients with SD are immunodeficient and commonly suffer from respiratory infections. Two children were evaluated for recurrent pneumonia with persistent radiographic infiltrate. In both cases, the radiological abnormalities were due to Morgagni hernias. Therefore, when a child with DS presents images of persistent radiographic infiltrate, the possibility of diaphragmatic defects must be considered²².

Prevention

Immunisations

Healthy children with DS should receive routine vaccines as other children. However, the immunological and morphological characteristics of children with DS and the severity and recurrence of these infections justifies the recommendation of certain selective immunisations, which include pneumococcal vaccination. The obvious causal role of pneumococcus in these processes suggests that a particular attention must be paid to its prevention and, consequently, there is interest in administering a conjugate pneumococcal vaccine, even in newborns.

We must also keep the influenza vaccination in mind. Abnormalities have been documented in the immune response of children with DS to the influenza virus. Its role in promoting otitis media and bacterial bronchopulmonary superinfections has been well demonstrated. The preventive value of the influenza vaccination on these infectious pathologies takes particular importance in patients with DS, whose immunogenicity is demonstrated.

The scope of these recommendations is universal, although they may be influenced by local variations in the immunisation schedule. Just as there is no single vaccination schedule for the Spanish state, there is no uniform version for the population with DS. Synchronising the guidelines for both situations is a desirable objective²³⁻²⁵.

The American Academy of Pediatrics through its Committee on Infectious Diseases, the Spanish Association of Pediatrics and the Standards Committee of the Spanish Society of Neonatology have drawn recommendations for the prevention of respiratory infections due to respiratory syncytial virus (RSV), which is increasingly frequent. Because some of the infant population with DS falls within the population at risk as defined by these bodies, one must consider taking measures to prevent this infection, both hygienic and immunoprophylaxis with palivizumab (R), which have managed to lower the number of patients infected with RSV²⁶.

References

- Down JL. Observations on an ethnic classification of idiots. Lond Hosp Rep. 1866;3:259-62.
- Marrie TJ, Campbell GD, Walker DH, et al. Pneumonia. En: Kasper DL et al, editors. Harrison's Principles of Internal Medicine, 16th ed. México FD: The McGraw-Hill Companies Interamerican Editors; 2005. p. 1690-1700.
- Nawal Lutfiyya M, Henley E, Chang LF. Diagnosis and treatment of community-acquired pneumonia. Am Fam Physician. 2006;73:442-50.
- Macfarlane JT, Miller AC, Roderick Smith WH, Morris AH, Rose DH. Comparative radiographic features of community acquired Legionnaires' disease, pneumococcal pneumonia, mycoplasma pneumonia, and psittacosis. Thorax. 1984;39:28-33.
- Ngeow Y, Suwanjutha S, Chantarojanasri T, Wang F, Saniel M, Alejandria M, et al. An Asian study on the prevalence of atypical respiratory pathogens in community-acquired pneumonia. Int J Infect Dis. 2009;9:144-53.
- Corretger JM, Bartrons J. Neumonía grave por *Mycoplasma pneumoniae* en el síndrome de Down. Revista Médica Internacional sobre el Síndrome de Down. 2000;4:33-43.
- Pirez MC, Berrondo C, Giacometti M, et al. Neumonía bacteriana adquirida en la comunidad en niños hospitalizados. Arch Pediatr Urug. 2003;74:6-14.
- Dyce Gordon E, Betharte Sotomayor Y, Dyce Gordon B. Infecciones respiratorias en niños con síndrome de Down. Revista Archivo Médico de Camagüey. 1997;1:1025-55.
- Diehr P, Wood RW, Bushyhead J, Krueger L, Wolcott B, Tompkins RK. Prediction of pneumonia in outpatients with acute cough, a statistical approach. J Chronic Dis. 1984;37:215-25.
- Mandell LA, Bartlett JG, Dowell SF, et al. Infectious Diseases Society of America. Update of practice guidelines for the management of community-acquired pneumonia in immunocompetent adults. Clin Infect Dis. 2003;37:1405-33.
- Orlicek SL, Walker MS, Kuhis TL. Severe *Mycoplasma pneumoniae* in young children with Down syndrome. Clin Pediatr (Phila). 1992;31:409-12.
- Jeffrey L, Winters BS, William N, et al. Bordetella bronchiseptica pneumonia in a patient with Down syndrome: A case report and review. Pediatrics. 1992;89:1262-5.
- Simon A, Völz S, Fleischhack G, et al. Human coronavirus OC43 pneumonia in a pediatric cancer patient with Down syndrome and acute lymphoblastic leukemia. J Pediatr Hematol Oncol. 2007;29:432-4.
- Fumi M, Yoshikawa, Tetsushi Y, Ayano F, et al. Pneumonia with marked pleural effusion caused by aspergillus infection. Pediatr Infect Dis J. 2006;25:186-7.
- Ribeiro LM, Jacob CM, Pastorino AC, et al. Evaluation of factors associated with recurrent and/or severe infections in patients with Down's syndrome. J Pediatr (Rio J). 2003;79:141-8.
- Lok RK, Harth SC, Thong YH, et al. Immunoglobulin G subclass deficiency and predisposition to infection in Down's syndrome. Pediatr Infect Dis J. 1990;547-51.
- Nelson W, Vaughan V, Mckoy J. Tratado de pediatría. 6.ª ed. Barcelona: Salvat; 1975. p. 115-7.
- McElhinney DB, Straka M, Goldmuntz E, et al. Correlation between abnormal cardiac physical examination and echocardiographic finding in neonates with Down syndrome. Am J Med Genet. 2002;113:238-41.
- Weir K, McMahon S, Barry L, et al. Oropharyngeal aspiration and pneumonia in children. Pediatr Pulmonol. 2007;42:1024-31.
- Müller R, Schmidt M, Müller KM, et al. Aspiration pneumonia caused by vertebrae of a dove in a 39 year old patient with Down syndrome. Pneumologie. 1999;53:360-3.
- Borbolla L. Un tema de actualidad: El síndrome de Down. Rev Cubana Pediatr. 1988;60:1078-87.
- Picard E, Ben Nun A, Fisher D, et al. Morgagni hernia mimicking pneumonia in Down syndrome. J Pediatr Surg. 2007;42:1608-11.
- Comité Asesor de Vacunas. AEP. Manual de Vacunas en Pediatría. Edición 2001. Madrid: Litofinter; 2001. p. 443-5.
- Rogers PT, Coleman M. Atención médica al síndrome de Down. Barcelona: Fundació Catalana Síndrome de Down; 1994.
- Gruber WC. Children as a target for immunization. En: Nicholson KG, Webster RG, Hay AJ, editors. Textbook of influenza. Oxford: Blackwell Science; 1998. p. 435-44.
- Flórez Beledo J, Figueras Aloy J. Infecciones respiratorias por el virus respiratorio sincitial: prevención en el síndrome de Down. Revista Síndrome de Down 2006: Revista española de investigación e información sobre el Síndrome de Down. 2006;89:45-50.