

# Anti-M Alloimmunization: Management and Outcome at a Single Institution

Bethany Stetson, MD<sup>1</sup> Scott Scrape, MD<sup>2</sup> Kara Beth Markham, MD<sup>1</sup>

<sup>1</sup>Division of Maternal Fetal Medicine, Department of Obstetrics and Gynecology, The Ohio State University Wexner Medical Center, Columbus, Ohio

<sup>2</sup>Department of Pathology, The Ohio State University Wexner Medical Center, Columbus, Ohio

Address for correspondence Bethany Stetson, MD, Division of Maternal Fetal Medicine, Department of Obstetrics and Gynecology, The Ohio State University Wexner Medical Center, 395 W 12th Avenue, Fifth Floor, Columbus, OH 43210 (e-mail: Bethany.stetson@osumc.edu).

Am J Perinatol Rep 2017;7:e205–e210.

## Abstract

**Objective** The objective of this study was to review the management strategies and outcomes in gravidas with anti-M alloimmunization over 15 years.

**Study Design** Data collected from 195 pregnant patients with anti-M antibodies from July 2000 through June 2016 were reviewed retrospectively. We analyzed indirect antiglobulin test titer results, paternal or fetal/neonatal M antigen status, antepartum course, and perinatal outcomes.

**Results** Anti-M antibodies were found in 146 women and 195 pregnancies. Among those with positive indirect antiglobulin tests, 193 pregnancies had titers at or below 1:4. Only one patient with an initial low titer experienced a more than twofold increase to a titer 1:64. Two women underwent an amniocentesis and cordocentesis. Ninety-five (73.6%) of the 129 infants tested were positive for the M antigen. Nine infants required phototherapy. There were no cases of hemolytic disease of the fetus or newborn, mild or severe.

**Conclusion** The incidence of severe hemolytic disease of the newborn due to anti-M is extremely low. We found no cases in our review of 195 pregnancies, despite several cases of severe hemolytic disease of the newborn reported in the literature. We have created an algorithm for the management of anti-M antibodies in pregnancy based on our data and extensive literature review.

## Keywords

- ▶ alloimmunization
- ▶ anti-M
- ▶ antibody
- ▶ hemolytic disease of the fetus and newborn

Despite routine antepartum and postpartum immunoglobulin prophylaxis, rhesus (RhD) alloimmunization remains a frequent cause of hemolytic disease in a newborn, and ABO incompatibility the most common. Although severe hemolytic disease of the fetus and newborn (HDFN) is most commonly the result of maternal incompatibility with paternally derived fetal RhD antigen, more than 60 different red cell antibodies have been identified and associated with HDFN.<sup>1</sup> For example, a national first-trimester screening program in the Netherlands found that non-RhD antibodies occurred in 1 in 304 pregnancies.<sup>2</sup>

Hemolytic disease of the fetus occurs only in the setting of immunoglobulin class G (IgG) maternal antibodies. Immu-

noglobulin class M (IgM) antibodies exist as pentamers that are too large to cross the placenta. Anti-M antibodies usually exist as common, naturally occurring cold IgM agglutinins and are thus clinically insignificant. Although uncommon, IgG anti-M alloantibodies can occur, and these have been identified as a very rare cause of severe HDFN.<sup>3</sup> Only nine pregnant women with clinically significant fetal disease have been reported in the English literature, including only one in the United States at The Ohio State University.<sup>4–12</sup> Conversely, in a series of almost 400 cases of anti-M detected during first-trimester screening in the Netherlands, there was no conversion to an IgG response and therefore no associated HDFN.<sup>1</sup>

received  
May 2, 2017  
accepted after revision  
August 15, 2017

DOI <https://doi.org/10.1055/s-0037-1607028>.  
ISSN 2157-6998.

Copyright © 2017 by Thieme Medical Publishers, Inc., 333 Seventh Avenue, New York, NY 10001, USA.  
Tel: +1(212) 584-4662.

License terms



Approximately 76% of the population carries the M antigen and is capable of producing children with this antigen. However, 21% of the Caucasian population and 26% of the African American population lacks the M antigen, and these individuals are capable of producing anti-M antibodies when exposed to the antigen.<sup>13</sup> The true incidence of anti-M antibodies in the population is difficult to determine. Given the paucity of data regarding the occurrence of HDFN and the relative frequency of anti-M antibodies in the pregnant population, this study was designed to evaluate the management and outcomes in pregnant women with anti-M alloimmunization at our institution. A similar study was published from our institution in 1997, but that data preceded the use of middle cerebral artery (MCA) Doppler monitoring in routine management of red blood cell alloimmunization.<sup>14,15</sup> Our goal here is therefore to update the literature with our experience using modern management techniques. Furthermore, we also sought to compare our outcomes to the most current experience reported in the literature.

## Materials and Methods

The Ohio State University Alloimmunization Program has maintained a database of pregnancies affected by alloimmunization since 1959. A retrospective review was performed including 146 women with a total of 195 pregnancies complicated by anti-M alloimmunization at The Ohio State University Wexner Medical Center (OSU) from July 2000 through June 2016. The review was limited to the inclusion of completed pregnancies managed during a time period in which MCA Doppler assessment was employed as part of the protocol for managing red blood cell alloimmunization. Patients received care in prenatal clinics at OSU, private practices affiliated with the university, and referral hospitals throughout central and southeastern Ohio. Patient information was reviewed in the alloimmunization program database, electronic medical records, and hospital charts for the mother and neonate.

Data collected included maternal demographics, indirect antiglobulin test titers, pregnancy outcomes including gestational age at delivery, and paternal M antigen status when available. Fetal ultrasound records were also reviewed as indicated. In regard to the neonate, direct antiglobulin tests (DATs) and M antigen status of the newborn were recorded when available. Neonatal outcomes were also analyzed, including gestational age at delivery, hemoglobin and bilirubin levels, and the need for phototherapy or transfusions. Institutional Review Board approval was obtained prior to data collection.

To determine maternal antibody screen, standard techniques endorsed by the AABB, (formerly known as the American Association of Blood Banks) were performed using gel column agglutination methods. The standard technique used in the laboratory at OSU during the study period was an anti-IgG antihuman globulin (AHG) phase reaction using Ortho ProVue Analyzer and Ortho Vision Analyzer (Ortho Clinical Diagnostics, Raritan, NJ). If the gel antibody screen is negative, no further evaluation is performed. If the antibody screen is positive at the AHG phase, an attempt is made to manually

identify the antibody in gel using multiple methods including tube testing using low-ionic saline solution enhancement, which help resolve difficult antibody identifications. Our laboratory does not perform any antibody screening or identification at immediate spin or room temperature.

We followed a tiered approach to management of pregnancies complicated by red blood cell alloimmunization. Patients were followed in our alloimmunization database when determined to have red blood cell antibodies regardless of the titer. If anti-M was identified with a titer  $\leq 1:8$ , we recommended obtaining a repeat titer at 28 weeks. If a titer of  $\geq 1:16$  was identified or the patient endorsed a concerning obstetric history, serial titers (every 4 weeks) were recommended. Although a critical titer of  $\geq 1:32$  was used for the majority of red blood cell antibodies at OSU, we initiated MCA Doppler assessment in the setting of anti-M titers of  $\geq 1:64$ . Cordocentesis was then reserved for cases with titers  $\geq 1:64$  and elevated MCA Doppler peak systolic velocity (PSV) values. Confidence intervals on proportion were performed when applicable.

In addition to evaluating our outcomes at OSU, the relevant English language literature was also reviewed using a computerized search of the MEDLINE database. The search terms used were anti-M, alloimmunization, hemolytic disease, neonatal, and fetal. Forty-one articles were initially identified; 7 were excluded due to non-English language, 12 were excluded for content not related to this study, and 1 was excluded due to analysis of coexisting anti-M and anti-RhD alloimmunization. After reference review of the remaining 21 articles, we found 8 additional relevant articles totaling 29 articles that were ultimately included for analysis.

## Results

Anti-M antibodies were identified in 146 women and 195 pregnancies being followed in the alloimmunization program at OSU throughout the study period. Of the 146 women, their ethnicity was 107 (73%) white, 27 (18%) black, 4 (3%) Asian, 2 (1%) Hispanic, and 6 (4%) other. The indirect antiglobulin titers were  $\leq 1:2$  in 187 (95.9%) (confidence interval [CI]: 0.92–0.97) of these pregnancies. Only one patient experienced an increase in the indirect antiglobulin titer of two dilutions or more. Among the 95 pregnancies with known M antigen positive fetuses/neonates, there was no increase in the indirect antiglobulin titers during the gestations (CI: 0.41–0.45). Of the 23 fathers who underwent testing for M antigen status, 4 (17.4%) were M negative indicating no fetal risk of HDFN. There was one case of nonpaternity identified through testing.

The outcomes of pregnancies with indirect antiglobulin titers of  $\geq 1:4$  are shown in **Table 1**. Only one of the patients with elevated titers (patient 1) was found to have an M antigen positive fetus/neonate, this patient was also noted to have a titer rise from 1:1 to 1:4 at 28 weeks' gestation, but no further work-up was needed and neonate had a negative DAT. Cordocentesis procedures were performed in two patients. The first patient (patient 8) had an indirect antiglobulin titer of 1:64 with elevated MCA Doppler PSV values

**Table 1** Outcome of patients with indirect antiglobulin titer >1:2

Patient number	Indirect antiglobulin	GA at delivery (wk)	M antigen	DAT	Lowest hemoglobin (g/dL)	Highest total bilirubin (g/dL)
1	4	34	+	–	16.8	15.8
2	4	39	–	–	UK	UK
3	4	38 <sup>3/7</sup>	UK	–	UK	UK
4	4	38 <sup>2/7</sup>	UK	–	UK	UK
5	4	38 <sup>5/7</sup>	UK	+	UK	UK
6	8	40 <sup>4/7</sup>	–	–	UK	UK
7	8	38 <sup>3/7</sup>	UK	UK	UK	UK
8	64	37	–	–	UK	UK

Abbreviations: DAT, direct antiglobulin test; GA, gestational age; UK, unknown.

>1.5 multiples of the median. Fetal blood sampling revealed a fetal hemoglobin of 12 g/dL, and the fetus was determined to be M antigen negative; therefore, no neonatal work-up was indicated. The second patient was referred to OSU with an indirect antiglobulin titer of only 1:1 (thus not shown in **Table 1**), but with elevated MCA Doppler PSV values obtained by an outside provider. The patient was followed with serial MCA Doppler assessment weekly for 3 weeks at OSU, with persistently elevated PSV values noted. The patient was counseled about her options for either continued expectant management or definitive evaluation via cordocentesis. The patient opted for cordocentesis, which revealed a fetal hemoglobin of 12 g/dL in an M antigen positive fetus. These results were felt to be consistent with falsely elevated MCA Doppler testing. The infant at delivery had a positive DAT of 1:1 and ultimately required phototherapy, but the hyperbilirubinemia may have been due to ABO compatibility.

Ninety-five (73.6%) of the 129 infants tested were positive for the M antigen (CI: 0.65–0.8), but only 11 of these neonates (11.6%) had a positive DAT at delivery (CI: 0.05–0.1). Of those infants who were M positive with a positive DAT, four required phototherapy. Sixty-two of the M antigen positive neonates had a negative DAT, four of whom required phototherapy. In total, there were nine neonates whose mothers had low anti-M titers who required phototherapy for other indications. There were no cases of hemolytic disease of the fetus or newborn, mild or severe.

## Comment

Based on our institutional review of 195 maternal pregnancies affected by anti-M alloimmunization, there were no cases of clinically significant HDFN. If we include the addition of our previously published series of 115 cases from 1969 to 1995,<sup>15</sup> a total of 310 pregnancies with anti-M antibodies have been managed at OSU in nearly 50 years without any cases of clinically significant HDFN. This is congruent with the current literature, indicating that the incidence of severe HDFN due to anti-M is extremely rare.

We also reviewed the literature regarding anti-M alloimmunization in pregnancy (**Table 2**). Nine studies were identified

with reports of nine women with pregnancies complicated by severe hemolytic disease of the fetus. The patients therein reported a history of recurrent pregnancy loss and/or intrauterine fetal demise potentially explained by the maternal antibody status and/or they required intrauterine transfusion (IUT), plasmapheresis, or intravenous immunoglobulin (IVIG) for attempted fetal salvage.<sup>4–12</sup> The first case of severe HDFN attributed to anti-M alloimmunization in the English literature was reported by MacPherson et al in 1961 at OSU.<sup>10</sup> The patient reported a history of multiple pregnancy losses in the setting of an anti-M titer of 1:2,048, with a confirmed M antigen positive fetus in one of these gestations and a subsequent successful pregnancy with delivery of an M antigen negative neonate. Although HDFN due to anti-M alloimmunization is not frequently reported in the literature, this complication may be more common in certain populations. For example, a literature review of Japanese publications by Yasuda et al identified 34 cases of HDFN, 6 with evidence of fetal hemolytic disease.<sup>16</sup> Of reported cases of fetal hemolytic anemia, the lowest maternal titer was 1:8, and the authors suggested that the Japanese population may have increased sensitivity to anti-M antibodies due to genetic factors that may affect the immune response to erythrocyte alloantigens.<sup>16</sup> This theory has not been substantiated in the transfusion literature. In addition to the review by Yasuda et al, 13 studies were identified in the literature with reports of severe hemolytic disease of the newborn based on a requirement for neonatal IVIG, red blood cell transfusion, or exchange transfusion.<sup>4,12,16–26</sup> Conversely, several studies report pregnancies complicated by anti-M alloimmunization without associated HDFN.<sup>2,15,27–30</sup> Notably, HDFN did not occur in approximately 400 patients with anti-M antibodies in the Netherlands and our previously reported 115 pregnancies in the United States.<sup>2,15</sup> Although there are a small number of cases of HDFN reported in the literature, these studies and the data supported here suggest a very rare incidence of fetal anemia due to anti-M alloimmunization.

In a recent study at the Johns Hopkins University, anti-M antibodies were found to be the second most common non-RhD antibody identified in pregnant woman.<sup>30</sup> Given this frequency, a protocol for management of affected pregnancies is required. Management recommendations have

**Table 2** Literature review

Author	Relevant history	Maximum indirect antiglobulin titer	DAT	Antenatal intervention	Outcomes
Fetal hemolytic disease					
Lin et al <sup>12</sup> (Taiwan)	N/A	1:32	N/A	Plasmapheresis, IVIG, IUT	Hydrops fetalis with an IUFD at 19 wk. Fetal antigen status not reported
Wikman et al <sup>4</sup> (Sweden)	N/A	1:1	–	IUTs in the setting of hydrops fetalis	Liveborn neonate
Seo et al <sup>5</sup> (Korea)	N/A	UK	UK	IUTs in the setting of hydrops fetalis	Liveborn neonate
Furukawa et al <sup>6</sup> (Japan)	History of recurrent pregnancy loss	1:4,096	+	Biweekly plasmapheresis	Liveborn neonate treated with phototherapy
Bajpayee et al <sup>7</sup> (India)	History of 6 pregnancy losses (11–32 wk of gestation)	1:32	–	IUTs in the setting of hydrops fetalis	Liveborn neonate treated with phototherapy
Kanra et al <sup>8</sup> (Turkey)	N/A	1:512	UK	No	History of seven pregnancy losses. Five of these fetuses with hydrops fetalis resulting in three IUFDs and two neonatal demises
Stone and Marsh <sup>11</sup> (UK)	N/A	1:1,000	+	No	Twin delivery: one fetus deceased and grossly hydropic at delivery, surviving neonate anemic and jaundiced with a requirement for exchange transfusion
Matsumoto et al <sup>9</sup> (Japan)	N/A	1:1,024	UK	No	Three third trimester IUFDs attributed to anti-M alloimmunization, no laboratory confirmation of HDFN diagnosis
MacPherson et al <sup>10</sup> (US)	N/A	1:2,048	UK	No	Four IUFDs, one fetus proven to be M antigen positive. Subsequent liveborn neonate proven to be negative for the M antigen
Yasuda et al <sup>16</sup> (Japan)	N/A	As low as 1:8			34 cases of HDFN including 6 cases of fetal disease
Newborn hemolytic disease					
Arora et al <sup>17</sup>	N/A	1:16	–/–	No	Twin gestation, both neonates requiring transfusions
Freiesleben and Jensen <sup>18</sup>	N/A	1:1	UK	No	Mild HDFN
Duguid and Bromilow <sup>19</sup>	N/A	1:16	+	No	Exchange transfusion and phototherapy
Thompson et al <sup>20</sup>	N/A	UK	–	No	Transfusion
Hinchliffe et al <sup>21</sup>	N/A	UK	UK	No	Transfusion
Lin et al <sup>12</sup>	N/A	1:4	+	No	Transfusion
Ishida et al <sup>22</sup>	N/A	1:16	–	No	IVIG and transfusion
Sharma et al <sup>23</sup>	N/A	1:32	+	No	Exchange transfusion

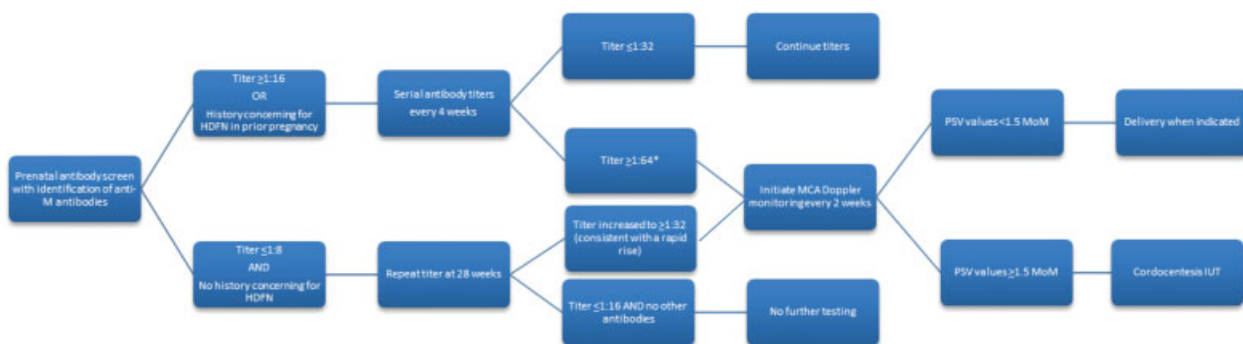
**Table 2** (Continued)

Author	Relevant history	Maximum indirect antiglobulin titer	DAT	Antenatal intervention	Outcomes
Kanra et al <sup>24</sup>	N/A	1:8	–	No	Transfusion
Yoshida et al <sup>25</sup>	N/A	1:4	–	No	IVIg
Wikman et al <sup>4</sup>	N/A	1:1	–	No	Exchange transfusion
Duro et al <sup>26</sup>	N/A	UK	–By “tube” +By “gel”	No	Exchange transfusion
Yasuda et al <sup>16</sup>	N/A	As low as 1:8			34 cases of HDFN including 6 cases of fetal disease
No clinically significant disease					
Gagliardo and Curiano <sup>27</sup>	N/A	1:32	–	No	Healthy neonate
Melartin and Kaarsalo <sup>28</sup>	N/A	1:13	+	No	Healthy neonate
Bowley et al <sup>30</sup>	N/A	1:128	+	No	Healthy neonate
Bowley et al <sup>30</sup>		1:2	+	No	Healthy neonate
Bowman <sup>29</sup>	N/A	N/A	N/A	N/A	82 pregnancies without clinically significant HDFN
Koelewijn et al <sup>2</sup>	N/A	N/A	N/A	N/A	~400 pregnancies without clinically significant HDFN
De Young-Owens et al <sup>15</sup>	N/A	N/A	N/A	N/A	115 pregnancies without clinically significant HDFN

Abbreviations: HDFN, hemolytic disease of the fetus and newborn; IUFD, intrauterine fetal demise; IUT, intrauterine transfusion; IVIG, intravenous immunoglobulin; N/A, not available; UK, unknown.

previously included serial amniotic fluid delta OD450 determinations analyzed using the Liley curve, serial MCA Doppler assessment in all patients due to the possibility of variable expression of disease at a given titer, and performance of MCA Doppler assessment only in patients with antibody titers  $\geq 1:64$ .<sup>31</sup> Based on our cumulative experience, we present our proposed management of anti-M in **Fig. 1**. In the setting of a low anti-M titer of  $< 1:8$  without a history of prior pregnancy complications suggesting a hemolytic process, we recommend against serial titers or automatic MCA Doppler assessment. However, we routinely recheck an indirect antiglobulin titer at approximately 28 weeks to evaluate for emergence of other alloantibodies or IgG con-

version. In rare cases with an elevated initial titer  $\geq 1:16$  or a concerning obstetrical history, we recommend performing serial titers every 4 weeks with initiation of MCA Doppler assessment in the setting of rapidly rising titers and/or an elevated titer  $\geq 1:64$ . Paternal M antigen testing and even amniocentesis for fetal M antigen testing may also play a role in these situations. We reserve cordocentesis and possible IUT for women with increased MCA PSV values, recognizing an approximately 12% false-positive rate with this technique.<sup>32</sup> Pediatricians and the institution’s blood bank should be notified at delivery of the maternal alloimmunization history and potential for HDFN. These recommendations are similar to those adopted by clinicians in the Netherlands



**Fig. 1** Proposed anti-M pregnancy management. HDFN, hemolytic disease of the fetus and newborn; IUT, intrauterine transfusion; MCA, middle cerebral artery; PSV, peak systolic velocity.

where repeat laboratory testing is performed in weeks 24, 30, and 36 to evaluate for a potential conversion to IgG antibodies.<sup>2</sup> Based on the technical manual by the AABB, in the setting of a <1:1 titer, further evaluation to distinguish IgM from IgG using dithiothreitol is not indicated.<sup>13</sup>

We recognize the limitations of this retrospective study including the potential for a sampling bias. However, given our large referral and university-based practice, we believe that our data are generalizable. This is currently the largest study in the United States evaluating antenatal and neonatal outcomes in pregnancies complicated by anti-M alloimmunization. We did not identify any cases of clinically significant HDFN at our institution during the last half-century, including the 15-year period presented here. Based on these data and the literature in general, the management strategy presented here should minimize unnecessary testing and procedures in the majority of women with anti-M antibodies while still identifying those at risk for HDFN.

#### Note

This study was approved by IRB 2015H0436 and was presented as poster presentation #192 at the 37th Annual Society for Maternal Fetal Medicine Meeting on January 26, 2017, in Las Vegas, NV.

#### Conflict of Interest

The authors report no conflict of interest.

#### References

- Moise KJ Jr, Argoti PS. Management and prevention of red cell alloimmunization in pregnancy: a systematic review. *Obstet Gynecol* 2012;120(05):1132–1139
- Koelwijn JM, Vrijkotte TG, van der Schoot CE, Bonsel GJ, de Haas M. Effect of screening for red cell antibodies, other than anti-D, to detect hemolytic disease of the fetus and newborn: a population study in the Netherlands. *Transfusion* 2008;48(05):941–952
- Klein HG, Anstee DJ. *Mollison's Blood Transfusion in Clinical Medicine*, 12 ed. Chichester, West Sussex, United Kingdom: John Wiley and Sons, Inc.; 2014
- Wikman A, Edner A, Gryfelt G, Jonsson B, Henter JI. Fetal hemolytic anemia and intrauterine death caused by anti-M immunization. *Transfusion* 2007;47(05):911–917
- Seo MW, Won HS, Kim SK, et al. Successful treatment of fetal erythroblastosis due to anti-M alloimmunization with fetal intravascular transfusion. *Prenat Diagn* 2007;27(04):385–387
- Furukawa K, Nakajima T, Kogure T, et al. Example of a woman with multiple intrauterine deaths due to anti-M who delivered a live child after plasmapheresis. *Exp Clin Immunogenet* 1993;10(03):161–167
- Bajpayee A, Dubey A, Sonker A, Chaudhary RK. A case of severe foetal anaemia due to anti-M isoimmunisation salvaged by intrauterine transfusions. *Blood Transfus* 2014;12(Suppl 1):s302–s304
- Kanra T, Yüce K, Özcebe IU. Hydrops fetalis and intrauterine deaths due to anti-M. *Acta Obstet Gynecol Scand* 1996;75(04):415–417
- Matsumoto H, Tamaki Y, Sato S, Shibata K. A case of hemolytic disease of the newborn caused by anti-M: serological study of maternal blood. *Acta Obstet Gynaecol Jpn* 1981;33(04):525–528
- MacPherson CR, Christiansen MJ, Newton WA Jr, Wheeler WE, Zartman ER. Anti-M antibody as a cause of intrauterine death. Report of two stillbirths resulting from anti-M antibody. *Am J Clin Pathol* 1961;35:31–35
- Stone B, Marsh WL. Haemolytic disease of the newborn caused by anti-M. *Br J Haematol* 1959;5:344–347
- Lin TH, Shih JC, Lin CH, Lin SY, Su YN, Lee CN. Intraperitoneal and intracardiac transfusion of recurrent fetal erythroblastosis due to anti-M alloimmunization with unfavorable outcome. *Taiwan J Obstet Gynecol* 2012;51(02):253–255
- Fung MK, Grossman BJ, Hillyer CD, Westhof CM. *Core Principles in Cellular Therapy*, 18th ed. Bethesda, MD: AABB; 2014:viii, 96
- Mari G, Deter RL, Carpenter RL, et al; Collaborative Group for Doppler Assessment of the Blood Velocity in Anemic Fetuses. Noninvasive diagnosis by Doppler ultrasonography of fetal anemia due to maternal red-cell alloimmunization. *N Engl J Med* 2000;342(01):9–14
- De Young-Owens A, Kennedy M, Rose RL, Boyle J, O'Shaughnessy R. Anti-M isoimmunization: management and outcome at the Ohio State University from 1969 to 1995. *Obstet Gynecol* 1997;90(06):962–966
- Yasuda H, Ohto H, Nollet KE, et al. Hemolytic disease of the fetus and newborn with late-onset anemia due to anti-M: a case report and review of the Japanese literature. *Transfus Med Rev* 2014;28(01):1–6
- Arora S, Doda V, Maria A, Kotwal U, Goyal S. Maternal anti-M induced hemolytic disease of newborn followed by prolonged anemia in newborn twins. *Asian J Transfus Sci* 2015;9(01):98–101
- Freiesleben E, Jensen KG. Haemolytic disease of the newborn caused by anti-M. The value of the direct conglutination test. *Vox Sang* 1961;6:328–335
- Duguid JK, Bromilow IM. Haemolytic disease of the newborn due to anti-k. *Vox Sang* 1990;58(01):69
- Thompson DJ, Stults DZ, Daniel SJ. Anti-M antibody in pregnancy. *Obstet Gynecol Surv* 1989;44(09):637–641
- Hinchliffe RF, Nolan B, Vora AJ, Stamps R. Neonatal pure red cell aplasia due to anti-M. *Arch Dis Child Fetal Neonatal Ed* 2006;91(06):F467–F468
- Ishida A, Ohto H, Yasuda H, et al. Anti-M antibody induced prolonged anemia following hemolytic disease of the newborn due to erythropoietic suppression in 2 siblings. *J Pediatr Hematol Oncol* 2015;37(06):e375–e377
- Sharma D, Murki A, Murki S, Pratap T. Anti-M antibodies as a cause of intrauterine fetal death and neonatal hyperbilirubinaemia. *BMJ Case Rep* 2014;2014(14):bcr2014203534
- Kanra T, Erdem G, Tekinalp G, Gürgey A, Yigit S, Dogru D. Further hemolytic disease of the newborn caused by anti-M. *Am J Hematol* 1996;53(04):280–281
- Yoshida H, Yoshida Y, Konishi Y, Iwai Y, Asoh T, Tatsumi K. Hemolytic disease of the newborn due to anti-M. *Nippon Ketsueki Gakkai Zasshi* 1984;47(04):888–895
- Duro EA, Desalvo L, Kuret S. Severe hemolytic disease of the newborn caused by anti-m antibodies. *Iran J Pediatr* 2013;23(05):607–608
- Gagliardo FJ, Curiano RR. A rare form of anti-M antibody associated with pregnancy. *Tech Bull Regist Med Technol* 1963;33:198–200
- Melartin L, Kaarsalo E. Anti-M antibody developed during pregnancy. *Scand J Haematol* 1965;2(03):183–186
- Bowman JM. Treatment options for the fetus with alloimmune hemolytic disease. *Transfus Med Rev* 1990;4(03):191–207
- Bowley CC, Dunsford I. The agglutinin anti-M associated with pregnancy; report on two cases. *Br Med J* 1949;2(4629):681
- Smith HM, Shirey RS, Thoman SK, Jackson JB. Prevalence of clinically significant red blood cell alloantibodies in pregnant women at a large tertiary-care facility. *Immunohematology* 2013;29(04):127–130
- Mari G, Norton ME, Stone J, et al; Society for Maternal-Fetal Medicine (SMFM). Electronic address: pubs@smfm.org. Society for Maternal-Fetal Medicine (SMFM) Clinical Guideline #8: the fetus at risk for anemia—diagnosis and management. *Am J Obstet Gynecol* 2015;212(06):697–710