

Available online at www.sciencedirect.com

ScienceDirect

journal homepage: www.elsevier.com/locate/radcr

Case Report

Recurrent breast cancer diagnosis delayed by COVID-19 pandemic ☆,☆☆

Hanna K. Thompson, BS^a, Paul J. Spicer, MD^{b,*}

^aUniversity of Louisville School of Medicine, Louisville, Kentucky, USA

^bDepartment of Radiology, University of Kentucky School of Medicine, Lexington, Kentucky, USA

ARTICLE INFO

Article history:

Received 18 February 2021

Revised 2 April 2021

Accepted 2 April 2021

Available online 8 April 2021

Keywords:

Ductal carcinoma in situ (DCIS)

Invasive ductal carcinoma (IDC)

COVID-19

ABSTRACT

We describe the case of a 65-year-old female with a history of left-sided ductal carcinoma in situ in 2008. Mammography in January 2020 demonstrated calcifications in the previously affected breast. Subsequent stereotactic biopsy results were benign. In the months that followed, the patient experienced breast changes but avoided returning to the facility as the COVID-19 pandemic worsened. In August of 2020, the patient returned for a repeat mammogram, which indicated 2 suspicious masses in the left breast. Further analysis through ultrasound-guided core biopsy ultimately led to a left mastectomy and lymph node biopsy, which were performed in September 2020. Pathology results revealed multifocal invasive ductal carcinoma stage IIB.

© 2021 The Authors. Published by Elsevier Inc. on behalf of University of Washington.

This is an open access article under the CC BY-NC-ND license

(<http://creativecommons.org/licenses/by-nc-nd/4.0/>)

Case report

A 65-year-old female presented in January 2020 for routine screening mammography. She had a history of ductal carcinoma in situ (DCIS) of the left breast in 2008, treated with lumpectomy, radiation, and a 4-year course of Tamoxifen. The Tamoxifen treatment was intended to reduce the risk of recurrence, however it was halted prematurely due to the patient's intolerance of the side effects. Medical records state that her DCIS was estrogen receptor-positive (ER+) and progesterone receptor-negative (PR-). The grade is unknown; however, the inclusion of radiation in her treatment plan indicates it was likely high-grade. After her initial diagnosis, the patient un-

derwent annual mammography, which showed longitudinal stability of postoperative changes and tissue density. No additional relevant medical history was noted. Since the patient is adopted, no family history is available.

Her mammogram revealed new coarse heterogeneous calcifications 7 cm from the nipple in the inferomedial quadrant of the left breast (Fig. 1A-B). The postlumpectomy changes of the breast were stable at this time. These findings were assessed as BI-RADS category 4B: Moderate suspicion for malignancy. Supplemental screening ultrasound was not offered, as it is not available at the facility and is not required in the state. A stereotactic biopsy was performed later that month and indicated proliferative fibrocystic changes, fibroadenomatoid hyperplasia, and benign calcifications. The patient was

☆ We have no conflicts of interest to disclose.

☆☆ Competing interest: The authors have no declarations of interests relevant to this case report.

* Corresponding author at: HX315 A B Chandler Medical Center, 800 Rose Street, Lexington, KY 40536, USA.

E-mail address: paul.spicer4@uky.edu (P.J. Spicer).

<https://doi.org/10.1016/j.radcr.2021.04.003>

1930-0433/© 2021 The Authors. Published by Elsevier Inc. on behalf of University of Washington. This is an open access article under the CC BY-NC-ND license (<http://creativecommons.org/licenses/by-nc-nd/4.0/>)

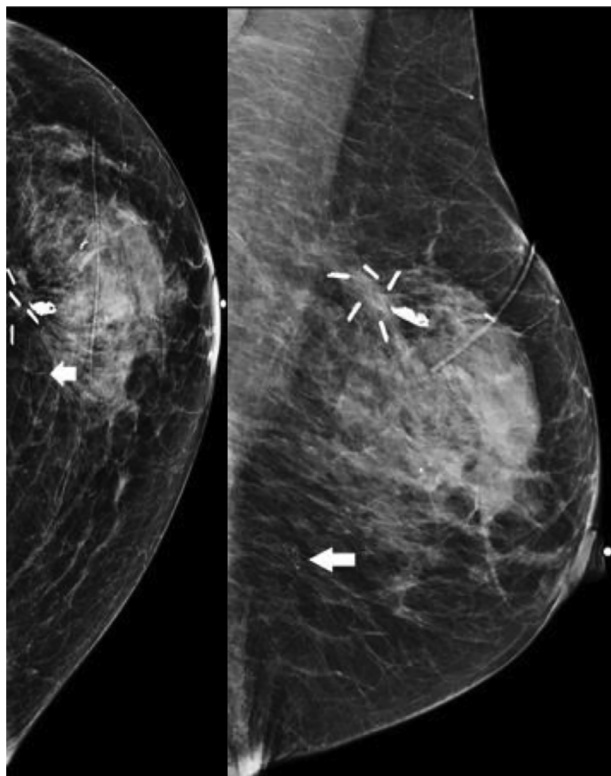


Fig. 1 – A-B: CC and MLO diagnostic mammography views from January 2020 demonstrate coarse heterogeneous calcifications in the lower inner quadrant, 7 cm from the nipple (arrow). BIRADS 4B – stereotactic core biopsy recommended.

scheduled to return for a repeat mammogram in 6 months based upon the benign pathology result.

In May 2020, the patient noticed shrinking and hardening of the left breast. Concerned about the ongoing COVID-19 pandemic, the patient chose not to return to the medical facility for reevaluation and instead attributed these breast changes to complications stemming from the stereotactic biopsy performed in January.

The patient returned in August 2020 for a 6-month follow-up mammogram which demonstrated new architectural distortion measuring 15 mm in diameter, at 1:00 in the superomedial quadrant of the left breast 4 cm from the nipple (Fig. 2A-B), distant from the site of the biopsy performed in January. A breast ultrasound indicated an irregular, shadowing mass with angular and spiculated margins ($3.1 \times 1.1 \times 3$ cm) correlating to the area of architectural distortion identified by mammography (Fig. 3A-B). This scan also demonstrated an additional $1.5 \times 1.5 \times 0.9$ cm oval, irregular mass with angular margins in the same breast quadrant, at 3:00 3 cm from the nipple (Fig. 4). The 3 axillary lymph nodes identified on ultrasound had a benign appearance.

An ultrasound-guided core biopsy was performed on the 2 masses identified. Both masses were interpreted as invasive ductal carcinoma (IDC) grade 2. Immunohistochemistry revealed that both tumors were ER+ 95%, PR-, and HER 2

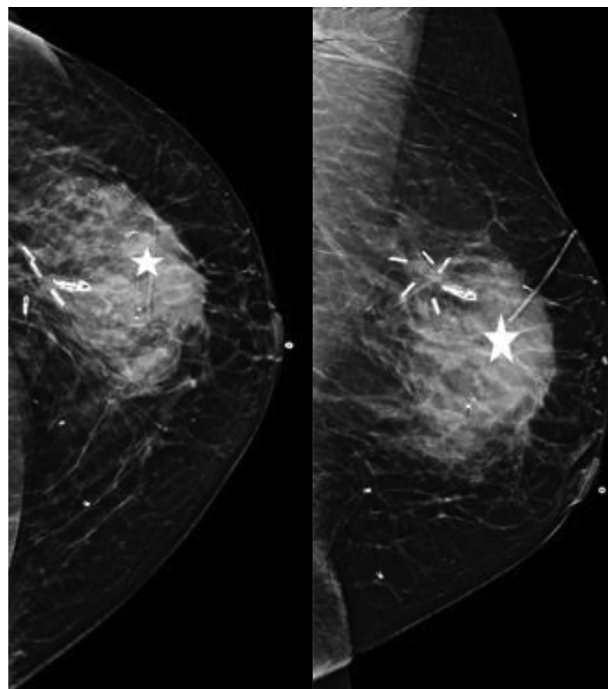


Fig. 2 – A-B: Follow-up CC and MLO diagnostic mammography views from August 2020 revealed a 15 mm area of architectural distortion at 1:00 4 cm from the nipple (star). Additionally, the area of architectural distortion is much denser as compared to the similar area on the January 2020 exam. Finally, the breast has decreased in size relative to the prior exam.

oncogene-negative (Her2-). As the larger mass fell between 20 and 50 mm, the primary tumor was classified as T2.

The patient underwent a left mastectomy with biopsies of 4 sentinel lymph nodes in September 2020. In the absence of symptoms of advanced metastasis (Mo), more comprehensive imaging studies were not performed in congruence with the guidelines of the National Comprehensive Cancer Clinic [1]. Micrometastasis was observed in 1 of the 4 lymph nodes (N1mi). Biopsy pathology and the biomarker results confirmed a diagnosis of multifocal IDC stage IIB (pT2mN1miMo). Adjuvant chemotherapy was initiated (TC—docetaxel with cyclophosphamide). An aromatase inhibitor was also prescribed for adjuvant endocrine therapy.

Discussion

DCIS occurs when malignant epithelial cells spread within the mammary ducts. Proliferation beyond the ducts results in IDC. While the incidence of DCIS increased with the advent of screening to make up 32.5 per 100,000 women in 2004, IDC maintained a higher incidence of 124.3 per 100,000 women [2]. One-in-ten women treated for DCIS will later develop recurrent DCIS or IDC in the same breast, as occurred in the patient profiled in this case study [3]. DCIS grade can predict future IDC. In 2 cohorts of DCIS patients, the low-grade group had a

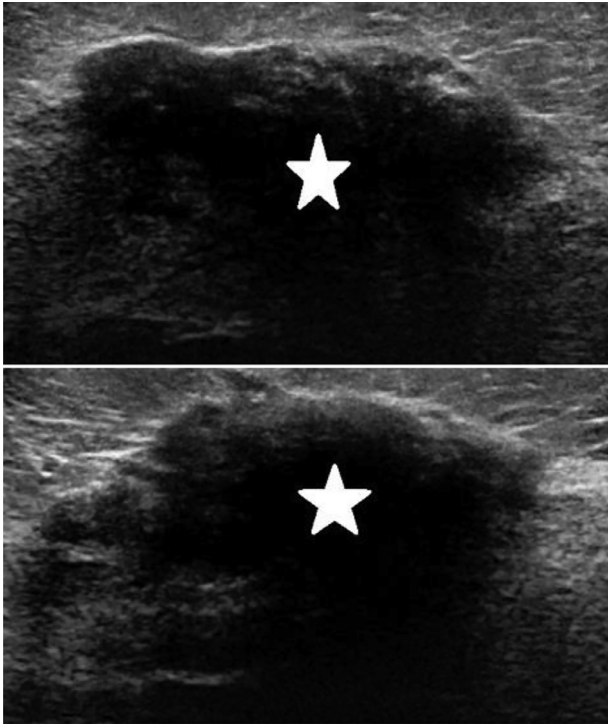


Fig. 3 – A-B: Radial and antiradial ultrasound images in August 2020 demonstrate an irregular, shadowing mass (star) with angular and subtle, spiculated margins at 1:00 4 cm from the nipple measuring 3.1 × 1.1 × 3.3 cm. This correlated with the mammographic finding, was given a BI-RADS 5 assessment, and ultimately underwent ultrasound-guided core biopsy.

12-year invasive local recurrence rate of 7.5% while the high-grade group had a rate of 13.4% [4].

While DCIS and IDC may be first detected by screening, IDC may also present with appreciable breast changes. These include thickened, dimpled, or reddened breast skin, nipple discharge or pain, and palpable lumps in the breast or axilla [5]. Multifocal IDC is traditionally defined as separate tumors within a breast quadrant, while multicentric IDC typically refers to tumors separated by normal tissue and unconfined to a single quadrant. As many studies do not distinguish between the 2, the incidence of multifocal IDC appears to range from 6% to 60% [6].

Following imaging, biomarker analysis, and biopsy pathology, surgical removal of the IDC tissue may proceed. In multifocal IDC, the noncancerous tissue from the affected breast has a higher likelihood of being able to be conserved [7]. Docetaxel and cyclophosphamide (TC) are the standard adjuvant therapy for early-stage, HER- IDC [8]. Patients additionally prescribed aromatase inhibitors have demonstrated approximately 40% lower breast cancer 10-year mortality rates than those not treated with endocrine therapy [9].

After a state of emergency was declared in the United States in March of 2020, many outpatient health care facilities closed to divert resources to the COVID-19 crisis. Individuals postponed elective screening due to concerns about the virus. Screening mammography rates dropped by as much as

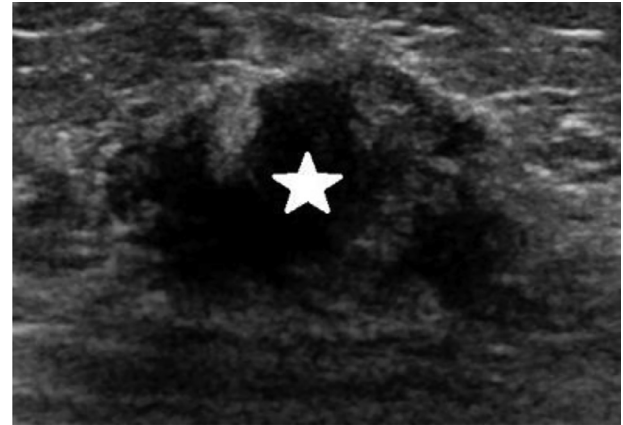


Fig 4 – Also in August 2020, an additional oval, irregular mass with angular margins (star) was noted at 3:00 3 cm from the nipple measuring 1.5 × 0.9 × 0.9 cm. This was also given a BI-RADS 5 assessment and ultrasound-guided core biopsy was performed.

94% [10]. Initially, COVID-19 infection was suspected to impact cancer patients more severely. As the pandemic has continued, international studies such as the COVID-19 and Cancer Consortium have demonstrated that cancer patients and individuals without cancer share a similar risk of complications or death from COVID-19. This was true regardless of cancer type, treatment type, and treatment timing [11].

This patient's case illustrates that those with increased risk of breast cancer or those who are symptomatic should not delay further evaluation, as disease can progress relatively quickly. In this instance, the patient's findings of a hardened, shrinking breast were a cause for concern for the development of an underlying malignancy. Unfortunately, these findings were misinterpreted as a complication of the recent benign biopsy. This case also highlights the rapidity with which breast malignancy may manifest. The initial benign biopsy was for calcifications in a distant area of the breast from which the cancer became evident within 6 months. Despite the pandemic, patients with worrisome self-reported physical exam findings should seek clinical evaluation by a healthcare provider.

Patient consent

Written, informed consent was obtained from the patient featured in this case report.

REFERENCES

- [1] National Comprehensive Cancer Network. NCCN guidelines. National Comprehensive Cancer Network website. https://www.nccn.org/professionals/physicians_gls/default.aspx. [accessed 19.02.18].
- [2] Virnig BA, Tuttle TM, Shamliyan T, Kane RL. Ductal carcinoma in situ of the breast: a systematic review of

- incidence, treatment, and outcomes. *JNCI: J Natl Cancer Inst* 2010;102(3):170–8. doi:10.1093/jnci/djp482.
- [3] Lee S, Stewart S, Nagtegaal I, Luo J, Wu Y, Colditz G, Medina D, Allred DC. Differentially expressed genes regulating the progression of ductal carcinoma in situ to invasive breast cancer. *Cancer Res* 2012;72(17):4574–86. CAN-12-0636. Epub 2012 Jul 2. PMID: 22751464; PMCID: PMC3899801. doi:10.1158/0008-5472.CAN-12-0636.
- [4] Barrio AV, Van Zee KJ. Controversies in the treatment of ductal carcinoma in situ. *Annu Rev Med* 2017;68:197–211. doi:10.1146/annurev-med-050715-104920.
- [5] John Hopkins Medicine. https://www.hopkinsmedicine.org/breast_center/breast_cancers_other_conditions/invasive_Ductal_carcinoma.html. [accessed 02.15.21].
- [6] Lynch SP, Lei X, Chavez-MacGregor M, Hsu L, Meric-Bernstam F, Buchholz TA, et al. Multifocality and multicentricity in breast cancer and survival outcomes. *Ann Oncol* 2012;23(12):3063–9. doi:10.1093/annonc/mds136.
- [7] Kalli S, Semine A, Cohen S, Naber SP, Makim SS, Bahl M. American Joint Committee on Cancer's Staging System for Breast Cancer, Eighth Edition: What the Radiologist Needs to Know. *Radiographics* 2018;38(7):1921–33. Epub 2018 Sep 28. PMID: 30265613. doi:10.1148/rg.2018180056.
- [8] Nakatsukasa K, Koyama H, Oouchi Y, et al. Docetaxel and cyclophosphamide as neoadjuvant chemotherapy in HER2-negative primary breast cancer. *Breast Cancer* 2017;24(1):63–8. doi:10.1007/s12282-016-0666-7.
- [9] Early Breast Cancer Trialists' Collaborative Group (EBCTCG) Aromatase inhibitors versus tamoxifen in early breast cancer: patient-level meta-analysis of the randomised trials. *Lancet* 2015;386(10001):1341–52. doi:10.1016/S0140-6736(15)61074-1.
- [10] Mast C, Munoz del Rio A. Delayed cancer screenings – a second look. epic health research network. 2020. <https://ehrn.org/articles/delayed-cancer-screenings-a-second-look>. [accessed 02.15.21].
- [11] American Cancer Society. <https://www.cancer.org/content/dam/cancer-org/research/cancer-facts-and-statistics/annual-cancer-facts-and-figures/2021/special-section-covid19-and-cancer-2021.pdf>. [accessed 02.15.21].