

# Complete urethrovesical disruption following obstructed labor

S. Arora, P. Goel, V. Bhalla<sup>1</sup>, N. Aggarwal

Department of Obstetrics, Gynecology and <sup>1</sup>Surgery, Government Medical College and Hospital, Chandigarh, Punjab, India

## ABSTRACT

A 22-years-old lady presented with obstructed labor with a probable preoperative diagnosis of bladder/urethral injury. When a laparotomy was performed there was a complete urethral disruption at the vesicourethral junction with a big anterior forniceal tear in the vagina with intact uterus and cervix. The fetus had pushed itself through the upper vagina and bladder neck into the extraperitoneal space leading to complete urethrovesical disruption as a result of prolonged pressure on the vesicourethral junction against pubic symphysis for which an end to end anastomosis was performed. Although trauma has been mentioned as a cause of such urethral disruption in the literature, no such case has been reported so far following obstructed labor. A brief discussion of various surgical options for such cases is discussed.

**Key words:** Obstructed labor, urethrovesical disruption, reconstruction

## INTRODUCTION

Obstructed labor is one of the most dreadful complications of human childbirth. It being a grave condition there is no place for a 'wait and watch' policy. Limited access to emergency obstetric services is still the most common contributory factor in developing nations.<sup>[1]</sup> Women who survive the ordeal of prolonged obstructed labor often suffer anatomical or functional damage of the pelvic floor leading to urethrovesicovaginal fistula, urinary or fecal incontinence and pelvic organ prolapse. Although rare, pelvic fracture and trauma is another important cause of urethral injury in females.<sup>[2]</sup> We present an extreme case of urogenital injury resulting from obstructed labor.

**For correspondence:** Dr. Sunita Arora, Department of Obstetrics and Gynecology, Government Medical College and Hospital, Sector 32 B, Chandigarh, Punjab, – 160 090, India.

E-mail: drsunitaarora@yahoo.com

### Access this article online

<b>Quick Response Code:</b> 	<b>Website:</b> <a href="http://www.indianjurol.com">www.indianjurol.com</a>
	<b>DOI:</b> 10.4103/0970-1591.102719

## CASE REPORT

A 22-year-old previously unsupervised primigravida was referred to the emergency department of our institute from a peripheral hospital at 40 weeks and two days of pregnancy in obstructed labor. She had been in labor for the last 36 h and had been leaking per vaginam for the last 24 h. She had been handled by an untrained attendant in a village for ~20 h before referring to the index peripheral hospital. There was no history of instrumentation. At presentation, she was dehydrated and pale, pulse rate was 120/min, blood pressure 100/70 mmHg and had mild tenderness in the lower abdomen. There was a single fetus in cephalic presentation, however, fetal heart could not be localized. Vaginal examination revealed small gynecoid pelvis; a large tear was observed in the right anterior vaginal wall extending till the fornix with urethral Foley catheter seen projecting from the tear (indicating urethra-vesical tear). Cervical lips were not felt, vertex was high up above the brim, with a big caput felt at -2 station. After initial resuscitation, she was immediately taken up for laparotomy. A single dead female fetus was found to lie in the extraperitoneal space which was delivered as breech. It weighed 2.5 kg with no gross congenital abnormality. On further exploration, complete urethrovesical disruption was noted although, uterovesical relation was maintained [Figure 1]. There was profuse bleeding from the pelvis and the upper end of the disrupted anterior fornix was unidentifiable. Bleeding could be partially controlled by prompt bilateral in-continuity internal iliac artery ligation. Since there was no identifiable vaginal tissue to which the cervix could be anastomosed total hysterectomy was done.

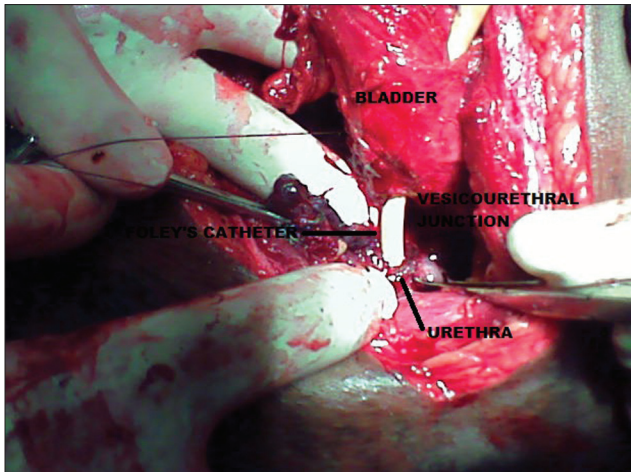


Figure 1: Complete vesicourethral disruption following obstructed labor

Anterior cystostomy was made and bilateral ureteral orifices identified. Both orifices showed efflux of clear urine; these were catheterized for further verification of ureteral integrity and urinary diversion in the postoperative period [Figure 2]. Urethra was identified and the urethral Foley was passed into the bladder through the bladder neck. After freshening of the edges of the bladder neck and urethra, urethra-vesical anastomosis was performed in interrupted manner using 3/0 Polyglactin 910 (Vicryl®, Ethicon, J and J Medical, USA). Cystostomy was subsequently closed over another 16-Fr Foley catheter using 2/0 Polyglactin 910. Her postoperative period was largely uneventful; she was started on orals from Day 1 progressively, drain and ureteral catheters were removed on Day 7 and suprapubic and urethral catheters on Day 21 following a normal cystogram. She developed sphincteric incontinence which progressively responded to pelvic floor muscle therapy and behavioral modification. At six months of follow-up she is fully continent and free of symptoms.

## DISCUSSION

Obstructed labor is associated with a very high incidence of maternal mortality, varying from 4.3–11.4%.<sup>[3,4]</sup> Ruptured uterus and urethra-vesicovaginal fistula following obstructed labor have been well documented. Complete urethrovesical disruption is an extremely rare occurrence and its existence is unknown in the setting of obstructed labor. In a retrospective analysis of our patients with obstructed labor, we found a total of 102 cases (2004-2009) out of which only two patients were found to have a bladder/urethral injury including the present one (incidence of 1.9%).

In the present case, the probable cause of obstructed labor was an inadequate pelvis. Longstanding labor with prolonged pressure of the fetal head on the vesico-urethral junction may have led to ischemia, which, coupled with disrupting forces, may have led to vaginal laceration and complete urethrovesical disruption<sup>[5]</sup>

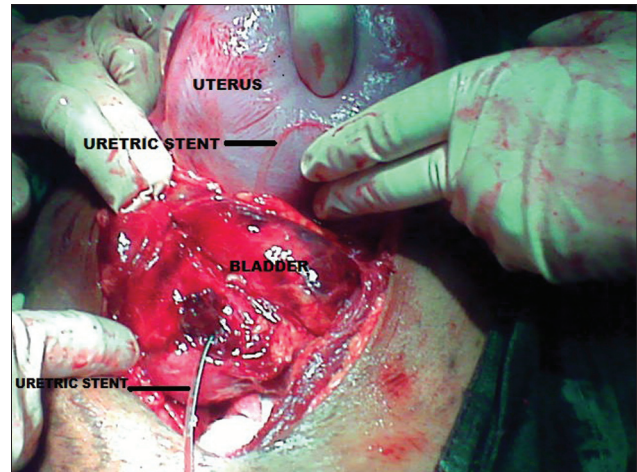


Figure 2: Bilateral ureteric openings stented

The management of urethral injury in female patients is not yet standardized. One school of thought recommends urinary diversion with delayed repair<sup>[6]</sup> while other recommends primary definitive repair at the time of initial trauma except in cases of extensive urethral disruption when complex plastic procedures may be required. A prospective case series of 25 patients by Roenneburg assessed the success rate of direct reanastomosis of the remaining distal urethra to the urethrovesical junction as the primary technique of repair in traumatic absence of proximal urethra and concluded that direct layered reanastomosis is an acceptable procedure in such cases,<sup>[6]</sup> however, it is associated with problems like urethral incontinence and anastomosis site leakage. The same study found a failure rate of 52% and dry rate of 48% if primary end to end anastomosis is chosen. Thirty-five per cent patients required sling surgery for urethral incontinence as second-stage surgery<sup>[6]</sup>

## REFERENCES

1. Wittman AB, Wall LL. The evolutionary origins of obstructed labor: bipedalism, encephalization, and the human obstetric dilemma. *Obstet Gynecol Survey* 2007;62:739-48.
2. Miguel L, Geralf H. Pelvic fracture urethral injuries in girls. *J Urol* 2001;165:1660-5.
3. Sahu NK, Sinha A. Emergence of obstetric maneuvers in preference to cesarean section in the management of obstructed labour. *J Obstet Gynaecol Ind* 1990;40:217-22.
4. Dutta DC, Pal SK. Obstructed labour: A review of 307 cases. *J Obstet Gynaecol Ind* 1978;28:55-8.
5. Normal Labour: Holland and Brews Manual Obstetrics 246-338.
6. Roenneburg ML, Wheelless CR Jr. Traumatic absence of proximal urethra. *Am J Obstet Gynaecol* 2005;193:2169-72.

**How to cite this article:** Arora S, Goel P, Bhalla V, Aggarwal N. Complete urethrovesical disruption following obstructed labor. *Indian J Urol* 2012;28:338-9.

**Source of Support:** Nil, **Conflict of Interest:** None declared.