


Review Article

Adhesive small bowel obstruction – an update

Jia Wei Valerie Tong,¹  Pravin Lingam,² and Vishalkumar Girishchandra Shelat²¹Yong Loo Lin School of Medicine, National University of Singapore, and ²Department of General Surgery, Tan Tock Seng Hospital, Singapore, Singapore

Abstract

Small bowel obstruction (SBO) accounts for 12–16% of emergency surgical admissions and 20% of emergency surgical procedures. Even with the advent of laparoscopic surgery, intra-abdominal adhesions remain a significant cause of SBO, accounting for 65% of cases. History and physical examination are essential to identify signs of bowel ischemia as this indicates a need for urgent surgical exploration. Another critical aspect of evaluation includes establishing the underlying cause for obstruction and distinguishing between adhesive and non-adhesive etiologies as adhesive SBO (ASBO) can be managed non-operatively in 70–90% of patients. A patient with a history of abdominopelvic surgery along with one or more cardinal features of obstruction should be suspected to have ASBO until proven otherwise. Triad of severe pain, pain out of proportion to the clinical findings, and presence of an abdominal scar suggest possible closed-loop obstruction. Computed tomography has higher sensitivity and specificity compared to plain films and is recommended by the Bologna guidelines. Correcting fluid and electrolyte imbalance is an initial crucial step to mitigate severe hypovolemia. Patients should proceed with surgery if symptoms of bowel compromise are present, or if symptoms do not resolve or have worsened. Surgery is indicated in patients with ischemia, strangulation, perforation, peritonitis, or failure of non-operative treatment. With advances in minimal access technology and increasing experience, laparoscopic adhesiolysis is recommended. Mechanical adhesion barriers are an effective measure to prevent adhesion formation.

Key words: Gastrointestinal tract, general surgery, intestinal obstruction, small intestine, tissue adhesion

INTRODUCTION

SMALL BOWEL OBSTRUCTION (SBO) accounts for 12–16% of emergency surgical admissions¹ and 20% of emergency surgical procedures.² Due to the possible risk of bowel ischemia or perforation, urgent evaluation is necessary.³ Emergent surgery is necessary for patients with clinical or radiological signs suggestive of bowel ischemia.⁴ Even with the advent of laparoscopic surgery, intra-abdominal adhesions remain a significant cause of SBO, accounting for 65% of cases, among other etiologies such as hernias, neoplasms, and Crohn's disease.⁵ Adhesive SBO (ASBO) contributes substantial financial burden,⁶ need for hospitalization,⁷ time away from routine life activities, and psychological impact.⁸

The severity of the index pathology, type, and the number of previous surgeries and surgical techniques determine the extent of adhesions.^{4,9} Pelvic procedures and open midline

laparotomy are associated with a higher risk of ASBO.¹⁰ Approximately 91–97% of patients with ASBO have a prior history of abdominal surgery.^{11,12} In a study on 410 patients admitted with a diagnosis of SBO, history of colorectal procedures (24%), gynecological procedures (22%), hernia repair (15%), and appendectomy (14%) was common.¹⁰ In an analysis of 12,756 patients, the Surgical and Clinical Adhesions Research (SCAR)-3 study reported a 5% risk of readmission in the 5 years following abdominopelvic surgery.¹³ A systematic review, including 25 studies, concluded that laparoscopic surgery reduced the incidence and severity of adhesion formation as compared to an open approach.⁹ Our review aims to provide an update on ASBO to guide clinical practice.

DEFINITION

ABDOMINAL ADHESIONS ARE abnormal intraperitoneal fibrous bands connecting surfaces (which usually are separated) to each other.⁵ The small bowel is a few meters long, intraperitoneal, free, mobile, and pan-quadrantic viscus. Hence, it is at most risk for adhesions to itself or the abdominal wall.⁴ Diagnosis of ASBO is established in a

Corresponding: Jia Wei Valerie Tong, MBBS Year 4, Yong Loo Lin School of Medicine, National University of Singapore, Singapore, Singapore. E-mail: valerietong1998@gmail.com.

Received 14 Jul, 2020; accepted 18 Sep, 2020

patient with prior history of any form of abdominal intervention and currently presenting with cardinal symptoms of intestinal obstruction such as abdominal pain, nausea or vomiting, abdominal distension, and absolute constipation. Adhesive SBO is a clinical diagnosis. Serum biochemistry and imaging complement clinical judgment.

TYPES OF ASBO

INTRA-ABDOMINAL ADHESIONS CAN be congenital or acquired, incomplete or complete, and single or matted. Congenital adhesions form *de novo* during organogenesis,¹⁴ are uncommon (3%),¹⁵ often asymptomatic, and can present as an incidental finding in all ages¹⁶ (Fig. 1). Acquired intra-abdominal adhesions form due to local inflammation in response to peritoneal injury, for example, abdominopelvic surgery (85%) (Fig. 2), peritonitis, endometriosis, and radiation.^{16,17,18} At sites where adhesions form, intestines can kink or twist, resulting in incomplete or complete mechanical SBO. In incomplete (partial or low grade) obstruction, some fluid or gas is still able to pass, whereas in complete (high grade) obstruction, no fluid or gas can pass beyond the site of obstruction.¹⁹

Abdominal adhesions can be single-band or matted. Single-band adhesions are <1 cm long and >1 cm in diameter and cause SBO through external compression.^{19,20} Bowel ischemia and high-grade obstructions are more frequent in single-band SBO. Matted adhesions are multiple, dense, and

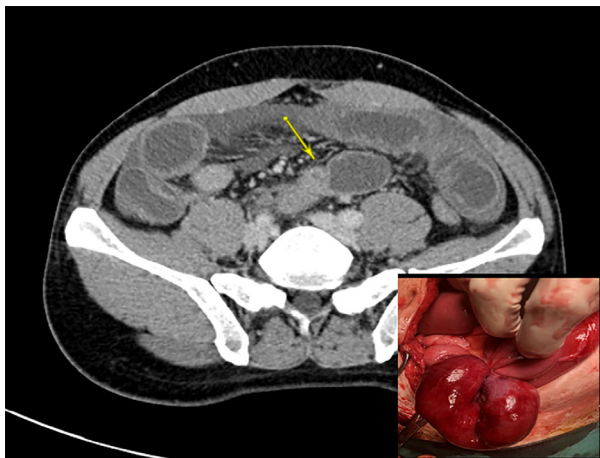


Fig. 1. A patient with no relevant medical history showed symptoms of small bowel obstruction. The computed tomography scan shows dilated distal jejunal loop with a transition point suggestive of small bowel obstruction. At laparotomy, a congenital adhesion band from the root of the mesentery to the bowel loop was detected and lysed. Yellow arrow indicates the transition point.

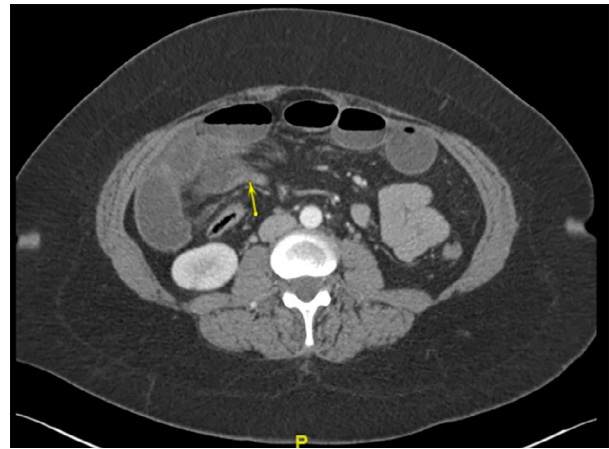


Fig. 2. A patient with a history of tubal ligation carried out more than a decade ago showed symptoms of small bowel obstruction. The computed tomography scan shows dilated distal jejunal loop with abrupt transition, suggestive of small bowel obstruction. Yellow arrow indicates the transition point.

tangled, and cause SBO through intestinal kinking (sharp turn of the long axis of the bowel) or torsion (rotation of the bowel about its axis). Matted adhesions have increased risk of bowel perforation, readmission rate following surgical intervention (49% versus 25% for single-band adhesions), and earlier recurrence.^{10,21,22} Closed-loop obstruction is a distinct type of adhesion formed when two points along a segment of the bowel are obstructed at a single point, isolating the obstructed segment (Fig. 3). This form of obstruction is associated with higher risks of strangulation and infarction with a mortality risk of 10–35%.^{23,24}

PATHOGENESIS OF ACQUIRED ADHESIONS

INJURY TO THE peritoneal mesothelium and resulting local inflammation activates fibrinocoagulative pathways.²⁴ This results in increased cellular turnover, infiltration of inflammatory cells, and deposition of fibrinogen.²⁵ As the fibrinous matrix forms, it creates a gelatinous connection to surrounding structures. Fibroblasts then infiltrate to form a permanent adhesion, and fibrinogen is converted to fibrin. Under normal circumstances, fibrinolytic factors (e.g., tissue plasminogen activators [tPA]) will degrade fibrin into smaller fragments known as fibrin degradation products.²⁶ However, imbalance in the process of fibrin formation and fibrinolysis leads to the formation of adhesive bands.²⁷ Reduced activity of tPA and matrix metalloproteinase, and increased activity of plasminogen activator inhibitors and tissue inhibitors of metalloproteinases alter this delicate balance. Notably, transforming growth factor- β overexpression

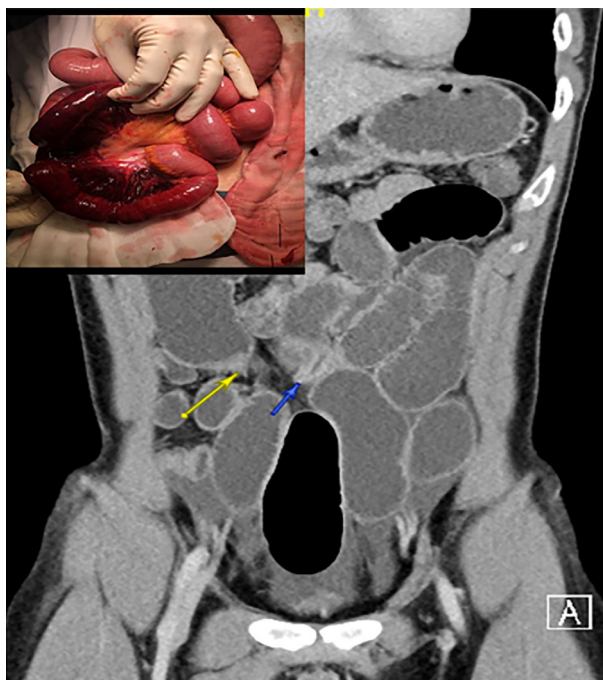


Fig. 3. A patient with a history of surgery for intussusception as an infant and showing symptoms of small bowel obstruction. The computed tomography scan shows dilated distal jejunal loop with two transition points close to each other, suggestive of closed-loop small bowel obstruction. Top left inset: intraoperative photograph of bowel ischemia caused by small bowel obstruction secondary to acquired adhesions. Yellow and blue arrows point to the transition points of the closed-loop obstruction.

is associated with an increased incidence of adhesions both in human and animal models due to its role in controlling the matrix metalloproteinase/tissue inhibitor of metalloproteinase and plasminogen activator inhibitor/tPA mechanisms.²⁸ Apart from molecular changes, peritoneal injury during surgery also causes decreased blood flow and local persistence of the fibrin matrix, impeding the organization and resolution of clots.²⁹ Figure 4 illustrates the pathogenesis of acquired adhesions.

PATHOPHYSIOLOGY

INITIALY, INTRALUMINAL DISTENSION causes a temporary increase in peristalsis proximally and inhibition distally, in an attempt to increase intraluminal pressure to overcome the obstruction.³⁰ However, muscle fatigue occurs, and peristaltic activity stops.³¹ Dilatation occurs as gas and fluid from swallowed contents, and bacterial fermentation, collects proximally.³² As 8–10 L of fluid passes

through the gastrointestinal (GI) tract daily,³³ impaired reabsorption causes fluid sequestration into the bowel lumen (third spacing), and loss of intravascular volume predisposes to dehydration, electrolyte disturbances, and hypovolemic shock. Decreased oral intake and vomiting compound the fluid electrolyte deficit.³¹ The compression of intestinal veins and lymphatics causes mural edema, which compresses on arterioles and capillaries, and this leads to reduced perfusion. Ischemia, in turn, predisposes to necrosis and perforation. This can progress to peritonitis and sepsis⁵. Anaerobic metabolism and ischemic cell death could lead to a build-up of lactic acid and release of intracellular potassium (K^+), resulting in metabolic acidosis and hyperkalemia.³⁴ Figure 5 illustrates the pathophysiology of SBO.

INITIAL EVALUATION OF PATIENTS WITH ASBO

HISTORY AND PHYSICAL examination are essential to identify signs of bowel ischemia as this indicates a need for urgent surgical exploration. History of worsening pain with abdominal tenderness is highly suggestive of ischemia.³⁵ Another critical aspect of evaluation includes establishing the underlying cause for obstruction and distinguishing between adhesive and non-adhesive etiologies as ASBO can be managed non-operatively in 70–90% of patients.^{10,36} Figure 6 shows our approach to ASBO evaluation and management. Table 1 shows the utility of history, physical examination, laboratory investigations, and imaging in the evaluation of ASBO.

History

A patient with a history of abdominopelvic surgery along with one or more cardinal features of obstruction should be suspected to have ASBO until proven otherwise. Crampy periumbilical abdominal pain is often the earliest sign. Initially, paroxysms of pain occur every 4–5 min; however, when bowel ischemia is present, abdominal pain becomes constant. Sudden onset of severe pain indicates perforation.³⁰ Nausea and vomiting follow the onset of pain and are an early feature of proximal SBO. Contents are usually bilious but could also be non-bilious or feculent, depending on the site of obstruction and severity.³⁷ Abdominal distension is more significant in distal obstruction. Complete SBO is associated with obstipation, the inability to pass flatus or feces. However, the passage of flatus or feces could still occur 12–24 h after the onset of symptoms as distal bowel decompresses.³⁸ Patients with incomplete obstruction might also present with watery diarrhea.³⁶ Symptoms lack

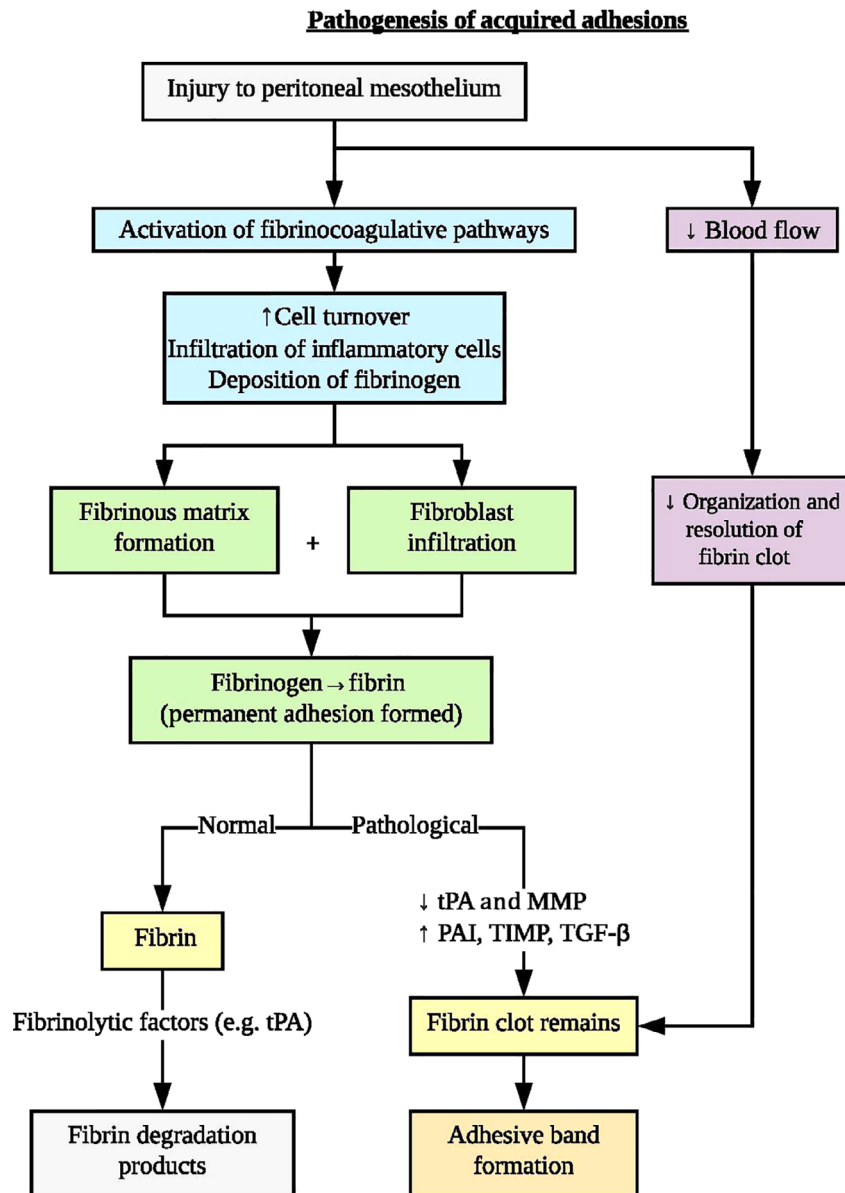


Fig. 4. Pathogenesis of acquired adhesions in the small bowel. MMP, matrix metalloproteinase; PAI, plasminogen activator inhibitor; TGF- β transforming growth factor- β ; TIMP, tissue inhibitor of metalloproteinase; tPA, tissue plasminogen activator.

sensitivity and specificity, especially in elderly patients who have atypical symptoms with diagnostic dilemma.^{8,40}

Physical examination

Signs of dehydration and hypovolemia manifest as tachycardia, hypotension, oliguria, and dry mucus membranes.³⁹ Triad of severe pain, pain out of proportion to the clinical findings, and presence of an abdominal scar

suggest possible closed-loop obstruction.³⁵ Fever could also suggest mucosal ischemia with bacterial translocation and sepsis. Hyperactive high-pitched tinkling bowel sounds suggest mechanical obstruction, though the inter-observer agreement is low.⁴⁰ Signs of peritonitis, such as abdominal tenderness, suggest strangulation.⁴¹ Once ischemia ensues, peristalsis could cease and abdominal pain could paradoxically improve, thus, silent abdomen is an ominous sign. An abdominal examination can also

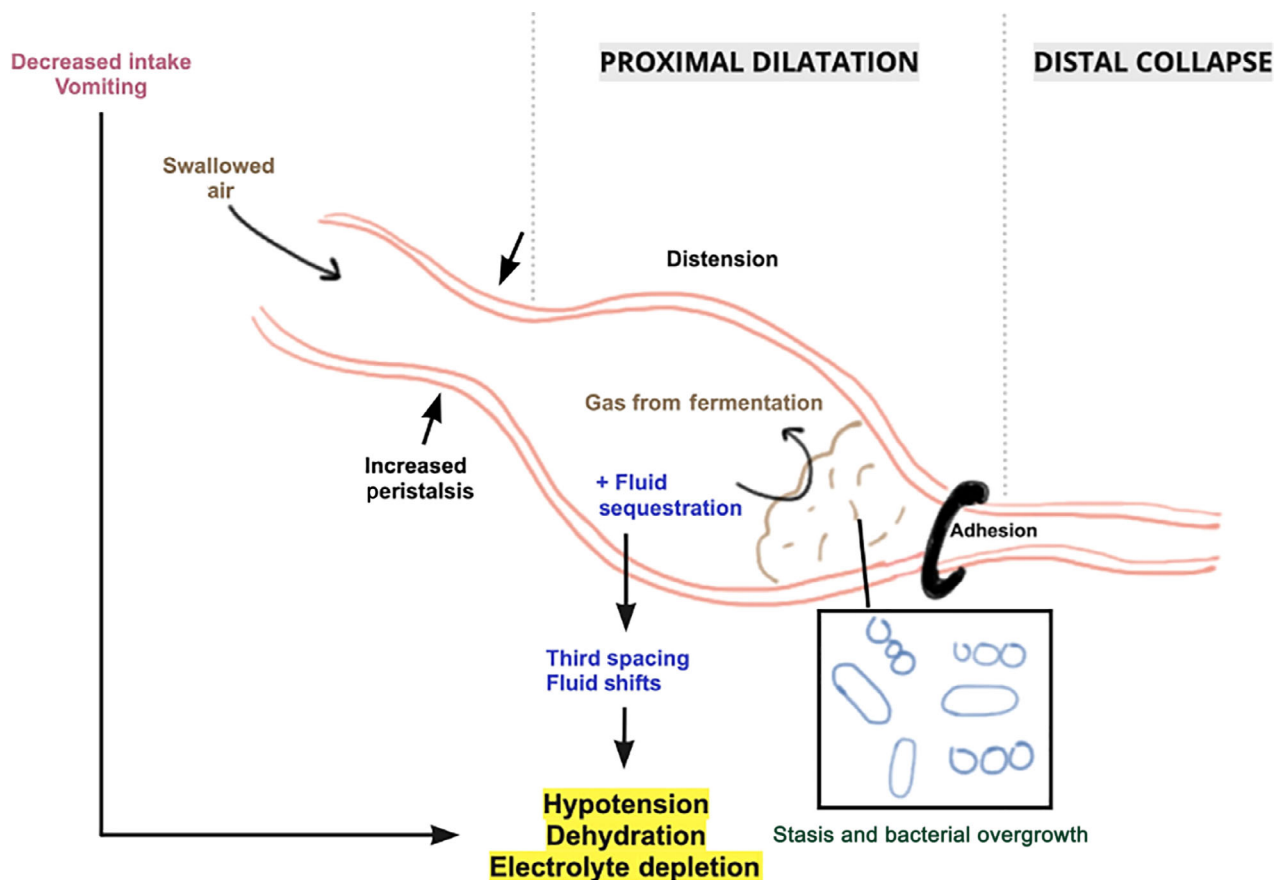


Fig. 5. Pathophysiology of small bowel obstruction (SBO). ASBO, adhesive SBO; BUN, blood urea nitrogen; CRP, C-reactive protein; FBC, full blood count; I-FABP, intestinal fatty acid-binding protein; NBM, nil by mouth; NGT, nasogastric tube.

help exclude SBO due to hernias. A digital rectal examination could reveal an empty rectum.

Serum investigations

Full blood count, C-reactive protein, blood urea nitrogen, creatinine, and electrolytes have limited diagnostic utility but help assess the impact of ASBO and risk of bowel compromise.⁴¹ Elevated C-reactive protein >75 units and white blood cell count >10 000/mm³ suggests peritonitis or perforation.⁴¹ In patients presenting with systemic inflammatory response syndrome, arterial blood gas, serum lactate, and blood cultures are essential. Elevated serum lactate has a sensitivity of 90–100% and specificity of 42–87% for ischemic bowel.^{42,43} Blood cultures guide antimicrobial therapy. Plasma and urinary intestinal fatty acid-binding protein, a protein released by necrotic enterocytes, is a useful marker of ischemia.^{44,45}

IMAGING

Plain radiograph

SUPINE AND UPRIGHT plain film of the abdomen and pelvis could show dilated gas- or fluid-filled loops of the small bowel, non-distended or gasless colon, air–fluid levels with >5 mm difference in height, and string of pearls signs.^{5,46} However, the diagnostic accuracy of the plain film is low.⁴⁷

Computed tomography scan

Computed tomography (CT) scan has higher sensitivity and specificity compared to plain films and is recommended by the Bologna guidelines.³⁶ Computed tomography scan can show extraluminal air (especially retroperitoneal air), mural thickening, reduced mural enhancement, mesenteric edema/

Diagnosis and management of ASBO

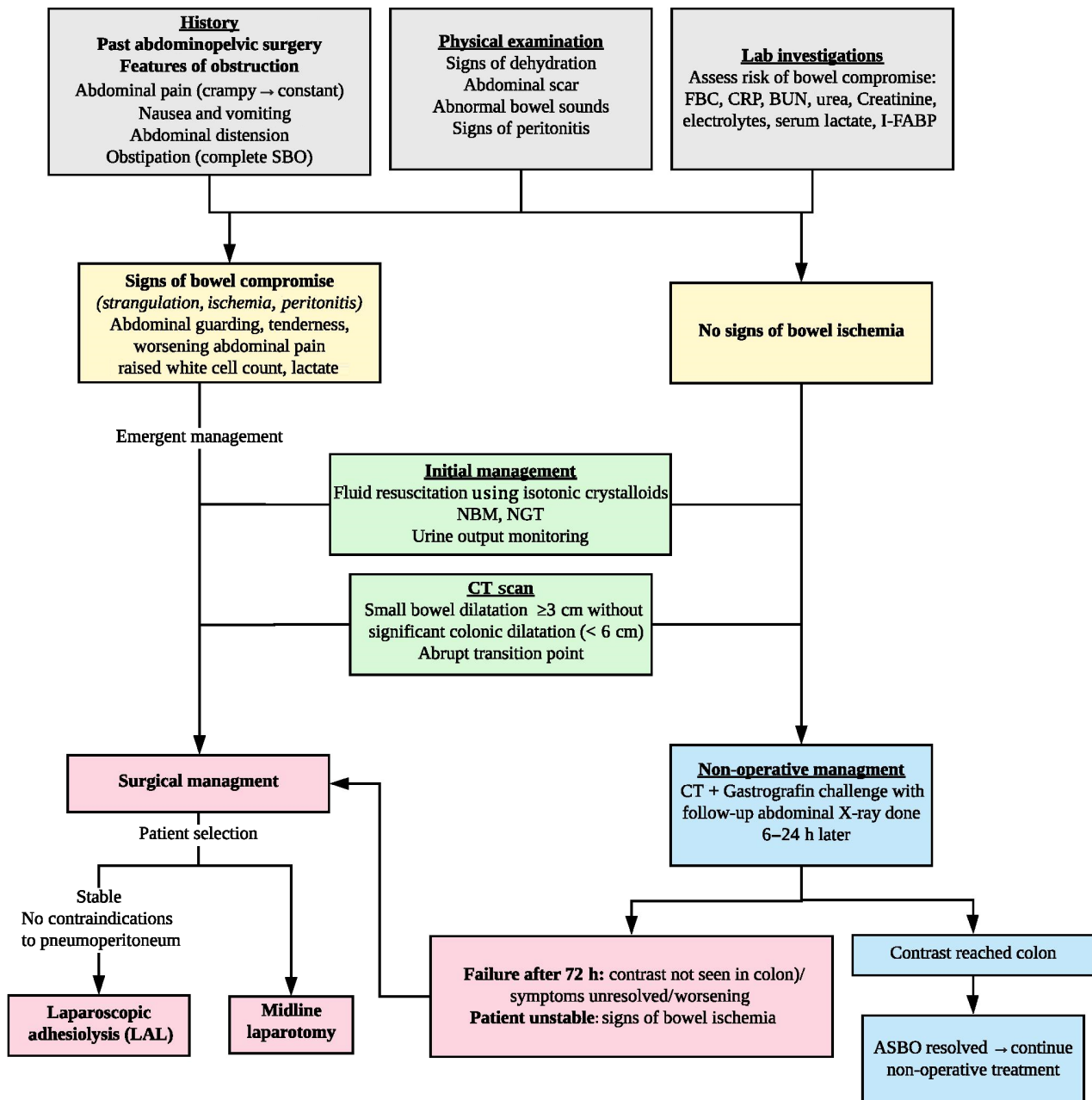


Fig. 6. Approach to adhesive small bowel obstruction (ASBO) evaluation and management.

venous congestion, pneumatosis intestinalis, and intra-abdominal free fluid.¹ The major criteria of SBO on CT scan include small bowel dilatation of ≥ 3 cm in diameter without significant colonic dilatation (< 6 cm in diameter), and abrupt transition point from dilated to the collapsed small bowel. Minor criteria include air–fluid levels and a

decompressed colon.² For ASBO, CT scan has higher diagnostic accuracy compared to plane radiograph in identifying the transition point (93%) and etiology of obstruction (85–90%).^{3,5} The presence of the “beak sign,” a pattern formed by the dilated proximal intestine and transition point, predicts ASBO.⁴⁸ The ability of the CT scan to distinguish

Table 1. Utility of history, physical examination, laboratory investigations, and imaging in patients with adhesive small bowel obstruction

History ^{36,44,47}					
	Sensitivity (%)	Specificity (%)	PPV	NPV	RR
History of abdominopelvic surgery	85	78	14	99	12.1
Abdominal pain	75.9–87	41–47.6	92.3	19.2	2.8
Nausea/vomiting	62.6–88	30–61.9	93.2	16.7	
Abdominal distension	74.1–88	19–47.6	92.8	19.6	
Constipation/obstipation	18–56.3	38–90	88.2	9.5	
Physical examination ^{123,124}					
	Sensitivity (%)	Specificity (%)	PPV	NPV	RR
Distended abdomen	67–88	44–96	39	99	13.1
Abdominal tenderness	69–88	72	10	98	
Guarding	33–63	47–60	5	97	
Abnormal bowel sounds (hyperactive/sluggish)	42–76	28.6–88	22–86.8	16.7–99	9.0
Laboratory investigations (in detecting bowel ischemia) ^{125,126}					
	Sensitivity (%)	Specificity (%)	PPV	NPV	
Leukocyte count ($\geq 10,000/\text{mm}^3$)	45–81	37–57	4	96	
Elevated lactate	90–100	42–87			
Intestinal fatty acid-binding protein	71.4–80	85–93.8	93.8	71.4	
Imaging ^{36,47}					
	Sensitivity (%)	Specificity (%)	Accuracy (%)		
Plain radiograph	79–83	67–83	64–82		
CT scan	90–94	96	90–95		

CT, computed tomography; NPV, negative predictive value; PPV, positive predictive value; RR, relative risk.

between ASBO caused by the single-band and matted adhesions is valuable for patient selection for laparoscopic adhesiolysis (LAL) and to optimize port placements.⁴⁹

Multidetector CT scan and multiplanar reformation enhance the diagnostic value of CT scans by providing better spatial resolution. Acute-angled, U-, or J-shaped pattern made up of proximal dilated and distal collapsed bowel loops suggests angulation/kinking, and this typically indicates ASBO caused by matted adhesions. The “fat notch sign” and “beak sign” occur more commonly in single-band ASBO.^{18,22} A CT scan of abdomen–pelvis with oral water-soluble contrast (e.g., Gastrografin [GGF]; Spain) with a follow-up abdominal X-ray carried out 6–24 h later is recommended in the evaluation of ASBO.³⁶ Oral water-soluble contrasts are safer and eliminate the risk of barium-induced peritonitis.⁵⁰ Two meta-analyses reported that water-soluble

contrast studies could predict a resolution of obstruction without surgery (>90% sensitivity and specificity), reduce the need for surgery (odds ratio [OR] = 0.55).^{50,51} Gastrografin challenge can cause unnecessary delays with a longer time to theater (71:25 h) compared to a CT scan (46:39 h). These delays can be potentially life-threatening due to the risk of ischemia⁵². Although water-soluble contrast studies are useful in identifying complete SBO and predicting the need for surgery,⁴⁷ its ability to identify or predict impending strangulation is questionable.³⁵

Ultrasound and magnetic resonance imaging

The utility of ultrasound depends on the skill of the operator, and factors such as intraluminal gas and patient body habitus affect visibility. Ultrasound has limited utility in diagnosing

ASBO. Magnetic resonance imaging is useful in situations where a CT scan is unavailable or not possible (e.g., pregnancy and dye allergy). However, its cost, access, and lower spatial and temporal resolution compared with the CT scan make it of limited value in the diagnosis of ASBO.^{36,47}

MANAGEMENT

Initial management

CORRECTING fluid and electrolyte imbalance is an initial crucial step to mitigate severe hypovolemia. Fluid resuscitation by isotonic crystalloids (e.g., lactated Ringer's solution or normal saline) should be done simultaneously with the diagnostic workup.⁴⁹ All patients suspected with ASBO need to have nil by mouth instruction, and decompression carried out using a wide bore nasogastric tube (NGT) or long intestinal tubes.^{36,49} An NGT is easier to insert but is less effective in decompressing the distal part of the small bowel. Long intestinal tubes can achieve distal decompression. However, insertion of long intestinal tubes requires endoscopy or fluoroscopy and can lead to regurgitation, vomiting, and respiratory and abdominal distress along with potential risk of aspiration pneumonia. In a randomized control trial comparing decompression by NGT versus long intestinal tubes, Fleshner *et al.* reported no advantage of using long intestinal tubes.⁵³ Recently, some authors reported inserting long intestinal tubes without the need for endoscopy and compromising patient comfort.⁵⁴ Urinary catheterization aids urine output monitoring and guides the adequacy of fluid resuscitation.⁵⁵

Non-operative management

Non-operative management involves readiness to operate following deterioration in the clinical condition of the patient and thus is not synonymous with conservative management. Elective non-operative management has a success rate of 70–90% in patients with ASBO.⁵⁶ Gastrografin (GGF) is hyperosmolar and causes a fluid shift from the intestinal wall to the lumen, thus increasing the motility and diluting intestinal contents. Gastrografin might also increase peristaltic activity and has a therapeutic role.⁵⁷ In patients managed by non-operative intent, GGF accurately (98%) predicts the need for surgery but does not influence the need for surgical intervention or mortality.^{58,59} Gastrografin also led to shorter length of stay (−2.18 days) and time to resolution (−28.25 h)^{50,51} but does not reduce morbidity or mortality.⁵ Gastrografin could exacerbate dehydration by fluid sequestration into the bowel lumen, and caution is needed to ensure the fluid balance of patients.

There is no uniform agreement about the timing of an abdominal X-ray after GGF. A meta-analysis of GGF with X-ray taken 2–6 h, 8–12 h, and 24–36 h post-challenge, reported that diagnostic accuracy was optimal at least 8 h after contrast was given (the 8–12 h group and the 24–36 h group did not show a significant difference).⁵⁰ Delays in surgical treatment of >24 h increase the need for bowel resection, prolong the length of stay, and are associated with higher morbidity and mortality (OR 1.64).^{60,61} A review of 27,000 patients reported a cut-off of 4 days for inferior outcomes, after which there is higher rate of mortality (OR 1.64) and longer postoperative stay.⁶¹ However, studies have also reported similar morbidity and rates of postoperative complications between the emergent and delayed surgery groups.⁶² Most studies recommended a cut-off of 3–5 days, and the Bologna guidelines advocate 72 h as a safe period for the trial of non-operative treatment should there be no signs of complications.³⁶

Patients should proceed with surgery if symptoms of bowel compromise are present, or if symptoms do not resolve or have worsened.⁴⁷ Use of GGF does not affect either the ASBO recurrence rates or recurrences needing surgery.⁶³ However, two recent studies reported that non-operative management is associated with higher readmissions and shorter disease-free intervals compared to surgery.^{52,64} The 5-year probability of recurrence increases with each episode up until the point when surgery is imminent, after which, the rate of recurrence decreases by approximately half.⁶⁴

Surgical management

Surgery is indicated in patients with ischemia, strangulation, perforation, peritonitis, or failure of non-operative treatment.³⁶ An age-old adage, “a sun should not both rise and set on an established case of strangulation,” is a useful aide-memoire in situations where non-operative management is contemplated. A midline laparotomy with adhesiolysis is the gold standard approach. However, laparotomy has higher risks of wound infection, incisional hernia, and future adhesions.⁶⁵ With advances in minimal access technology and increasing experience, LAL is recommended. Laparoscopic adhesiolysis reduces the duration of surgery by 50% ($P < 0.001$),^{66,67} postoperative length of stay (by ~1.3–2 days),⁶⁸ overall complication rate ($P = 0.014$) with an adjusted OR of 0.37 ($P = 0.002$),⁶⁹ and adhesion reformation.⁷⁰ It is also associated with faster GI recovery (e.g., quicker removal of nasogastric tube and passage of flatus).⁶⁹ A recent systematic review of over 38,000 patients also identified reduced morbidity ($P < 0.001$), mortality ($P < 0.001$), and surgical infections ($P = 0.003$).⁷⁰

Disadvantages inherent to the use of laparoscopy include difficulty handling bowel loops, poor visibility of the cause of obstruction, and higher costs.⁷¹ However, a meta-analysis found no significant differences in rates of intraoperative injury to the bowel, wound infection, or mortality.⁷² In terms of incidence of adhesion reformation and adhesion score, both the laparoscopic and open approach reported similar outcomes.⁷³ Patient selection for LAL is essential, and “conversion is not a crime.”⁷⁴ The Bologna guidelines recommend LAL in stable patients with no signs of diffuse peritonitis or perforation, and caution advised in patients with grossly distended bowel loops or multiple complex adhesions, as this can increase the risk of enterotomy.³⁶

To reduce the risk of iatrogenic bowel injury during LAL, surgeons should avoid grasping the distended loops and handle only the mesentery. Enterotomy in the presence of pneumoperitoneum disseminates rapidly and increases the risk of intra-abdominal abscess. Conversely, another guideline suggested that the only absolute exclusion criteria for LAL are patients with contraindications to pneumoperitoneum (e.g., hemodynamic instability or cardiopulmonary impairment), and all other contraindications should be judged on a case by case basis depending on the experience of the surgeon.⁷⁵ Factors associated with a higher success rate of LAL are fewer previous laparotomies (≤ 2), no previous median incisions, adhesion caused by the previous appendectomy, single-band adhesions, early laparoscopic management <24 h from the onset of symptoms, lower American Society of Anesthesiologists class, and experienced surgeon.^{76,77} Open conversion rates vary (10–39%). Risk of open conversion is higher in patients with dense or diffuse adhesions, previous midline laparotomy, iatrogenic injuries, bowel ischemia or perforation, inadequate exposure, need for bowel resection, non-adhesive etiologies of obstruction (e.g., hernia, malignancies), CT scan findings of free abdominal fluid, distended bowel of ≥ 4 cm, or small bowel feces sign.^{69,68} Open conversion does not increase the rate of complications or morbidity.^{36,65,69}

As thermal injuries could lead to delayed perforation, surgeons must avoid energy-based dissections, and perform sharp scissor dissection with patience.⁷⁸ The authors recommend doing complete small bowel adhesiolysis from duodenojejunal flexure up to ileocecal junction as routine, if feasible. However, in difficult situations, one needs to balance the risk of bowel injury and potential harm. Table 2 provides a summary of the management options.

Recurrence

Relapse and recurrence are universal in patients with ASBO; that is, once an adhesion, always an adhesion. As the

Table 2. Summary of management options for patients with adhesive small bowel obstruction and their advantages/disadvantages

Management	
Non-operative	
Benefits (versus operative management)	Risks
Accurately predicts need for surgery (98%)	Delay in surgical treatment
Shorter length of stay	↑Readmission rate
Shorter time to resolution	↓Disease-free interval
No effect on need for surgery/morbidity/mortality/recurrence rate	↑Risk of recurrence
LAL versus midline laparotomy with adhesiolysis	
Potential benefits of LAL	Disadvantages of LAL
↓Morbidity, mortality	Difficulty handling bowel loops
↓Duration of surgery (by 50%)	Poor visibility of the cause of obstruction
↓Intraoperative injury to bowel	Higher costs
↓Postoperative length of stay	
↓Time to recovery of GI function	
↓Adhesion reformation	
↓Overall complications	
↓Postoperative complications: pain, wound infection, incisional hernia, pleuropulmonary/cardiac complications, venous thromboembolism	

GI, gastrointestinal; LAL, laparoscopic adhesiolysis.

number of (re)admissions increase, recurrence risk increases, and the disease-free interval between recurrences decreases.^{10,79} In patients treated by non-operative management, recurrence is a matter of “when” and not “if”. Surgery for ASBO does not confer immunity towards recurrence (Fig. 7). In a retrospective study of 5,060 cases over 4 years, 21% of patients showed recurrent ASBO after their first admission regardless of the treatment received.⁸⁰ A population study involving over 32,000 patients also noted similar outcomes 5 years postoperatively, regardless of treatment during the first admission.⁸¹ Several factors influence the rate of recurrence of ASBO (e.g., adhesion type, prior episodes of ASBO, and previous treatment). Patients with matted adhesion have higher rates of recurrence as compared to single-band adhesions.¹⁰ The 5-year recurrence rate for patients treated with or without operation was similar (27% and 34%, respectively) regardless of the number of previous readmissions.¹⁰ However, patients treated conservatively tended to have an earlier recurrence than those

treated surgically, with the median time to readmission being 0.7 and 2.0 years, respectively.^{10,79} Repeated conservative management for recurrent ASBO leads to increased risk of recurrence, whereas surgical treatment is associated with reduced risk of future admissions.^{21,80} Hence, considering the number of previous recurrences is necessary for deciding the management method.

PREVENTION OF ABDOMINAL ADHESIONS

Surgical technique

SURGICAL TECHNIQUE AND the use of adhesion barriers reduce adhesion formation.⁵⁶ Minimal access surgery reduces adhesions due to reduced trauma and hemorrhage, smaller surgical wounds, and the ability to maintain humidity in the native environment. Establishing pneumoperitoneum also allows separation of surfaces during healing, reducing the likelihood of adhesion formation.^{5,56} However, the use of foreign bodies, desiccation, and the insufflation of carbon dioxide can also promote adhesion

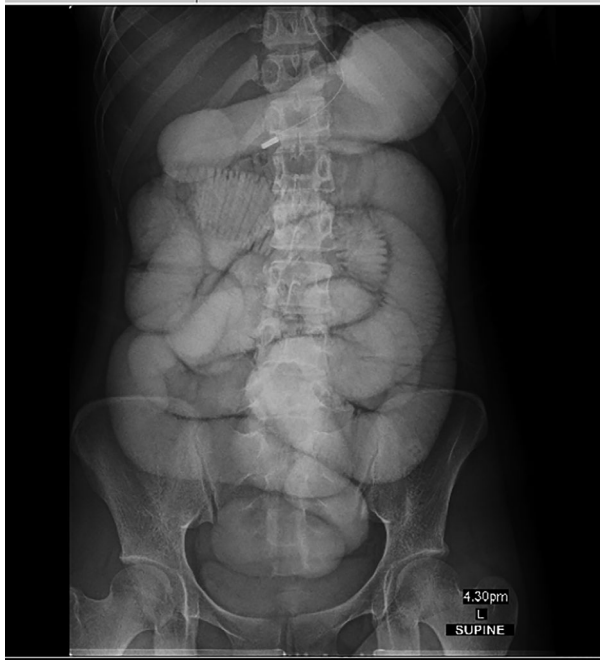


Fig. 7. A patient with a history of laparoscopic appendectomy 2 years ago and showing symptoms of small bowel obstruction. A barium meal and follow-through after 100 mL undiluted Omnipaque dye insertion through a nasogastric tube showing dilated small bowel loops (up to 4.3 cm) and prolonged transit (>7.5 h) without the flow of contrast into the large bowel, suggestive of high-grade small bowel obstruction.

formation.⁸² Other technical factors associated with reduced adhesion formation include not closing the peritoneum, choice of suture material, and using ultrasonic dissection instead of electrocautery.⁸³ Animal studies reveal that adequate peritoneum conditioning to avoid hypoxia, acidosis, and desiccation has a protective effect.⁸⁴

Pharmacoprevention

As the pathogenesis of adhesions is closely related to the inflammation and fibrinocoagulative pathway, large numbers of animal studies report the effect of human recombinant tPA on preventing adhesions by supplementing the deficient plasminogen and fibrinolytic activity in the injured peritoneum.⁸⁵ Human studies also establish a reduction in adhesions.⁸⁶ Other fibrinolytics, such as streptokinase, also reduce the incidence of postoperative ASBO following a local intraperitoneal treatment.⁸⁷ In a rat model, angiotensin-receptor blocker, telmisartan, reduces the formation and stability of postsurgical adhesion bands by stimulating anti-inflammatory responses and antifibrotic effects, and by reducing submucosal edema and oxidative stress at the surgical site. However, these effects were not evident with other angiotensin-receptor blockers such as losartan and valsartan.⁸⁸ This concurs with studies suggesting links between the renin-angiotensin system and inflammatory or fibrotic pathways.⁸⁹ However, pharmacotherapy can cause bleeding complications and should be used with caution, especially in patients who are on anticoagulants.⁹⁰

Mechanical barriers

Mechanical adhesion barriers are an effective measure to prevent adhesion formation. They involve the application of mechanical barriers around the surgical area to keep the injured peritoneal and serosal surfaces apart until mesothelialization, and complete healing occurs. Mechanical barriers are available in different forms. Hyaluronate carboxymethylcellulose (Seprafilm, Illinois, USA), oxidized regenerated cellulose (Interceed, New Jersey, USA), and 100% type I collagen (CollaGUARD, Wisconsin, USA) are solid barriers, and 4% icodextrin solution (Adept, Illinois, USA) and polyethylene glycol (Sprayshield, Minneapolis, USA) are liquid barriers. A sterile gel containing activated protein C (Hyalobarrier, Massachusetts, United States) is a gel barrier.

Barriers are safe and cost-effective for use in abdominopelvic surgeries.⁹¹ For open surgeries, any form of barrier is easy to use, but for minimal access surgery, solid barriers are not user-friendly, and gel barriers are more straightforward to insert through trocar sites. Hyaluronate carboxymethylcellulose resulted in fewer intraperitoneal

adhesions in major procedures⁹² and reduced the risk of ASBO requiring reoperation and operative time.^{91,93} A 4% icodextrin solution is safe and effective in reducing the risk of ASBO.⁹⁴ An increase in the local expression of growth factors and antifibrinolytic factors reduces the efficacy of adhesion barriers.⁹⁵ A systematic review of 93 studies reported that Seprafilm, icodextrin, and polyethylene glycol reduced the adhesion score of reformed adhesions, but none of the current commercially available adhesion barriers reduced the incidence of adhesion reformation in animal models.⁷³

Studies involving newer adhesion barriers such as novel dextrin hydrogel (AdSpray, Italy) reported reduced incidence⁹⁶ and severity of adhesions.⁹⁷ Starch-based formulation 4DryField PH (UK) also showed its utility in reducing adhesion severity, the extent of reoperations,⁹⁸ and adhesion prevention.⁹⁹ AABO3 (Korea), a micronized thermosensitive antiadhesion barrier developed from the human-derived acellular dermal matrix, reduces adhesions by reducing macrophage counts, microvessel density, and collagen fiber density.¹⁰⁰

Special situations (oncology, hernia, gallstone, and bezoar)

Among cancer patients, postoperative ASBO is a leading cause of small bowel obstructions.¹⁰¹ However, the recurrence of cancer needs to be ruled out. Oncology therapy, like radiation, also increases the risk of adhesions by inducing fibrotic changes. Pericancer inflammation could also predispose adhesion formation. Imaging aids in differentiating between malignant versus adhesive SBO. The absence of observable masses suggests a benign cause. Magnetic resonance imaging with gadolinium contrast can distinguish malignant etiology of SBO by features such as peritoneal enhancement and mesenteric infiltration.¹⁰² The management of patients with and without malignancy is similar unless SBO is due to recurrence or metastases. However, for cancer patients, overall outcomes are determined by oncology, and hence fitness for surgery needs stringent evaluation criteria with clearly defined goals of care.^{103,104} Factors associated with poorer surgical outcomes include recurrent ascites after paracentesis, hypoalbuminemia, Eastern Cooperative Oncology Group performance status ≥ 2 , diffuse palpable abdominal masses, previous surgery showing diffuse metastatic cancer, and the involvement of proximal stomach.¹⁰⁵

Hernias cause obstruction by extrinsic compression on the small bowel, and incarcerated hernias are a significant cause of complicated SBO.³⁸ Hernias should be differentiated from ASBO (10% of all SBOs).⁵ Recognizing hernia

as the etiology is significant, as delayed treatment could potentially lead to increased morbidity and progression to strangulation.¹⁰⁶ In a study investigating the various etiologies of SBO (adhesions, Crohn's disease, neoplasm, and hernia), patients who underwent surgical intervention and conservative management had similar median intervals to recurrence (at 1 year), except for patients with obstructions caused by hernias (0.2 years). In patients with SBO due to hernia, non-operative management leads to higher recurrence rates, and hence laparotomy should be considered early in the course of disease.^{5,106} Hernias can be external (caused by weakness of muscles or ligaments) or internal (caused by mesenteric defects). Risk factors for internal hernias include previous bowel resection or bariatric procedures (e.g., intestinal bypass)¹⁰⁷ and can be differentiated from ASBO by CT scan. In a consensus opinion obtained by the Delphi method, Costa *et al.* recommends immediate surgical intervention in patients with a strangulated hernia, >10 cm cecal diameter, signs of ischemia, and refractory metabolic acidosis.¹⁰⁸

Gallstone SBO is a complication of cholelithiasis and accounts for 0.5% of all mechanical SBO.¹⁰⁹ It occurs more commonly among elderly women, and patients with multiple comorbidities,¹⁰⁹ with an estimated mortality of up to 30%.¹¹⁰ Common sites of obstruction include the ileum (60%), jejunum (15%), stomach (15%), and colon (5%). Small bowel obstruction is usually caused by stones > 2.5 cm in diameter.¹¹¹ Presentation is non-specific, often with cardinal symptoms of SBO. Symptoms are occasionally sudden but often of fluctuating subacute nature caused by enterolith tumbling through the bowel lumen. Fever and jaundice might also be present.¹¹¹ Laboratory investigations are typically unremarkable but could reveal leukocytosis and anemia from enterolith-related pressure on the intestinal mucosa. Computed tomography is the gold standard for diagnosis,¹¹⁰ and presence of two of three Rigler's triad signs (pneumobilia, SBO, and an ectopic gallstone) are diagnostic. The presence of cholecystoduodenal fistula is also suggestive. In cases of acute SBO, emergent surgical management is often required. However, for stones <2 cm with no underlying bowel compromise, management with supportive treatment and NGT suctioning could be considered.¹¹² For stones >2 cm, spontaneous passage is unlikely and surgical removal is indicated. Enterolithotomy (open or laparoscopic approach)¹¹³ with or without definite biliary surgery is the established treatment of choice.¹¹⁴ Endoscopic segment dilatation and stone retrieval, electrohydraulic lithotripsy, and mechanical lithotripsy have also reported successful outcomes.^{115,116}

Bezoar-induced SBO is a less common differential of ASBO and constitutes 4% of SBO. Bezoars are masses of indigestible substances that accumulate in the GI system.¹¹⁷ The clinical presentation is similar to ASBO, and preoperative diagnosis can be difficult.¹¹⁸ Misdiagnosing bezoar-induced SBO could lead to increased morbidity.¹¹⁹ For bezoar-induced SBO, prompt surgical intervention is usually necessary. Hence, physicians must consider this differential and look out for signs on imaging that are suggestive of bezoars, such as the finding of a mass with mottled gas in the transition point on CT scan (diagnostic rate of 73–95% and accuracy of 65–100%).¹²⁰ Bezoars might also appear similar to feces in the small bowel. However, bezoars are more commonly single in number, appear as gas-containing masses, and have an encapsulating wall.¹²¹ In addition, patients with bezoar have a history of gastric surgery, poor dentition, or high fiber diet. In patients with suspected bezoar or patients without prior abdominal surgeries, early CT scans should be considered.¹²²

CONCLUSION

ADHESIVE SBO IS a common complication following abdominal surgery, with a significant impact on health-care resources and the burden of morbidity. The initial evaluation should focus on the identification of potential complications such as ischemia, strangulation, perforation, peritonitis, and systemic sepsis as urgent surgical management is required in these cases. Establishing the diagnosis of ASBO is necessary given the utility of non-operative management in ASBO. History of abdominopelvic surgery is highly suggestive of an ASBO, and CT imaging is used to assist in diagnosing and planning treatment. Initial management should focus on correcting fluid and electrolyte imbalances. A trial of non-operative management is feasible in patients without complications and can be continued for up to 3–4 days. Open midline laparotomy or LAL are both feasible, and careful handling of the bowel along with sharp scissor dissection are vital to minimize iatrogenic enterotomy. Laparoscopic adhesiolysis has better postsurgical outcomes and is preferred if patients are suitable. Prevention is a crucial cornerstone of management as recurrences are universal regardless of treatment method. Adhesion barriers have shown safety and efficacy in reducing adhesions.

DISCLOSURE

Approval of the research protocol: N/A.

Informed consent: N/A.

Registry and the registration no. of the study/trial: N/A.

Animal studies: N/A.

Conflict of interest: None.

REFERENCES

- 1 Maung AA, Johnson DC, Piper GL, *et al.* Evaluation and management of small-bowel obstruction: An Eastern Association for the Surgery of Trauma practice management guideline. *J. Trauma Acute Care Surg.* 2012; 73: S362–S369.
- 2 Millet I, Ruyer A, Alili C, *et al.* Adhesive small-bowel obstruction: Value of CT in identifying findings associated with the effectiveness of nonsurgical treatment. *Radiology* 2014; 273: 425–32.
- 3 Chou CK. CT manifestations of small bowel ischemia due to impaired venous drainage-with a correlation of pathologic findings. *Indian J. Radiol. Imaging* 2016; 26: 342.
- 4 Tabibian N, Swehli E, Boyd A, Umbreen A, Tabibian JH. Abdominal adhesions: A practical review of an often overlooked entity. *Ann. Med. Surg.* 2017; 15: 9–13.
- 5 Rami Reddy SR, Cappell MS. A systematic review of the clinical presentation, diagnosis, and treatment of small bowel obstruction. *Curr. Gastroenterol. Rep.* 2017; 19: 1–14.
- 6 Krielen P, van den Beukel BA, Stommel MWJ, van Goor H, Strik C, ten Broek RPG. In-hospital costs of an admission for adhesive small bowel obstruction. *World J. Emerg. Surg.* 2016; 11: 1–8.
- 7 Kössi JAO, Salminen PTP, Laato MK. Surgical workload and cost of postoperative adhesion-related intestinal obstruction: Importance of previous surgery. *World J. Surg.* 2004; 28: 666–70.
- 8 Ozturk E, van Iersel M, Stommel MMWJ, Schoon Y, ten Broek RRP, van Goor H. Small bowel obstruction in the elderly: A plea for comprehensive acute geriatric care. *World J. Emerg. Surg.* 2018; 13: 1–8.
- 9 Okabayashi K, Ashrafian H, Zacharakis E, *et al.* Adhesions after abdominal surgery: a systematic review of the incidence, distribution and severity. *Surg. Today* 2014; 44: 405–20.
- 10 Miller G, Boman J, Shrier I, Gordon PH. Natural history of patients with adhesive small bowel obstruction. *Br. J. Surg.* 2000; 87: 1240–7.
- 11 Beardsley C, Furtado R, Mosse C, *et al.* Small bowel obstruction in the virgin abdomen: the need for a mandatory laparotomy explored. *Am. J. Surg.* 2014; 208: 243–8.
- 12 Perea García J, Turégano Fuentes F, Quijada García B, *et al.* Adhesive small bowel obstruction: predictive value of oral contrast administration on the need for surgery. *Rev. Española Enfermedades Dig.* 2004; 96: 191–200.
- 13 Parker MC, Wilson MS, Menzies D, Sunderland G, Clark DN, Knight AD. The SCAR-3 study: 5-year adhesion-related readmission risk following lower abdominal surgical procedures. 2005:551–558.

- 14 Brüggmann D, Tcharchian G, Wallwiener M, Münstedt K, Tinneberg H-R, Hackethal A. Intra-abdominal Adhesions. *Dtsch. Aerzteblatt Online* 2010; 769–75.
- 15 Sozen S, Emir S, Yazar FM, *et al.* Small bowel obstruction due to anomalous congenital peritoneal bands-case series in adults. *Bratislava Med. J.* 2012; 113: 186–9.
- 16 Liakakos T, Thomakos N, Fine PM, Derveniz C, Young RL. Peritoneal adhesions: etiology, pathophysiology, and clinical significance. *Dig. Surg.* 2001; 18: 260–73.
- 17 Cheong YC, Laird SM, Li TC, Shelton JB, Ledger WL, Cooke ID. Peritoneal healing and adhesion formation/reformation. *Hum. Reprod. Update* 2001; 7: 556–66.
- 18 Frager DH, Baer JW. Role of CT in evaluating patients with small-bowel obstruction. *Semin. Ultrasound, CT, MRI* 1995; 16: 127–40.
- 19 Osada H, Watanabe W, Ohno H, *et al.* Multidetector CT appearance of adhesion-induced small bowel obstructions: Matted adhesions versus single adhesive bands. *Jpn J. Radiol.* 2012; 30: 706–12.
- 20 Duron JJ, du Montcel ST, Berger A, *et al.* Prevalence and risk factors of mortality and morbidity after operation for adhesive postoperative small bowel obstruction. *Am. J. Surg.* 2008; 195: 726–34.
- 21 Fevang BTS, Fevang J, Lie SA, Søreide O, Svanes K, Viste A. Long-term prognosis after operation for adhesive small bowel obstruction. *Ann. Surg.* 2004; 240: 193–201.
- 22 Delabrousse E, Lubrano J, Jehl J, *et al.* Small-bowel obstruction from adhesive bands and matted adhesions: CT differentiation. *Am. J. Roentgenol.* 2009; 192: 693–7.
- 23 Pothiwala S. Early diagnosis of bowel obstruction and strangulation by computed tomography in emergency department. *World J. Emerg. Med.* 2012; 3: 227.
- 24 Hellebrekers BWJ, Kooistra T. Pathogenesis of postoperative adhesion formation. *Br. J. Surg.* 2011; 98: 1503–16.
- 25 Mutsaers SE, Birnie K, Lansley S, Herrick SE, Lim CB, Prêle CM. Mesothelial cells in tissue repair and fibrosis. *Front. Pharmacol.* 2015; 6: 1–12.
- 26 Rajfer J. Role of fibrin in the development of surgical adhesions. *Rev. Urol.* 2005; 7: 238–39.
- 27 Arung W, Meurisse M, Detry O. Pathophysiology and prevention of postoperative peritoneal adhesions. *World J. Gastroenterol.* 2011; 17: 4545.
- 28 Seriau L, Lauretta A, Infantino A, *et al.* Abdominal adhesions: from formation to prevention - part one. *Soc. Ital. di Chir. Color* 2012; 42: 275–88.
- 29 DiZerega GS, Campeau JD. Peritoneal repair and post-surgical adhesion formation. *Hum. Reprod. Update* 2001; 7: 547–55.
- 30 Shi XZ, Lin YM, Hegde S. Novel Insights Into the Mechanisms of Abdominal Pain in Obstructive Bowel Disorders. *Front. Integr. Neurosci.* 2018; 12: 1–7.
- 31 Griffiths S, Glancy DG. Intestinal obstruction. *Surgery (Oxford)* 2020; 38: 43–50.
- 32 Faryniuk A, MacDonald A, Van Boxel P. Amnesia in modern surgery: Revisiting Wangensteen's landmark studies of small bowel obstruction. *Can. J. Surg.* 2015; 58: 83–4.
- 33 Kiela PR, Ghishan FK. Physiology of intestinal absorption and secretion. *Best Pract. Res. Clin. Gastroenterol.* 2016; 30: 145–59.
- 34 Bordeianou L, Yeh DD. Epidemiology, clinical features, and diagnosis of mechanical small bowel obstruction in adults. *UpToDate.* 2014.
- 35 Moran BJ. Adhesion-related small bowel obstruction. *Color. Dis.* 2007; 9(s2): 39–44.
- 36 ten Broek RPG, Krielen P, Di Saverio S, *et al.* Bologna guidelines for diagnosis and management of adhesive small bowel obstruction (ASBO): 2017 update of the evidence-based guidelines from the world society of emergency surgery ASBO working group. *World J. Emerg. Surg.* 2018; 13: 1–13.
- 37 Jackson PG, Raiji M. Evaluation and management of intestinal obstruction. *Am. Fam. Physician* 2011;83:159–65.
- 38 Markogiannakis H, Messaris E, Dardamanis D, *et al.* Acute mechanical bowel obstruction: Clinical presentation, etiology, management and outcome. *World. J. Gastroenterol.* 2007; 13: 432.
- 39 Nellgård P. Mechanisms of fluid losses in small-bowel obstruction. *Acta. Anaesthesiol. Scand.* 1996; 40: 1253.
- 40 Breum BM, Rud B, Kirkegaard T, Nordentoft T. Accuracy of abdominal auscultation for bowel obstruction. *World. J. Gastroenterol.* 2015; 21: 10018.
- 41 Huang X, Fang G, Lin J, Xu K, Shi H, Zhuang L. A prediction model for recognizing strangulated small bowel obstruction. *Gastroenterol. Res. Pract.* 2018: 1–7.
- 42 Murray MJ, Gonze MD, Nowak LR, Cobb CF. Serum D(-)-lactate levels as an aid to diagnosing acute intestinal ischemia. *Am. J. Surg.* 1994; 167: 575–78.
- 43 Lange H, Jackel R. Usefulness of plasma lactate concentration in the diagnosis of acute abdominal disease. *Eur. J. Surg. Acta Chir.* 1994; 160: 381–84.
- 44 Kittaka H, Akimoto H, Takeshita H, *et al.* Usefulness of intestinal fatty acid-binding protein in predicting strangulated small bowel obstruction. *PLoS One* 2014; 9: 1–8.
- 45 Sun DL, Cen YY, Li SM, Li WM, Lu QP, Xu PY. Accuracy of the serum intestinal fatty-acid-binding protein for diagnosis of acute intestinal ischemia: A meta-analysis. *Sci. Rep.* 2016; 6: 1–7.
- 46 Long B, Robertson J, Koyfman A. Emergency medicine evaluation and management of small bowel obstruction: evidence-based recommendations. *J. Emerg. Med.* 2019; 56: 166–76.
- 47 Catena F, Di Saverio S, Coccolini F, *et al.* Adhesive small bowel adhesions obstruction: Evolutions in diagnosis, management and prevention? *World J. Gastrointest. Surg.* 2016; 8: 222.

- 48 Ha HK, Park CH, Kim SK, *et al.* Ct analysis of intestinal obstruction due to adhesions: Early detection of strangulation. *J. Comput. Assist Tomogr.* 1993;17:386-9.
- 49 Köstenbauer J, Truskett PG. Current management of adhesive small bowel obstruction. *ANZ J Surg* 2018;88:1117-22.
- 50 Ceresoli M, Coccolini F, Catena F, *et al.* Water-soluble contrast agent in adhesive small bowel obstruction: A systematic review and meta-analysis of diagnostic and therapeutic value. *Am. J. Surg.* 2016; 211: 1114–25.
- 51 Branco BC, Barmparas G, Schnüriger B, Inaba K, Chan LS, Demetriades D. Systematic review and meta-analysis of the diagnostic and therapeutic role of water-soluble contrast agent in adhesive small bowel obstruction. *Br. J. Surg.* 2010; 97: 470–8.
- 52 Köstenbauer J. Managing adhesive small bowel obstruction with water-soluble contrast should be protocolized: a retrospective analysis. *Surg. J.* 2018; 04: e123–e128.
- 53 Fleshner PR, Siegman MG, Slater GI, Brolin RE, Chandler JC, Aufses AH. A prospective, randomized trial of short versus long tubes in adhesive small-bowel obstruction. *Am. J. Surg.* 1995; 170: 366–70.
- 54 Sekiba K, Ohmae T, Odawara N, *et al.* A new method for insertion of long intestinal tube for small bowel obstruction Nonendoscopic over-the-wire method via short nasogastric tube. *Med (United States)* 2016; 95: e5449.
- 55 Jackson P, Cruz MV. Intestinal obstruction: Evaluation and management. *Am. Fam. Physician* 2018; 98: 362–67.
- 56 Richard PG, Issa Y, Van Santbrink EJP, *et al.* Burden of adhesions in abdominal and pelvic surgery: Systematic review and met-analysis. *BMJ* 2013; 347: 1–15.
- 57 Assalia A, Schein M, Kopelman D, Hirshberg A, Hashmonai M. Therapeutic effect of oral Gastrografin in adhesive, partial small-bowel obstruction: A prospective randomized trial. *Surgery* 1994;115:433-7.
- 58 Abbas S, Bissett IP, Parry BR. Oral water soluble contrast for the management of adhesive small bowel obstruction. *Cochrane Database Syst. Rev.* 2007: 1–25.
- 59 Koh A, Adiamah A, Chowdhury A, Mohiuddin MK, Bharathan B. Therapeutic role of water-soluble contrast media in adhesive small bowel obstruction: a systematic review and meta-analysis. *J. Gastrointest. Surg.* 2020; 24: 473–8.
- 60 Keenan JE, Turley RS, McCoy CC, Migaly J, Shapiro ML, Scarborough JE. Trials of nonoperative management exceeding 3 days are associated with increased morbidity in patients undergoing surgery for uncomplicated adhesive small bowel obstruction. *J. Trauma Acute Care Surg.* 2014; 76: 1367–72.
- 61 Schraufnagel D, Rajae S, Millham FH. How many sunsets? Timing of surgery in adhesive small bowel obstruction: A study of the Nationwide Inpatient Sample. *J. Trauma Acute Care Surg.* 2013; 74: 181–9.
- 62 Bauer J, Keeley B, Krieger B, *et al.* Adhesive small bowel obstruction: Early operative versus observational management. *Am Surg* 2015; 81: 614–20.
- 63 Di Saverio S, Catena F, Ansaloni L, Gavioli M, Valentino M, Pinna AD. Water-soluble contrast medium (Gastrografin) value in adhesive small intestine obstruction (Asio): A prospective, randomized, controlled, clinical trial. *World J. Surg.* 2008; 32: 2293–304.
- 64 Behman R, Nathens AB, Mason S, *et al.* Association of Surgical Intervention for Adhesive Small-Bowel Obstruction with the Risk of Recurrence. *JAMA Surg.* 2019; 154: 413.
- 65 Nordin A, Freedman J. Laparoscopic versus open surgical management of small bowel obstruction: an analysis of clinical outcomes. *Surg. Endosc.* 2016; 30: 4454–63.
- 66 Saleh F, Ambrosini L, Jackson T, Okrainec A. Laparoscopic versus open surgical management of small bowel obstruction: An analysis of short-term outcomes. *Surg. Endosc.* 2014; 28: 2381–6.
- 67 Köckerling F, Simon T, Hukauf M, *et al.* The Importance of Registries in the Postmarketing Surveillance of Surgical Meshes. *Ann. Surg.* 2017; 268: 1097–104.
- 68 Sallinen V, Di Saverio S, Haukijärvi E, *et al.* Laparoscopic versus open adhesiolysis for adhesive small bowel obstruction (LASSO): an international, multicentre, randomised, open-label trial. *Lancet. Gastroenterol. Hepatol.* 2019; 4: 278–86.
- 69 Byrne J, Saleh F, Ambrosini L, Queresby F, Jackson TD, Okrainec A. Laparoscopic versus open surgical management of adhesive small bowel obstruction: a comparison of outcomes. *Surg. Endosc.* 2015; 29: 2525–32.
- 70 Sajid MS, Khawaja AH, Sains P, Singh KK, Baig MK. A systematic review comparing laparoscopic vs open adhesiolysis in patients with adhesional small bowel obstruction. *Am. J. Surg.* 2016; 212: 138–50.
- 71 Sebastian-Valverde E, Poves I, Membrilla-Fernández E, Pons-Fragero MJ, Grande L. The role of the laparoscopic approach in the surgical management of acute adhesive small bowel obstruction. *BMC Surg.* 2019; 19: 1–7.
- 72 Li MZ, Lian L, Bin XL, Wu WH, He YL, Song XM. Laparoscopic versus open adhesiolysis in patients with adhesive small bowel obstruction: A systematic review and meta-analysis. *Am. J. Surg.* 2012;204:779-86.
- 73 Strik C, Wever KE, Stommel MWJ, van Goor H, ten Broek RPG. Adhesion reformation and the limited translational value of experiments with adhesion barriers: A systematic review and meta-analysis of animal models. *Sci Rep.* 2019; 9: 1–10.
- 74 Amirthalingam V, Low JK, Woon W, Shelat V. Tokyo Guidelines 2013 may be too restrictive and patients with moderate and severe acute cholecystitis can be managed by early cholecystectomy too. *Surg Endosc* 2017;31:2892-900.

- 75 Vettoretto N, Carrara A, Corradi A, *et al.* Laparoscopic adhesiolysis: Consensus conference guidelines. *Color Dis.* 2012;14:e208-e215.
- 76 Farinella E, Cirocchi R, La Mura F, *et al.* Feasibility of laparoscopy for small bowel obstruction. *World J. Emerg. Surg.* 2009;4:3.
- 77 Grafen FC, Neuhaus V, Schöb O, Turina M. Management of acute small bowel obstruction from intestinal adhesions: Indications for laparoscopic surgery in a community teaching hospital. *Langenbeck's Arch. Surg.* 2010; 395:57–63.
- 78 Di Saverio S, Birindelli A, Ten BR, Davies JR, Mandrioli M, Sallinen V. Laparoscopic adhesiolysis: not for all patients, not for all surgeons, not in all centres. *Updates Surg.* 2018;70:557-61.
- 79 Barkan H, Webster S, Ozeran S. Factors predicting the recurrence of adhesive small-bowel obstruction. *Am J Surg* 1995; 170: 361–5.
- 80 Yang KM, Yu CS, Lee JL, *et al.* The long-term outcomes of recurrent adhesive small bowel obstruction after colorectal cancer surgery favor surgical management. *Medicine (United States)* 2017; 96 :1–6.
- 81 Foster NM, McGory ML, Zingmond DS, Ko CY. Small bowel obstruction: a population-based appraisal. *J. Am. Coll. Surg.* 2006. <https://doi.org/10.1016/j.jamcollsurg.2006.04.020>.
- 82 Ten Broek RPG, Bakkum EA, Van Laarhoven CJHM, Van Goor H. Epidemiology and prevention of postsurgical adhesions revisited. *Ann Surg.* 2016.
- 83 Ten Broek RPG, Kok-Krant N, Bakkum EA, Bleichrodt RP, Van Goor H. Different surgical techniques to reduce postoperative adhesion formation: A systematic review and meta-analysis. *Hum. Reprod. Update* 2013; 19: 12–25.
- 84 Molinas CR, Binda MM, Manavella GD, Koninckx PR. Adhesion formation after laparoscopic surgery: what do we know about the role of the peritoneal environment? *Facts Views Vis ObGyn.* 2010; 2: 149–60.
- 85 Hellebrekers BWJ, Trimbos-Kemper TCM, Trimbos JBMZ, Emeis JJ, Kooistra T. Use of fibrinolytic agents in the prevention of postoperative adhesion formation. *Fertil Steril* 2000;74:203-12.
- 86 Buttram VC, Gomel V, Siegler A, DeCherney A, Gibbons W, March C. The American Fertility Society classifications of adnexal adhesions, distal tubal occlusion, tubal occlusion secondary to tubal ligation, tubal pregnancies, Mullerian anomalies and intrauterine adhesions. *Fertil. Steril.* 1988; 49: 944–55.
- 87 The role of fibrinolytics in prevention of adhesive intestinal obstruction.
- 88 Arjmand MH, Zahedi-Avval F, Barneh F, *et al.* Intraperitoneal Administration of Telmisartan Prevents Postsurgical Adhesion Band Formation. *J. Surg. Res.* 2020; 248: 171–81.
- 89 Arab HH, Al-Shorbagy MY, Abdallah DM, Nassar NN. Telmisartan attenuates colon inflammation, oxidative perturbations and apoptosis in a rat model of experimental inflammatory bowel disease. *PLoS One* 2014; 9: e97193.
- 90 Jilani TN, Siddiqui AH. *Tissue Plasminogen Activator.* In: Statpearls; 2020.
- 91 Ten Broek RPG, Stommel MWJ, Strik C, Van Laarhoven CJHM, Keus F, Van Goor H. Benefits and harms of adhesion barriers for abdominal surgery: A systematic review and meta-analysis. *Lancet.* 2014; 383: 48–59.
- 92 Vrijland WW, Tseng LNL, Eijkman HJM, *et al.* Fewer intraperitoneal adhesions with use of hyaluronic acid-carboxymethylcellulose membrane: A randomized clinical trial. *Ann Surg* 2002; 235: 193–9.
- 93 Fazio VW, Cohen Z, Fleshman JW, *et al.* Reduction in adhesive small-bowel obstruction by Seprafilm® adhesion barrier after intestinal resection. *Dis. Colon Rectum* 2006; 49: 1–11.
- 94 Catena F, Ansaloni L, Di SS, Pinna AD. P.O.P.A. Study. Prevention of Postoperative Abdominal Adhesions by Icodextrin 4% Solution After Laparotomy for Adhesive Small Bowel Obstruction. A Prospective Randomized Controlled Trial. *J. Gastrointest. Surg.* 2012; 16: 382–8.
- 95 Holmdahl L, Kotseos K, Bergström M, Falk P, Ivarsson ML, Chegini N. Overproduction of transforming growth factor- β 1 (TGF- β 1) is associated with adhesion formation and peritoneal fibrinolytic impairment. *Surgery* 2001; 129: 626–32.
- 96 Kai M, Maeda K, Tasaki M, *et al.* Evaluation of a Spray-type, Novel Dextrin Hydrogel Adhesion Barrier Under Laparoscopic Conditions in a Porcine Uterine Horn Adhesion Model. *J. Minim. Invasive. Gynecol.* 2018; 25: 447–54.
- 97 Chino N, Ishihara H, Niimi T, Kai M, Kawanishi T. Development of a spray-type adhesion barrier. *Polym. J.* 2020; 52: 1–7.
- 98 Ahmad M, Crescenti F. Significant adhesion reduction with 4dryfield ph after release of adhesive small bowel obstruction. *Surg J.* 2019; 5: 28–34.
- 99 Blumhardt G, Haas M, Polte S. Effect of 4DryField® PH, a Novel Adhesion Barrier, on Recurrence of Intestinal Adhesions after Extensive Visceral Adhesiolysis. *Case Rep. Surg.* 2018; 2018: 1–6.
- 100 Jeong JJ, Lee DW, Song SY, *et al.* Development of novel biocompatible thermosensitive anti-adhesive agents using human-derived acellular dermal matrix. *PLoS One* 2019: 1–9.
- 101 La Denise Prost À J, Douard R, Malamut G, Mecheri F, Wind P. Small bowel obstruction in patients with a prior history of cancer: Predictive findings of malignant origins. *World J. Surg.* 2014; 38: 363–9.
- 102 Low RN, Chen SC, Barone R. Distinguishing benign from malignant bowel obstruction in patients with malignancy: Findings at MR imaging. *Radiology* 2003; 228: 157–65.
- 103 Winner M, Mooney SJ, Hershman DL, *et al.* Management and outcomes of bowel obstruction in patients with stage IV colon cancer: A population-based cohort study. *Dis. Colon Rectum* 2013; 56: 834–43.

- 104 Henry JC, Pouly S, Sullivan R, *et al.* A scoring system for the prognosis and treatment of malignant bowel obstruction. *Surgery (United States)* 2012; 152: 756–7.
- 105 Sebastiano Mercadante MPalliative care of bowel obstruction in cancer patients. In: UpToDate.
- 106 Miller G, Boman J, Shrier I, Gordon PH. Etiology of small bowel obstruction. *Am. J. Surg.* 2000; 180: 33–6.
- 107 Bower KL, Lollar DI, Williams SL, Adkins FC, Luyimbazi DT, Bower CE. Small Bowel Obstruction. *Surg. Clin. North Am.* 2018; 98: 945–71.
- 108 Costa G, Ruscelli P, Balducci G, *et al.* Clinical strategies for the management of intestinal obstruction and pseudo-obstruction. *Ann. Ital. Chir.* 2016; 87: 105–17.
- 109 Halabi WJ, Kang CY, Ketana N, *et al.* Surgery for gallstone ileus: A nationwide comparison of trends and outcomes. *Ann. Surg.* 2014; 259: 329–35.
- 110 Chang L, Chang M, Chang HM, Chang AI, Chang F. Clinical and radiological diagnosis of gallstone ileus: a mini review. *Emerg. Radiol.* 2018; 25: 189–96.
- 111 Gurvits GE, Lan G. Enterolithiasis. *World J. Gastroenterol.* 2014; 20: 17819–29.
- 112 Ihara E, Ochiai T, Yamamoto K, Kabemura T, Harada N. A case of gallstone ileus with a spontaneous evacuation. *Am J Gastroenterol* 2002; 97: 1259–60.
- 113 Shiwani MH, Ullah Q. Laparoscopic enterolithotomy is a valid option to treat gallstone ileus. *J Soc Laparoendosc Surg.* 2010; 14: 282–5.
- 114 Ploneda-Valencia CF, Gallo-Morales M, Rinchon C, *et al.* Gallstone ileus: An overview of the literature. *Rev. Gastroenterol. Mex.* 2017; 82: 248–54.
- 115 Moriai T, Hasegawa T, Fuzita M, Kimura A, Tani T, Makino I. Successful removal of massive intragastric gallstones by endoscopic electrohydraulic lithotripsy and mechanical lithotripsy. *Am. J. Gastroenterol.* 1991.
- 116 Patel I, Romanoff A, Bansal R, Rosberger S, Ahmad S, Mestre J. Gallstone induced small bowel obstruction. *QJM* 2017; hcw215.
- 117 Teng TZJ, Tan YP, Shelat VG. Persimmon fruit causing simultaneous small bowel and stomach obstruction. *Singapore Med. J.* 2019; 60: 550.
- 118 Shelat VG, Tan J. Durian seed causing small bowel obstruction. *Dig. Surg.* 2009; 26: 212.
- 119 Escamilla C, Robles-Campos R, Parrilla-Paricio P, Lujan-Mompean J, Liron- Ruiz R, Torralba-Martinez JA. Intestinal obstruction and bezoars. *J Am Coll Surg.* 1994; 179: 285–8.
- 120 Ho TW, Koh DC. Small-bowel obstruction secondary to bezoar impaction: A diagnostic dilemma. *World J. Surg.* 2007; 31: 1073–9.
- 121 Kim JH, Ha HK, Sohn MJ, *et al.* CT findings of phytobezoar associated with small bowel obstruction. *Eur Radiol* 2003; 13: 299–304.
- 122 Oh SH, Namgung H, Park MH, Park DG. Bezoar-induced small bowel obstruction. *J. Korean Soc. Coloproctol.* 2012.
- 123 Al Salamah SM, Fahim F, Hameed AMA, Abdulkarim AA, Al Mogbal ES, Al Shaer A. How predictive are the signs and symptoms of Small Bowel Obstruction. *Oman Med. J.* 2012; 27: 281–4.
- 124 Jang TB, Schindler D, Kaji AH. Predictive value of signs and symptoms for small bowel obstruction in patients with prior surgery. *Emerg. Med. J.* 2012; 27: 281–4.
- 125 Eskelinen M, Ikonen J, Lipponen P. Contributions of history-taking, physical examination, and computer assistance to diagnosis of acute small-bowel obstruction: A prospective study of 1333 patients with acute abdominal pain. *Scand. J. Gastroenterol.* 1994; 29: 715–21.
- 126 Sarr MG, Bulkley GB, Zuidema GD. Preoperative recognition of intestinal strangulation obstruction. Prospective evaluation of diagnostic capability. *Am. J. Surg.* 1983; 145: 176–82.