

Experience with Liposuction for the Treatment of Subcutaneous Lipoma: A Case Series from a Tertiary Health Institution in Nigeria

Abstract

Background: Lipomas are the commonest benign tumours in the body. Treatment is often by excision biopsy. Liposuction has traditionally been used for body sculpturing, but recently, it was introduced for the operative management of lipomas. The aim of this study was to present our experience with liposuction lipectomy-assisted lipoma aspiration in terms of its efficacy, complications, risk of recurrence, and patient satisfaction. **Materials and Methods:** A retrospective review of 16 patients with solitary or multiple lipomas managed with liposuction over a 5-year period was done. All the patients had a prior fine needle aspiration cytology, which was reported as benign. Informed consent was obtained, and the procedures were performed as a day case under tumescent anaesthesia. Lipo-aspiration was done with manual liposuction device. The patients were discharged on oral analgesics and antibiotics. **Results:** Sixteen patients (10 females and six males) with 21 lesions were managed. The median age was 43 years (23–66 years). All the patients had satisfactory outcomes. The procedure was converted to open-excisional surgery in one patient, and the histology was reported as fibro lipoma. Friction burn at the cannula site occurred in one patient, which subsequently healed with scars. No recurrence was reported in any of the patients. **Conclusion:** In well-selected patients, liposuction-assisted lipectomy may have an advantage over the classical open technique. All patients should have a minimum investigation of fine needle aspiration cytology because of the risk of atypical lipomas or liposarcoma, which might have similar features as subcutaneous lipoma.

Keywords: *Lipectomy, lipoma, lipoma management, liposuction*

Introduction

Lipomas are the most common benign mesenchymal tumours in the human body. They arise from the adipose tissue and are mostly encapsulated.^[1] They are most commonly found in the subcutaneous tissue plane of the trunks and extremities.^[2] Because of their superficial location, they often become obvious even when small and may pose significant cosmetic concerns, especially in females. Many patients are without symptoms. However, the fear of malignancy and the concern with disfigurement, especially with larger lesions, make many patients seek its removal. The traditional method of treatment is by open-excisional surgery, which may be complicated with scarring, especially in Africans and those predisposed to fibro-proliferative disorders. Open excision is also fraught with longer operation time, increased blood loss, greater perioperative pain, and longer wound-healing time. In

order to minimise these complications, less invasive options have been tried in the last few decades. These include the use of lasers,^[3,4] subcutaneous deoxycholate injections,^[5] endoscopic-assisted suction extraction,^[6] and liposuction.^[7-12]

Liposuction was first used in 1975 and has become a common surgical procedure.^[13] At its onset, it was primarily used for body contouring and sculpturing. Currently, there are several indications for its use, such as lipodystrophy, gynaecomastia, axillary hyperhidrosis, body asymmetry, and lipoma.^[13,14]

Herein, we report our experience with tumescent liposuction in a case series of patients who presented with subcutaneous lipoma.

Materials and Methods

This study was a retrospective review of 16 patients with 21 lesions who presented over a 5-year period between February

Olayinka Adebajji Olowoye^{1,2},
Afieharo I. Michael^{1,2},
Rotimi Aderibigbe²,
Kayode Iyun²,
Samuel Ademola^{1,2},
Odunayo M. Oluwatosin^{1,2}

¹Department of Surgery, College of Medicine, University of Ibadan, Ibadan, ²Department of Plastic, Reconstructive and Aesthetic Surgery, University College Hospital, Ibadan, Nigeria

Received: 16-Aug-2022

Accepted: 19-Aug-2022

Published: 23-Nov-2022

Address for correspondence:

Dr. Olayinka Adebajji Olowoye,
Department of Surgery, College of Medicine, University of Ibadan, Ibadan, Nigeria.
E-mail: yinkaolawoye@yahoo.co.uk

Access this article online

Website:

www.jwacs-jcoac.com

DOI: 10.4103/jwas.jwas_172_22

Quick Response Code:



How to cite this article: Olowoye OA, Michael AI, Aderibigbe R, Iyun K, Ademola S, Oluwatosin OM. Experience with liposuction for the treatment of subcutaneous lipoma: A case series from a tertiary health institution in Nigeria. *J West Afr Coll Surg* 2022;12:117-21.

This is an open access journal, and articles are distributed under the terms of the Creative Commons Attribution-NonCommercial-ShareAlike 4.0 License, which allows others to remix, tweak, and build upon the work non-commercially, as long as appropriate credit is given and the new creations are licensed under the identical terms.

For reprints contact: reprints@medknow.com

2015 and January 2020. The clinical evaluation of the patients revealed lesions with classical features consistent with subcutaneous lipomas. All the patients subsequently had fine needle aspiration cytology (FNAC), which were reported as benign. The biodata of the patients and location(s) and size(s) of the lesions were documented. Informed consent was obtained from each patient. The procedures were performed as a day case surgery using tumescent anaesthesia, prepared by a mixture of 10 mL of 2% lignocaine, 0.5 mL of 1:1000 adrenaline, and 500 mL of normal saline, giving a concentration of 0.04% lignocaine and 1:1 million adrenaline. An appropriate volume of the fluid was infused into each lesion until tumescence was achieved. A minimum of 10 min was allowed after infusion to achieve satisfactory tumescent anaesthesia.

Afterward, one or two small incisions for liposuction cannulas were made at the periphery of the lipoma with a no. 11 scalpel blade. One or both of the incisions were usually positioned in line with the long axis of the lesions (and opposite to each other when two incisions were required) to allow for satisfactory tunnelling through the lesion.

The lipo-aspiration was done with a 4-mm cannula connected to a manual 60-mL luer-lock syringe with a stopper for negative pressure [Figure 1]. The basic concept is that fat lobules are bluntly broken down, curetted by a cannula, and removed through the cannula's aperture by a vacuum force generated from a suction syringe. One or two stitches were applied with a 4/0 nylon suture to the incision sites after aspiration. Firm pressure dressing was applied over each site to prevent seroma or haematoma

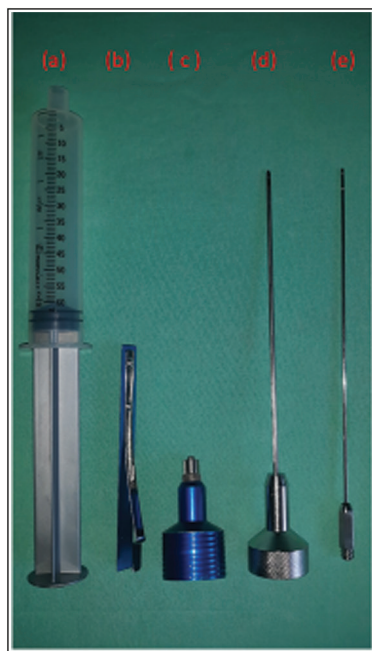

Figure 1: Manual liposuction set: (a) aspiration syringe, (b) syringe lock, (c) syringe luer adapter for infiltration cannula, (d) aspiration cannula, and (e) tumescent infiltration cannula

formation. No drains were used in all the patients. The patients were discharged the same day on oral analgesics for 3 days and antibiotics for 5 days. The first postoperative review was done on the third day, and sutures were removed on the seventh day. The patients were followed up for any complication or recurrence.

Results

Sixteen patients consisting of six males and 10 females (M:F = 1:1.7) were managed over a 5-year period. Thirteen of the patients had solitary lesions, and the remaining three had multiple lesions. The smallest of the lesions measured 5 × 4 cm, whereas the biggest lesion was 13 × 12 cm. The median age of the patients was 43 years (range: 23–66 years). Eleven of the lesions were located on the posterior trunk, six on the anterior trunk and abdomen, and four lesions on the upper extremity [Table 1].

Lipo-aspiration was challenging and limited in one of the male patients whose lesion was located in the midline of the posterior trunk, which necessitated the conversion of the procedure to open-excisional surgery. The lesion appeared fibrous and firm after excision, and the histology was reported as fibrolipoma. None of the patients required oral analgesics beyond the third day postoperation. The early complications following liposuction include a friction burn at the cannula site in one patient and a haematoma at the site of the lesion in another patient, which resolved with conservative care. All the other patients had satisfactory healing after the spontaneous resolution of the initial dimpling and ecchymosis within the first week after the procedure. The only late complication was the burn scar in the patient who had a friction burn at the cannula site. None of the patients had a recurrence within the follow-up duration, which ranged from 1 to 28 months. Figures 2 and 3 depict the pre- and postoperative pictures of two of the patients.

Discussion

Attempts to remove fatty tissues through surgical methods date back to the 1920s, when French physicians used a curette to remove fat from a patient's knees. This resulted in infection and amputation.^[15] In the 1960s, Dr. Josef Schrudde, a plastic surgeon from Cologne, West Germany, introduced the term lipexeresis (the removal of fat). This is performed by curetting fatty tissue from a subcutaneous tunnel formed by scissors in a localised adipose deposit.^[16] The remaining fat particles are irrigated and vigorously suctioned. Further modifications were described by Kesselring in the mid-1970s.^[17]

In 1976, Fischer and Fischer described the “cellusuctiotome,” a surgical suction instrument, which was combined with an undermining device.^[18] Unfortunately, it was associated with significant complications and had to be abandoned. Subsequently, the Parisian surgeons, Illouz

Table 1: Characteristics of patients' lesions

Serial number	Age (years)	Sex	Location of the lesion	Size of the lesion (cm)
1	63	Male	Posterior trunk	10×8
2	47	Male	Anterior trunk	13×11
3	27	Female	Right arm	11×7
4	56	Male	Anterior trunk	13×9
5a	66	Male	Posterior trunk	7×6
5b				9×8
6	63	Female	Anterior trunk	9×6
7	23	Female	Anterior trunk	6×5
8	33	Female	Anterior trunk	10×8
9	42	Female	Posterior trunk	5×4
10	37	Male	Posterior trunk	9×6
11	42	Female	Anterior trunk	13×12
12a	59	Female	Posterior trunk	12×6
12b				13×8
12c			Left arm	11×8,5
13	49	Male	Posterior trunk	10×9
14a	56	Female	Posterior trunk	13×10
14b				12×11
14c				8×7
15	43	Female	Anterior trunk	13×12

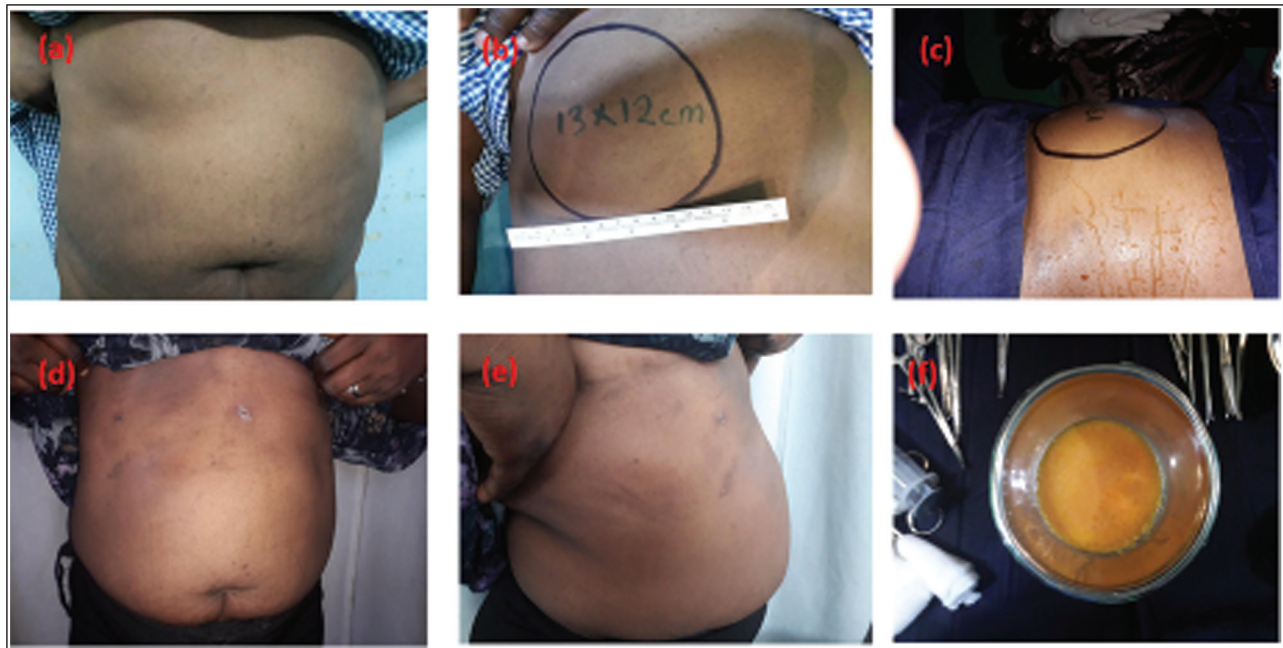

Figure 2: Pre- and postoperative pictures of one of the female patients: (a) preoperative anterior–posterior view showing the lesion on the right hypochondrium, (b) preoperative view in the supine position, (c) intraoperative view, (d) postoperative view in the antero-posterior plane, (e) postoperative view in the right oblique plane, and (f) yellowish lipo-aspirate from the patient

and Fournier, popularised the surgical suction device developed by Fischer. Following further refinements, this evolving technique became known as liposuction and was widely embraced by medical practitioners from various specialties.^[19] Throughout this period, liposuction surgery was mostly performed under general anaesthesia. But in 1987, a dermatologist named Jeffrey Klein first reported the use of large volumes of very dilute anaesthesia, which allowed significant liposuction to occur using only local

anaesthesia.^[20] This technique was termed “tumescent anaesthesia.”^[21,22] Although it has undergone subtle refinements in subsequent years, it remains the backbone of liposuction currently used around the world.

Liposuction has rapidly evolved into the most commonly requested cosmetic surgery.^[23] This innovative procedure allows body sculpturing through minute incisions by combining the existing techniques of undermining and curettage with high-pressure suction. Like previous medical

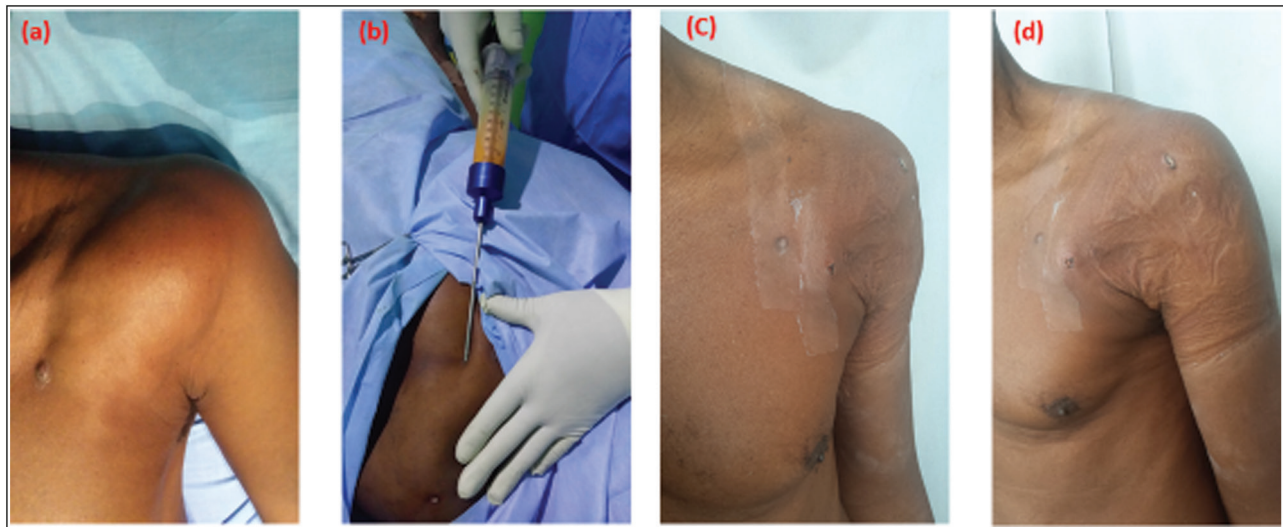


Figure 3: Pre-, intra-, and postoperative pictures of one of the male patients: (a) preoperative view of the patient showing the lesion on the left anterior axillary area, (b) intraoperative photograph of lipo aspiration, (c) postoperative antero-posterior view, and (d) postoperative left oblique view

innovations, this technique has spawned interest in many other noncosmetic applications. The development of these new noncosmetic liposuction procedures has broadened the scope of liposuction surgery and increased its appeal to both dermatologic and plastic surgeons.^[8]

The most common noncosmetic use is in the removal of lipomas. Other noncosmetic uses of liposuction include flap defatting, gynaecomastia, pseudogynaecomastia, lymphoedema, benign symmetric lipomatosis, breast reduction, hypertrophic insulin lipodystrophy, buffalo hump, evacuating haematoma, emergency neck defatting for airway restoration, and axillary hyperhidrosis.^[8]

Surgical excision remains the most utilised treatment option of lipomas. This, however, usually involves large incisions and a multilayered closure, with a greater risk of bleeding and postoperative wound complications.^[7] Although this modality of care is effective, wound healing is usually associated with scarring,^[5] especially in Africans and patients with fibro-proliferative disorders. The resulting scar(s) may be hypertrophic or keloidal, with significant disfigurement and cosmetic concerns, especially with lesions located on the exposed parts of the body. The disfigurement may be aggravated when multiple lesions are removed. Bigger lesions may also require excisions under general anaesthesia in an operating room, which adds to the cost and possible morbidity.^[7]

Liposuction lipectomy has become a viable alternative in the management of subcutaneous lipoma because of the obvious advantages, which include minimal incisions, shorter operation time, reduced blood loss, faster postoperative recovery, reduced wound-healing complications, and, most importantly, the superior cosmetic result following treatment.

About two-thirds (62.7%) of the patients were female, with 70% of them between the third and fifth decades

of life. This is usually the age when the body image is of greater significance to women, and many who require surgery will desire to have surgical options that will leave minimal or no scars on the body. Three (18.8%) of the patients had multiple lesions and two of them had three localised lesions each, whereas another patient had two lesions. These required more than one stab incisions for the suction cannula, which all healed without scars, giving the much desired cosmetic outcome. Conventional excisional surgery would have required multiple larger incisions with the risk of unsightly scars after healing. All the lesions were bigger than 4cm, which is the minimum size of lipomas recommended for liposuction.^[24] The mean length of the main axis of the lipomas was 10.3cm (range: 5–13cm). One of the early patients in the series had a friction burn at the cannula site, which healed with a scar. Following this finding, subsequent patients had excision of about 1mm margin of the skin rim at the cannula site before wound apposition with a stitch or two. We recommend this step because of the potential friction injury from the repeated movement of the metal cannula at the incision site. The liposuction procedure in one of our patients had to be aborted and converted to an open-excision biopsy because of limited aspiration. The lesion that had the preoperative fine-needle aspiration cytology reported as a benign was subsequently reported as fibrolipoma on histology of the specimen. The lesion was located in the midline of the posterior trunk of one of the male patients and had the clinical characteristics of a subcutaneous lipoma on physical examination preoperatively. All the other lesions (95.2%) were successfully aspirated through the liposuction device with the characteristic yellowish lipo-aspirate. The clinical features of a slowly growing, soft, and homogenous nontender, lobulated mass with positive slipping sign in the subcutaneous tissue plane is a characteristic of lipoma. These, in addition to a benign

FNAC report, are sufficient indications for the use of liposuction in its surgical treatment.

Despite the increasing application of liposuction for lipoma treatment in many developed countries,^[11-17] there has not been any report of its use in the West African subregion. This may be as a result of the slowly evolving practice of cosmetic surgery.^[25] The procedure is simple, with a short learning curve and potential benefits for all patients presenting with lipomas, especially those with multiple lesions and tendency for scarring. It is therefore important for plastic, dermatologic, and general surgeons to add liposuction to the armamentarium of care when counselling patients for its surgical removal.

Conclusion

Liposuction is an exciting technique, which is gaining rapid acceptance for the removal of unwanted fat deposits, whether localised as lipoma or generalised, and requiring body sculpturing. Although surgical excision of lipomas is still indicated, liposuction provides a safe, simple, and effective option in treating these lesions. Careful patient selection and benign cytology on fine needle aspiration should ensure a successful outcome.

Declaration of patient consent

The authors certify that they have obtained all appropriate patient consent forms. In the form the patient(s) has/have given his/her/their consent for his/her/their images and other clinical information to be reported in the journal. The patients understand that their names and initials will not be published and due efforts will be made to conceal their identity, but anonymity cannot be guaranteed.

Financial support and sponsorship

Nil.

Conflicts of interest

There are no conflicts of interest.

References

1. Plötz S, Hein R, Ring J. Virusinduzierte benigne Hauttumoren (Warzen). In: Häufige Hauttumoren in der Praxis. Berlin, Heidelberg: Springer; 2012. https://doi.org/10.1007/978-3-642-24702-6_11.
2. Koh HK, Bhawan J. Tumors of the skin. In: Moschella SL, Hurley HJ, editors. Dermatology. 3rd ed. Philadelphia: Saunders; 1992. p. 1721-808.
3. Goldman A, Wollina U. Lipoma treatment with a subdermal Nd:YAG laser technique. *Int J Dermatol* 2009;48:1228-32.
4. Lee SH, Jung JY, Roh MR, Chung KY. Treatment of lipomas using a subdermal 1,444-nm micropulsed neodymium-doped yttrium aluminum garnet laser. *Dermatol Surg* 2011;37:1375-6.
5. Rotunda AM, Ablon G, Kolodney MS. Lipomas treated with subcutaneous deoxycholate injections. *J Am Acad Dermatol* 2005;53:973-8.
6. Hallock GG. Endoscope-assisted suction extraction of lipomas. *Ann Plast Surg* 1995;34:32-4.
7. Rubenstein R, Roenigk HH Jr, Garden JM, Goldberg NS, Pinski JB. Liposuction for lipomas. *J Dermatol Surg Oncol* 1985;11:1070-4.
8. Coleman WP 3rd. Noncosmetic applications of liposuction. *J Dermatol Surg Oncol* 1988;14:1085-90.
9. Spinowitz AL. Liposuction surgery: An effective alternative for treatment of lipomas. *Plast Reconstr Surg* 1990;86:606.
10. Pinski KS, Roenigk HH Jr. Liposuction of lipomas. *Dermatol Clin* 1990;8:483-92.
11. Boyer M, Monette S, Nguyen A, Zipp T, Aughenbaugh WD, Nimunkar AJ. A review of techniques and procedures for lipoma treatment. *Clinic Dermatol* 2015;3:105-12.
12. Peev I, Spasevska L, Mirchevska E, Tudzarova-Gjorgova S. Liposuction assisted lipoma removal—Option or alternative? *Open Access Maced J Med Sci* 2017;5:766-70.
13. Al-basti HA, El-Khatib HA. The use of suction-assisted surgical extraction of moderate and large lipomas: Long-term follow-up. *Aesthetic Plast Surg* 2002;26:114-7.
14. Apesos J, Chami R. Functional applications of suction-assisted lipectomy: A new treatment for old disorders. *Aesthetic Plast Surg* 1991;15:73-9.
15. Glazer F. Suction-assisted lipectomy, suction lipectomy, lipolysis and lipexeresis. *Plast Reconstr Surg* 1983;72:620-3.
16. Schrudde J. Lipexeresis as a means of eliminating local adiposity. *Aesthetic Plast Surg* 1980;4:215-26.
17. Kesselring UK, Meyer R. A suction curette for removal of excessive local deposits of subcutaneous fat. *Plast Reconstr Surg* 1978;62:305-6.
18. Fischer A, Fischer GM. Revised technique for cellulitis fat reduction in riding breeches deformity. *Bull Int Acad Cosmet Surg* 1977;2:40.
19. Markey AC. Liposuction in cosmetic dermatology. *Clin Exp Dermatol* 2001;26:3-5.
20. Klein JA. The tumescent technique for liposuction surgery. *Am J Cosmet Surg* 1987;4:263-7.
21. Klein JA. Tumescent technique for regional anesthesia permits lidocaine doses of 35 mg/kg for liposuction. *J Dermatol Surg Oncol* 1990;16:248-63.
22. Klein JA. Tumescent technique for local anesthesia improves safety in large volume liposuction. *Plast Reconstr Surg* 1993;92:1085-98.
23. Page L. Specialists debate: Who should do cosmetic surgery? *Am Med News* 1987;1-18.
24. Spinowitz AL, Rumsfield J. Stability-time profile of trichloroacetic acid at various concentrations and storage conditions. *J Dermatol Surg Oncol* 1989;15:974-5.
25. Olawoye OA. Building capacity for aesthetic surgery in Nigeria: Perspectives from the cosmetic surgery fellowship at the Ivo Pitanguy Institute Rio de Janeiro, Brazil. *Nigerian J Plast Surg* 2019;15:14-9.