

an endometrial component of those focal changes favors a diagnosis of RPOC, whereas an unmistakably intramural component increases the suspicion of AVM⁽²⁾.

The second pitfall in cases such as this is the association with LIPS, an entity that can occur in the presence of RPOC (usually determined by focal accretions) or in isolation^(5,6). The prominent myometrial/periuterine vessels seen in patients with LIPS are indistinguishable from the findings in those with AVMs⁽²⁾. Therefore, because it is a rare diagnosis that is fundamentally histopathological^(5,7) and little discussed in the radiology literature, it is likely that LIPS also accounts for a portion of the cases of overdiagnosis⁽⁴⁾ and unconfirmed diagnosis of AVMs. Nevertheless, AVM is still rarer than in LIPS^(2,6).

In summary, when there is postpartum vaginal bleeding in a patient with normal b-HCG values and a finding of uterine hypervascular focal alteration, an endometrial component (RPOC) should first be excluded. When this differentiation is not clear, and especially when anomalous dilated myometrial vessels are detected in the adjacent areas, a diagnosis of LIPS accompanied by RPOC should be considered as a possible alternative to that of AVMs. The diagnosis of AVM can be confirmed by digital angiography, or the differentiation between the two diagnoses can be made through pathological study^(1,4).

Juvenile fibroadenoma

Dear Editor,

A 17-year-old black female presented with palpable nodules in both breasts. Five months prior, she had noticed abrupt growth, consequently undergoing ultrasound (Figure 1) and magnetic resonance imaging (Figure 2). Due to the growth of the lesions over a short period of time, ultrasound-guided core biopsy was requested for a better diagnostic evaluation (Figure 3).

In children and adolescents, most of the clinical conditions that result in an increase in breast size or nodules in the breast are of a benign nature. A unilateral increase in breast size is most commonly related to abnormal breast development, whereas nodules in the breast are most commonly related to fibroadenoma. Such nodules present a low risk of becoming malignant, are hormone-dependent, and can shrink after menopause⁽¹⁾.

Juvenile (or cellular) fibroadenomas, which account for 7–8% of all histological fibroadenoma subtypes, present accelerated growth and have a predilection for young black females^(2,3). At diagnosis, 10–25% of juvenile fibroadenoma patients have multiple or bilateral tumors, as in the case presented here. The biological behavior of juvenile fibroadenoma is one of a rapidly growing lesion affecting the breast, some patients showing skin ulceration and superficial venous distention^(3,4).

Ultrasound examination is the main tool used in the diagnostic investigation of breast lesions in young patients, being highly sensitive for the detection and monitoring of fibroadenomas. In the vast majority of cases, they have a typical appearance—an oval, circumscribed, hypoechoic nodule, with its longest axis parallel to the skin, with or without vascularization on a Doppler study. In older patients, such nodules can show calcium or necrotic degeneration, mimicking aggressive lesions⁽⁵⁾. On magnetic resonance imaging, fibroadenoma can exhibit a variety of behaviors. In the great majority of cases, fibroadenoma lesions show a hypointense or isointense signal in T2-weighted sequences and internal septations; after intravenous administration of paramagnetic contrast medium, the pattern of enhancement can be

REFERENCES

1. Annaiah TK, Sreenivasan SK. Uterine arteriovenous malformations: clinical implications. *The Obstetrician & Gynaecologist*. 2015;17:243–50.
2. Sellmyer MA, Desser TS, Maturen KE, et al. Physiologic, histologic, and imaging features of retained products of conception. *Radiographics*. 2013;33:781–96.
3. Goyal S, Goyal A, Mahajan S, et al. Acquired uterine arteriovenous malformation developing in retained products of conception: a diagnostic dilemma. *J Obstet Gynaecol Res*. 2014;40:271–4.
4. Müngen E. Vascular abnormalities of the uterus: have we recently overdiagnosed them? *Ultrasound Obstet Gynecol*. 2003;21:529–31.
5. Plunk M, Lee JH, Kani K, et al. Imaging of postpartum complications: a multimodality review. *AJR Am J Roentgenol*. 2013;200:W143–54.
6. Babarinsa IA, Hayman RG, Draycott TJ. Secondary post-partum haemorrhage: challenges in evidence-based causes and management. *Eur J Obstet Gynecol Reprod Biol*. 2011;159:255–60.
7. Weydert JA, Benda JA. Subinvolution of the placental site as an anatomic cause of postpartum uterine bleeding: a review. *Arch Pathol Lab Med*. 2006;130:1538–42.

Laiz Laura Godoy¹, Ulysses S. Torres¹, Giuseppe D'Ippolito²

1. Hospital São Luiz, Grupo Fleury, São Paulo, SP, Brazil. 2. Hospital São Luiz, Grupo Fleury, e Escola Paulista de Medicina da Universidade Federal de São Paulo (EPM-Unifesp), São Paulo, SP, Brazil. Mailing address: Dra. Laiz Laura Godoy. Fleury Medicina e Saúde. Rua Cincinato Braga, 282, Bela Vista. São Paulo, SP, Brazil, 01333-010. E-mail: laizgodoy@hotmail.com.

<http://dx.doi.org/10.1590/0100-3984.2016.0131>

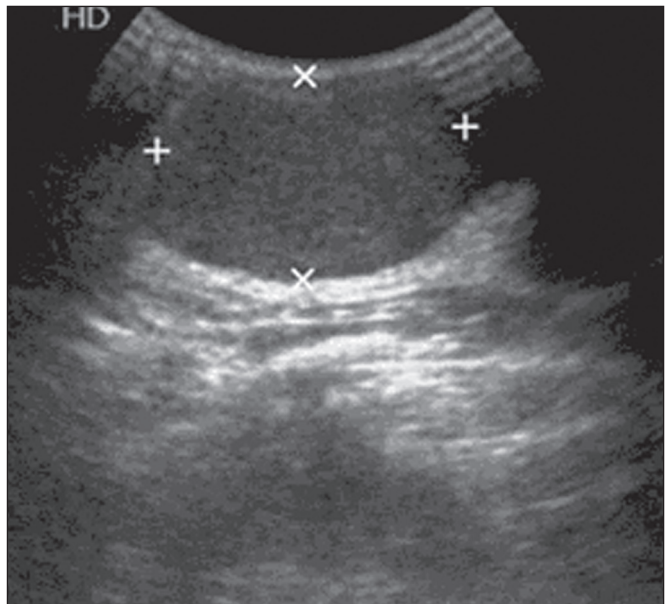


Figure 1. Ultrasound showing oval, circumscribed, hypoechoic nodules, with their longest axis parallel to the skin, suggestive of lesions that are probably benign in nature.

type I (progressive ascending curve), type II (plateau curve), or absent⁽⁶⁾.

The main differential diagnosis of fibroadenoma is a phyllodes tumor, which can be of a malignant or benign nature, making it fundamental to perform biopsy with histological analysis in order to differentiate between the two. Giant fibroadenomas and phyllodes tumor can be indistinguishable by imaging methods^(2–4).

Knowledge of the clinical history, the characteristics identified by imaging methods, and the histological correlation with morphologic changes or growth of the nodules of more than 20% over a short period of time provide the tools necessary for

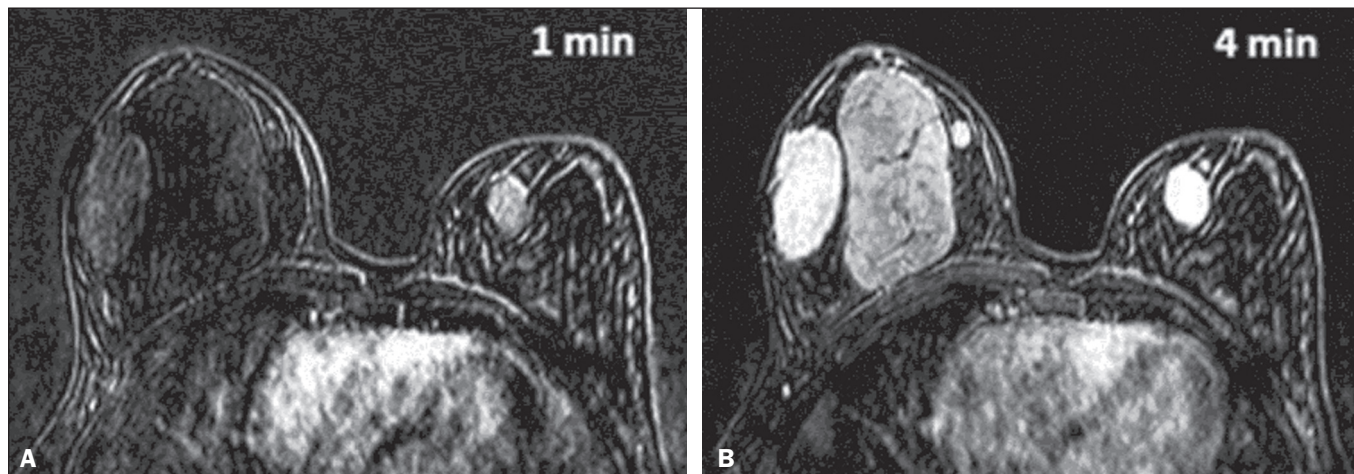


Figure 2. Magnetic resonance imaging identifying lesions with the same morphology described on ultrasound, all of the lesion showing a hypointense or isointense signal in T2-weighted sequences, as well as delayed, progressive enhancement after administration of paramagnetic contrast agent in the T1-weighted sequence, with subtraction from the first minute (A) to the fourth minute (B).

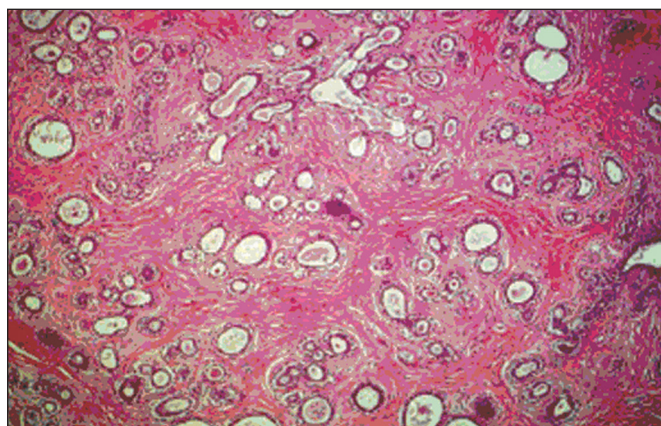


Figure 3. Electron microscopy image showing immature lobules and ducts in clefts, together with proliferation of myoepithelial and stromal cells, findings consistent with juvenile fibroadenoma.

radiologists and attending physicians to manage cases of juvenile fibroadenoma appropriately.

REFERENCES

1. Medeiros MM, Graziano L, de Souza JA, et al. Lesões hipercogênicas na mama: correlação anatomopatológica e diagnósticos diferenciais à ultrasonografia. *Radiol Bras.* 2016;49:43–8.
2. Chung EM, Cube R, Hall GJ, et al. Breast masses in children and adolescents: radiologic-pathologic correlation. *Radiographics.* 2009;29:907–31.
3. Goel NB, Knight TE, Pandey S, et al. Fibrous lesions of the breast: imaging-pathologic correlation. *Radiographics.* 2005;25:1547–59.
4. Greydanus DE, Matytsina L, Gains M. Breast disorders in children and adolescents. *Prim Care.* 2006;33:455–502.
5. Kim SJ, Park YM, Jung SJ, et al. Sonographic appearances of juvenile fibroadenoma of the breast. *J Ultrasound Med.* 2014;33:1879–84.
6. Hochman MG, Orel SG, Powell CM, et al. Fibroadenomas: MR imaging appearances with radiologic-histopathologic correlation. *Radiology.* 1997;204:123–9.

Décio Roveda Júnior¹, Gustavo Machado Badan¹, Mário Sérgio Dantas do Amaral Campos¹, Bianca Maragno¹, Laís Bastos Pessanha²

1. Santa Casa de São Paulo, São Paulo, SP, Brazil. 2. Faculdade de Medicina de Campos (FMC), Campos dos Goytacazes, RJ, Brazil. Mailing address: Dra. Laís Bastos Pessanha, Rua Primeiro de Maio, 79, Centro, Campos dos Goytacazes, RJ, Brazil, 28035-145. E-mail: laispessanha@hotmail.com.

<http://dx.doi.org/10.1590/0100-3984.2016.0162>

Bilateral pulmonary interstitial emphysema in a preterm infant on continuous positive airway pressure: clinical and radiological correlation

Dear Editor,

Here, we report the case of a newborn male, the product of a diamniotic twin pregnancy and a vaginal birth at 27 weeks and 2 days of gestational age, who had a birth weight of 920 g, with 1-, 5-, and 10-min Apgar scores of 3, 7, and 9, respectively. The mother did not receive corticosteroids, and there were no signs of infection in the amniotic fluid at the time of delivery. At birth, the neonate presented bradycardia and received mask ventilation with a positive pressure of 20 cmH₂O. After 50 s, the heart rate returned to baseline, the infant then being transferred to the neonatal intensive care unit (NICU). At NICU admission, the infant was placed on continuous positive airway pressure (CPAP) at 5 cmH₂O with a fraction of inspired oxygen of 50%. On physical examination, lung auscultation revealed normal breath sounds and few rhonchi. The neonate also showed moderate intercostal retractions and respiratory rate of 60 breaths/min. As can be seen in Figure 1A, the chest X-ray findings were consistent with respi-

ratory distress syndrome (RDS). After five hours of life, lung auscultation showed a decrease in air intake and there were moderate intercostal retractions. At eight hours of life, he evolved to apnea, respiratory difficulty, grunting, and subdiaphragmatic retractions. A new chest X-ray showed diffuse, bilateral cystic images consistent with pulmonary interstitial emphysema (PIE), as depicted in Figure 1B. Endotracheal intubation was performed, the neonate subsequently evolving to bradycardia and cyanosis of the extremities. Adrenaline and calcium gluconate were administered. Cardiopulmonary resuscitation was performed, without success, for 20 min, and the infant died at nine hours of life.

PIE consists in the passage of air to the lung interstitium, radiologically characterized by tubular, tortuous radiolucent images, 2–3 mm in width, radiating from the hila to the lung periphery, as in the present case. PIE should not be confused with the peripheral air bronchograms seen in neonatal RDS, in which the bronchial branches show smaller diameters and a more regular configuration. The evolution can be rapid, cystic images forming within a few hours. In patients with PIE, tomography of the chest can show a pattern of lines and points in the