



Video

Acute neuroretinitis as a delayed manifestation of tubulointerstitial nephritis and uveitis syndrome

Sara E. Vazquez^a, Katherine Niemeyer^{b,c}, Akshay Mentreddy^{b,c}, John Gonzales^{b,c}, Nailyn Rasool^c, Nisha R. Acharya^{b,c}, Thuy Doan^{b,c}, Jessica G. Shantha^{b,c,*}

^a School of Medicine, University of California San Francisco, San Francisco, CA, USA

^b Francis I. Proctor Foundation, University of California San Francisco, San Francisco, CA, USA

^c Department of Ophthalmology, University of California San Francisco, San Francisco, CA, USA

ARTICLE INFO

Keywords:

TINU syndrome
Uveitis
Neuroretinitis

ABSTRACT

Purpose: Tubulointerstitial nephritis syndrome with uveitis (TINU) is a rare, acquired syndrome characterized by interstitial nephritis with bilateral uveitis. We report a case of TINU with typical bilateral anterior uveitis complicated by an atypical, delayed-onset neuroretinitis in a 12-year old patient.

Observation: A 12-year-old female with a 21-month history of TINU featuring chronic bilateral anterior uveitis presented with one week of blurred vision in her left eye. On exam she was found to have new-onset disc edema in the right eye and neuroretinitis in the left eye. After a negative infectious disease workup, the patient was treated with a course of intravenous (IV) solumedrol with prednisone taper and advancement of her systemic immunosuppression. In follow up she demonstrated resolution of her disc edema and neuroretinitis with improved visual acuity and clinical exam.

Conclusion: This case stresses the importance of monitoring for additional ocular manifestations including neuroretinitis years after the onset of anterior uveitis in TINU. In comparison to the two published cases of TINU with neuroretinitis, this case shares features of uveitis progression, and thus highlights the value of further description of TINU-associated neuroretinitis.

1. Introduction

Tubulointerstitial nephritis and uveitis syndrome (TINU) is rare disorder consisting of uveitis and interstitial nephritis in the absence of other known causes. TINU predominantly affects young women with a median age of onset of 14–17 years, and accounts for roughly one third of sudden-onset bilateral anterior uveitis in the pediatric population.^{1–3} Although significant progress has been made in understanding the clinical course and treatment of TINU since it was first described in 1975,⁴ its risk factors and etiology remain poorly understood.

The main features of the syndrome as defined by Mandeville et al. in 2001 consist of bilateral anterior uveitis with onset less than 2 months prior to or less than 12 months after the onset of renal disease. However, multiple recent case series and systematic reviews support that the ocular manifestations of TINU can extend beyond anterior uveitis to involve the intermediate and posterior segments.^{2,5,6} Additional case reports have described other manifestations of posterior uveitis including retinal pigment epithelium detachments, subfoveal choroidal

neovascularization, multifocal choroiditis, and chorioretinal scarring.^{7–10}

Neuroretinitis is defined as a triad of unilateral loss of visual acuity, optic disc edema and formation of a macular star. It is thought to reflect a process originating in the optic disc vasculature and is most frequently caused by infectious or inflammatory diseases including *Bartonella henselae*, syphilis, sarcoidosis, and numerous viral etiologies.¹¹ Neuroretinitis in TINU is extremely rare, having been described in two previous case reports. Interestingly, in both cases, neuroretinitis occurred within 7 months of anterior uveitis onset and without systemic immunosuppressive therapy.^{12,13} Herein, we present a case of TINU syndrome on systemic immunosuppression that developed neuroretinitis, nearly two years after initial development of bilateral anterior uveitis and interstitial nephritis.

2. Case report

A 12-year-old female presented to uveitis clinic with one week of

* Corresponding author. Francis I. Proctor Foundation, University of California San Francisco, San Francisco, CA, USA.

E-mail address: jessica.shantha@ucsf.edu (J.G. Shantha).

<https://doi.org/10.1016/j.ajoc.2024.102050>

Received 27 June 2023; Received in revised form 29 November 2023; Accepted 21 March 2024

Available online 16 April 2024

2451-9936/© 2024 Published by Elsevier Inc. This is an open access article under the CC BY-NC-ND license (<http://creativecommons.org/licenses/by-nc-nd/4.0/>).

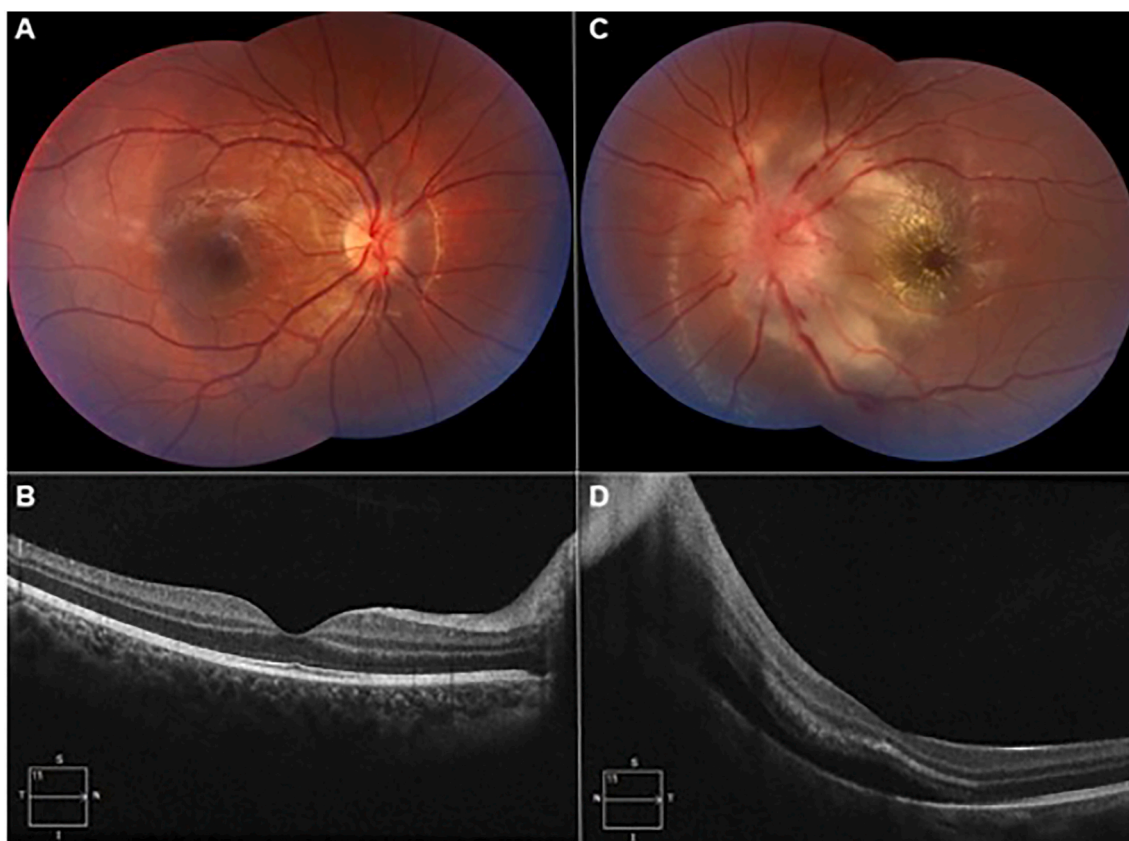


Fig. 1. Baseline presentation: A. Fundoscopic photos of the right eye showing optic nerve elevation with a high watermark nasally. B. HD-OCT demonstrating normal foveal contour with nasal edema approaching the optic nerve. C. Fundoscopic photos of the left eye showing optic nerve edema with hemorrhages and whitening extending into the macula with central macular star. D. HD-OCT demonstrating optic disc edema with subretinal fluid tracking to the subfoveal space and hyperreflective material in Henle's fiber layer.

acutely decreased visual acuity in the left eye. The patient had been diagnosed with TINU syndrome 21 months prior and was known to have chronic bilateral non-granulomatous anterior uveitis (NGAU) and recovered renal function. She had been immunosuppressed on methotrexate and adalimumab.

The patient initially presented with 5 weeks of bilateral ocular irritation and was diagnosed with bilateral NGAU. Laboratory testing was significant for an elevated beta-2-microglobulin (2869 $\mu\text{g/L}$; normal 0–300 $\mu\text{g/L}$), CRP (8.7 mg/L), ESR (20 mm/hr), low-grade proteinuria (24 mg/dl; normal <13.5mg/dl), and normal creatinine (0.72 mg/dl).⁵ Further workup did not reveal any evidence for other inflammatory or infectious etiologies, and she was diagnosed with probable TINU syndrome. She was followed by nephrology and rheumatology with return of beta-2-microglobulin levels to baseline within one year of onset without any further renal sequelae.

Over the course of a year, the patient's NGAU was treated with topical corticosteroids and mydriatics, with recurrent flares each time a steroid taper was attempted. She was started on methotrexate (25mg/week subcutaneous) but continued to have active NGAU requiring a course of oral corticosteroids with taper (40mg daily). Her course was further complicated by bilateral steroid response ocular hypertension treated topically with dorzolamide-timolol (one drop twice a day) and brimonidine (one drop twice a day).

Six months after starting methotrexate, during the tapering of oral corticosteroids, she presented to clinic with 1 week of acutely worsening vision in her right eye. On exam, she was found to have active anterior uveitis with 3+ anterior chamber (AC) cells and flare with posterior synechiae in the right eye (OD) and 2+ AC cells in the left eye (OS). Newly noted was 1+ anterior vitreous cells bilaterally. Optical coherence tomography (OCT) showed a slight increase in macular thickness,

and oral fluorescein angiography showed bilateral peripheral temporal vascular leakage. Oral corticosteroid dose was increased (from 10mg to 40mg) and the patient was started on adalimumab (40mg injection every 14 days).

Three months later, shortly after finishing the oral steroid taper from her previous flare, the patient was again found to have active bilateral anterior uveitis with 4+ AC and 1+ vitreous cells, now with bilateral posterior synechiae, with a corrected visual acuity (BCVA) of 20/20 OD and 20/25 OS. Due to concurrent weight gain and psychosocial stressors, she was treated with topical difluprednate 4 times a day and atropine 1% before bed, with topical ocular hypotensives in both eyes avoiding oral corticosteroids. Additionally, the patient was found to have undetectable levels of adalimumab (<0.8mcg/ml) accompanied by anti-drug antibodies (>100AU), and a plan was made to transition the patient to infliximab infusions.

Three weeks later (21 months after initial diagnosis), the patient presented with one week of dramatically decreased vision in her left eye. On examination, her BCVA was 20/20 OD and 20/400 OS. There were 3+ AC cells with 1+ flare and 1+ anterior vitreous cells in both eyes. Posterior synechiae were seen bilaterally. Fundoscopic exam of the right eye showed one small cotton wool spot outside the arcade and elevated optic disc. Fundoscopic exam of the left eye showed 360° disc edema with surrounding heme and cotton wool spots, retinal whitening extending from the optic nerve into the macula, a prominent macular star, tortuous vessels, and normal periphery (Fig. 1). On imaging, OCT of the left macula showed optic nerve thickening with subretinal fluid adjacent to the nerve and tracking into the macula (Fig. 1). Further history and review of systems revealed she had recently acquired a stray kitten, had been around farm animals, drank unpasteurized goat milk, and recently traveled to Mexico to visit her family. Given the concern for

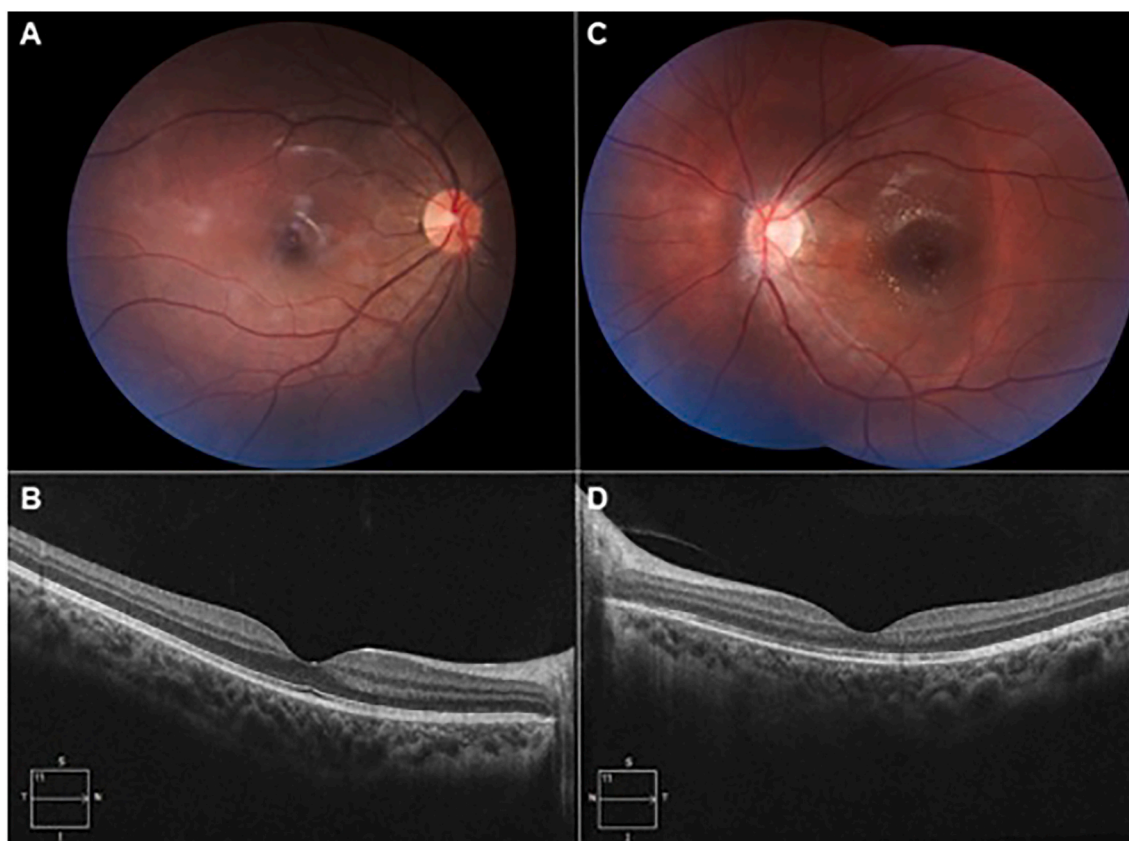


Fig. 2. Follow up at 16 weeks: A. Fundoscopic photo of the right eye showing resolution of optic nerve elevation. B. HD-OCT of the right eye demonstrating normal foveal contour and resolution of nasal edema. C. Fundoscopic photos of the left eye showing resolution of optic disc edema and improvement in macular star. D. HD-OCT of the left eye demonstrating normal foveal contour with resolution of subretinal fluid and decrease in hyperreflective deposits in Henle's fiber layer.

possible infectious etiology, immunomodulatory therapy (current regimen was methotrexate (25mg/week subcutaneous) and adalimumab (40mg injection every 14 days) was stopped, and doxycycline and rifampin were initiated for empiric treatment of *Bartonella henselae*.

The patient was admitted to the hospital for expedited work-up and treatment. MRI of the brain and orbits with and without contrast in the emergency department showed no acute intracranial pathology, with normal appearance of the orbits and optic nerves. Lumbar puncture was unable to be obtained. Labs showed elevation of CRP (3.4 mg/L); all other admission labs and vital signs were within normal limits. IV sol-medrol (3 days \times 1 g) was started after 24 hours of antibiotic therapy. After 5 days of admission, the patient was discharged on oral doxycycline, oral rifampin, and prednisone (60mg/day), with mildly improved macular edema and stable macular star in the left eye. Laboratory testing for *Bartonella* species, *Brucella*, *Toxocara*, *Treponema pallidum*, *Toxoplasma*, tuberculosis, EBV, CMV, HSV and *Coccidioides* were negative. Oral prednisone was tapered, and the patient was transitioned to IV infliximab (10mg/kg every 4 weeks).

Over the course of 16 weeks, the patient's visual acuity was maintained in the right eye at 20/20 and gradually improved in the left eye to 20/20 with resolution of retinal edema (Fig. 2). The macular and disc edema had resolved. Her anterior uveitis was quiet with no anterior chamber cells and 1+ anterior vitreous cells bilaterally. Repeat serologies for *Bartonella* remained negative. The patient remained stable on a regimen of infliximab (10mg/kg every 4 weeks), methotrexate (7.5mg weekly), and prednisone (10mg daily).

3. Discussion

TINU is a rare disease and its risk factors and etiology remain poorly understood.² The diagnosis of TINU has remained primarily clinical and

is defined by the presence of idiopathic interstitial nephritis and anterior uveitis.¹ While our patient did not undergo a renal biopsy, they did meet criteria for probable TINU by elevated beta-2-microglobulin, proteinuria, and typical bilateral anterior uveitis.^{1,5} Given the risks of renal biopsy may outweigh the benefits particularly when renal disease is mild, nephrology felt that renal biopsy for histopathologic confirmation was not warranted in this case.

While renal disease tends to resolve spontaneously or with corticosteroid treatment, TINU-associated uveitis can be more difficult to manage and frequently recurs.¹⁴ One recent retrospective cohort study found that corticosteroid treatment for nephritis could be discontinued after a median of 8 months, compared to a median of 18 months for uveitis.¹⁵ In the same study, most patients (~74%) were managed for uveitis with topical corticosteroids and mydriatics alone. Of those 12 patients requiring further treatment, only 2 required treatment with adalimumab after failing adequate control with methotrexate or mycophenolate mofetil.¹⁵ Similarly, a recent systemic review showed that only 15% (90/592) of patients with TINU required immunosuppressive agents for uveitis treatment, with only 23% of those (21/90) requiring multiple immunosuppressive drugs.² Thus, the case presented here is unusual in regard to the requirement for multiple treatment escalations, including topical, oral and IV corticosteroids, methotrexate, adalimumab, and infliximab.

Most cases of TINU are characterized by bilateral anterior uveitis. However, an increasing number of intermediate and posterior uveitis manifestations have been reported in recent years. Among the rarest TINU-associated ocular manifestations is neuroretinitis, with only two previous case reports.^{12,13} In all three cases, initial presentation was that of typical bilateral anterior uveitis with gradual (in two cases) and abrupt (in one case) progression to the intermediate and posterior segments of the eye. An unusual aspect of this case is the occurrence of

neuroretinitis nearly two years after the initial onset of uveitis and at least one year after renal function had returned to normal. Additionally, our patient developed neuroretinitis while on systemic immunosuppression therapy while the other reported cases were not receiving systemic treatment. These findings highlight the importance of continued monitoring for new uveitis occurrences, including neuroretinitis, even years after initial diagnosis of TINU.

Over 50% of neuroretinitis can be attributed to infection with *Bartonella henselae*, also known as cat scratch disease.¹⁶ Despite our patient's recent exposure to a stray kitten, extensive serologic and nucleic acid testing workup revealed no evidence of infection with *Bartonella*. Other possible causes of neuroretinitis, taking into consideration her exposures as well as her immunosuppressed status, include syphilis, brucellosis, toxoplasmosis, coccidioides, HSV, VZV, and tuberculosis^{11,16}; testing for these pathogens were negative. Other inflammatory etiologies for neuroretinitis include sarcoidosis, Vogt-Kayanagi-Harada syndrome, Behcet's syndrome, and polyarteritis nodosa.¹¹ Our patient had no clinical or laboratory evidence for any of these processes. In addition, the patient's findings occurred concurrently with a steroid taper and flare of her pre-existing anterior and intermediate uveitis. This temporal proximity to the onset of neuroretinitis further supports TINU as the most likely underlying etiology.

Despite common relapses and a relatively long duration of disease, outcomes of TINU-associated uveitis tend to resolve with minimal long term visual deficits.³ Similarly, the clinical course of neuroretinitis tends to be favorable, most commonly with resolution of macular star and visual impairment by 3 months.¹¹ Based on the previous two case reports as well as the case presented here, treatment of TINU-associated neuroretinitis with corticosteroids (and infliximab) appears to lead to full return to baseline visual function.^{12,13}

4. Conclusion

It is important for uveitis specialists to be aware that neuroretinitis can develop years after initial TINU diagnosis. Particularly for patients on immunosuppression, infectious causes should be excluded. If patients with TINU have ongoing ocular inflammation that is not controlled, it is important to advance immunosuppression. In this case, TINU-associated neuroretinitis was treated successfully with high dose corticosteroids and advancement of systemic immunosuppression with infliximab.

Patient consent

Patient consent was obtained.

Funding

This research was supported, in part, by the UCSF Vision Core shared resource of the NIH/NEI P30 EY002162, and by an unrestricted grant from Research to Prevent Blindness, New York, NY. This work is supported by grant funding from the That Man May See (Rasool).

CRediT authorship contribution statement

Sara E. Vazquez: Conceptualization, Methodology, Writing – original draft, Writing – review & editing. **Katherine Niemeyer:** Conceptualization, Writing – original draft. **Akshay Mentreddy:** Conceptualization, Writing – original draft. **John Gonzales:** Conceptualization, Project administration, Writing – review & editing. **Nailyn**

Rasool: Conceptualization, Writing – original draft, Writing – review & editing. **Nisha R. Acharya:** Conceptualization, Writing – review & editing. **Thuy Doan:** Conceptualization, Project administration, Supervision, Writing – review & editing. **Jessica G. Shantha:** Conceptualization, Supervision, Writing – original draft, Writing – review & editing.

Declaration of competing interest

The authors declare that they have no known competing financial interests or personal relationships that could have appeared to influence the work reported in this paper.

Acknowledgements and disclosures

The authors report no conflicts of interest.
All authors meet criteria for authorship.

References

- Mandeville JTH, Levinson RD, Holland GN. The tubulointerstitial nephritis and uveitis syndrome. *Surv Ophthalmol*. 2001;46:195–208. [https://doi.org/10.1016/S0039-6257\(01\)00261-2](https://doi.org/10.1016/S0039-6257(01)00261-2).
- Regusci A, Lava SAG, Milani GP, Bianchetti MG, Simonetti GD, Vanoni F. Tubulointerstitial nephritis and uveitis syndrome: a systematic review. *Nephrol Dial Transplant*. 2021;37:876–886. <https://doi.org/10.1093/ndt/gfab030>.
- Amaro D, Carreño E, Steeples LR, Oliveira-Ramos F, Marques-Neves C, Leal I. Tubulointerstitial nephritis and uveitis (TINU) syndrome: a review. *Brit J Ophthalmol*. 2020;104:742–747. <https://doi.org/10.1136/bjophthalmol-2019-314926>.
- Dobrin RS, Vernier RL, Fish AJ. Acute eosinophilic interstitial nephritis and renal failure with bone marrow-lymph node granulomas and anterior uveitis A new syndrome. *Am J Medicine*. 1975;59:325–333. [https://doi.org/10.1016/0002-9343\(75\)90390-3](https://doi.org/10.1016/0002-9343(75)90390-3).
- Hettinga YM, Scheerlinck LME, Lilien MR, Rothova A, Boer JH de. The value of measuring urinary β 2-microglobulin and serum creatinine for detecting tubulointerstitial nephritis and uveitis syndrome in young patients with uveitis. *Jama Ophthalmol*. 2015;133:140–145. <https://doi.org/10.1001/jamaophthalmol.2014.4301>.
- Paroli MP, Cappiello D, Staccini D, Caccavale R, Paroli M. Tubulointerstitial nephritis and uveitis syndrome (TINU): a case series in a tertiary care uveitis setting. *J Clin Medicine*. 2022;11:4995. <https://doi.org/10.3390/jcm11174995>.
- Sheth HG, Laverde-Konig T, Raina J. TINU-associated retinal pigment epithelium detachments: a possible novel posterior segment feature. *Int Ophthalmol*. 2009;29:179–181. <https://doi.org/10.1007/s10792-007-9185-z>.
- Takemoto Y, Namba K, Mizuuchi K, Ohno S, Ishida S. Two cases of subfoveal choroidal neovascularization with tubulointerstitial nephritis and uveitis syndrome. *Eur J Ophthalmol*. 2012;23:255–257. <https://doi.org/10.5301/ejo.5000240>.
- Derzko-Dzulynsky L, Rabinovitch T. Tubulointerstitial nephritis and uveitis with bilateral multifocal choroiditis. *Am J Ophthalmol*. 2000;129:807–809. [https://doi.org/10.1016/S0002-9394\(00\)00484-0](https://doi.org/10.1016/S0002-9394(00)00484-0).
- Ali A, Rosenbaum JT. TINU (tubulointerstitial nephritis uveitis) can be associated with chorioretinal scars. *Ocul Immunol Inflamm*. 2014;22:213–217. <https://doi.org/10.3109/09273948.2013.841624>.
- Abdelhakim A, Rasool N. Neuroretinitis. *Curr Opin Ophthalmol*. 2018;29:514–519. <https://doi.org/10.1097/ICU.0000000000000527>.
- Khochtali S, Harzallah O, Hadhri R, Hamdi C, Zaouali S, Khairallah M. Neuroretinitis: a rare feature of tubulointerstitial nephritis and uveitis syndrome. *Int Ophthalmol*. 2014;34:629–633. <https://doi.org/10.1007/s10792-013-9820-9>.
- Leclaire-Collet A, Villeroy F, Vasseneix C, Landthaler G, Bresseur G. Tubulointerstitial nephritis and uveitis syndrome (TINU syndrome) with unilateral neuroretinitis: a case report. *Eur J Ophthalmol*. 2004;14:334–337. <https://doi.org/10.1177/112067210401400410>.
- Sobolewska B, Bayyoud T, Deuter C, Doycheva D, Zierhut M. Long-term follow-up of patients with tubulointerstitial nephritis and uveitis (TINU) syndrome. *Ocul Immunol Inflamm*. 2018;26:601–607. <https://doi.org/10.1080/09273948.2016.1247872>.
- Chevalier A, Duflos C, Clave S, et al. Renal prognosis in children with tubulointerstitial nephritis and uveitis syndrome. *Kidney Int Reports*. 2021;6:3045–3053. <https://doi.org/10.1016/j.ekir.2021.09.017>.
- Purvin V, Sundaram S, Kawasaki A. Neuroretinitis: review of the literature and new observations. *J Neuro Ophthalmol*. 2011;31:58–68. <https://doi.org/10.1097/WNO.0b013e31820cf78a>.