


# Ingestion of bedding material as a cause of acute copper sulfate poisoning in turkey poults

Marta Giergiel,\* Maciej M. Durkalec ,\*<sup>1</sup> Agnieszka Nawrocka,\* Bartosz Sell,\* Iwona Stolarska,<sup>†</sup> and Andrzej Posyniak\*

\**Department of Pharmacology and Toxicology, National Veterinary Research Institute, Aleja Partyzantow 57, 24-100 Pulawy, Poland; and* <sup>†</sup>*Medicalvet Iwona Stolarska – Private Veterinary Practice, Karola Marcinkowskiego 2E, 59-220 Legnica, Poland*

**ABSTRACT** The article reports a case of acute copper sulfate (CuSO<sub>4</sub>) poisoning in 2-day-old turkeys. The first incidences were noticed 2 h after placing the animals in the poultry house, where turkeys were provided with wood shaving bedding. Post-mortem examination showed wood shavings present in gastric and intestinal contents and numerous lesions in the alimentary tract: dark green color of the koilin lining, and surface erosions, deep ulceration, and severe congestion of the gizzard. The copper (Cu) concentration in samples of

the liver, kidney, heart, gizzard content, gizzard muscle, gizzard lining, and wood shavings from the bedding was determined. Our results showed that the level of Cu in the livers of affected birds was more than sevenfold higher than the recommended value and the Cu content in bedding material was above the value considered to be toxic to turkeys. Our investigation identified the bedding disinfected using a CuSO<sub>4</sub> solution as a possible cause of turkey fatalities.

**Key words:** acute poisoning, bedding material, copper sulfate, disinfection, turkey

2019 Poultry Science 98:707–711  
<http://dx.doi.org/10.3382/ps/pey430>

## INTRODUCTION

Copper (Cu) is an essential trace element that plays an important role as a cofactor in numerous enzymatic reactions that are involved in energy metabolism, the antioxidant defense system, pigmentation, and maturity and stability of collagen and elastin (National Research Council, 2005). Humans, rodents, pigs, and poultry are generally tolerant of high Cu intake. An appropriate level of Cu in an avian diet is crucial for normal growth and development. It is well known that Cu supplementation may increase feed intake and weight gain, and its compounds including copper sulfate (CuSO<sub>4</sub>) are used as feed supplements in poultry (Fisher et al., 1973; Harms and Buresh, 1987). Poultry diets often exceed the mandated Cu content for classical nutrition of 8 to 20 mg/kg, due to the growth-promoting effect and the reduction of chole-

sterol in chicken meat imparted by higher dietary levels such as 125 to 250 mg/kg (Pesti and Bakalli, 1996).

Cu compounds are widely used as pesticides and sanitizing agents due to their strong antimicrobial properties (Russell, 2008; Koseoglu et al., 2015; Vincent et al., 2016). CuSO<sub>4</sub> solution is used in ruminants as a foot bath to control foot and other lameness-related problems and in poultry for the disinfection of bedding material. Ingestion of Cu from baths or consumption of contaminated plants from the pasture where the CuSO<sub>4</sub> solution has been disposed of may be a reason for Cu poisoning in animals (National Research Council, 2005). The excess of Cu ions may bind to proteins and nucleic acids and induce oxidative stress that may lead to tissue damage (Gaetke and Chow, 2003; National Research Council, 2005). The main target organs for Cu are the liver and kidneys, but the effects of toxicosis may occur in the gastrointestinal tract (Jensen and Maurice, 1978; Wideman et al., 1996; Leeson and Summers, 2009). In the literature there are numerous examples of Cu toxicosis in animals (Chiou et al., 1999; Bozynski et al., 2009; Minervino et al., 2009; Fieten et al., 2012) but few examples of toxic effects of Cu in turkeys have been reported (Christmas and Harms, 1979; Harms and Buresh, 1987).

In the presented paper we report a case of Cu poisoning in 2-day-old turkeys after exposure to CuSO<sub>4</sub> used for disinfection of the bedding material in turkey sheds.

© The Author(s) 2018. Published by Oxford University Press on behalf of Poultry Science Association. This is an Open Access article distributed under the terms of the Creative Commons Attribution Non-Commercial License (<http://creativecommons.org/licenses/by-nc/4.0/>), which permits non-commercial re-use, distribution, and reproduction in any medium, provided the original work is properly cited. For commercial re-use, please contact [journals.permissions@oup.com](mailto:journals.permissions@oup.com).

Received February 26, 2018.

Accepted August 28, 2018.

<sup>1</sup>Corresponding author: [maciej.durkalec@piwet.pulawy.pl](mailto:maciej.durkalec@piwet.pulawy.pl)

## MATERIAL AND METHODS

### Case Background

In April 2016, increased mortality was observed in 2 flocks of 2-day-old turkeys of Hybrid Converter strain, which had been newly placed in 2 separate turkey sheds on a commercial turkey farm in northeast Poland. Females and males (8,772 and 5,614 respectively) were kept separately in the first turkey shed (A), whereas only males (16,116 individuals) were housed in the second one (B). Pine wood shavings previously sanitized by spraying with a  $\text{CuSO}_4$  solution were used as bedding in both turkey sheds. Two hours after allocating birds, increased mortality was observed in turkey shed A. After 24 h 299 birds had died in both turkey sheds (267 males and 3 females in shed A and 29 males in shed B). Another 300 incidences were recorded by hour 48 after allocation of the animals on the farm. The mortality after 1 wk was: 775 males and 63 females in shed A and 814 males in shed B. According to the owner's observation, birds were laying on their sides or bellies with their necks extended and were gasping for air. Those signs were not observed 48 h later, however, birds were losing balance and lying on their backs (flip-over) before their deaths.

### Sampling on the Farm

Dead birds ( $n = 6$ ) were collected and submitted to the Diagnostic Unit of the Department of Pharmacology and Toxicology of the National Veterinary Research Institute in Pulawy, Poland for necropsy examination and other diagnostic procedures. Subsequently, 4 samples of the bedding material were collected for analysis from each turkey shed. No ethical committee permission was required as the samples were collected post-mortem.

### Necropsy and Tissue Sampling

A clinical examination and initial necropsy of dead birds was performed on the farm by a veterinarian and based on their results disease agents were excluded as a potential cause of turkey falls. The second post-mortem examination of 6 individuals was carried out in the laboratory of the National Veterinary Research Institute in Pulawy, Poland. Several tissues (liver, kidney, heart, gizzard muscle, and the lining of the gizzard) and gizzard contents were collected from 3 birds during the second necropsy. Based on necropsy findings and the dark green color of the gizzard contents and several parts of the alimentary tracts we decided to investigate for excessive Cu and toxic compounds that can cause similar signs.

### Toxicological Analysis

Because intoxication was suspected based on the necropsy examinations, the presence of 61

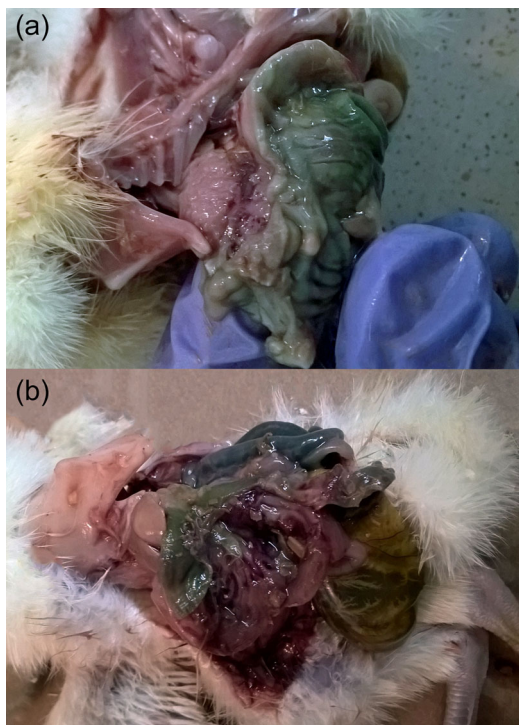toxic compounds including rodenticides, carbamates, organophosphorus pesticides, coccidiostats, and mycotoxins was tested in liver samples of dead birds using the LC-MS/MS method as previously described by Sell et al. (2017). The concentration of Cu was analyzed with atomic absorption spectroscopy with flame atomization (F-AAS). Prior to the analysis, samples of liver, kidney, heart, gizzard content, gizzard muscle, and gizzard lining as well as samples of bedding material were wet-digested using the Speedwave 4 microwave digestion system equipped with DAK-100 high-pressure vessels (Berghof, Einingen, Germany). Samples were weighed into previously acid-cleaned digestion vessels and digested by a mixture of 5 mL of concentrated nitric acid  $\text{HNO}_3$  (Suprapur, Merck, Darmstadt, Germany) and 2 mL of 30% hydrogen peroxide solution  $\text{H}_2\text{O}_2$  (POCH, Gliwice, Poland). All samples were digested in triplicate and 1 reagent blank was prepared for each digestion batch (8 vessels) to monitor the Cu background level.

Levels of Cu were analyzed using an Avanta PM spectrometer (GBC Scientific Equipment, Braeside, Victoria, Australia) after an external calibration. An in-house validation study was performed to establish method parameters such as working range, linearity, sensitivity, limit of detection (LOD), limit of quantification (LOQ), precision (repeatability and within-laboratory reproducibility), and recovery, and the uncertainty budget was estimated (see Supplementary Table S1). Quality control of the analytical measurements was confirmed by analyzing Cu in the following certified reference materials (CRMs): SRM-1577c bovine liver (NIST, Gaithersburg, USA), INCT.-SBF-4 Soya Bean Flour, INCT.-CF-3 Corn Flour (ICHTJ, Warsaw, Poland), and DORM-3 Fish Protein (NRC-CNRC, Ottawa, Canada). The obtained recoveries were: 100, 97, 98, and 102% respectively (see Supplementary Table S2).

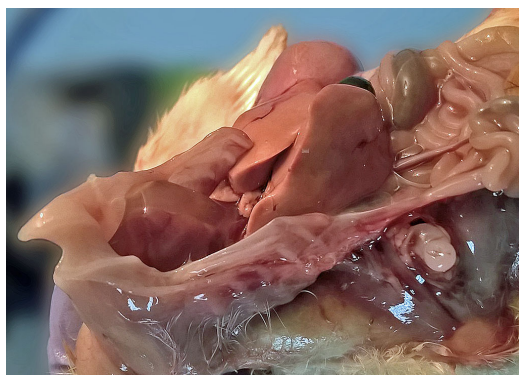## RESULTS

### Gross Pathology

The most characteristic lesions could be observed in the alimentary tracts of dead birds: gizzards were filled with mucus with numerous fragments of wood shavings from ingested bedding; proventriculi and proximal parts of the small intestine were green; the koilin linings of the gizzards were dark green and could be easily separated from the mucous membrane; and surface erosions, deep ulceration and severe congestion of the mucous membrane of the gizzard were observed (Figure 1(a), Figure 1(b)). No visible lesions were found in other parts of the alimentary tracts (cecum, colon, and rectum). Congestion of lungs and kidneys, pale and friable livers (Figure 2), and pleural, pericardial, peritoneal, and abdominal effusions were found. The gross pathology findings were similar in all examined birds.



**Figure 1.** Dark green lining of the gizzard (a) and deep erosions of the gizzard mucous membrane (b) of 2-day-old intoxicated turkey poul after the ingestion of wood shavings contaminated with copper sulfate.



**Figure 2.** Pale and friable liver of 2-day-old intoxicated turkey poul after the ingestion of wood shavings contaminated with copper sulfate.

### Toxicological Analysis

The results of liver sample analysis by LC-MS/MS did not confirm the occurrence of any common organic compound that may be toxic to turkeys, and analysis of Cu presence was necessary to check if Cu compounds were the cause of poisoning.

The results of Cu analysis in tissues and gastric contents of dead turkeys are presented in Table 1. Levels of Cu in samples of the bedding material from both turkey sheds are presented in Table 2. The levels of Cu in the gastric contents of birds were similar to the Cu

**Table 1.** Concentrations of Cu in tissues and gizzard content of poisoned birds.

Sample	Concentration of Cu (in mg/kg of wet weight)		
	Bird 1	Bird 2	Bird 3
Liver	70.6	100.1	70.18
Kidney	44.48	41.58	47.32
Heart	12.84	18.42	23.35
Gizzard muscle	602.73	209.49	477.69
Koilin lining	1695.7	1609.68	1059.31
Gizzard content	1449.53	2314.45	1583.34

concentration in bedding material. The content of Cu in the bedding material taken from turkey shed A was twofold higher than that from turkey shed B where bird mortality was lower.

### DISCUSSION

Cleaning and disinfection are key components of biosecurity in poultry farming (Meroz and Samberg, 1995). Different disinfectants, e.g., alcohols, oxidizing compounds, hypochlorite, phenols, aldehydes, quaternary ammonium compounds, and inorganic compounds are routinely used for decontamination to prevent infections in birds (Denyer and Stewart, 1998; McLaren et al., 2011). Fungistatic agents like  $\text{CuSO}_4$  solutions used on bedding material serve to reduce the concentration of fungi, especially *Aspergillus sp.* (Dyar et al., 1984; Arné et al., 2011). The recommended concentration of  $\text{CuSO}_4$  used for sanitization by spraying on the bedding or by fogging is 1 to 1.5%. Improper spraying or fogging may result in an uneven accumulation of the active compound on the surface of bedding and thus may cause intense coloration of some parts of the bedding material. Avian color perception plays an important role in foraging (Osorio et al., 1999). It was reported that the color of the feeder can affect feed intake in broiler chickens. Adult broilers preferred red, whereas green feeders were preferred by chicks up to the 5th day of life (Deines et al., 2016). In the case presently reported, the color of wood shavings collected from different parts of turkey sheds A and B was dark green, and that could attract birds for foraging. The consumption of litter is common in poultry, especially in early stage of life. It has been experimentally demonstrated that newly hatched chicks cannot recognize food and peck indiscriminately at bedding material and food (Hogan, 1973). Malone et al. (1983) reported that broiler chickens in the 1st week of life may consume up to 6.35% of diet as litter. The litter consumption rate could be influenced by different factors such as the distance of feed and water from the heating source for birds (Crawford et al., 1980). More recent evidence shows that turkey poults are more prone to litter consumption than broiler chickens and turkey brooded on pine shavings may consume litter regularly (Grimes et al., 2002, 2007). The maximum level of Cu in wood shavings was found in turkey shed A and was

**Table 2.** Concentrations of Cu in the bedding material from turkey sheds.

Sample	Concentration of Cu (in mg/kg of dry weight)			
	Sample 1	Sample 2	Sample 3	Sample 4
Litter from turkey shed A	2151.97	886.16	1710.61	867.65
Litter from turkey shed B	4540.39	2478.84	2353.85	3649.86

4540.4 mg/kg. The concentration of Cu in the gastric contents of the birds ranged from 1449.5 to 2314 mg/kg of wet wt. Excessive levels of dietary Cu may adversely affect the health of birds causing several disorders in the organism. It was found that high amounts of CuSO<sub>4</sub> may reduce feed consumption and cause gizzard erosion in turkey poults (Christmas and Harms, 1979). Similar effects have been reported in broiler chickens by Chiou et al. (1999). The authors found that dietary Cu above 250 mg/kg may adversely affect the productive efficiency of broiler chickens, including feed conversion rate, and may cause severe oral lesions and gastrointestinal erosions. According to Porter (2018), the symptoms such as catarrhal gastroenteritis, burns or erosions in the lining of the gizzard, and greenish, seromucous exudate throughout the intestinal tract could be found during necropsy of birds poisoned with CuSO<sub>4</sub>. In our case, surface erosions and ulceration of the mucous membrane of the gizzards as well as liver congestion were observed in all examined birds. Our findings concur well with the results of an experiment on White Leghorn males fed with acute doses of 2 Cu compounds (Shivanandappa et al., 1983). The authors described the impairment of spermatogenesis concomitant with testicular atrophy, congestion of the liver and kidneys and high mortality that occurred within 24 to 28 h in birds fed with CuSO<sub>4</sub>. The median lethal dose (LD<sub>50</sub>) reported by authors was 643 mg/kg of body weight (BW). In our case, high mortality was observed within 48 h of the animals being placed in turkey sheds and the concentration of Cu in the gizzard contents ranged between 1449.5 and 2314.5 mg/kg. It has been proved that dietary Cu levels above 300 mg/kg may result in accumulation of Cu in the liver and a single oral dose above 1,000 mg is considered to be lethal to turkeys (Puls, 1988; Porter, 2018). In our case higher mortality was observed in males than in females. We hypothesize that the uneven accumulation of CuSO<sub>4</sub> in the bedding material from different parts of turkey shed could be a reason of difference in mortality. Another possible explanation could be the difference in foraging behavior between males and females (Murphy et al., 2014; Fernandes et al., 2015). In this paper, we have described cases of acute Cu toxicosis in turkeys after the ingestion of bedding contaminated with CuSO<sub>4</sub>. Our results revealed that the improper use of this compound as a disinfecting agent may cause its uneven accumulation on the surface of the bedding material and intensive coloration of that material, which may attract young birds to forage. The resulting ingestion of contaminated bedding material may cause

Cu poisoning. Although CuSO<sub>4</sub> solutions are widely used as disinfectants in poultry farms, caution must be taken during spraying or fumigation in order to prevent the accidental intoxication of birds.

## SUPPLEMENTARY DATA

Supplementary data are available at *Poultry Science* online.

**Supplementary Table S1.** Validation parameters of the method of Cu determination in biological samples.

**Supplementary Table S2.** The recoveries of Cu in selected certified reference materials (CRMs).

## ACKNOWLEDGMENTS

We would like to thank our colleagues Tomasz Sniegocki and Wojciech Kozdrun from the National Veterinary Research Institute in Pulawy, Poland for their valuable suggestions. The financial support was given by the KNOW (Leading National Research Centre) Scientific Consortium "Healthy Animal—Safe Food", Ministry of Science and Higher Education Resolution No. 05-1/KNOW2/2015.

## REFERENCES

- Arné, P., S. Thierry, D. Wang, M. Deville, G. Le Loc'h, A. Desoutter, F. Féménia, A. Nieguitsila, W. Huang, R. Chermette, and J. Guillot. 2011. *Aspergillus fumigatus* in poultry. *Int. J. Microbiol.* 2011:1–14.
- Bozynski, C. C., T. J. Evans, Y. K. Dae, G. C. Johnson, J. M. Hughes-Hanks, W. J. Mitchell, G. E. Rottinghaus, J. Perry, and J. R. Middleton. 2009. Copper toxicosis with hemolysis and hemoglobinuric nephrosis in three adult boer goats. *J. Vet. Diagn. Invest.* 21:395–400.
- Chiou, P. W. S., C. L. Chen, K. L. Chen, and C. P. Wu. 1999. Effect of high dietary copper on the morphology of gastro-intestinal tract in broiler chickens. *Asian Australas. J. Anim. Sci.* 12:548–553.
- Christmas, R. B., and R. H. Harms. 1979. The effect of supplemental copper and methionine on the performance of turkey poults. *Poult. Sci.* 58:382–384.
- Crawford, R. D., J. B. O'Neil, and T. A. Scott. 1980. Canadian research includes chick survival, rapeseed. *Feedstuffs.* 23: 16.
- Deines, J., E. Lhamon, D. Yoho, L. Chick, and R. Bramwell. 2016. Feeder color preference of broilers and its effects on performance. *Poult. Sci.* 95 (E-Suppl. 1):220. (Abstr.)
- Denyer, S. P., and G. S. A. B. Stewart. 1998. Mechanisms of action of disinfectants. *Int. Biodeterioration & Biodegradation* 41:261–268.
- Dyar, P. M., O. J. Fletcher, and R. K. Page. 1984. *Aspergillosis* in turkeys associated with use of contaminated litter. *Avian Dis.* 28:250–255.
- Fernandes, D. P. B., I. J. O. Silva, A. C. Nazareno, A. C. Donofre, and K. B. Sevegnani. 2015. Reconhecimento de cores de objetos e

- de alimentos de cromaticidades opostas por pintos de corte. *Arq. Bras. Med. Vet. Zootec.* 67:873–881.
- Fieten, H., P. A. J. Leegwater, A. L. Watson, and J. Rothuizen. 2012. Canine models of copper toxicosis for understanding mammalian copper metabolism. *Mamm. Genome* 23:62–75.
- Fisher, G., A. P. Laursen-Jones, K. J. Hill, and W. S. Hardy. 1973. The effect of copper sulphate on performance and the structure of the gizzard in broilers. *Br. Poult. Sci.* 14:55–68.
- Gaetke, L. M., and C. K. Chow. 2003. Copper toxicity, oxidative stress, and antioxidant nutrients. *Toxicology* 189:147–163.
- Grimes, J. L., T. A. Carter, A. E. Gernat, and J. L. Godwin. 2007. A novel bedding material made from cotton waste, gypsum, and old newsprint for rearing turkeys. *J. Appl. Poult. Res.* 16:598–604.
- Grimes, J. L., J. Smith, and C. M. Williams. 2002. Some alternative litter materials used for growing broilers and turkeys. *Worlds Poult. Sci. J.* 58:515–526.
- Harms, R. H., and R. E. Buresh. 1987. Influence of three levels of copper on the performance of turkey poults with diets containing two sources of methionine. *Poult. Sci.* 66:721–724.
- Hogan, J. A. 1973. Development of food recognition in young chicks: I. Maturation and nutrition. *J. Comp. Physiol. Psychol.* 83:355–366.
- Jensen, L. S., and D. V. Maurice. 1978. Effect of methionine on Copper-Induced growth depression and gizzard erosion. *Poult. Sci.* 57:1530–1532.
- Koseoglu Eser, O., A. Ergin, and G. Hascelik. 2015. Antimicrobial activity of copper alloys against invasive multidrug-resistant nosocomial pathogens. *Curr Microbiol* 71:291–295.
- Leeson, S., and J. D. Summers. 2009. *Commercial Poultry Nutrition*. 3rd ed. MISC PUBS, Guelph, Ontario.
- Malone, G. W., G. W. Chaloupka, and W. W. Saylor. 1983. Influence of litter type and size on broiler performance.: 1. Factors affecting litter consumption. *Poult. Sci.* 62:1741–1746.
- McLaren, I., A. Wales, M. Breslin, and R. Davies. 2011. Evaluation of commonly-used farm disinfectants in wet and dry models of Salmonella farm contamination. *Avian Pathol.* 40:33–42.
- Meroz, M., and Y. Samberg. 1995. Disinfecting poultry production premises. *Rev. Sci. Tech.* 14:273–291.
- Minervino, A. H. H., R. A. Barrêto Júnior, R. N. F. Ferreira, F. A. M. L. Rodrigues, S. A. Headley, C. S. Mori, and E. L. Ortolani. 2009. Clinical observations of cattle and buffalos with experimentally induced chronic copper poisoning. *Res. Vet. Sci.* 87:473–478.
- Murphy, K. J., T. J. Hayden, and J. P. Kent. 2014. Chicks change their pecking behaviour towards stationary and mobile food sources over the first 12 weeks of life: improvement and discontinuities. *Peer J.* 2:e626.
- National Research Council. 2005. *Mineral Tolerance of Animals*. Natl. Acad. Press, Washington, D.C.
- Osorio, D., M. Vorobyev, and C. D. Jones. 1999. Colour vision of domestic chicks. *J. Exp. Biol.* 202:2951–2959.
- Pesti, G. M., and R. I. Bakalli. 1996. Studies on the feeding of cupric sulfate pentahydrate and cupric citrate to broiler chickens. *Poult. Sci.* 75:1086–1091.
- Puls, R. 1988. *Mineral Levels in Animal Health: Diagnostic Data*. 1st ed. Sherpa International, Clearbrook, BC.
- Porter, R. E. 2018. Overview of Poisonings in Poultry. *Merck Vet. Man.* Accessed Jul. 2018. <https://www.merckvetmanual.com/poultry/poisonings/overview-of-poisonings-in-poultry>.
- Russell, S. M. 2008. The effect of an acidic, copper Sulfate-Based commercial sanitizer on indicator, pathogenic, and spoilage bacteria associated with broiler chicken carcasses when applied at various intervention points during poultry processing. *Poult. Sci.* 87:1435–1440.
- Sell, B., T. Sniegocki, J. Zmudzki, and A. Posyniak. 2017. Development of an analytical procedure for the determination of multi-class compounds for forensic veterinary toxicology. *J. Anal. Toxicol.* 41:1–9, doi:10.1093/jat/bkx093/4670993.
- Shivanandappa, T., M. K. Krishnakumari, and S. K. Majumder. 1983. Testicular atrophy in Gallus domesticus fed acute doses of copper fungicides. *Poult. Sci.* 62:405–408.
- Vincent, M., P. Hartemann, and M. Engels-Deutsch. 2016. Antimicrobial applications of copper. *Int. J. Hyg. Environ. Health* 219:585–591.
- Wideman, R. F., Y. K. Kirby, T. L. Barton, D. Clark, G. R. Bayyari, W. E. Huff, P. A. Moore, and P. A. Dunn. 1996. Excess dietary copper triggers enlargement of the proventriculus in broilers. *J. Appl. Poult. Res.* 5:219–230.