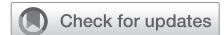

# Doubly committed ventricular septal defect: Is it safe to perform surgical closure through the pulmonary trunk approached by right vertical axillary thoracotomy?



Uoc Huu Nguyen, MD, PhD,<sup>a</sup> Truong Ly Thinh Nguyen, MD, PhD,<sup>b</sup> Yasuhiro Kotani, MD, PhD,<sup>c</sup> Mai Tuan Nguyen, MD,<sup>b</sup> Duyen Dinh Mai, MD,<sup>b</sup> Van Anh Thi Nguyen, MD,<sup>d</sup> and Nam Trung Nguyen, MD<sup>e</sup>

## ABSTRACT

**Objective:** This study investigated the safety of performing surgical repair for doubly committed ventricular septal defects by right vertical infra-axillary minithoracotomy (RVIAT).

**Methods:** A retrospective comparative study was performed to evaluate the outcomes of patients who underwent doubly committed ventricular septal defects closure from January 2019 to May 2022. Seventy-four patients were enrolled in the study and treated with either the median sternotomy approach (MSA: n = 37) or the RVIAT approach (RVIAT: n = 37).

**Results:** The median weight and age in the MSA group were significantly lower than those in the RVIAT group (MSA: 6.0 kg [interquartile range] (IQR), 5.2 to 8.7 kg] vs RVIAT: 7.5 kg [IQR, 5.6-14 kg];  $P = .034$  and MSA: 4.9 months [IQR, 3.6-9.4 month] vs 9.6 months [IQR, 5.0-60.4 months];  $P = .0084$ ). No patients died, and no patients in the RVIAT group required conversion to the MSA approach. The mean prebypass surgical time was longer in the RVIAT group ( $36.1 \pm 8.2$  minutes vs  $31.8 \pm 5.6$  minutes;  $P = .03$ ). There were no significant differences between the 2 groups in cardiopulmonary bypass time, aortic crossclamp time, or operation time. Significantly shorter ventilation times were observed in the RVIAT group ( $11.9 \pm 8.2$  hours vs  $15.4 \pm 6.3$  hours;  $P = .006$ ).

**Conclusions:** Closure of doubly committed ventricular septal defects through the pulmonary trunk by the RVIAT approach is feasible and safe, and does not increase the risk of bypass-related complications. (JTCVS Open 2023;15:368-73)



DCVSD closure via the RVIAT approach.

### CENTRAL MESSAGE

The RVIAT approach is feasible and safe for DCVSD closure through the pulmonary trunk and does not increase the risk of bypass-related complications.

### PERSPECTIVE

In this study, investigators found that patients who underwent the RVIAT technique for DCVSD closure had shorter mechanical ventilation times than the MSA group. The RVIAT method is workable and less intrusive when bypass is utilized.

▶ Video clip is available online.

From the <sup>a</sup>Department of Surgery, Hanoi Medical University, Hanoi, Vietnam; Departments of <sup>b</sup>Cardiovascular Surgery and <sup>c</sup>Cardiology, Vietnam National Children's Hospital, Hanoi, Vietnam; <sup>d</sup>Department of Cardiovascular Surgery, Okayama University Hospital, Okayama, Japan; and <sup>e</sup>Department of Thoracic and Cardiovascular Surgery, Thanh Hoa Children Hospital, Thanh Hoa, Vietnam. Clinical Trial Registration: Ref. No. 2606/QD-BVNTU-HĐĐĐ.

Ethics Approval: This study was approved by the Vietnam National Children's Hospital.

Informed Consent: According to our National Legislation and the Institutional Requirements, written informed consent was not required for this retrospective study. Received for publication April 1, 2023; revisions received May 22, 2023; accepted for publication June 20, 2023; available ahead of print July 25, 2023.

Address for reprints: Truong Ly Thinh Nguyen, MD, PhD, Department of Cardiovascular Surgery, Vietnam National Children's Hospital, 18/879 La Thanh St, Dong Da, Hanoi, 10000 Vietnam (E-mail: [nltruong@gmail.com](mailto:nltruong@gmail.com)).

2666-2736

Copyright © 2023 The Author(s). Published by Elsevier Inc. on behalf of The American Association for Thoracic Surgery. This is an open access article under the CC BY-NC-ND license (<http://creativecommons.org/licenses/by-nc-nd/4.0/>). <https://doi.org/10.1016/j.xjon.2023.06.012>

The median sternotomy approach (MSA) is considered a standard procedure for heart surgery involving congenital heart defects (CHDs). Conventionally, surgical closure of a doubly committed ventricular septal defect (DCVSD) has been performed through the pulmonary artery trunk using a patch with continuous sutures or interrupted sutures with pledgets.<sup>1,2</sup> The objective of a surgical technique to close a DCVSD is to repair the shunt and to avoid damage to the aortic valve beneath the VSD.

Recent developments in surgical techniques and devices combined with increasing demand for improved postsurgery cosmetic results presents an opportunity for

### Abbreviations and Acronyms

CHD	= congenital heart defect
DCVSD	= doubly committed ventricular septal defect
ICU	= intensive care unit
MSA	= median sternotomy approach
RVIAT	= right vertical infra-axillary mini-thoracotomy

the use of minimally invasive methods for treating various common CHDs.<sup>3-7</sup> Numerous minimally invasive surgical techniques have been introduced to repair various CHDs, including ministernotomy, right anterior minithoracotomy, right vertical infra-axillary minithoracotomy (RVIAT), and total endoscopy.<sup>8-13</sup> However, the RVIAT approach is considered unsuitable for DCVSD closure due to the difficulty associated with exposing lesions in the left side of the chest using this technique, especially in adolescents and adults, and is quite different from the right thoracotomy approach.<sup>5</sup> In this study, we investigated the feasibility and safety of surgical closure of DCVSDs using the RVIAT approach in a single institution.

### METHODS

From January 2019 to May 2022, 74 patients who were diagnosed with DCVSD and underwent surgical closure at Vietnam National Children's Hospital were consecutively enrolled in this study (2606/QD-BVNTU-HĐĐĐ, 12/27/2021). Since the minimally invasive open-heart surgery via the RVIAT approach was introduced at our hospital with the support of Okayama University Hospital in August 2019, the first patient with DCVSD who underwent VSD closure via RVIAT was treated in January 2020. Therefore, data from patients diagnosed with DCVSD who underwent RVIAT were collected from January 2020 to May 2022 ( $n = 37$ ). Data from patients who underwent MSA were collected retrospectively from January 2019 to December 2019 as a control group ( $n = 37$ ). According to our national legislation and the institutional requirements, written informed consent was not required for this retrospective study.

Indications for surgical repair were left ventricular enlargement, progressive congestive heart failure, prolapse of the aortic valve, and recurrent respiratory infections. DCVSD closure is indicated for patients with a weight of more than 4 kg and an age older than 2 months. The presence of a patent ductus arteriosus or a left superior vein cava was not considered a contraindication for performing the RVIAT approach.

### Surgical Techniques

**RVIAT group.** Patients were placed in a left lateral decubitus position with the right side elevated by 70° to 80°. The right arm was slung with a wrapped soft cloth and positioned over the head. The pelvis was elevated 45°, and the shoulder joint was approximately 100° to 120°. A marker was used to make the anterior axillary line, the middle axillary line, the posterior axillary line, and the fourth to the fifth intercostal line. A middle axillary incision of 5 to 7 cm was performed, and the thorax was entered regularly through the fifth intercostal space and recently through the fourth intercostal space. The standard Finochietto rib spreader was used, and the lung was retracted posteriorly with a wet sponge in patients weighing <7 to

8 kg; single left lung ventilation was applied in patients weighing more than 8 kg. Direct vision was used without a port at the thoracotomy site. Local anesthesia was introduced routinely using intercostal nerve block with a single dose of levobupivacaine 0.25% (0.5-1.5 mg/kg) and then a programmed intermittent epidural bolus every 3 hours through the epidural catheter placed intrapleural by the surgeon via the minithoracotomy. The pericardium was opened 2 cm anterior to the phrenic nerve and retracted with stay traction sutures to expose the aorta, the superior vena cava, and the inferior vena cava. Cardiopulmonary bypass was conducted with a Livanova 135° curved tip arterial cannula, 2 venous cava cannulas, and a vent tube inserted via the right superior pulmonary vein. The aortic cannula was inserted into the lateral side of the aorta with the support of Babcock intestinal forceps. More recent practice has been to introduce the inferior vena cava venous cannula through a separate incision (5-7 mm) in the sixth intercostal space, which is subsequently used for chest tube placement. If a patent ductus arteriosus was present, it was dissected and ligated after starting the cardiopulmonary bypass, and a vessel loop retracted at the right pulmonary artery was used to help expose the patent ductus arteriosus. The bypass was maintained at 32 °C, and both vena cavae were snared. The instruments used for aortic crossclamping were the DeBakey ductus clamp (for infants) or the DeBakey aortic aneurysm clamp (for adolescents). A simple set of endoscopic instruments was used for the included adolescent patients: forceps, needle holders, and knot pushers. Cold crystalloid Histidine-Tryptophan-Ketoglutarate cardioplegia was induced through the aortic root after aortic crossclamping. A small hole was opened at the right atrium to remove the crystalloid cardioplegia solution to reduce hemodilution. In cases where a left superior vena cava was present, a sump sucker was placed at the coronary sinus without snaring the left superior vena cava. The cardioplegic cannula was removed for improved visualization after finishing the cardioplegia infusion.

The main pulmonary artery trunk was retracted, and a longitudinal incision was made up to the base of the pulmonary sinus. A Cushing vein retractor and 2 stay traction sutures along the border of the pulmonary incision were used to expose the ventricular septal defect. Interrupted polypropylene sutures with pledget support were inserted, and the DCVSD was closed with a bovine pericardial patch (Figure 1). The suture was started at 5 o'clock from the surgeon's perspective as the deepest of the VSD border and was retracted to the left side for better visualization of the next suture at 6 o'clock. The subarterial border of the DCVSD is easily seen through the opening of the pulmonary trunk, with interrupted pledget sutures passing through the pulmonary annulus, and aortic valve injuries are totally prevented. In 3 patients who presented with total conal septum insufficiency resulting in a large DCVSD that extended to the perimembranous septum, a combination of the right atrial approach and main pulmonary artery trunk approach was used to close the defect. No right ventricular outflow tract incision has been used thus far, and direct closure of the defect was avoided. Additional procedures, which included atrial septal defect closure, tricuspid valve repair, and resection of the jet lesion in the right ventricular outflow tract, were performed if needed (Video 1).

After completely closing the defect, the pulmonary artery trunk was closed with running sutures, the heart was filled for de-airing via the cardioplegia catheter hole, and the aortic crossclamp was released. The cardiopulmonary bypass was weaned off, the pericardium was left open, and a single chest tube drain was used through the hole at the sixth intercostal space. Transesophageal echocardiography was performed to confirm the result of surgery in the operating room before transferring the patient to the intensive care unit (ICU). Sedation was not used after the operation, and early extubation in the operating room, whenever reasonable, was considered for all patients.

**MSA group.** Patients were placed in a supine position, and a midline ministernotomy approach was used. Standard cardiopulmonary bypass was introduced with arterial cannula and bicaval venous cannulation. After aortic crossclamping, a cold crystalloid Histidine-Tryptophan-Ketoglutarate cardioplegia solution was introduced through the aortic root cardioplegic cannula. The procedure for DCVSD closure in the MSA group is



**FIGURE 1.** Exposure of the doubly committed ventricular septal defect (VSD) via the right vertical infra-axillary minithoracotomy (RVIAT) approach.

described as for the RVIAT group. The sternum was closed after 2 drains were inserted into the pericardium cavity and the mediastinal cavity.

**Statistical analysis.** Categorical variables are presented as absolute values and as percentages. Continuous variables are described as median and interquartile range (IQR), and categorical variables are expressed as frequencies and percentages. All statistical tests were 2-tailed. Categorical variables were compared using Pearson  $\chi^2$  test. In cases in which the expected frequency was  $<5$ , Fisher exact test was used. Continuous variables were compared using the  $t$  test or Wilcoxon test based on the normality of the data. Data were collected and analyzed using R studio 2022.02.1 software.

## RESULTS

The patient demographics of both groups are shown in Table 1. The median age of the MSA group was significantly lower than that of the RVIAT group (4.9 months [IQR, 3.6-9.4 months] vs 9.6 months [IQR, 5.0-60.4 months];  $P = .0084$ ). The median weight of the MSA group was also significantly lower than that of the RVIAT group (6.0 kg [IQR, 5.2-8.7 kg] vs 7.5 kg [IQR, 5.6-14];  $P = .034$ ). The VSD diameter was not significantly different between the two groups. The median VSD diameter before the operation in the MSA group was 8.0 mm (IQR, 7.0-11 mm), comparable to that in the RVIAT group (8.0 mm; IQR, 7.0-10 mm). No case in the RVIAT group was converted to the MSA approach.

### Perioperative Data

Early mortality or late mortality was not observed in either group. The prebypass surgical time (calculated as the time from skin incision to the start of partial cardiopulmonary bypass) in the RVIAT group was significantly higher than that in the MSA group ( $31.8 \pm 5.6$  minutes vs  $36.1 \pm 8.2$  minutes;  $P = .03$ ). The median length of incision in the RVIAT group was 6 cm (IQR, 5-6 cm). As shown in Table 2, there were no significant differences between

**TABLE 1. Patient demographics**

Variables	RVIAT (n = 37)	MSA (n = 37)	P value
Age (mo)	9.6 (5.03-60.4)	4.9 (3.6-9.4)	.0084
Sex			.3500
Male	16 (43)	21 (57)	
Female	21 (57)	16 (43)	
Weight (kg)	7.5 (5.6-14)	6.0 (5.2-8.7)	.0340
VSD diameter (mm)	$8.4 \pm 3.2$	$8.9 \pm 3.2$	.3400
Total canal defect	3 (8)	0 (0)	
Moderate MR	2 (5)	1 (3)	
Mild AR	7 (19)	0 (0)	

Values are presented as median (interquartile range), n (%), or mean  $\pm$  SD. RVIAT, Right vertical infra-axillary mini-thoracotomy; MSA, median sternotomy approach; VSD, ventricular septal defect; MR, mitral valve regurgitation; AR, aortic valve regurgitation.

groups in the mean aortic crossclamp time, the mean bypass time, and the mean operation time. However, the mean time of mechanical ventilation in the RVIAT group was significantly shorter than that in the MSA group ( $11.9 \pm 8.2$  hours vs  $15.4 \pm 6.3$  hours;  $P = .006$ ). Five patients experienced postoperative arrhythmia in the RVIAT group, including 3 with junctional ectopic tachycardia, 1 with sinus bradycardia, and 1 with atrial tachycardia, whereas no patients experienced arrhythmia after surgery in the MSA group ( $P = .05$ ). All patients with tachycardiac arrhythmia fully recovered after cooling and medications. Before discharge, 2 patients in the MSA group had residual VSD, but no residual VSD was found in the RVIAT group. All residual VSD was spontaneously closed 6 months after surgery. At a median follow-up time of 35.9 months (IQR, 15.9-40.6 months), all patients survived with New York Heart Association functional class I.

## DISCUSSION

The RVIAT approach has been applied to repair simple CHDs and is demonstrated to be a safe approach with satisfactory cosmetic results compared with conventional MSA.<sup>7,8,10,11</sup> DCVSD closure has a limited number of reports from Fuwai Hospital<sup>14,15</sup> and Qingdao University Hospital.<sup>16</sup> DCVSD closure through the tricuspid valve using the RVIAT approach by Fuwai's team was performed with a very short aortic crossclamp time. Additionally, they suggested sutures at the superior edge of the patch could be placed through the aortic sinus, which requires an additional incision in the ascending aorta. The team from Qingdao University Hospital has chosen to close the DCVSD with a right subaxillary thoracotomy via the incision at the pulmonary artery trunk or right ventricular outflow tract. They are more comfortable closing the DCVSD by the RVIAT approach and recommend using this approach for surgeons who are not experienced with the thoracotomy

**TABLE 2. Perioperative data**

Perioperative data	RVIAT (n = 37)	MSA (n = 37)	P value
Operation time (min)	154.7 ± 31.1	151.7 ± 17.3	.59
Aortic crossclamp time (min)	54.1 ± 19.0	46.9 ± 11.7	.08
Bypass time (min)	71.8 ± 21.5	64.9 ± 11.6	.21
Prebypass surgical time (min)	36.1 ± 8.2	31.8 ± 5.6	.03
Mechanical ventilation time (h)	11.9 ± 8.2	15.4 ± 6.3	.006
ICU stay time (d)	1.9 ± 0.7	1.9 ± 0.7	.89
Hospital time after surgery (d)	8.6 ± 3.1	9.9 ± 3.4	.09
Blood transfusion	48.6%	59.5%	.48
Arrhythmia	5 (13.5%)	0	.05
Residual shunt	0	2 (5.4%)	
Atelectasis	2 (5.4%)	0	
Hemorrhage	0	2 (5.4%)	
Wound infection	1 (2.7%)	1 (2.7%)	
Pneumothorax	0	1 (2.7%)	

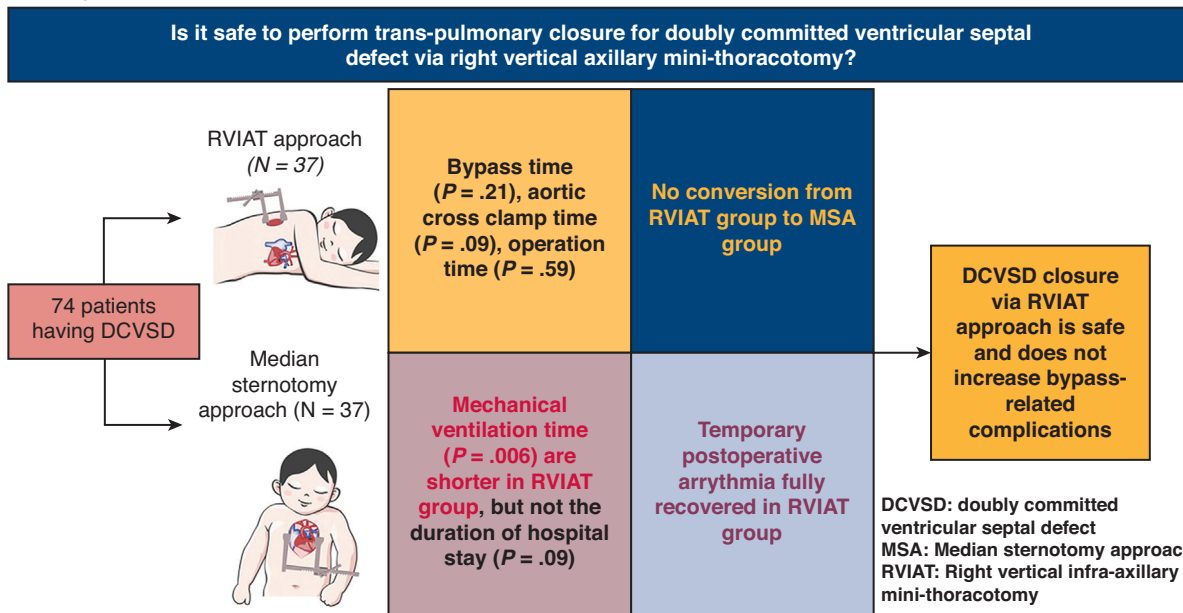
Values are presented as mean ± SD unless otherwise noted. RVIAT, Right vertical infra-axillary mini-thoracotomy; MSA, median sternotomy approach; ICU, intensive care unit.

approach. Due to the difficulty approaching through right-side thoracotomy, Zhu and colleagues<sup>5</sup> used left anterolateral thoracotomy and peripheral cardiopulmonary bypass to close the DCVSD through the pulmonary trunk with a technique similar to the conventional MSA approach. According to our cumulative experiences of DCVSD

closure via the RVIAT approach, the left anterolateral thoracotomy approach might be unnecessary to close the DCVSD. Cherup and colleagues<sup>17</sup> also reported that anterolateral thoracotomy in the third or fourth space of a child may result in significant breast or pectoral asymmetry in at least 60% of children operated on.

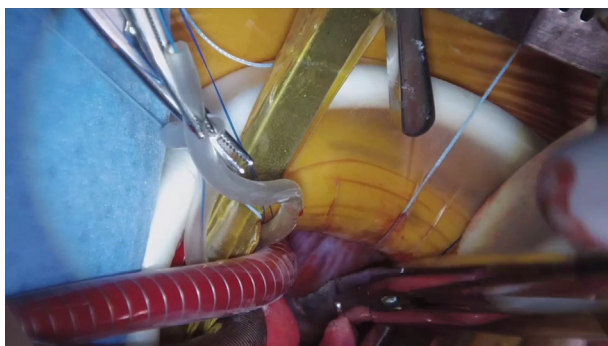Technically, the most critical part of closure of a DCVSD is the superior border, which has a risk of aortic valve injury. We doubt that closure of a DCVSD through the tricuspid valve will be a safe approach for preventing aortic valve injury, especially in cases of moderate or severe aortic valve prolapse, which is not a rare complication of DCVSD in infants or young adolescents. For that reason, approaching through the pulmonary artery trunk is our first choice. In the beginning, we started the thoracotomy by the fifth intercostal space, which required more time and did not enable good visualization of the DCVSD. Recently, we have approached the fourth intercostal space, which provides better visualization and better exposure. We removed the cardioplegia needle immediately after completing the cardioplegia infusion to minimize the instrumentation in an already crowded operative field. No patient in our study had intraoperative aortic valve injury or the degree of aortic valve insufficiency progressing after surgery and during follow-up.

In our study, the lower limits of patient age (2 months) and weight (4 kg) were the only criteria used to select patients, and more older patients were accidentally included



**FIGURE 2.** Doubly committed ventricular septal defect (VSD) closure via the right vertical infra-axillary minithoracotomy (RVIAT) approach is feasible and does not increase the rate of bypass-related complications. MSA, Median sternotomy approach; DCVSD, doubly committed ventricular septal defect.





**VIDEO 1.** Video demonstration of the RVIAT approach for DCVSD closure. Video available at: [https://www.jtcvs.org/article/S2666-2736\(23\)00173-0/fulltext](https://www.jtcvs.org/article/S2666-2736(23)00173-0/fulltext).

in the RVIAT group, which explains why the mean prebypass surgical time was longer in the RVIAT group than the MSA group ( $P = .03$ ) and indicates the possibility of a more difficult preparing cannulation via the thoracotomy approach. However, our operation results showed that there were no significant differences between groups in bypass time ( $P = .21$ ), aortic crossclamp time ( $P = .08$ ), and operation time ( $P = .59$ ). In our study, the oldest patient was 15 years old (46 kg), and some patients were older than age 10 years. Approaching the DCVSD through the main pulmonary trunk via RVIAT was much more challenging in these patients than in infants because of the larger thoracic depth and deeper surgical field created by the pulmonary artery's location on the left side of the thorax, which did not reflect the learning curve. We recommend starting the RVIAT approach of DCVSD closure for a patient with a body weight of approximately 7 to 8 kg to obtain better visualization and easier cannulation.

In our study, the mechanical ventilation time in the RVIAT group was significantly shorter than that in the MSA group ( $P = .006$ ), and that there was a trend toward a shorter duration of hospital stay ( $P = .09$ ). More patients who underwent the RVIAT approach were extubated in the operating room, resulting in a shorter ICU stay and early discharge from the hospital, which is helpful for decreasing associated medical costs (Figure 2). Our strategy of using local anesthesia for intercostal nerve block with levobupivacaine before starting the intracardiac procedure helped promote early extubation in the RVIAT group. This strategy was also proven effective in reducing pain and opioid use for maintaining sedation during surgery.<sup>18-20</sup> Most of the patients in our study did not require any additional dose of fentanyl or muscle relaxant after levobupivacaine was administered. Although some patients developed arrhythmia after undergoing the RVIAT approach in the early stages of the study period, possibly due to the manifestation of adverse outcomes related to levobupivacaine use for anesthesia, the length of ICU stay was comparable between the groups ( $P = .89$ ). However,

because we reduced the dose of levobupivacaine to 0.5 mg/kg, no significant arrhythmia was detected in the ICU.

The current study included 3 patients diagnosed with total conal defects resulting in a very large VSD from the juxta-arterially deviated to the membranous septum, which required closing the VSD through the pulmonary artery trunk combined with the tricuspid valve approach. Despite this, no patients in the RVIAT group were transferred to the MSA group, and neither required extension of the incision for clearer visualization. RVIAT for DCVSD closure should be performed by an experienced surgeon with the ability to introduce safe cardiopulmonary bypass, overcome the challenge of difficult VSD exposure with a long-distance approach to the pulmonary artery trunk, and potentially limit complications during the operation. Overall, our results demonstrated that RVIAT is indeed feasible, reproducible, and safe despite the defect being present in the left side of the chest and far removed from the right side of the chest.

#### Limitations

Our study has many limitations, including a small number of patients, a retrospective study design, and enrollment in a single institution. The follow-up time may need further extension to more precisely evaluate the effectiveness of DCVSD closure via the RVIAT approach. Future studies involving multiple institutions are essential to further evaluate patient outcomes associated with the RVIAT approach.

#### CONCLUSIONS

Closure of the DCVSD through the RVIAT is feasible and safe, and does not increase bypass-related complications.

#### Conflict of Interest Statement

The authors reported no conflicts of interest.

The *Journal* policy requires editors and reviewers to disclose conflicts of interest and to decline handling or reviewing manuscripts for which they have a conflict of interest. The editors and reviewers of this article have no conflicts of interest.

#### References

1. Sim EKW, Grignani RT, Wong ML, Quek SC, Wong JCL, Yip WCL, et al. Outcome of surgical closure of doubly committed subarterial ventricular septal defect. *Ann Thorac Surg*. 1999;67:736-8.
2. Shamsuddin AM, Chen YC, Wong AR, Le TP, Anderson RH, Corno AF. Surgery for doubly committed ventricular septal defects. *Interact Cardiovasc Thorac Surg*. 2016;23:231-4.
3. Pretre R, Kadner A, Dave H, Dodge-Khatami A, Bettex D, Berger F. Right axillary incision: a cosmetically superior approach to repair a wide range of congenital cardiac defects. *J Thorac Cardiovasc Surg*. 2005;130:277-81.
4. Dave HH, Comber M, Solinger T, Bettex D, Dodge-Khatami A, Prêtre R. Mid-term results of right axillary incision for the repair of a wide range of congenital cardiac defects. *Eur J Cardio Thorac Surg*. 2009;35:864-70.
5. Zhu J, Zhang Y, Bao C, Ding F, Mei J. Individualized strategy of minimally invasive cardiac surgery in congenital cardiac septal defects. *J Cardiothorac Surg*. 2022;17:5.

6. Dodge-Khatami A, Salazar JD. Right axillary thoracotomy for transatrial repair of congenital heart defects: VSD, partial AV canal with mitral cleft, PAPVR or warden, cor triatriatum, and ASD. *Oper Tech Thorac Cardiovasc Surg.* 2015;20:384-401.
7. An G, Zhang H, Zheng S, Wang W, Ma L. Mid-term outcomes of common congenital heart defects corrected through a right subaxillary thoracotomy. *Heart Lung Circ.* 2017;26:376-82.
8. Hong ZN, Chen Q, Lin ZW, Zhang GC, Chen LW, Zhang QL, et al. Surgical repair via submammary thoracotomy, right axillary thoracotomy and median sternotomy for ventricular septal defects. *J Cardiothorac Surg.* 2018;13:47.
9. Mishaly D, Ghosh P, Preisman S. Minimally invasive congenital cardiac surgery through right anterior minithoracotomy approach. *Ann Thorac Surg.* 2008;85:831-5.
10. Liu H, Wang Z, Xia J, Hu R, Wu Z, Hu X, et al. Evaluation of different minimally invasive techniques in surgical treatment for ventricular septal defect. *Heart Lung Circ.* 2018;27:365-70.
11. Wang Q, Li Q, Zhang J, Wu Z, Zhou Q, Wang DJ. Ventricular septal defects closure using a minimal right vertical infraaxillary thoracotomy: seven-year experience in 274 patients. *Ann Thorac Surg.* 2010;89:552-5.
12. Ma ZS, Wang JT, Dong MF, Chai SD, Wang LX. Thoracoscopic closure of ventricular septal defect in young children: technical challenges and solutions. *Eur J Cardio Thorac Surg.* 2012;42:976-9.
13. Konstantinov IE, Kotani Y, Buratto E, Schulz A, Ivanov Y. Minimally invasive approaches to atrial septal defect closure. *J Thorac Cardiovasc Surg Tech.* 2022;14:184-90.
14. Liu R, Rui L, Zhang B, Lin Y, Li S, Hua Z. Through tricuspid closure for doubly committed subarterial ventricular septal defect with right vertical subaxillary - mini-incision: a matched-pair analysis. *Pediatr Cardiol.* 2019;40:1247-52.
15. Wang G, Liu R, Ma K, Zhang B, Pang K, Qi L, et al. Doubly committed subarterial ventricular septal defect closure through tricuspid approach: a clinical analysis. *Cardiol Young.* 2021;31:799-803.
16. An G, Zhang H, Zheng S, Wang W, Wu Q, Xing Q. Minimally invasive surgical closure for doubly committed subarterial ventricular septal defects through a right subaxillary thoracotomy. *Interact Cardiovasc Thorac Surg.* 2016;23:924-8.
17. Cherup LL, Siewers RD, Futrell JW. Breast and pectoral muscle maldevelopment after anterolateral and posterolateral thoracotomies in children. *Ann Thorac Surg.* 1986;41:492-7.
18. Lukošienė L, Kalibaitienė L, Barauskas V. Intercostal nerve block in pediatric minimally invasive thoracic surgery. *Acta Med Litu.* 2012;19:150-3.
19. Kaushal B, Chauhan S, Saini K, Bhoi D, Bisoi AK, Sangdup T, et al. Comparison of the efficacy of ultrasound-guided serratus anterior plane block, pectoral nerves II block, and intercostal nerve block for the management of postoperative thoracotomy pain after pediatric cardiac surgery. *J Cardiothorac Vasc Anesth.* 2019; 33:418-25.
20. Kobayashi Y, Kasahara S, Kotani Y. Right vertical infra-axillary thoracotomy approach in simple congenital heart diseases. *Oper Tech Thorac Cardiovasc Surg.* 2022;27:294-301.

**Key Words:** doubly committed ventricular septal defect, right vertical axillary mini-thoracotomy, congenital heart defect