

Ropivacaine continuous wound infusion after mastectomy with immediate autologous breast reconstruction

A retrospective observational study

Jeong Eun Lee, MD, PhD^a , Young Je Park, MD^a, Jeong Woo Lee, MD, PhD^{b,*} 

Abstract

Continuous wound infusion usually provides postoperative analgesia as a multimodal analgesia with systemic opioid use. When continuous wound infusion of local anesthetics (LA) supports successful postoperative analgesia without systemic opioid use, the side effects of opioid can be reduced. Nevertheless, continuous wound infusion after mastectomy with immediate autologous breast reconstruction leads to concerns about wound healing. This study evaluated analgesic effects and wound healing conditions of continuous wound infusion of LA compared with opioid-based, intravenous patient-controlled analgesia (IV PCA) in mastectomy with immediate autologous breast reconstruction.

This retrospective observational study included females, aged between 33 and 67 years, who underwent mastectomy with immediate autologous breast reconstruction. Sixty-five patients were enrolled. The eligible patients were placed into 2 groups for managing postoperative pain, one used continuous wound infusion with 0.5% ropivacaine (ON-Q, $n=32$) and the other used a fentanyl-based IV PCA (IV PCA, $n=33$). Using the electronic medical record system, the postoperative recovery profiles were examined over 5 days using a visual analogue scale (VAS), incidence of postoperative nausea and vomiting (PONV), incidence of sleep disturbance, frequency of rescue analgesic use, analgesia-related adverse events, length of hospital stay, and degree of patient satisfaction. The condition of the surgical wound was observed for 1 year after surgery.

The primary endpoint was the intensity of pain at 6 hours after surgery. The VAS was comparable between the groups ($P > .05$). Although recovery profiles and the degree of patient satisfaction were similar between the groups, the incidence of PONV was significantly lower in the ON-Q group than in the IV PCA group on the day of surgery and postoperative day 1. No patients had severe wound complications. The satisfaction score of analgesia in the ON-Q group was comparable with that of the patients in the IV PCA group.

This study demonstrates that single use of continuous wound infusion showed comparable analgesia with fentanyl-based IV PCA in patients who underwent mastectomy with immediate autologous breast reconstruction. Furthermore, the continuous infusion of LA directly on the surgical site did not significantly affect wound healing.

Abbreviations: IV PCA = intravenous patient-controlled analgesia, LA = local anesthetics, LD = latissimus dorsi, POD = postoperative day, PONV = postoperative nausea and vomiting, VAS = visual analogue scale.

Keywords: fentanyl, local anesthetics, mastectomy, postoperative pain

Editor: Bernhard Schaller.

The authors report no conflicts of interest.

Data availability: The datasets generated during the current study are available from the corresponding author on reasonable request.

All data generated or analyzed during this study are included in this published article [and its supplementary information files]. The datasets generated during and/or analyzed during the current study are available from the corresponding author on reasonable request.

^aDepartment of Anesthesiology and Pain Medicine, ^bDepartment of Plastic and Reconstructive Surgery, School of Medicine, Kyungpook National University, Kyungpook National University Hospital, Daegu, Republic of Korea.

*Correspondence: Jeong Woo Lee, Department of Plastic and Reconstructive Surgery, School of Medicine, Kyungpook National University, 130, Dongdeok-ro, Jung-gu, Daegu 41944, Republic of Korea (e-mail: jeongwoo@knu.ac.kr).

Copyright © 2021 the Author(s). Published by Wolters Kluwer Health, Inc.

This is an open access article distributed under the terms of the Creative Commons Attribution-Non Commercial License 4.0 (CCBY-NC), where it is permissible to download, share, remix, transform, and buildup the work provided it is properly cited. The work cannot be used commercially without permission from the journal.

How to cite this article: Lee JE, Park YJ, Lee JW. Ropivacaine continuous wound infusion after mastectomy with immediate autologous breast reconstruction: A retrospective observational study. *Medicine* 2021;100:24(e26337).

Received: 28 May 2019 / Received in final form: 24 May 2021 / Accepted: 25 May 2021

<http://dx.doi.org/10.1097/MD.00000000000026337>

1. Introduction

Mastectomy with immediate autologous breast reconstruction causes moderate to severe pain due to the tension applied at the flap donor site, long duration of surgery, multiple surgical incisions, and frequent chemotherapy or radiotherapy. Patients can also be mentally vulnerable to postoperative pain due to a perceived loss of femininity. Postoperative recovery can be hindered without acute pain control, and continuous noxious stimulation may develop into chronic, uncontrolled neuropathic pain. Up to 50% of the patients develop postoperative pain syndrome after mastectomy.^[1] The first 48 hours after surgery are the most critical and difficult period for controlling acute postoperative pain.^[2] It is difficult to relieve acute postoperative pain with only conventional opioid-analgesics due to opioid-related adverse effects such as respiratory depression, altered consciousness, sleep disturbance, and, mainly, postoperative nausea and vomiting (PONV). Therefore, continuous wound infusion has emerged as an adjunctive therapy for opioid-sparing effects and for reducing opioid-related side effects.^[3–6]

Although continuous wound infusion with local anesthetics (LA) is now recognized as an effective analgesic method in different surgical settings, it is generally used with opioid-based intravenous patient-controlled analgesia (IV PCA). So far, there has been no consensus on whether an analgesic regimen of continuous wound infusion can replace systemic opioid use. Moreover, surgical concerns remain over wound healing, such as the propensity for infection, necrotic change, seroma, and hematoma. Because additional indwelling catheters deliver LA directly to the wound bed over several postoperative days (PODs), surgeons cannot exclude the possibility of surgical complications following aesthetic reconstructive surgery. The correlation between surgical complications and continuous wound infusion has been evaluated in several prospective studies, but there is yet to be a long term follow-up study to report the effect of continuous wound infusion on wound healing.^[7,8] In our hospital, continuous wound infusion with LA has been introduced as a primary option of acute postoperative analgesia for patients with breast cancer since 2013. The purpose of this study is to establish whether continuous wound infusion has a significant analgesic efficacy and influence on wound healing condition when compared with opioid-IV PCA in patients who undergo mastectomy with immediate autologous breast reconstruction.

2. Methods

2.1. Study design and participants

This study was approved by the Institutional Review Board of Kyungpook National University Hospital. All patients who underwent unilateral mastectomy with immediate autologous breast reconstruction using continuous wound infusion or IV PCA between January 2013 and July 2015 were included in the study. The presented figures have been anonymized, and the patients gave their permission for publication. Data up until the 1-year follow-up period were manually retrieved from the patients' completed medical records.

Immediate autologous breast reconstruction included surgery using a latissimus dorsi (LD) flap or the volume displacement technique under general anesthesia. Before surgery, the patient chose the analgesic method after an explanation from the attending physician. The cost of both analgesic methods was

similar, and the methods were explained unbiasedly. The exclusion criteria were patients who were aged <19 or >70 years; American Society of Anesthesiologists physical status III or IV; discontinuation of analgesic therapy (continuous wound infusion or IV PCA); a history of regular use of opioids, other analgesics, sedative medications, or corticosteroids; obesity (BMI >30 kg/m²); and abnormal preoperative levels of C-reactive protein or leukocytosis (>11,000 cells/ μ L).

2.2. Interventions

The patient records were reviewed by anesthesiologists who did not participate in this study. Patients were classified according to the analgesic method used (a continuous wound infusion with 0.5% ropivacaine or IV PCA). The ON-Q group ($n=32$) received a continuous 0.5% ropivacaine infusion at the surgical site via an ON-Q pain pump (ON-Q PainBuster; I-Flow Corporation, Lake Forest, CA), whereas the IV PCA group ($n=33$) received fentanyl-based IV PCA (Accumate 1000; WooYoung Medical, Seoul, Korea).

No patient received premedication. General anesthesia was induced with 2 mg/kg propofol, 0.8 mg/kg rocuronium, and 0.5 to 1 μ g/kg remifentanyl. After endotracheal intubation was performed, patients were ventilated with a mixture of 50% oxygen in air. Patients were monitored intraoperatively by pulse oximetry, electrocardiography, bispectral index, and noninvasive blood pressure measurements taken at 5-minute intervals. Anesthesia was sustained with sevoflurane (1.5–2.5 vol%) and remifentanyl (0.1–0.2 μ g/kg), and the bispectral index was maintained between 40 and 60. Blood pressure and heart rate were controlled to within 20% of the preanesthetic values. An additional injection of 0.3 mg/kg rocuronium was given hourly. Neuromuscular blockades were reversed with 0.2 mg/kg pyridostigmine and 0.01 mg/kg glycopyrrolate.

The same surgical team, which was composed of general and plastic surgeons, performed the mastectomy with immediate autologous breast reconstruction in all cases. In the ON-Q group, 2 multiholed Soaker catheters were inserted at each of the donor and recipient sites before skin closure in the case of LD flap (Fig. 1A and B). After the elevation of LD flap, the plastic surgeon inserted the first ON-Q catheter through an introducer needle, located 2 to 3 cm below the lateral portion of the suture line of LD flap donor, and placed 1 Jackson–Pratt drain inferior to the catheter site. Then, the surgeon inserted the second ON-Q catheter in the same manner 2 to 3 cm inferior to the lateral portion of the inframammary fold before closure of the recipient site. These 2 Jackson–Pratt drains were placed inferior to the ON-Q catheter site. Analgesics delivered via the ON-Q pain pump consisted of 200 mL of 0.75% ropivacaine and 100 mL of normal saline, and were administered through the 2 multiholed Soaker catheters at a rate of 4 mL/h (2 mL/h per catheter). As with LD flap, the plastic surgeon inserted one multiholed Soaker catheter at the surgical site in the volume displacement surgery, and placed 1 Jackson–Pratt drain inferior to the multiholed Soaker catheter site (Fig. 1C). The analgesics delivered via the ON-Q pain pump consisted of 140 mL of 0.75% ropivacaine and 70 mL of normal saline, and they were administered through a multi-holed Soaker catheter at a rate of 2 mL/h. The infusion of analgesics commenced immediately before the completion of skin suture and continued for 3 days postoperatively. When the analgesic device was connected, an IV bolus comprised of 30 mg ketorolac and 0.3 mg ramosetron was injected in both groups.

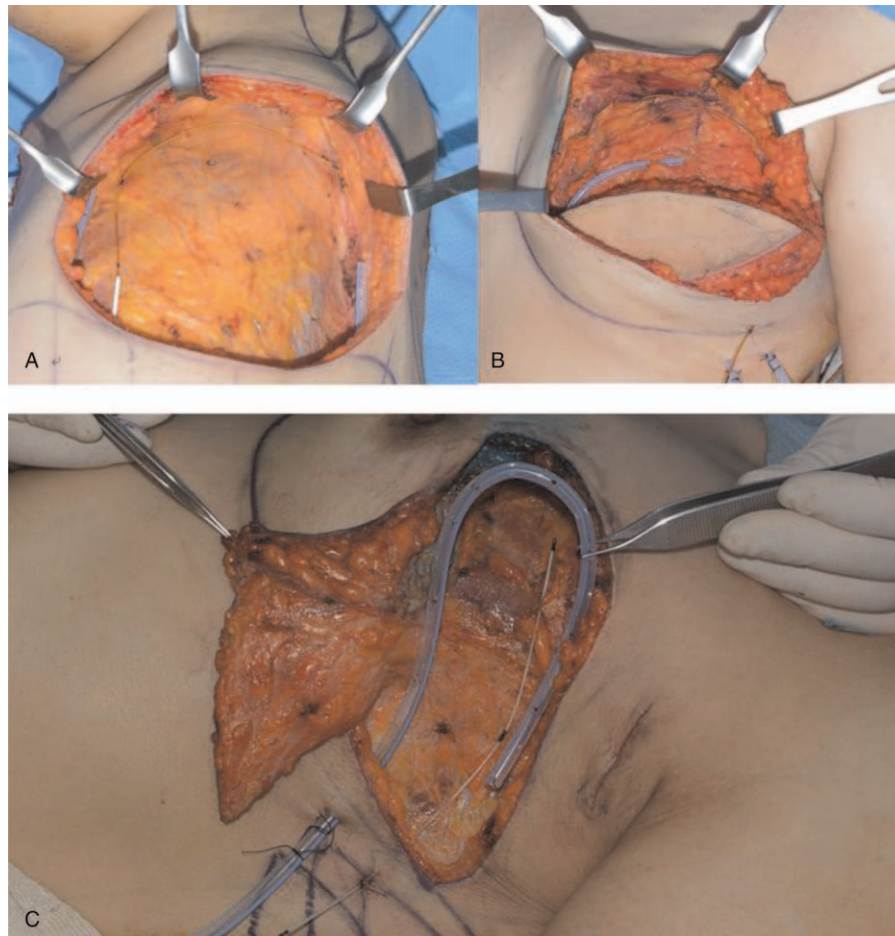

Figure 1. Two multiholed Soaker catheters were inserted at each of the donor (A) and recipient (B) sites before skin closure in cases involving latissimus dorsi flap. A multiholed Soaker catheter was inserted at the surgical site during mastectomy with volume displacement (C).

For the IV PCA group, fentanyl citrate ($25\ \mu\text{g}/\text{kg}$) and ketorolac ($2.5\ \text{mg}/\text{kg}$) were mixed with normal saline to a total volume of $100\ \text{mL}$. This mixture was delivered at a basal infusion rate of $1\ \text{mL}/\text{h}$, a bolus dose of $0.5\ \text{mL}$, and a lockout interval of 15 minutes. Patients in the IV PCA group had Jackson–Pratt drains located at the same sites as the patients in the ON-Q group. Approximately 15 minutes before the end of surgery, an IV PCA was connected, and the infusion continued until POD 3.

2.3. Measurements and outcomes

In our hospital, before breast surgery, all patients learned how to complete a questionnaire on postoperative pain patterns and discomfort; these results were recorded as an electronic medical chart. The questionnaire included information on postoperative pain score (visual analogue scale, VAS), PONV, sleep disturbance, and satisfaction score of postoperative analgesic treatment. Starting at 6 hours after surgery, patients documented their postoperative pain score and the degree of sleep disturbance at the same time each day until POD 5. The patients also recorded the incidence of PONV as either absent or present. The VAS was used to define a pain score, ranging from 0 to 10 (0=no pain, 10=worst pain), and a sleep disturbance scale was used to define pain-related sleep disturbance caused by pain (0=slept very well, 1=difficult to sleep due to pain). When the pain score exceeded 4

or when a patient needed additional analgesia, an IV bolus of $50\ \text{mg}$ tramadol was injected as a rescue analgesic. The number of patients who required rescue analgesics was counted and recorded. After surgery, the plastic surgeon observed the drainage volume daily at a particular time, and the Jackson–Pratt drain catheters were removed when the drainage volume collected during 24 hours was $<10\ \text{mL}$ for 2 consecutive days. The surgeons carefully checked the condition of the surgical wounds every day until the patients were discharged.

The primary outcome was the intensity of pain at 6 hours after surgery. The secondary outcomes were analgesia-related adverse events, analgesic device-related wound conditions, and assessment of patient satisfaction. Data on demographics, physical status, duration of surgery and anesthesia, time until drain removal, and length of hospital stay were also collected. Moreover, the postoperative adverse events, wound complications, and degree of satisfaction with analgesic treatment were evaluated. Surgical wound complications were observed on an outpatient basis for a 1-year period after patient discharge.

2.4. Statistical analysis

All statistical analyses were performed with SPSS 22.0 (SPSS Inc., Chicago, IL). The data were analyzed using Student *t* test (continuous variables with nearly normal distribution, including

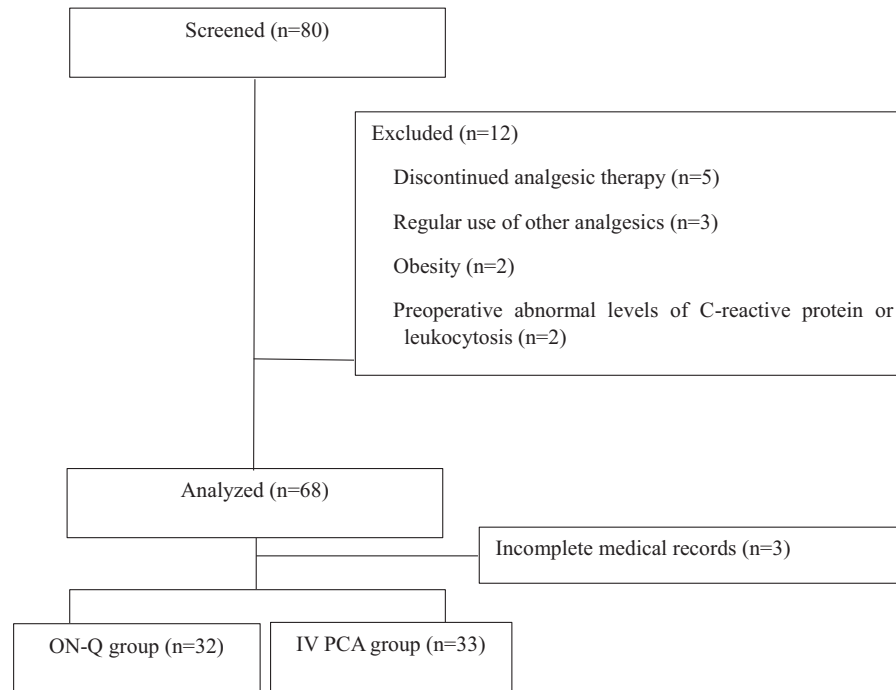


Figure 2. Flow diagram.

patients' age, weight, height, and body mass index), Mann-Whitney *U* test (VAS and patient satisfaction with analgesia), χ^2 test, and Fisher exact test (categorical variables including the American Society of Anesthesiologists classification, number of patients who needed rescue analgesics, and adverse events), as appropriate.

We compared changes in VAS and drainage volume over time between the groups using repeated-measures analysis of variance, and the differences between continuous variables at each time point were compared using *t* tests. The threshold for statistical significance was set at $P < .05$ for all analyses.

Table 1

Demographic data.

	ON-Q (n=32)	IV PCA (n=33)	P
Age, y	45.3±7.7	46.8±8.4	.454
Height, cm	159.2±6.5	158.7±4.3	.713
Weight, kg	56.6±9.6	56.5±6.4	.968
BMI, kg/m ²	22.3±3.0	22.4±2.4	.790
ASA physical status			.199
I	25 (78.1)	21 (63.6)	
II	7 (21.9)	12 (36.4)	
Diabetes mellitus	1 (3.1)	1 (3.0)	>.99
Hypertension	1 (3.1)	3 (9.1)	.613
Tumor location			.174
Left	14 (43.8)	20 (60.6)	
Right	18 (56.3)	13 (39.4)	
Preoperative			
Radiotherapy	0 (0)	1 (3.0)	>.99
Chemotherapy	7 (21.9)	5 (15.2)	.485
TNM stage			.832
0	2 (6.3)	1 (3.0)	
IA	12 (37.5)	14 (42.4)	
IB	2 (6.3)	0 (0)	
IIA	7 (21.9)	13 (39.4)	
IIB	9 (28.1)	5 (15.2)	

Values are presented as mean ± standard deviation or number (%).

IV PCA = intravenous patient controlled analgesia, BMI = body mass index, ASA = American Society of Anesthesiologists, TNM = tumor node metastasis.

3. Results

We assessed the eligibility of the 80 patients during the study period, and excluded 15 patients who met the exclusion criteria and who had incomplete medical records. A total of 65 patients were included in this analysis (Fig. 2). There were no significant differences in demographic data and preoperative disease conditions between the 2 groups (Table 1). The type of reconstruction surgery was classified into LD flap and volume displacement. The weight of the removed tumor and the flap showed no significant difference, indicating that the extent of the surgical wound was similar in the 2 groups (Table 2).

Table 2

Surgical outcomes and perioperative data.

	ON-Q (n=32)	IV PCA (n=33)	P
Type of surgery			.543
LD flap	19 (59.4)	22 (66.7)	
Volume displacement	13 (40.6)	11 (33.3)	
Tumor weight, g	165.8±143.1	163.2±120.7	.937
Flap weight of LD flap, g	312.3±75.1	352.8±74.9	.209
Duration			
Surgery, min	381.3±95.3	376.2±57.0	.886
Anesthesia, min	422.2±98.3	415.3±53.8	.848
Hospital stay, days	14.1±6.5	13.1±4.7	.479
Jackson-Pratt drain insertion, days	10.6±4.5	10.1±3.8	.624

Values are presented as number (%) or mean ± standard deviation.

IV PCA = intravenous patient controlled analgesia, LD = latissimus dorsi.

The pain score 6 hours after surgery of the ON-Q group was analogous to that of the IV PCA group (4.5 ± 2.3 in the ON-Q group vs 4.7 ± 2.5 in the IV PCA group, $P = .735$). The pain scores were also similar between the groups until POD 5 (Fig. 3); thus, no significant differences existed between the groups during the observation period regarding total postoperative rescue analgesic use (Fig. 4). However, the incidence of PONV was significantly lower in the ON-Q group on POD 0 and 1 ($P = .009$ and $P = .019$, respectively) (Fig. 5). Furthermore, no patient from the ON-Q group complained of PONV on POD 4 and 5.

Sleep disturbance was also investigated as another measure of sufficient analgesic treatment, and the incidence of sleep disturbance was comparable between the groups (Fig. 6). Overall, both groups were satisfied with their respective postoperative analgesic method. The analgesic effect of the ON-Q pain pump infusion was as satisfactory to patients as the fentanyl-based IV PCA (Table 3). Despite no statistical difference between the groups, 93.8% of patients in the ON-Q group were willing to reuse the continuous wound infusion method for analgesia if they required a similar surgery in the future.

Regarding the surgical aspect, there was no significant difference in the incidence of wound complications (necrotic change, seroma, and hematoma) in both groups. All the complications were of minimal severity, and there was no flap

loss. The surgeon observed minimal necrotic changes, which was treated with prolonged antibiotics. Seroma and hematoma were aspirated via drain placement and pressure dressings were applied until resolution. As a result, reoperation was not necessary for these patients (Table 4). There were no significant differences in the duration of hospital stay (14.1 ± 6.5 in the ON-Q group vs 13.1 ± 4.7 in the IV PCA group $P = .479$) or Jackson-Pratt drain insertion (10.6 ± 4.5 in the ON-Q group vs 10.1 ± 3.8 in the IV PCA group, $P = .624$) (Table 2). None of the patients had complications related to the analgesic method or medication (Table 4). Moreover, no wound complications or wound infections were observed during the 1-year follow-up period.

4. Discussion

This study demonstrates that continuous wound infusion was sufficiently effective for acute postoperative analgesia and could be used as an alternative method to opioid-based IV PCA in patients undergoing mastectomy with immediate autologous breast reconstruction. Opioid-based IV PCA has been used routinely for postoperative pain control, but opioids have serious consequences such as nausea, vomiting, ileus, respiratory depression, and sedation. Therefore, it has been recommended to reduce opioid use with the multimodal analgesic method for

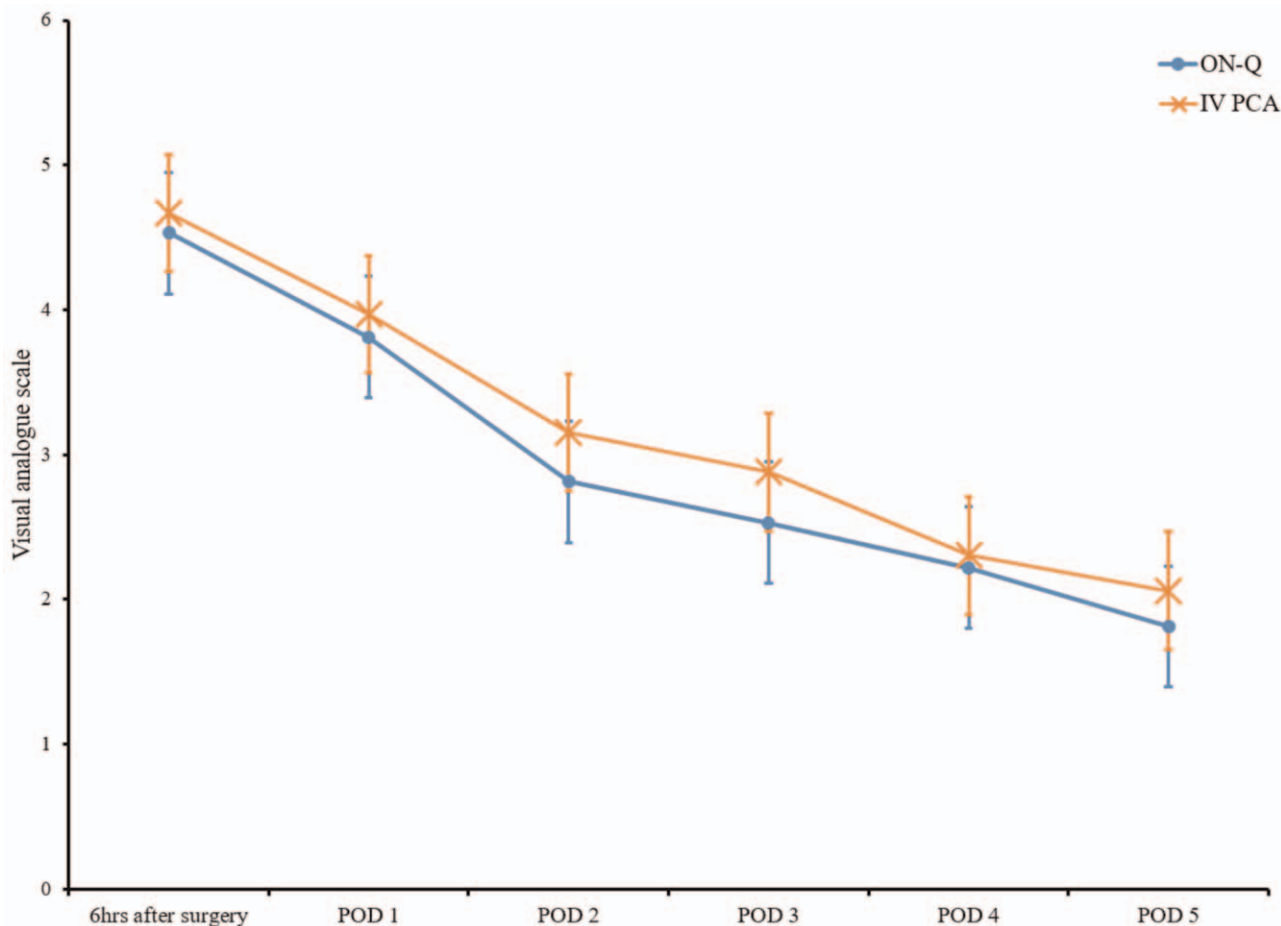


Figure 3. Visual analogue scale pain score. Data are expressed as mean ± standard deviation in both the ON-Q and IV PCA group. No differences were found between the groups. IV PCA=intravenous patient controlled analgesia, POD=postoperative day.

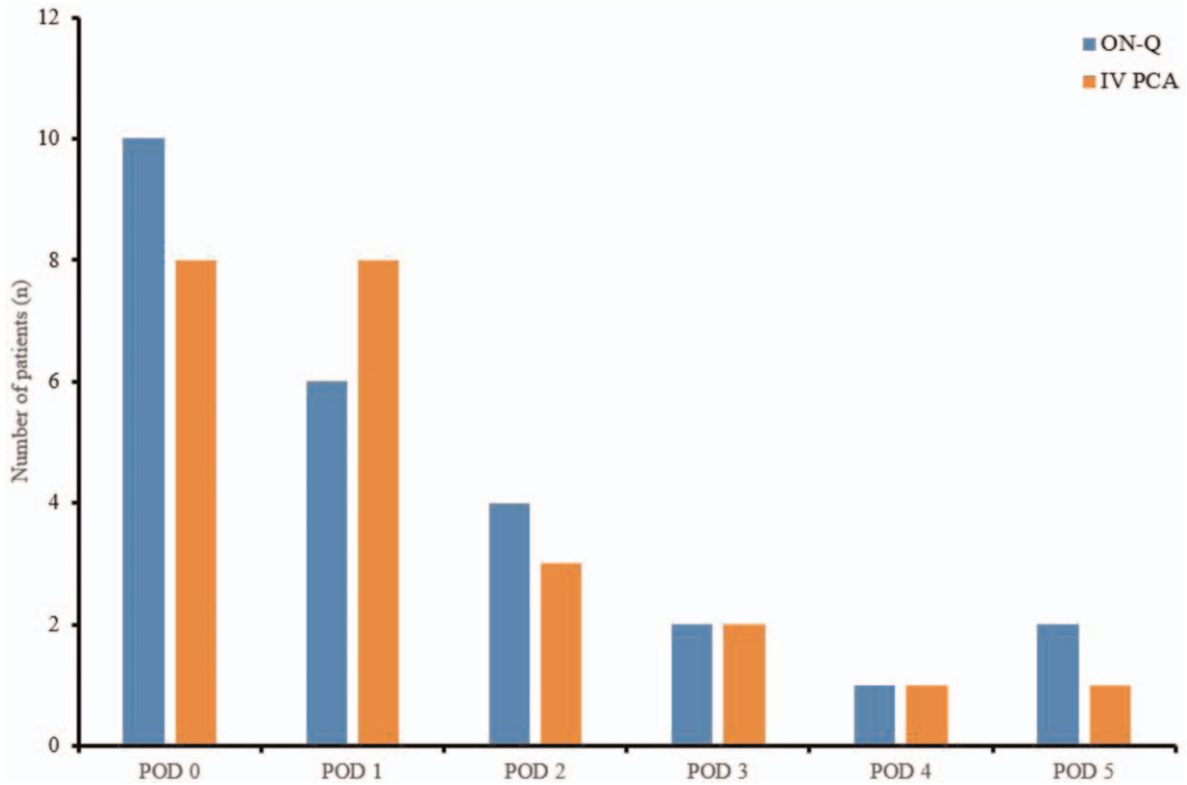


Figure 4. Rescue analgesia administration after surgery. No differences were found between the groups. IV PCA=intravenous patient controlled analgesia, POD= postoperative day.

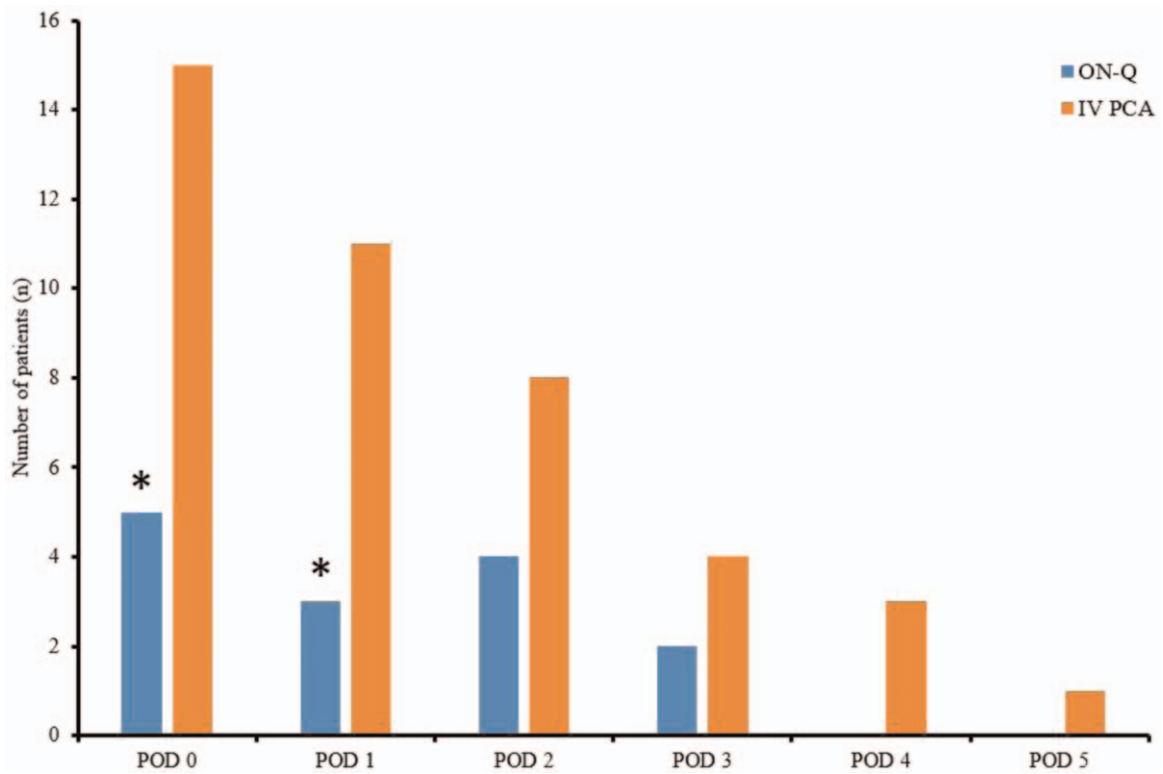


Figure 5. Incidence of postoperative nausea and vomiting. * $P < .05$ vs IV PCA group. ($P = .009$ on POD 0, $P = .019$ on POD 1). IV PCA=intravenous patient controlled analgesia, POD=postoperative day.

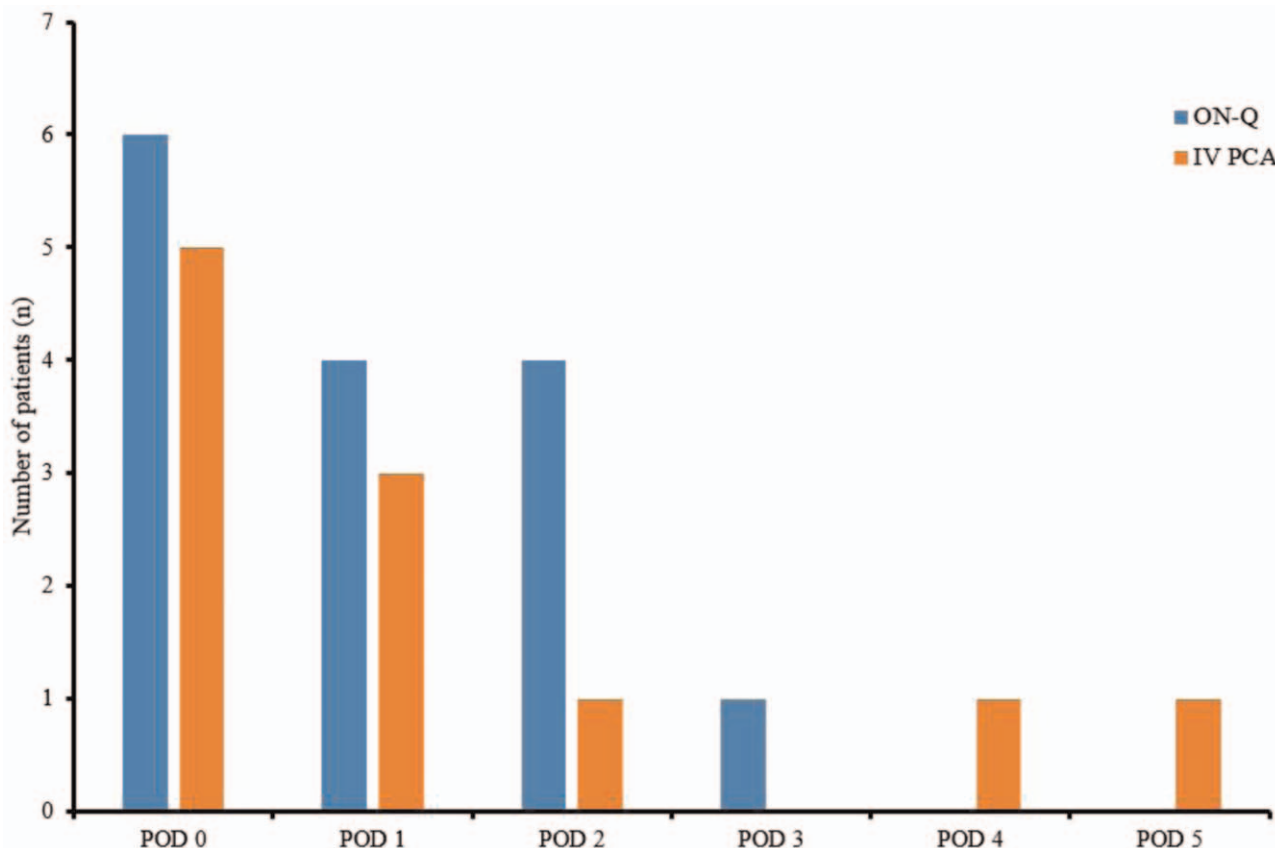


Figure 6. Incidence of sleep disturbance. No differences were found between the groups. IV PCA=intravenous patient controlled analgesia, POD=postoperative day.

postoperative analgesia. Moreover, some surgical characteristics of breast reconstruction are sensitive to the side effects of using opioids. Mastectomy with immediate autologous breast reconstruction involves the whole trunk from the anterior chest to the back, and immediate autologous breast reconstruction with LD flap showed more severe postoperative pain compared with mastectomy alone or mastectomy with other types of breast reconstruction surgery.^[9] Mastectomy with immediate autologous breast reconstruction using LD flap makes patients experience chest tightness because the surrounding tissues are pulled to achieve closure, and this tightness in the surgical site is perceived as pain. This muscle tightness also leads to the inhibition of full inspiration, cough, and ambulation. In addition, when the axillary lymph node is dissected, the intercostobrachial

nerve is damaged in most patients.^[10] These peripheral nerve injuries may result in structural changes as well as functional impairments. As a result of these features of immediate autologous breast reconstruction with LD flap, substantial doses of opioid may be required for acute postoperative analgesia; however, the opioid-related side effects can lead to delayed ambulation, cause atelectasis or pneumonia, or increase the duration of hospital stay.

Although the analgesic techniques using PCA are thought to be more effective and popular since the patients controls the pain themselves, patient characteristics should be considered when adjusting the PCA. Individual factors, such as age and sex, can affect the consumption of analgesics. Therefore, this technique may be associated with a higher incidence of analgesia-related side effects, such as PONV, pruritus, or respiratory depression. In particular, IV PCA can be influenced by the patient’s IV condition

Table 3
Satisfaction score of postoperative analgesic treatment.

	ON-Q (n=32)	IV PCA (n=33)	P
Willing to reuse of device	30 (93.8)	26 (78.8)	.149
Satisfaction to Analgesic treatment			.193
Very poor	0 (0)	0 (0)	
Poor	1 (3.1)	4 (12.1)	
Satisfactory	4 (12.5)	5 (15.2)	
Good	17 (53.1)	16 (48.5)	
Excellent	10 (31.3)	8 (24.2)	

Values are presented as number (%).
IV PCA=intravenous patient controlled analgesia.

Table 4
Postoperative complications.

Complications	ON-Q (n=32)	IV PCA1 (n=33)	P
Surgical wound			.184
Necrotic change	7 (21.9)	4 (12.1)	
Seroma	5 (15.6)	4 (12.1)	
Hematoma	1 (3.1)	0	
Analgesic method related	0	0	>.99

Values are presented as number (%).
IV PCA=intravenous patient controlled analgesia.

or fluid management, and in these cases, there are sufficient risks of excessive or deficient administration of analgesic drugs despite the PCA setting.^[11,12] With respect to accidentally inadequate analgesia, advanced analgesic nerve blocks, such as epidural or peripheral nerve block, also have the risk of late analgesic failure due to inaccurate catheter placement and catheter migration. However, continuous wound infusion has the advantage of simple insertion into the surgical site without specialized technique, and its management after insertion is as simple as wound dressing. Therefore, continuous wound infusion enables consistent analgesia.^[13]

Furthermore, breast cancer patients generally experience loss of femininity and great anxiety over the cancer diagnosis itself, which leads to a state of vulnerability regarding surgical pain.^[14–16] In a study on the relationship between psychological variables and PCA use, conventional opioid-based IV PCA was used, but patients who were preoperatively more anxious or depressed required a greater frequency of rescue analgesics.^[17] Although opioids have no ceiling effect on postoperative analgesia, the dose must be limited because opioid-related adverse events can unintentionally lead to delayed recovery after surgery or to increased mortality. Furthermore, tolerance and dependence can be induced in patients who have a history of opioid use, and the incidence of these side effects tends to reduce acute postoperative analgesic satisfaction in patients. Chronic postsurgical pain has been reported in 25% to 50% of patients who undergo mastectomy with breast reconstruction.^[18] Chronic surgical pain may occur in cases when acute postoperative pain cannot be fully controlled or when a strong opioid is required in the acute postoperative period. Chronic surgical pain is also associated with poor quality of life. Therefore, having diverse strategies for perioperative analgesic method is important to patients who have breast cancer surgery.^[19,20]

In various surgeries, continuous infiltration of LA into the surgical site is presented as a novel method to sparing opioids, and this analgesic method shows failure rates as low as 1%.^[21] Unlike a conventional neuraxial analgesic method administered by an anesthesiologist, continuous wound infusion is minimally invasive and the surgeon can easily insert the infusion catheter before wound closure.^[3,4] Administration of LA into the surgical wound can directly inhibit the transmission of pain from the nociceptive afferents, and it can inhibit a local inflammatory response.^[3,6] Using continuous wound infusion with LA, acute postoperative pain control has been proven to be effective in mastectomy with immediate autologous breast reconstruction.^[22] Since the mechanism of continuous wound infusion is sufficient LA delivery to the somatosensory nerve fibers in the surgical site, the efficacy of this analgesic modality may affect the location of catheter placement. Considering the effect of gravity depending on the patient's position, LA infusion catheters should be placed directly over the nerve or surgical area to enable it to spread throughout the entire wound. Furthermore, applying it on a relatively small range of wounds would be more effective. If the coverage of the surgical wound to be infused is too wide, LA can be localized owing to tissue adhesions, preventing effective analgesia. Another point to consider is the drain catheter of the wound; infusion catheters must be installed properly so that infused LA is not drained immediately through the drain catheter.^[21,23]

To date, most research on breast reconstruction has presented the efficacy of continuous wound infusion as a supplementary method, and there are some limitations regarding the assessment

of its analgesic efficacy as an alternative to opioid-based IV PCA. In this study, the patients who only used continuous wound infusion with 0.5% ropivacaine showed an equivalent level of analgesia after surgery when compared with those using conventional fentanyl-based IV PCA. The difference in rescue analgesic requirements was not significantly different on the day of surgery (31.3% of the ON-Q group vs 24.2% of the IV PCA group). Although no significant differences were observed in the number of patients who needed rescue analgesics during the observational period, the incidence of PONV in the ON-Q group was significantly lower at POD 0 and 1. Although it was not statistically significant, the number of patients complaining of PONV was also lower in the ON-Q group until POD 5. The patients who used continuous wound infusion with LA had fewer requirements for rescue analgesics than did patients with IV PCA, and this opioid-sparing effect attenuated PONV in the acute postoperative period.

However, in terms of surgical outcomes, complications related to wound healing must be considered with respect to breast reconstruction. Thus far, no study has evaluated the influence of continuous wound infusion on wound healing. In the present study, we were able to identify the effect on surgical wounds through outpatient follow-up for 1 year after surgery.

First, concerns exist as to whether the injected LA will directly affect the surgical wound. Depending on the patient's posture or the position of the inserted catheters, the drain volume might increase and develop seroma. Seroma is one of the most common complications in autologous breast reconstruction, and it makes wound healing difficult. Moreover, concerns remain that the infused LA might flow directly into the Jackson–Pratt drain, and as such, have a reduced analgesic effect. If the volume of drainage from the wound increased due to the ON-Q pain pump, the Jackson–Pratt drains would have been placed for a longer duration. Although the author could not find the exact drain volume from the patients' records, the time until drain removal was not significantly different between the groups.

Second, wound healing may be interrupted because of infection through the LA infusion catheter. In addition, necrotic change caused by inflammation or hematoma from an irritated ON-Q catheter was an issue of concern. None of the patients developed infection-related complications postoperatively, and the duration of hospital stay was also comparable without surgical wound-related complications. The ON-Q catheter has a filter to reduce the chance of infection. Furthermore, some studies have shown that ropivacaine has antimicrobial qualities at a concentration of 0.5%, and LA can inhibit a local inflammatory response.^[3,6,24,25]

Third, the changes in blood flow to the flap may be considered according to the concentration of LA that is infused. Because LA has biphasic effects on blood flow to the flap through the vascular smooth muscle, vasoconstriction can occur at low concentrations, and vasodilation can occur at clinical concentrations. Differences in the degree of vasodilation depend on the type of drugs used. Studies investigated which concentrations of ropivacaine maintain tissue perfusion showed a biphasic vascular action on isolated human arteries.^[26] In the biphasic curve of vascular effect, the vasoconstriction effects of ropivacaine increased as its concentration increased from 0.1% to 0.75%, and intradermal injection of 1% ropivacaine provoked vasodilation in healthy volunteers.^[27,28] The author used 0.5% ropivacaine, and the flap conditions were comparable in both groups. When observed for 1 year after the surgery, the healing

condition of the surgical wounds showed no significant differences between the groups.

Nevertheless, continuous wound infusion with LA runs the risk of accumulation or accidental intravenous administration at the surgical site. Therefore, caution is required when choosing the dose and type of LA. To reduce the systemic toxicity of continuous LA infusion, ropivacaine, rather than bupivacaine, can be used because a pain pump continuously infuses large amounts of LA. Ropivacaine has lower systemic toxicity due to its lower affinity for the central nervous system and heart than bupivacaine. In our study, patients received an infusion of 0.5% ropivacaine, and no LA-related side effects occurred. Although plasma levels of continuously infused ropivacaine were not measured in this study, previous studies have shown that ropivacaine plasma levels during a continuous 0.5% infusion are below the toxicity threshold.^[29,30]

This study has a limitation due to the retrospective review of medical records, and unavailability of more detailed information about chronic pain. Acute postoperative analgesic method-related side effects were expressed mainly as PONV in both groups. If other side effects such as respiratory depression, drowsy mentality, and dizziness had occurred, the events were described routinely. However, no numerical scoring assessment of side effects was recorded, and thus the difference was not compared. In addition, the authors were unable to evaluate the improvement in chest discomfort and respiratory function from the records for the patients who had a continuous LA wound infusion. More advanced studies are needed for chronic pain, and evaluation of respiratory function will make it possible to evaluate the effects of opioid reduction and LA itself even in cases with cancer recurrence.

In conclusion, continuous wound infusion with 0.5% ropivacaine had an equianalgesic effect to that of fentanyl-based IV PCA in patients who underwent mastectomy with immediate autologous breast reconstruction, without any specific complications on wound healing, even 1 year after surgery. Moreover, the patients' satisfaction with the postoperative analgesia was also comparable with that of opioid-based IV PCA. These findings suggest that continuous wound infusion with LA is a satisfactory substitute for opioid-based IV PCA in patients who undergo mastectomy with immediate autologous breast reconstruction.

Author contributions

Conceptualization: Jeong Woo Lee.

Data curation: Young Je Park, Jeong Woo Lee.

Formal analysis: Young Je Park, Jeong Woo Lee.

Investigation: Young Je Park, Jeong Woo Lee.

Methodology: Jeong Woo Lee.

Project administration: Jeong Woo Lee.

Resources: Young Je Park, Jeong Woo Lee.

Supervision: Jeong Woo Lee.

Validation: Jeong Eun Lee, Jeong Woo Lee.

Visualization: Jeong Eun Lee.

Writing – original draft: Jeong Eun Lee.

Writing – review & editing: Jeong Eun Lee, Jeong Woo Lee.

References

[1] Chevillon AL, Tchou J. Barriers to rehabilitation following surgery for primary breast cancer. *J Surg Oncol* 2007;95:409–18.

- [2] Man D, Plosker H. The pain-control infusion pump for postoperative pain control in plastic surgery. *Plast Reconstr Surg* 2002;109:2169–70.
- [3] White PF. The changing role of non-opioid analgesic techniques in the management of postoperative pain. *Anesth Analg* 2005;101(5 suppl):S5–22.
- [4] Shah A, Rowlands M, Krishnan N, et al. Thoracic intercostal nerve blocks reduce opioid consumption and length of stay in patients undergoing implant-based breast reconstruction. *Plast Reconstr Surg* 2015;136:584e–91e.
- [5] Tan KJ, Farrow H. Improving postoperative analgesia for transverse rectus abdominis myocutaneous flap breast reconstruction; the use of a local anaesthetic infusion catheter. *J Plast Reconstr Aesthet Surg* 2009;62:206–10.
- [6] Turan Z, Sandelin K. Local infiltration of anaesthesia with subpectoral indwelling catheters after immediate breast reconstruction with implants: a pilot study. *Scand J Plast Reconstr Surg Hand Surg* 2006;40:136–9.
- [7] Dhanapal B, Sistla SC, Badhe AS, et al. Effectiveness of continuous wound infusion of local anesthetics after abdominal surgeries. *J Surg Res* 2017;212:94–100.
- [8] Lee SH, Gwak MS, Choi SJ, et al. Prospective, randomized study of ropivacaine wound infusion versus intrathecal morphine with intravenous fentanyl for analgesia in living donors for liver transplantation. *Liver Transpl* 2013;19:1036–45.
- [9] Kulkarni AR, Pusic AL, Hamill JB, et al. Factors associated with acute postoperative pain following breast reconstruction. *JPRAS Open* 2017;11:1–13.
- [10] Karydas I, Fentiman IS, Habib F, et al. Sensory changes after treatment of operable breast cancer. *Breast Cancer Res Treat* 1986;8:55–9.
- [11] Grass JA. Patient-controlled analgesia. *Anesth Analg* 2005;101(5 suppl):S44–61.
- [12] Gambling DR, Yu P, Cole C, et al. A comparative study of patient-controlled epidural analgesia (PCEA) and continuous infusion epidural analgesia (CIEA) during labour. *Can J Anaesth* 1988;35(3 pt 1):249–54.
- [13] Ilfeld BM, Morey TE, Enneking FK. New portable infusion pumps: real advantages or just more of the same in a different package? *Reg Anesth Pain Med* 2004;29:371–6.
- [14] Albornoz CR, Bach PB, Mehrara BJ, et al. A paradigm shift in U.S. Breast reconstruction: increasing implant rates. *Plast Reconstr Surg* 2013;131:15–23.
- [15] Caffo O, Amichetti M, Ferro A, et al. Pain and quality of life after surgery for breast cancer. *Breast Cancer Res Treat* 2003;80:39–48.
- [16] Alderman AK, Wilkins EG, Lowery JC, et al. Determinants of patient satisfaction in postmastectomy breast reconstruction. *Plast Reconstr Surg* 2000;106:769–76.
- [17] Ozalp G, Sarioglu R, Tuncel G, et al. Preoperative emotional states in patients with breast cancer and postoperative pain. *Acta Anaesthesiol Scand* 2003;47:26–9.
- [18] Tsoi B, Ziolkowski NI, Thoma A, et al. Systematic review on the patient-reported outcomes of tissue-expander/implant vs autologous abdominal tissue breast reconstruction in postmastectomy breast cancer patients. *J Am Coll Surg* 2014;218:1038–48.
- [19] Roth RS, Qi J, Hamill JB, et al. Is chronic postsurgical pain surgery-induced? A study of persistent postoperative pain following breast reconstruction. *Breast* 2018;37:119–25.
- [20] Steyaert A, Forget P, Dubois V, et al. Does the perioperative analgesic/anaesthetic regimen influence the prevalence of long-term chronic pain after mastectomy? *J Clin Anesth* 2016;33:20–5.
- [21] Liu SS, Richman JM, Thirlby RC, et al. Efficacy of continuous wound catheters delivering local anesthetic for postoperative analgesia: a quantitative and qualitative systematic review of randomized controlled trials. *J Am Coll Surg* 2006;203:914–32.
- [22] Baroody M, Tameo MN, Dabb RW. Efficacy of the pain pump catheter in immediate autologous breast reconstruction. *Plast Reconstr Surg* 2004;114:895–8. discussion 899–900.
- [23] Losken A, Parris JJ, Douglas TD, et al. Use of the infusion pain pump following transverse rectus abdominis muscle flap breast reconstruction. *Ann Plast Surg* 2005;54:479–82.
- [24] Lütftiye P, Tekin K, Yasemin Z, et al. Antibacterial effect of bupivacaine and ropivacaine; effect of adjuvant drugs. *The Pain Clinic* 2005;17:73–80. doi:10.1163/1568569053421762.
- [25] Johnson SM, Saint John BE, Dine AP. Local anesthetics as antimicrobial agents: a review. *Surg Infect (Larchmt)* 2008;9:205–13.
- [26] Gherardini G, Samuelson U, Jernbeck J, et al. Comparison of vascular effects of ropivacaine and lidocaine on isolated rings of human arteries. *Acta Anaesthesiol Scand* 1995;39:765–8.

- [27] Cederholm I, Evers H, Löfström JB. Skin blood flow after intradermal injection of ropivacaine in various concentrations with and without epinephrine evaluated by laser Doppler flowmetry. *Reg Anesth* 1992;17:322–8.
- [28] Moffitt DL, De Berker DA, Kennedy CT, et al. Assessment of ropivacaine as a local anesthetic for skin infiltration in skin surgery. *Dermatol Surg* 2001;27:437–40.
- [29] Lee SH, Sim WS, Kim GE, et al. Randomized trial of subfascial infusion of ropivacaine for early recovery in laparoscopic colorectal cancer surgery. *Korean J Anesthesiol* 2016;69:604–13.
- [30] Forastiere E, Sofra M, Giannarelli D, et al. Effectiveness of continuous wound infusion of 0.5% ropivacaine by On-Q pain relief system for postoperative pain management after open nephrectomy. *Br J Anaesth* 2008;101:841–7.