

## CASE REPORT

# Lead failure in transvenous implantable cardioverter defibrillator: a new opportunity for an effective management

Carlo Pignalberi  & Furio Colivicchi

Cardiology Division, "San Filippo Neri" Hospital, Rome, Italy

### Correspondence

Carlo Pignalberi, Cardiology Department, San Filippo Neri Hospital, Via Giovanni Martinotti, 20, Rome 00135, Italy.  
Tel: +39-06-33062294;  
Fax: +39-06-0633062489;  
E-mail: c.pignalberi@libero.it

### Funding Information

No sources of funding were declared for this study.

Received: 12 November 2017; Revised: 31 January 2018; Accepted: 6 March 2018

*Clinical Case Reports* 2018; 6(9): 1668–1670

doi: 10.1002/ccr3.1533

### Key Clinical Message

In case of transvenous defibrillator lead failure, a subcutaneous defibrillator may be implanted and the lead may be abandoned in order to avoid particular risk situations. For patients who require pacing and with an operational atrial lead, the transvenous ICD may be also maintained to ensure antibradycardia support.

### Keywords

Lead failure, subclavian obstruction, subcutaneous defibrillator, transvenous defibrillator.

## Introduction

The subcutaneous defibrillator (S-ICD) is an entirely subcutaneous system that does not require vascular access and that was developed to overcome the well-known complications associated with transvenous defibrillators (T-ICD) [1, 2]. The S-ICD does not provide pacing but may be implanted in association with a permanent pacemaker, after verification of compatibility (i.e., adequacy of S-ICD detection during pacing) [3, 4]. To our knowledge, it has never been described the implantation of an S-ICD in a patient requiring pacing and with multiple abandoned transvenous leads.

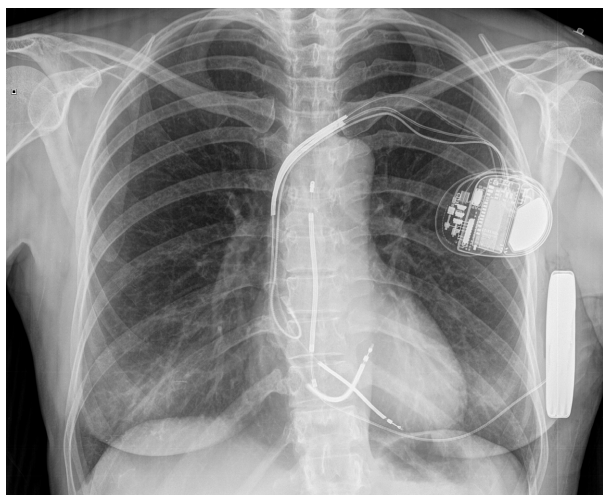
## Case Report

A 47-year-old female patient with idiopathic ventricular fibrillation underwent implantation of a single-chamber T-ICD in 2005. After 8 years, the patient was admitted at our hospital because of an ICD alarm. At follow-up, the stored EGM revealed more than 2000 nonsustained ventricular tachycardia episodes, several short nonphysiologic

V-V intervals were recorded, and the lead impedance was higher than 3000 ohms. We decided to add a second ICD lead and leave the fractured one in situ. The patient developed need for antibradycardia support due to the introduction of beta-blocker therapy, thus an atrial pacing lead was also implanted and connected to a dual-chamber ICD.

Three years later, during a routine follow-up, we observed new nonsustained ventricular tachycardia episodes, lead impedance higher than 3000 ohms, and a second diagnosis of right ventricular lead fracture was made. Therefore, the decision was made to implant an S-ICD leaving the fractured ventricular leads in situ and using the T-ICD for delivering atrial pacing. Before S-ICD implantation, the adequacy of S-ICD sensing was verified using the dedicated ECG morphology tool during spontaneous and paced rhythm in multiple conditions (pacing amplitude and rate). The screening process confirmed S-ICD eligibility, identifying two suitable sensing vectors (primary and secondary). The S-ICD (Emblem A219, Boston Scientific, Natick, MA) implantation was conventionally performed with the lead vertically positioned in

the subcutaneous tissue of the chest, 2 cm to the left of the sternal midline (Fig. 1). The primary sensing vector was found adequate by S-ICD, and it was permanently programmed with a 1x gain. The defibrillation test was performed, and the induced ventricular fibrillation was successfully converted by S-ICD with a 65 J biphasic shock in standard polarity (Fig. 2). The shock impedance was 53 ohms. All T-ICD antitachycardia therapies were disabled, and the device was finally programmed in AAI



**Figure 1.** The final Rx image.

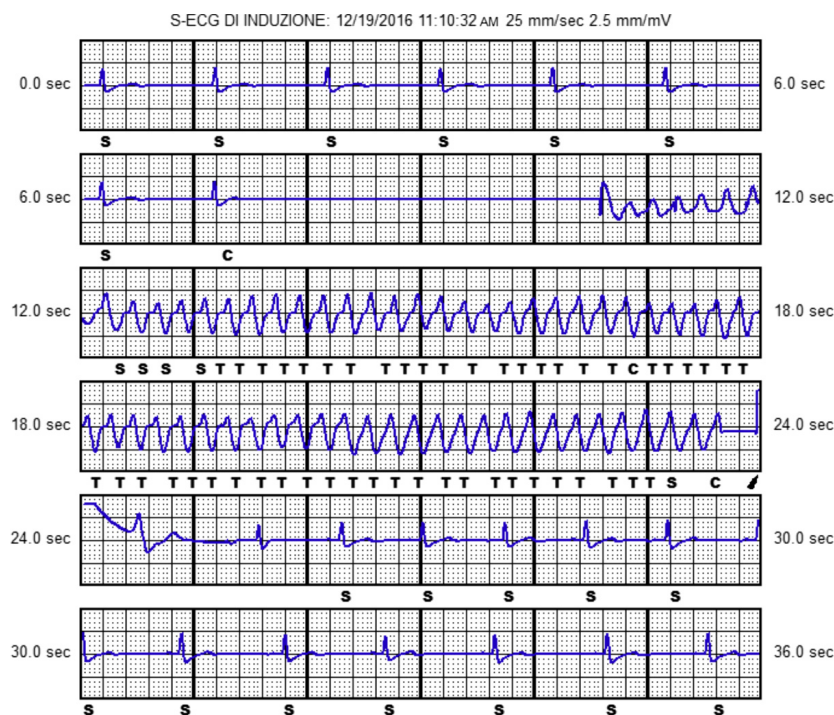
pacing mode with lower rate limit of 60 bpm. The post-operative course was uneventful, and the patient was discharged 48 h after the procedure.

## Discussion

The incidence of ICD lead malfunctions is recognized to be around 40% at 10 years [1]. Malfunctions seem to occur more frequently in young patients with morphologically normal heart [2]. The S-ICD was designed to prevent long-term transvenous ICD lead complications, as it relies on a totally subcutaneous lead. The system was shown to be safe and effective [3, 4].

In the present report, we describe a case of transvenous ICD system malfunction that was managed by implanting an S-ICD. The S-ICD resulted effective in terminating induced ventricular fibrillation, regardless of the presence of abandoned leads, and the required antibradycardia support was ensured by maintaining the transvenous ICD together with the atrial lead.

In these situations, international guidelines suggest lead removal in patients with bilateral subclavian vein or superior vena cava occlusion precluding implantation of a new lead or in patients with leads that interfere with the operation of implanted cardiac devices [5]. Indeed, in this patient, we decided to simply add a second transvenous lead after the failure of the first lead. While, after the second event, the only way to restore the



**Figure 2.** The defibrillation test.

T-ICD functioning was to attempt the implantation of an additional transvenous ICD lead using the contralateral side, followed by the tunneling of the atrial lead. In fact, the transvenous extraction was excluded because of the risks associated with removal of leads in place by more than 10 years and the need to preserve the functioning of the atrial lead. In case of explantation of the two malfunctioning ventricular catheters, in fact, there would certainly also be a damage to the atrial lead that would then have required the reimplantation of two catheters. This reimplantation, then, would have been opportune to have been carried out in a contralateral way, sacrificing the second access route, for two reasons: (1) such a demanding explanting operation would have made the ipsilateral reimplanting technically very difficult; (2) the fracture of two leads in a relatively short period of time can probably be explained by a particularly unfavorable anatomy, which causes great stress to any catheter, thus discouraging the placement of another one in the same place. In the event that in the future the patient needs ventricular pacing, the right subclavian access route may be used, with only one ventricular pacing and sensing catheter, with lower risk of fracture, which can be tunneled to the left. The same thing can be done in case of atrial lead malfunction.

Although the S-ICD does not provide pacing, the combined implantation with a pacing system is possible and its feasibility has been already described [6]. The only recommendations are to consider bipolar pacing and to preliminarily verify the adequacy of S-ICD sensing in all possible pacing conditions. In the present case, we identified two suitable sensing vectors and we confirmed the adequacy of arrhythmia detection at the time of the defibrillation test. Regardless of the presence of multiple leads in the heart, the S-ICD finally resulted effective in terminating induced ventricular fibrillation, confirming, and extending the conclusions of previous reports that described the efficacy of S-ICD in the presence of intracardiac leads [7].

## Conclusion

The present case showed the efficacy of an hybrid approach that included S-ICD implantation and T-ICD maintenance for the management of a complex case of transvenous lead failure.

## Acknowledgments

L. Spadoni for support in correcting the manuscript.

## Conflict of Interest

None declared.

## Authorship

CP: performed the implantation of both transvenous and subcutaneous defibrillator catheters and also took care of the drafting of the article. FC: carried out the design of this article.

## References

1. Swerdlow, C. D., G. Kalahasty, and K. A. Ellenbogen. 2016. Implantable cardiac defibrillator lead failure and management. *J. Am. Coll. Cardiol.* 67:1358–1368.
2. Pettit, S. J., A. McLean, I. Colquhoun, D. Connelly, and K. McLeod. 2013. Clinical experience of subcutaneous and transvenous implantable cardioverter defibrillators in children and teenagers. *Pacing Clin. Electrophysiol.* 36:1532–1538.
3. Sponder, M., C. Khazen, W. Dichtl, L. Fiedler, D. Mörtl, A. Teubl, et al. 2017. Specific indications and clinical outcome in patients with subcutaneous ICD - A nationwide multicenter registry. *Eur. J. Intern. Med.* 48:64–68.
4. Boersma, L., C. Barr, R. Knops, D. Theuns, L. Eckardt, P. Neuzil, et al. 2017. EFFORTLESS investigator group. implant and midterm outcomes of the subcutaneous implantable cardioverter-defibrillator registry: the EFFORTLESS study. *J. Am. Coll. Cardiol.* 70:830–841.
5. Santini, M., S. A. Di Fusco, L. Santini, B. Magris, C. Pignalberi, S. Aquilani, et al. 2016. Prevalence and predictor factors of severe venous obstruction after cardiovascular electronic device implantation. *Europace* 18:1220–1226.
6. Mondésert, B., M. Dubuc, P. Khairy, P. G. Guerra, G. Gosselin, and B. Thibault. 2015. Combination of a leadless pacemaker and subcutaneous defibrillator: first in-human report. *HeartRhythm Case Rep.* 1:469–471.
7. Erath, J. W., A. S. Sirat, M. Vamos, and S. H. Hohnloser. 2016. Epicardial CRT-P- and S-ICD implantation in a young patient with persistent left superior vena cava. *Herzschrittmacherther Elektrophysiol.* 27:396–398.