

HIV-associated lymphoma presenting with painful ophthalmoplegia

Sir,

Infection by human immunodeficiency virus (HIV) leads to a wide range of clinical pictures as it may involve almost all systems, including the central nervous system.^[1,2] In patients with acquired immune deficiency syndrome (AIDS) there is a 3%-8% incidence of neuro-ophthalmological disorders.^[1-3] We present a rare case of HIV-associated lymphoma, which presented with painful ophthalmoplegia.

A previously healthy 26-year-old female presented with a 2-week history of right retro-orbital pain, ptosis, and diplopia. The neurological examination revealed a nearly total ophthalmoplegia of the right eye [Figure 1a and b] and right V1 sensory loss. A gadolinium-enhanced magnetic resonance image of the brain showed a homogeneously enhanced mass in the right cavernous sinus [Figure 1c, arrow]. The results of routine laboratory tests were within normal limits. A presumptive diagnosis of Tolosa-Hunt syndrome was made, and prednisolone treatment was started. Transient improvement in the symptoms was obtained, however, she presented with dyspnea as well as a relapse of the eye symptoms 2 months later. Repeated laboratory tests revealed positivity for HIV antibodies. Bone marrow aspirate examination revealed findings compatible with Burkitt's lymphoma. She was treated with cyclophosphamide, vincristine, dexamethasone, and adriamycin, however, she died 8 months later.

Ophthalmoplegia with retro-orbital pain has been rarely reported as the initial manifestation of AIDS.^[4] This case suggests that painful ophthalmoplegia should be considered as one of the initial presentations of HIV-associated lymphoma.^[4] We believe that a knowledge of this clinical course can allow early diagnosis of HIV.

Financial support and sponsorship

Nil.

Conflicts of interest

There are no conflicts of interest.

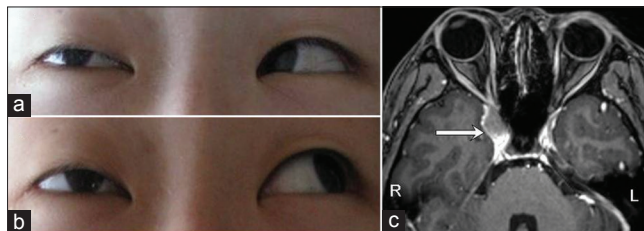


Figure 1: Ophthalmoplegia of the right eye (a) rightward gaze; (b) leftward gaze, (c) Gadolinium-enhanced T1-weighted magnetic resonance image showing an enhanced mass in the right cavernous sinus

Satoru Takeuchi, Shotaro Hagiwara¹,
Hiroshi Nawashiro, Katsuji Shima

Department of Neurosurgery, National Defense Medical College, Saitama, ¹Department of Internal Medicine, National Center for Global Health and Medicine, Tokyo, Japan

Address for correspondence:

Dr. Satoru Takeuchi,
E-mail: s.takeuchi@room.ocn.ne.jp

References

- Keane JR. Neuro-ophthalmologic signs of AIDS: 50 patients. *Neurology* 1991;41:841-5.
- Mwanza JC, Nyamabo LK, Tylleskär T, Plant GT. Neuro-ophthalmological disorders in HIV infected subjects with neurological manifestations. *Br J Ophthalmol* 2004;88:1455-9.
- Dhillon WS, Shah T. Images in clinical medicine. Diplopia in a patient with HIV infection. *N Engl J Med* 2010;362:e52.
- Levy J, Kratz A, Lifshitz T. Burkitt's lymphoma presenting as oculomotor palsy in an hiv-positive patient. *Eur J Ophthalmol* 2006;16:186-9.

This is an open access article distributed under the terms of the Creative Commons Attribution-NonCommercial-ShareAlike 3.0 License, which allows others to remix, tweak, and build upon the work non-commercially, as long as the author is credited and the new creations are licensed under the identical terms.

Access this article online	
Quick Response Code:	Website: www.asianjns.org
	DOI: 10.4103/1793-5482.145108

How to cite this article: Takeuchi S, Hagiwara S, Nawashiro H, Shima K. HIV-associated lymphoma presenting with painful ophthalmoplegia. *Asian J Neurosurg* 2017;12:341.