

Infections in the Immunocompromised

Andrew Cant and Theresa Cole

1 Introduction

Infections in the immunocompromised differ significantly from those in the immunocompetent. They can be more serious, more often life threatening, more difficult to diagnose and are caused by more unusual organisms. Children can be immunocompromised for a variety of reasons and the numbers, worldwide, are growing.

2 Types of Immunodeficiency and Infection

Globally, the most common causes for immunocompromise are acquired. Severe malnutrition and the spread of HIV continue to be major causes of immunocompromise in the developing world. The development of more intensive chemotherapy and immunosuppressive drugs for malignancy and inflammatory diseases continues and the number of patients undergoing solid organ transplant (SOT) or haemopoietic stem cell transplant (HSCT) is also rising. Primary immunodeficiencies (PIDs) are also being increasingly recognized. Defects in humoral immunity make up the largest group of PIDs, at around 50%, with 20–30% being combined humoral and cellular deficiencies.

Different types of immunodeficiency or immunosuppression affect different aspects of the immune system and so predispose to different types of infection: bacterial, viral, fungal or protozoal. Understanding which part of the immune system is compromised helps identify the most likely infecting agent.

T lymphocyte defects predispose to infections such as life-threatening cytomegalovirus (CMV) pneumonitis or disseminated Epstein Barr virus (EBV) infection. These defects also present a significant risk of serious infection with

A. Cant (✉)

Paediatric Immunology & Infectious Diseases, Newcastle General Hospital, Westgate Road, Newcastle upon Tyne NE4 6BE, UK
e-mail: andrew.cant@nuth.nhs.uk

cryptosporidium and *Aspergillus* species. B lymphocyte defects can result in infections by bacteria such as *Streptococcus pneumoniae*, *Haemophilus influenzae* and *Staphylococcus aureus*, as well as echo virus and protozoa such as *Giardia*, whereas phagocytic defects will result in infections by *Staphylococcus*, *Pseudomonas* and *Aspergillus* species.

When considering infections in those undergoing HSCT, it is also important to note that there is a recognized sequence of risk for different infections at different times after HSCT, which equates with different aspects of the immune system compromise at these times (Fig. 1). Within the first 30 days, when the patient is neutropenic, there is a significant risk of infection by both Gram-negative and Gram-positive bacteria, along with herpes-simplex virus. Between 30 and 90 days after transplant, when T-cell immunity is still limited, there is a rise in the numbers of fungal and CMV infections. Later infections are more commonly caused by varicella zoster virus (VZV) or *S. pneumoniae*.

Week:	1	2	3	4	5	6	7	8	9	10	11	12	13	14	15	16	17	18	19	20	...	52	104	
HSV	■	■	■																							
Gram +ve	■	■	■	■																						
Gram -ve	■	■	■	■																						
Candida	■	■	■	■																						
Aspergillus												■	■	■	■	■										
Resp. virus	■	■	■	■	■																					
CMV								■	■	■	■	■	■	■	■											
VZV													■	■	■	■	■	■	■	■	■	■	■	■	■	■
PCP				■	■	■	■	■	■	■	■	■	■	■	■	■	■	■	■	■	■	■	■	■	■	■

HSV: herpes simplex virus, Gram +ve: Gram positive bacteria, Gram -ve: Gram negative bacteria, CMV: cytomegalovirus, VZV: varicella zoster virus, PCP: *Pneumocystis jiroveci* pneumonia

Fig. 1 Diagrammatic representation of timing of infections after HSCT

Whatever the cause of the immunocompromise, possible infection requires a different approach to investigation and management from those in an immunocompetent child.

3 Site of Infection

Although an understanding of the type of immunocompromise is helpful to predict the likely organism, infection in the immunocompromised also needs to be considered by the system affected.

Infections can occur in any system of the body, but the respiratory system and gastrointestinal tract are especially vulnerable, as they have large surface areas and their barrier defences are, of necessity, compromised by the need to transport

oxygen and nutrients, respectively. Disseminated viral and fungal infections are another important risk, whilst central venous catheter (CVC) infections also constitute a frequent problem in the immunocompromised. Each of these will be discussed in turn.

4 Respiratory Tract

The respiratory tract can be exposed to a wide variety of different organisms. *Pneumocystis jiroveci* pneumonia (PCP), CMV and *Aspergillus* are particularly important and well recognized sources of infection in the immunocompromised host; however, other significant pathogens have more recently been identified. These include respiratory syncytial virus (RSV); influenza; parainfluenza; adenovirus; picornaviruses; measles; human metapneumovirus; cocavirus; Coronaviruses NL63, and HKU1 and polyomaviruses WU and K1.

Pneumonitis and bronchiolitis are the most common presentations of respiratory infection, but lobar pneumonia may also occur. A defective immune/inflammatory response means that patients may have few respiratory symptoms, so there should be a low threshold for investigation. In one study where broncho-alveolar lavage (BAL) was performed in 69 children with immunodeficiency pre-HSCT, pathogens were isolated in 26 of these, six of whom were asymptomatic. PCP and bacteria were the most commonly identified organisms, followed by parainfluenza virus, CMV, RSV, influenza B and human herpes virus-6 (HHV6) (Slatter et al., 2007).

Accurate diagnosis depends on collecting the right samples and using appropriate diagnostic techniques. These include throat swabs, nasopharyngeal aspirates (NPA), BAL fluid and even lung biopsy, as deemed appropriate. Samples must be sent to look specifically for bacteria, fungi and viruses. Some respiratory pathogens will not be isolated from the upper respiratory tract; for example, PCP will not be identified on NPA, whilst other organisms found on NPA may not be found in the lower respiratory tract. This highlights the importance of BAL as a diagnostic procedure. Lung biopsy may be particularly important in the diagnosis of fungal infection, especially when there is a negative BAL in patients with persistent signs, symptoms or chest x-ray changes.

Diagnosis may require culture of organisms (bacteria, mycobacteria or viruses), immunofluorescence (viruses), polymerase chain reaction (bacteria, viruses and fungi) or antigen testing (e.g. galactomannan for *Aspergillus*). Serological testing is often ineffective, as immunodeficient children may not mount an antibody response or may be receiving intravenous immunoglobulin (IVIG), which will make results impossible to interpret. It is important to know what tests are available in your local laboratory. Discussion with the local microbiologist or virologist is essential to ensure the right samples are sent for appropriate investigations, so as not to miss a serious infection.

High resolution computerized tomography (HRCT) of the chest is more sensitive than chest x-ray, aiming to classify a disease as interstitial, airway or involving airspace, which may aid diagnosis.

4.1 *Pneumocystis jiroveci* Pneumonia (PCP)

PCP has historically been associated with HIV but is also a significant cause of morbidity in other groups of immunocompromised patients, particularly those with haematological malignancies, brain tumours requiring prolonged courses of steroids, prolonged neutropaenia or lymphopaenia, and those undergoing HSCT. Therefore PCP prophylaxis is important, as recommended by a recent Cochrane review (Green et al., 2007). This treatment is generally in the form of cotrimoxazole given three times per week. In children that cannot tolerate cotrimoxazole, either dapsone or aerosolized pentamidine can be used.

P. jiroveci infection commonly presents with tachypnoea, non-productive cough and fever, but the severity can vary. There is usually a sub-acute diffuse pneumonitis and chest x-ray changes can be subtle. These often take the form of bilateral diffuse interstitial changes, although lobar, miliary or nodular changes can be seen. HRCT may show ground glass attenuation, consolidation, nodules, thickening of interlobular septa and thin walled cysts. Mortality ranges between 5 and 40%, if treated, but can reach nearly 100% if left untreated.

Identification of PCP can be difficult. Definitive diagnosis depends on identifying the organism in respiratory tract secretions or lung tissue, usually from tracheal secretions, bronchial secretions or from lung biopsy. More recently, PCR technology has been developed for identifying PCP from secretions. In a review of children diagnosed with severe combined immune deficiency (SCID) treated at a supra-regional center, 10 out of 50 were identified as having PCP. One was diagnosed on BAL prior to transfer to the supra-regional center, one was diagnosed on nasopharyngeal secretions and BAL, seven were diagnosed on BAL alone, and in one diagnosis was not made until lung biopsy was performed (Berrington et al., 2000).

Recommended first line PCP treatment is high dose cotrimoxazole. This can, however cause a number of adverse effects, for example, neutropenia, anaemia, renal dysfunction, rash, vomiting and diarrhea. Those that cannot tolerate cotrimoxazole or those that have not improved after 5–7 days of treatment should be changed to a different agent. Choices include pentamidine, atovaquone, clindamycin/primaquine or dapsone, but experience with these agents in children is limited.

Corticosteroids should be given as an adjunctive therapy in moderate and severe PCP. A number of studies have shown a reduction in acute respiratory failure, decreased need for ventilation and decreased mortality (Sleasman et al., 1993; Bye et al., 1994; McLaughlin et al., 1995). A recent Cochrane review supports the use of corticosteroids in HIV-infected patients with PCP, especially in those with substantial hypoxaemia (Briel et al., 2006).

4.2 Viruses

A wide variety of respiratory viruses will also cause significant morbidity and mortality in the immunocompromised. Measles is an important respiratory pathogen in the immunocompromised host and it must be remembered that the typical rash may not develop. Mortality can be high, especially amongst patients with leukaemia and those undergoing HSCT. A prospective multi-center review of patients undergoing HSCT found direct RSV-associated mortality to be 17.4%, and mortality directly attributable to influenza A to be 15.3% (Ljungman et al., 2001). Respiratory viruses often present with non-specific symptoms but progress to a significant lower respiratory tract infection. Chest x-ray will often show a pneumonitis picture with diffuse interstitial changes. HRCT may show peri-bronchial thickening and ground glass attenuation without consolidation in a lobular distribution. Diagnosis requires identification of the organism from respiratory secretions. This may be possible on nasopharyngeal secretions or throat swab but may require more invasive testing, such as bronchoscopy and BAL. Laboratory techniques include immunofluorescence, PCR and viral culture. Treatment is mainly supportive, but specific treatment options are evolving, making rapid and accurate diagnosis increasingly important. Appropriate isolation and infection-control measures are essential to prevent transmission between immunocompromised patients, as these viruses can be easily spread. One UK study in a HSCT unit identified 10 cases of RSV over one winter season, and eight of the nine RSV strains that could be tested by molecular methods were found to be identical (Taylor et al., 2001).

Specific treatments for RSV infection include ribavirin and RSV monoclonal antibody (palivizumab). Ribavirin can be given orally, intravenously or via inhalation; however, the aerosolized route has been used most frequently for RSV infection. Historically, pooled hyperimmune RSV immunoglobulin has been proposed as an additional treatment, but this has been superseded by the anti-RSV monoclonal antibody, palivizumab. Combinations of inhaled ribavirin and intravenous palivizumab have shown encouraging results. Palivizumab has been shown to be safe and well tolerated in patients undergoing HSCT, with a suggestion of better outcome (improved survival) when compared to ribavirin alone (Boeckh et al., 2001; Chavez-Bueno et al., 2007).

There are two groups of drugs available for the treatment of influenza – namely the adamantanes (effective against influenza A, e.g. rimantadine) and the neuraminidase inhibitors (effective against both influenza A & B, e.g. oseltamivir). In recent years, there has developed increasing resistance to adamantanes. The neuraminidase inhibitors have been shown to reduce the duration of illness by one day when given to an immunocompetent host within 48 h of onset of symptoms. Although there are few data on the benefit of treating influenza in an immunocompromised patient with a neuraminidase inhibitor, their use appears sensible and safe.

There is, thus far, no specific treatment available for rhinovirus, coronavirus or human metapneumovirus. Ribavirin has been proposed as a treatment for parainfluenza virus infection but evidence, so far, of benefit is disappointing. Although

there is little clinical data on the use of ribavirin for measles pneumonitis, it does have in vitro activity and therefore, due to the high level of mortality with this condition, should be considered.

A review of respiratory viral infection in children with primary immune deficiencies in a HSCT unit found 22 of 73 patients admitted for HSCT had respiratory viral infection. Of these, 11 had paramyxoviruses (RSV or parainfluenza I–IV), and were treated with aerosolized ribavirin and IVIG. Five of these patients also received nebulized immunoglobulin and corticosteroid. Three of these five survived, compared to two out of the six who did not receive nebulized treatment. It was concluded that the nebulized treatment was well tolerated and could be a useful adjunctive therapy (Crooks et al., 2000).

In children who have undergone HSCT, infection and inflammation can become inextricably interwoven to generate pneumonitis. In this case, in addition to the need for anti-infective agents, immunomodulation will be required through agents such as steroids, IVIG and anti-tumour necrosis factor monoclonal antibodies.

5 Gut

The gastrointestinal tract is also exposed to a wide variety of organisms and viruses which are of particular concern in the immunocompromised child, notably enteroviruses, adenovirus, rotavirus, caliciviruses, but also protozoa, mainly *Cryptosporidium* and *Giardia*. Presentation is most commonly with diarrhea and vomiting, which may protracted. *Cryptosporidium* can also be responsible for ascending cholangitis and liver disease. In some cases, identification of the causative organism can be difficult. Culture may be required to identify some viruses. PCR can be useful, for example, for adenovirus and is more sensitive than microscopy alone in detecting *Cryptosporidium*.

Prevention of transmission between immunocompromised patients is essential. There must be strict adherence to infection-control policies to prevent hospital wards from becoming sources of infection. One study looking at the extent of gastroenteric virus contamination in a pediatric-primary immunodeficiency ward and a general pediatric ward found viruses on 17 and 19% of environmental swabs, respectively. Interestingly, these were contaminating objects used by parents rather than staff – for example the parents' room television, the parents' toilet tap and the microwave used by parents on the pediatric-primary immunodeficiency ward (Gallimore et al., 2008). This highlights the importance of ensuring that parents and visitors, as well as staff, comply with hand washing and infection control measures.

5.1 Viruses

Rotavirus infection, which is usually relatively mild and self-limiting in the immunocompetent, can lead to persistent vomiting and diarrhea and, if untreated, severe malnutrition, in the immunocompromised. It can be identified in stool by

using enzyme immunoassay and may also be identified on electron microscopy. There is no specific treatment. Fluid and electrolyte management is important. Orally administered immunoglobulin has been used in some cases.

Caliciviruses, namely Noroviruses and Sapoviruses can also cause significant problems in the immunocompromised. Symptomatic infection and virus shedding can be prolonged; for example, one case report of a child undergoing HSCT for cartilage hair hypoplasia demonstrated Norovirus shedding for 156 days following transplant, during the period of immune reconstitution. The child was symptomatic throughout this time (Gallimore et al., 2004). Again, there is no specific treatment but meticulous management of fluids, electrolytes and nutritional support is essential, allowing time for immune reconstitution and consequent viral clearance.

Adenovirus will be discussed in more detail in the section on disseminated infection in the immunocompromised.

5.2 *Cryptosporidium*

Cryptosporidium species are oocyst-forming protozoa that cause watery diarrhea which can result in severe dehydration and even death, if not treated. Disease is normally confined to the gastrointestinal tract, but there is a risk of biliary tree, pulmonary or even disseminated disease in the immunocompromised. Infection may be diagnosed on identification of oocysts by microscopy. Enzyme immunoassays have also been used and PCR, too, can be helpful.

Treatment of *Cryptosporidium* infection can be difficult and a number of agents have been proposed, including nitazoxanide, paromomycin, rifabutin and the macrolides. Evidence is limited but a recent review has indicated that nitazoxanide may reduce parasite load and therefore be useful (Abubakar et al., 2007). In the authors' experience, azithromycin and nitazoxanide are safer options in post-HSCT patients, as paromomycin has been associated with significant hearing loss, particularly when given with ciclosporin. Supportive care remains essential. In those with HIV, anti-retroviral therapy, with its associated improvement in CD4 count, can result in improvement in the *Cryptosporidium* infection.

5.3 *Giardia*

Giardia intestinalis is a flagellate protozoan that exists in trophozoite or cyst forms. The cysts are the infective form. Children with humoral immunodeficiencies are particularly at risk of chronic symptomatic infection, with foul-smelling stool, abdominal distension and anorexia. Cysts may be identified on stool microscopy or by using immunofluorescent antibody testing. Treatment is with metronidazole, tinidazole or nitazoxanide. It may be necessary to use combination therapy in the immunocompromised if they have failed to respond to single-agent treatment.

6 Disseminated Infection

Disseminated viral infection in the immunocompromised is of particular concern. The most significant culprits are adenovirus and members of the human herpes virus: CMV, EBV, HHV6, HSV and VZV. These can affect the lungs, gastrointestinal tract and brain, resulting in a variety of symptoms. Reactivation of latent herpes viral infection is more common than primary infection after SOT or HSCT. Investigation using PCR techniques allows early diagnosis and quantification of viral load, and is now possible for adenovirus, CMV, EBV and HHV6. Prophylaxis to prevent CMV and HSV reactivation is used for children undergoing HSCT and many SOTs. Surveillance in high-risk patients enables pre-emptive treatment to be given before damaging disease occurs. Treatment will depend on the causative virus.

6.1 Adenovirus

Adenovirus is usually responsible for relatively minor upper respiratory tract or gastrointestinal infection but can result in life-threatening pneumonia, meningitis, encephalitis and disseminated disease in the immunocompromised. Those most at risk are patients who receive allogeneic bone marrow transplant, those with active graft versus host disease and those who receive total body irradiation. There are a number of different species of adenovirus, and these are divided into serotypes, some of which are primarily associated with the respiratory tract, while others have a predilection for the gastrointestinal tract. Young children are particularly vulnerable, as they often carry adenovirus in their gastrointestinal tract, predisposing them to reactivation and dissemination when they become immunocompromised. In view of this, screening can be important in the immunocompromised and adenovirus is usually identified in urine, stool, or sometimes respiratory secretions prior to being identified in blood. A study of 132 patients undergoing HSCT were screened for adenovirus in stool, urine, on throat swab and in peripheral blood during the post transplant period. 27% had a positive adenoviral PCR on at least one screening test, but this was not associated with clinical signs unless it was detected in peripheral blood and, even then, there was a median delay of 3 weeks from first detection of adenovirus until the patient demonstrated clinical signs. In one study, mortality was as high as 82% in those with adenovirus detected on peripheral blood. This highlights the importance of early recognition and consideration of pre-emptive use of antivirals (Lion et al., 2003).

Successful treatment of adenovirus infection has so far been limited. The most widely used agents are cidofovir or ribavirin, which may be given together with IVIG. Although cidofovir has potent nephrotoxic effects, these can be greatly reduced by the concurrent use of intravenous hyperhydration and probenecid. Cidofovir has been shown to be more effective in adenovirus and is now considered the best first-line treatment. Data on the clinical effectiveness of ribavirin in adenoviral infections are more conflicting. In vitro data suggest that ribavirin

alone has activity against subgenus C serotypes. In a post-HSCT patient with adenoviral infection, immune suppression should be reduced as much as possible, as T-cell immune reconstitution is very important for viral elimination.

6.2 Cytomegalovirus

CMV infection is often asymptomatic in the immunocompetent; however, in the immunocompromised it can lead to pneumonia, colitis and retinitis. CMV persists in a latent form after primary infection and can result in reactivation in someone who later becomes immunosuppressed – for example, when undergoing HSCT. CMV can be identified from respiratory secretions, urine and blood. As with adenovirus, PCR screening may be useful in identifying the virus before a child becomes symptomatic, especially in cases where reactivation is likely with immunosuppression. Treatment is usually with intravenous ganciclovir, with foscarnet or cidofovir as second-line treatment. Oral valganciclovir is very well absorbed and is also now an option for treatment. Foscarnet has also been used in cases of children undergoing HSCT to avoid the myelosuppressive effects of ganciclovir. IVIG should be used alongside antiviral therapy. There has been one case report of ganciclovir- and foscarnet-resistant CMV being successfully treated with artesunate (Shapira et al., 2008). There is also interest in the new antiviral agent maribavir for resistant CMV.

6.3 Epstein Barr Virus

EBV is associated with lymphoproliferative disorders in the immunocompromised. Replication of EBV in B cells is usually inhibited by natural killer cells, antibody-dependent cell cytotoxicity and T-cell cytotoxic responses. Therefore, children with cellular immune deficiencies are at risk of uncontrolled lymphoproliferation. Those at particular risk are children who are transplant recipients, both SOT or HSCT, and those with HIV. EBV can be detected in blood by PCR and viral load can be monitored. Alongside monitoring of the virus, it is important to monitor for signs of lymphoproliferation, both clinically and biochemically. Biopsy of suspicious lesions is often needed to make a diagnosis.

EBV infection requires treatment if it causes B lymphoproliferation or post-transplant lymphoproliferative disease (PTLD). This may take the form of the anti-CD20 monoclonal antibody rituximab, chemotherapy or radiotherapy. Decreasing immunosuppression whenever possible in a post-transplant patient is very important. More recently there have been encouraging results from work with cytotoxic T-cell therapy in PTLD. This involves the infusion of EBV-specific cytotoxic T lymphocytes (CTLs) generated from EBV sero-positive blood donors. In one recent multi-center study, 33 patients who had failed conventional therapy were recruited and monitored for response: 14 patients achieved complete remission while three showed a partial response (Haque et al., 2007).

6.4 Human Herpes Virus 6

Primary HHV6 infection in the immunocompetent host leads to the typical clinical picture of roseola or a non-specific febrile illness. The virus remains latent after primary infection and therefore, similar to CMV, can reactivate in immunocompromised states. The importance of HHV6 as a pathogen in the immunocompromised is probably underestimated, and many labs do not screen for infection; thus, many infections may not be recognized. HHV6 can cause fever, rash, hepatitis, pneumonia and encephalitis, as well as bone marrow suppression. HHV6 also appears to have synergistic effects and interactions with other infectious agents, such as CMV, adenovirus and fungi. It can be identified and quantified on blood samples by PCR. Treatment, where necessary, is with intravenous ganciclovir or foscarnet.

6.5 Varicella Zoster Virus

Primary varicella infection results in chickenpox, a common and generally self-limiting childhood illness. In the immunocompromised, there is a significant risk of both primary or reactivated disease becoming disseminated. This is particularly associated with T lymphocyte defects. VZV is the second most common cause of viral pneumonitis in children with AIDS. It should be remembered that fatal VZV infection has been reported in cases where the only immunosuppressant medication has been corticosteroids at a dose of 1 mg/kg/day of prednisolone for 2 weeks. The virus can be identified from vesicular fluid. Treatment is usually in the form of intravenous aciclovir, but, oral valaciclovir is a useful alternative in older children.

An important area to consider in relation to VZV infection is that of post-exposure prophylaxis. Although long-term prophylaxis for VZV is not usually recommended, post-exposure prophylaxis in non-immune immunocompromised children is important. Two options are available. The most widely used is varicella zoster immunoglobulin (VZIG). However, due to a shortage of VZIG a few years ago, oral aciclovir was reconsidered and has been shown to be effective. It must be remembered, however, that aciclovir has low bioavailability when given orally and requires multiple daily dosing. It may be more appropriate to consider the oral pro-drug valaciclovir, which has been shown to be effective and well tolerated (Nadal et al., 2002). Further work to clarify the best prophylactic and pre-emptive treatment regimens is needed.

7 Fungal Infections

Fungal infections must be considered in specific circumstances; for example, in those who are neutropenic (where risk increases exponentially with duration of neutropenia), those on steroids and those with graft versus host disease. *Candida* and *Aspergillus* are of particular interest in children who have undergone HSCT.

Symptoms that should raise the suspicion of fungal infection are persistent fevers unresponsive to antibiotics, skin nodules, chest pain and radiological evidence of infection crossing tissue planes. *Candida* is most commonly associated with CVC infection but can also cause disseminated disease. *Aspergillus* infection can have an insidious onset, frequently affecting the respiratory tract but then spreading to involve other areas such as the spine and intracranial cavity. Investigation and diagnosis remain difficult and may require antigen testing, PCR, cross-sectional imaging and biopsy of suspicious lesions/areas.

7.1 Candidiasis

Persistent mucocutaneous candidiasis is seen in patients with defects in T-cell function and may be a presenting feature for HIV infection or primary immune deficiency. Disseminated infection can involve almost any organ or any anatomical site and can be rapidly fatal. It is a particular concern in patients with CVC, especially those receiving multiple infusions and/or parenteral nutrition. There are a number of different *Candida* species that can result in disseminated infection. *Candia albicans* is the most common but *C. parapsilosis*, *C. glabrata*, *C. tropicalis* and *C. krusei* are increasingly common (Fig. 2). Diagnosis may be difficult, as blood cultures are not always positive. However, identification can be made by microscopy of biopsy specimens. Suspicious lesions, which are often found in organs such as the liver, kidney, spleen and brain, are best identified by cross-section imaging. PCR techniques have been developed, as well as detection of antigen from the fungal cell wall (Mannan). However, these techniques are not as yet wholly reliable. There are a number of agents available for treatment, including amphotericin B, caspofugin or an azole, such as voriconazole. Prolonged treatment is usually required and if there is a CVC

Species	Potential resistance
<i>C. albicans</i>	Resistance remains rare
<i>c. glabrata</i>	Fluconazole resistance in up to 20% cases, decreased susceptibility to other azoles; some cases of amphotericin B resistance
<i>C. parapsilosis</i>	Decreased susceptibility to caspofungin
<i>C. tropicalis</i>	
<i>C. krusei</i>	Resistant to ketoconazole and fluconazole; decreased susceptibility to itraconazole and amphotericin B
<i>C. guilliermondi</i>	Decreased suscepability to fluconazole
<i>C. lusitanae</i>	Generally resistant to amphotericin B
<i>C. rugosa</i>	Resistant to fluconazole in up to 60% cases; resistant to voriconazole

Fig. 2 *Candida* species and potential resistance to antifungal agents

involved it should be removed. Recently, there have been increasing concerns about anti-fungal drug resistance.

7.2 *Aspergillosis*

Invasive *Aspergillus* infection in the immunocompromised usually involves lungs, sinuses, brain or skin and commonly crosses tissue planes. Less commonly, it can cause endocarditis, osteomyelitis, meningitis and infection around the eye or orbit. It can cause angio-invasion, resulting in thrombosis and, occasionally, erosion of the blood vessel wall, often with catastrophic hemorrhage as a consequence. There are a number of *Aspergillus* species that cause invasive disease. Most commonly it is due to *Aspergillus fumigatus*, but *A. flavus*, *A. terreus*, *A. nidulans* and *A. niger* are also responsible for invasive infection. Diagnosis can be challenging. Cross-sectional imaging is very important in identifying suspicious lesions. *Aspergillus* is infrequently identified from blood and is most commonly indicated from biopsy specimens. Galactomannan, a complex sugar molecule found in the cell wall of the *Aspergillus* species, may also be identified from blood and can be useful in aiding diagnosis. Treatment is usually with amphotericin B, voriconazole or caspofungin and requires a prolonged course. Surgical excision of fungal lesions may be required, especially if there are significant areas of necrotic tissue into which antifungal agents will not penetrate effectively.

There is also an important association between *Aspergillus* infection and building work on a hospital site. One study in an Italian hematology unit found three cases of proven Aspergillosis in patients with acute leukemia that coincided with renovation work on the hospital site and high levels of *A. fumigatus* in the corridors (Pini et al., 2008). This highlights the importance for high-risk patients (e.g. after HSCT) of sterile isolation in cubicles maintained at positive pressure with highly purified air. Extra attention must be paid to reducing exposure of immunocompromised patients when there is building work on any hospital site.

8 Central Venous Catheter Infections

Many immunocompromised children will have indwelling CVC for treatment, be this an external Broviac or Hickman line, or an internal Portacath. Although very beneficial they, unfortunately, provide a site for infection. Catheter-related blood stream infections can be serious and in some cases life-threatening. Clinical features of catheter-related blood stream infection can be very non-specific. Diagnosis is often made on identification of organisms from blood culture along with lack of focal infective symptoms/signs. Organisms causing CVC infection are often those that would be non-virulent normal flora in an immunocompetent host; for example, coagulase negative staphylococci, enterococci and viridans streptococci. However, mycobacterial CVC infections also occur (Hawkins et al., 2008), as do *Candida* CVC infections.

Prevention has to be the priority. Lines should be inserted under strict aseptic technique and, once in place, access should be by fully trained staff using aseptic technique. Local policies should be followed for accessing and flushing CVCs.

Historically, CVCs were often removed when infection was identified; however, many patients were left in the difficult situation of poor venous access and in need of a further general anaesthetic to replace the line. Many catheter-related blood stream infections can be treated with antibiotics, without requiring CVC removal. If there is clinical suspicion of catheter-related blood stream infection, antibiotics for both coagulase negative *Staphylococcus* and Gram negative organisms should be introduced. Once organisms are identified from blood culture, antibiotics can be tailored appropriately. Antibiotic “locks” can be used alongside systemic antibiotics to reduce colonization within the CVC. Antibiotic “locking” involves instilling 1–2 ml of concentrated antibiotic solution in to the CVC and leaving it for a pre-determined time before removal. Antibiotics used in studies to treat CVC colonization have included vancomycin, amikacin and minocycline. There is also limited evidence on the use of amphotericin locks. Studies have attempted to look at whether using locks alone or in combination with systemic antibiotics has benefits. The results are variable and, at this stage it must be concluded that locks are a useful adjunct to systemic treatment. There is not enough evidence to suggest they can be used alone in immunocompromised children with CVCs (Berrington and Gould 2001).

In an attempt to prevent CVC infection, antibiotic-impregnated CVCs have also been developed. A recent systematic review found significant reductions in catheter-related blood stream infections in heparin-coated or antibiotic-impregnated CVCs, when compared to standard CVCs, as well as those coated with chlorhexidine, silver sulphadiazine, or silver-impregnated. There were, however, some concerns about the development of antibiotic resistance and further study is required before recommendations can be made about the most appropriate CVC to be used (Gilbert and Harden, 2008).

It must be remembered that catheter-related blood stream infection can be life threatening and there should be a low threshold for removal of the CVC if there are signs of clinical deterioration on treatment or if blood cultures drawn from CVCs are repeatedly positive, despite ongoing appropriate antibiotic treatment. There is increased mortality associated with delayed catheter removal in *S. aureus* and fungal infections, and so removal must be considered urgent if these organisms are isolated. The benefits of removing the CVC if Gram-negative organisms are identified is slightly more difficult to assess due to scarcity of data; however, it is likely that immediate removal does contribute to increased survival. In all infections the risk/benefit ratio of removing or retaining CVCs should be carefully considered.

9 Febrile Neutropenia

In children receiving treatment for malignancy, febrile neutropenia is a significant cause of morbidity and mortality. Over time, outcome has improved dramatically but it still remains a frequent reason for hospitalization. It has been shown that

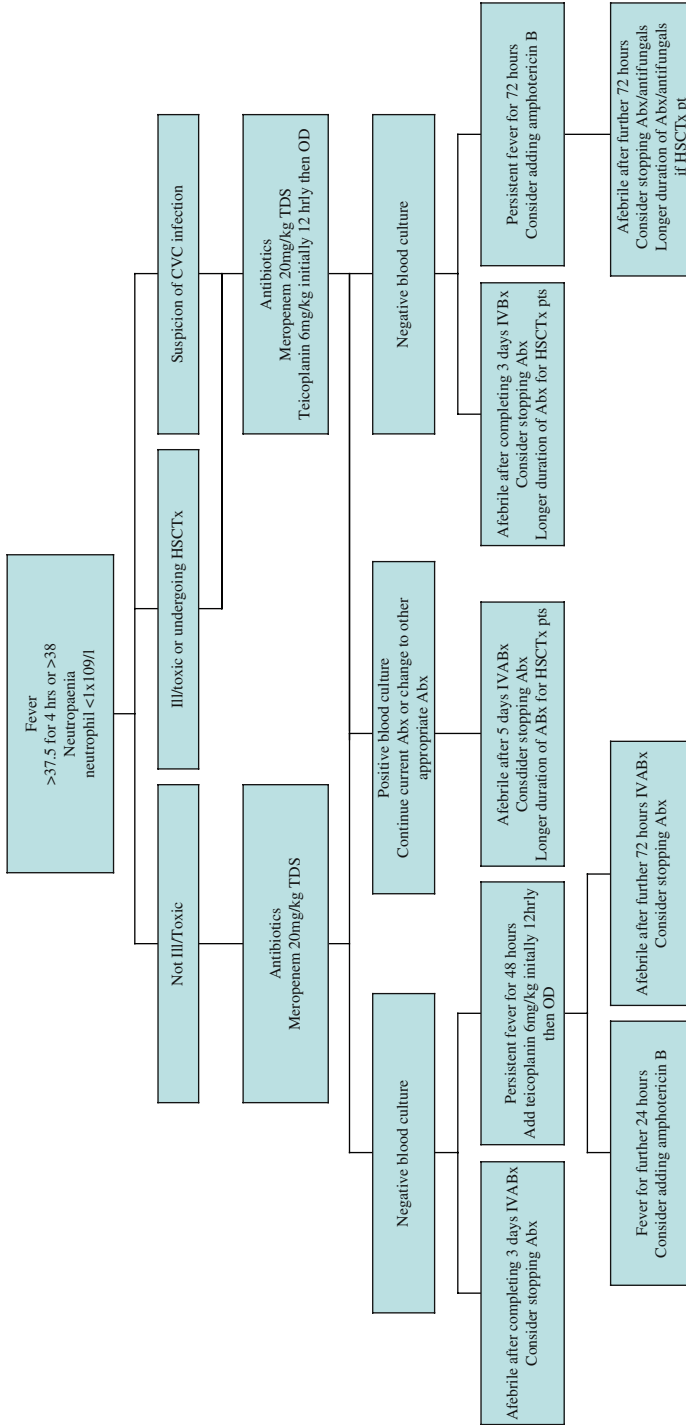


Fig. 3 Suggested protocol for febrile neutropenia treatment

empiric use of antibiotics decreases mortality (Schmipff et al., 1971); hence, empiric antibiotics have become a standard part of treatment for children and adults with febrile neutropenia.

Fever with neutropenia in any immunocompromised child should be acted on promptly. However, exactly how this is defined and what is appropriate management varies widely. This was highlighted by a recent review of febrile neutropenia management in the United Kingdom Children's Cancer Study Group centers (Phillips et al., 2007). There was wide variation in the definition of fever (from persistent temperature higher than 37.5°C to a single reading of 39°C) and neutropenia (absolute neutrophil count $<1 \times 10^9$, $<0.75 \times 10^9$ or $<0.5 \times 10^9$). Empirical antibiotic regimes also varied greatly, including aminoglycosides plus a second agent (piperacillin based, cephalosporin or carbapenem), carbapenem alone or, in two cases, cefuroxime plus flucloxacillin and ciprofloxacin plus ceftazidime. Timing of the anti-fungal therapy was even more variable, in terms of when to start and the duration of empirical treatment. Some of this variation can be explained by variations in organisms isolated and antibiotic sensitivity from unit to unit, but this does not seem to account for all the differences in practice. Therefore, although local findings should influence presenting patterns, further work is required to devise a framework within which local policies that target specific patient populations and microbiological flora are implemented. A specimen protocol is shown in Fig. 3

10 Conclusions

Infections in immunocompromised children offer a variety of challenges in both diagnosis and management. Organisms that result in mild, self-limiting illness in an immunocompetent host can have catastrophic effects on an immunocompromised child. Signs and symptoms are often less specific and finding a causative organism can be more difficult. It is important to have a low threshold for thinking about infections and looking for them. Negative tests should not be taken to be reassuring if there is clinical suspicion and it may be necessary to look further and more closely. It is important to develop a good relationship with local microbiology and virology laboratories to aid this process. Once an infection is identified, it must be acted upon quickly as delay may be disastrous. Treatment of any infection in an immunocompromised child is likely to be more intense and prolonged than in a child with a fully functioning immune system. It is also important to consider prophylaxis for specific patient groups in specific situations (e.g. post HSCT) and each unit should have defined policies and guidelines to follow for these patients.

In summary, when dealing with an immunocompromised child, for whatever reason, when there is suspicion about infection, think early, look carefully and treat now!

References

- Abubakar, I., Aliyu, S.H., Arumugam, C., Usman, N.K., & Hunter, P.R. (2007). Treatment of cryptosporidiosis in immunocompromised individuals: systematic review and meta-analysis. *Br J Clin Pharm*, (63), 387–393
- Alexander, S.W., Mueller, B.U., & Pizzo, P. (2002). Infectious complications in children with cancer and children with Human Immunodeficiency Virus Infection. *Clinical Approach to Infection in the Compromised Host*. R. Rubin, L.S. Young (Eds.) pp. 441–464. New York: Kluwer Academic/Plenum Publishers
- Andris, D.A., Krzywda, E.A., & Edmiston, C.E. (1998). Elimination of intraluminal colonisation by antibiotic lock in silicone vascular catheters. *Nutrition*, (14), 427–432
- Baum, S.G. (2000). Adenovirus. *Mandell, Douglas and Bennet's Principles & Practice of Infectious Disease* (5th ed.) G.L. Mandell, J.E. Bennet, R. Dolin (Eds.) pp. 1624–1630. Philadelphia: Churchill Livingstone
- Benfield, T., Atzori, C., Miller, R.F., & Helweg-Larsen J. (2008). Second line salvage treatment of AIDS-associated Pneumocystis jiroveci pneumonia: a case series and systematic review. *J Acquir Immune Defic Syndr*, 48(1), 63–67
- Berrington, A. & Gould, K. (2001). Use of antibiotic locks to treat colonized central venous catheters. *J Antimicrob Chemother*, (48), 597–603
- Berrington, J.E., Flood, T.J., Abinun, M., Galloway, A., & Cant, A.J. (2000). Unsuspected Pneumocystis carinii pneumonia at presentation of severe primary immunodeficiency. *Arch Dis Child*, (82), 144–147
- Biron, K.K. (2006). Antiviral drugs for cytomegalovirus diseases. *Antiviral Res*, (71), 154–163
- Boeckh, M., Berrey, M.M., Bowden, R.A., Crawford, S.W., Balsley, J., & Corey, L. (2001). Phase I evaluation of the respiratory syncytial virus specific monoclonal antibody Palivizumab in recipients of hematopoietic stem cell transplants. *JID*, (184), 350–354
- Boeckh, M. (2006). Prevention of VZV infection in immunosuppressed patients using antiviral agents. *Herpes*, 13(3), 60–65
- Briel, M., Bucher, H.C., Boscacci, R., & Furrer, H. (2006). Adjunctive corticosteroids for Pneumocystis jiroveci pneumonia in patients with HIV infection. *Cochrane Database Syst Rev*, 2006 Jul, (193), CD006150
- Bye, M.R., Cairns-Bazarian, A.M., & Ewig, J.M. (1994). Markedly reduced mortality associated with corticosteroid therapy of Pneumocystis carinii pneumonia in children with acquired immune deficiency syndrome. *Arch Pediatric Adolesc Med*, (148), 638–641
- Chakraborty, R. & Shingadia, D. (2006). Treating opportunistic infections in HIV infected children. Guidelines for the Children's HIV association (CHIVA)
- Chavez-Bueno, S., Mejias, A., Merryman, R., Ahmad, N., Jafri, H.S., & Ramilo, O. (2007). Intravenous palivizumab and ribavirin combination for respiratory syncytial virus disease in high-risk paediatric patients. *Ped Inf Dis J*, 26(12), 1089–1093
- Cherry, J.D. (1998). Adenoviruses. *Textbook of Pediatric Infectious Diseases* (4th ed.) R.D. Fegin, & J.D. Cherry (Eds.) pp. 1666–1684. Philadelphia: W.B. Saunders Company.
- Crooks, B.N.A., Taylor, C.E., Turner, A.J.L., Osman, H.K.E., Abinun, M., Flood, T.J., & Cant, A.J. (2000). Respiratory viral infections in primary immune deficiencies: significance and relevance to clinical outcome in a single BMT unit. *Bone Marrow Transplant*, (26), 1097–1102
- Drew, W.L., Miner, R.C., Marousek, G.I. & Sunwen, C. (2006). Maribavir sensitivity of cytomegalovirus isolates resistant to ganciclovir, cidofovir or foscarnet. *J Clin Virol*, (37), 124–127
- Gallimore, C., Taylor, C., Gennery, A.R., Cant, A.J., Galloway, A., Xerry, J., Adigwe, J., & Gray, J.J. (2008). Contamination of the hospital environment with gastroenteric viruses: comparison of two pediatric wards over a winter season. *J Clin Microbiol*, 46(9), 3112–3115
- Einsle, H., Reusser, P., Bornhauser, M., Kalhs, P., Ehninger, G., Hebart, H., Chalandon, Y., Kroger, N., Hertenstein, B., & Rohde, F. (2006). Oral valganciclovir leads to higher exposure to ganciclovir than intravenous ganciclovir in patients following allogeneic stem cell transplantation. *Blood*, (107), 3002–3008

- Gallimore, C., Lewis, D., Taylor, C., Cant, A., Gennery, A., & Gray, J. (2004). Chronic excretion of a norovirus in a child with cartilage hair hypoplasia(CHH). *J Clin Virol*, (30), 196–204
- Garret Nichols, W., Peck Campbell, A.J., & Boeckh, M. (2008). Respiratory viruses other than influenza virus: impact and therapeutic advances. *Clin Micro Rev*, 21(2), 274–290
- Gaynor, A.M., Nissen, M.D., Whiley, D.M., Mackay, I.M., Lambert, S.B., Guang, W.U., Brennan, D.C., Storch, G.A., Sloots, T.P., & Wang D. (2007). Identification of a novel polyomavirus from patients with acute respiratory tract infections. *PLoS Pathog*, 3(5), e64. doi:10.1371/journal.ppat.0030064
- Green, H., Paul, M., Vidal, L., & Leibovici, L. (2007). Prophylaxis for Pneumocystis pneumonia (PCP) in non-HIV immunocompromised patients. *Cochrane Database Syst Rev*, 2007 Jul 18, (3), CD005590
- Gilbert, R.E. & Harden, M. (2008). Effectiveness of impregnated central venous catheters for catheter related blood stream infection: a systematic review. *Curr Opin Infect Dis*, 21(3), 235–245
- Haque, T., Wilie, G.M., Jones, M.M., Higgins, C.D., Urquhart, G., Wingate, P., Burns, D., McAulay, K., Turner, M., Bellamy, C., Amlot, P.L., Kelly, D., MacGilchrist, A., Gandhi, M.K., Swerdlow, A.J., & Crawford, D. (2007). Allogeneic cytotoxic T cell therapy for EBV positive posttransplantation lymphoproliferative disease: results of a phase 2 multicenter clinical trial. *Blood*, (110), 1123–1131
- Hawkins, C., Qi, C., Warren, J., & Stosor, V. (2008). Catheter related bloodstream infections caused by rapidly growing nontuberculous mycobacteria: a case series including rare species. *Diagn Microbiol Infect Dis*, 61(2), 187–191
- Hodge, D. & Puntis, J.W.L. (2002). Diagnosis, prevention and management of catheter related bloodstream infection during long term parenteral nutrition. *Arch Dis Child Fetal Neonatal Ed*, (87), F21–F24
- Investigation of Blood Cultures (for organisms other than Mycobacterium species). Issue no: 5.* issue date 09.08.05. Issued by: Standards Unit, Evaluations and Standard Laboratory. Reference no: BSOP 37i5
- Lee, I & Barton, T.D. (2007). Viral respiratory tract infections in transplant patients. *Drugs*, 67(10), 1411–1427
- Lenaerts, L. & Naesens, L. (2006). Antiviral therapy for adenovirus infections. *Antiviral Res*, (71), 172–180
- Lion, T., Baumgartinger, R., Watzinger, F., Matthes-Martin, S., Suda, M., Preuner, S., Futterknecht, B., Lawitschka, A., Peters, C., Pötschegr, U., & Gadner, H. (2003). Molecular monitoring of adenovirus in peripheral blood after allogeneic bone marrow transplantation permits early diagnosis of disseminated disease. *Blood*, 102(3), 1114–1120
- Ljungman, P., Ward, K.N., Crooks, B.N.A., Parker, A., Martine, R., Shaw, P.J., Brinch, L., Brune, M., De La Camara, R., Dehher, A., Pauksen, K., Russell, N., Schwarere, A.P., & Cordonnier, C. (2001). Respiratory virus infections after stem cell transplantation: a prospective study from the Infectious Diseases Working Party of the European Group for Blood and Marrow Transplantation. *Bone Marrow Transplant*, (28), 479–484
- McLaughlin, G.E., Virdee, S.S., Schleien, C.L., Holzman, B.H., & Scott G.B. (1995). Effect of corticosteroids on survival of children with acquired immune deficiency syndrome and Pneumocystis carinii-related respiratory failure. *J Pediatr*, (126), 821–824
- Nadal, D., Leverger, G., Sokal, E.M., Floret, D., Perel, Y., Leibundgut, K., & Weller S. (2002). In investigation of the steady-state pharmacokinetics of oral valaciclovir in immunocompromised children. *JID*, 186(Suppl 1), S123–130
- Pfaller, M.A. & Diekema, D.J. (2007). Epidemiology of invasive candidiasis: a persistent public health problem. *Clin Micro Rev*, 20(1), 133–163
- Phillips, B., Selwood, K., Lane, S.M., Skinner, R., Gibson, F., & Chisholm, J. (2007). Variation in policies for the management of febrile neutropaenia in United Kingdom Children’s cancer Study Group centres. *Arch Dis Child*, (92), 495–498
- Pickering, L.K., Baker, C.J., Long, S.S., & McMillan, J.A, (Eds.) (2006). *Red Book. Report of the Committee on Infectious Diseases.* (27th ed.). Elk Grove Village, IL: American Academy of Paediatrics.

- Pini, G., Faggi, E., Donato, R., Sacco, C., & Fanci, R. (2008). Invasive pulmonary aspergillosis in neutropenic patients and the influence of hospital renovation. *Mycoses*, 51(2), 117–122
- Schildgen, O., Müller, A., Allander, T., Mackay, I.M., Völz, S., Kupfer, B., & Simon, A. (2008). Human bocavirus: passenger of pathogen in acute respiratory tract infections? *Clin Micro Rev*, 21(2), 291–304
- Schimpff, S., Slatterlee, W., & Young, V.M. (1971). Empiric therapy with carbenicillin and gentamicin for febrile patients with cancer and granulocytopenia. *NEJM*, (284), 1061–1065
- Shankar, S.M. & Nania, J.J. (2007). Management of Pneumocystis jiroveci pneumonia in children receiving chemotherapy. *Paediatr Drugs*, 9(5), 301–309
- Shapira, M.Y., Resnick, I.B., Chou, S., Neumann, A.U., Lurain, N.S., Stamminger, T., Caplan, O., Saleh, N., Efferth, T., Marschall, M., & Wolf, D. (2008). Artesunate as a potent antiviral agent in a patient with late drug-resistant cytomegalovirus infection after hematopoietic stem cell transplantation. *CID*, (46), 1455–1457
- Slatter, M.A., Rogerson, E.J., Taylor, C.E., Galloway, A., Clark, J.E., Flood, T.J., Abinun, M., Cant, A.J., & Gennery, A.R. (2007). Value of bronchoalveolar lavage before haematopoietic stem cell transplantation for primary immunodeficiency or autoimmune diseases. *Bone Marrow Transplant Sep*, 40(6), 529–533.
- Sleasman, J.W., Hemenway, C., Klein, A.S., & Barrett D.J. (1993). Corticosteroids improve survival of children with AIDS and Pneumocystis carinii pneumonia. *Am J Dis Child*, (147), 30–34
- Soldatou, A. & Graham Davies, E. (2003). Respiratory virus infections in the immunocompromised host. *Paed Resp Rev*, (4), 193–204
- Taylor, G.S., Vipond, I.B., & Caul, E.O., (2001). Molecular epidemiology of outbreak of respiratory syncytial virus within bone marrow transplant unit. *J Clin Microbiol*, 39(2), 801–803
- Van Burik, J. & Weisdorf, D. (2000). Infections in recipients of blood and marrow transplantation. *Mandell, Douglas and Bennet's Principles & Practice of Infectious Disease*. (5th ed.) G.L. Mandell, J.E. Bennet, R. Dolin (Eds.) p. 3138. Philadelphia: Churchill Livingstone.
- Walls, T., Shankar, A.G., & Shingadia, D. (2003). Adenovirus: an increasingly important pathogen in paediatric bone marrow transplant patients. *The Lancet*, Feb, (3), 79–86
- Yee-Guardino, S., Gowans, K., Yen-Lieberman, B., Berk, P., Kohn, D., Wang, F.Z., Danziger-Isakov, L., Sabella, C., Worley, S., Pellet, P.E., & Goldfarb, J. (2008). Beta-herpesviruses in febrile children with cancer. *Emerg Infect Dis*, 14(4), 579–585