

Demons-Meigs Pseudosyndrome Mimicking the Symptoms of Pregnancy: A Case Report

Erdogan Nohuz^{1,2*}, Maher Alaboud¹, Bilal El-Drayi³, Stefano Tamburro⁴, Said Kachkach⁵, Janos Varga²

1- Department of Obstetrics and Gynecology, General Hospital of Thiers, Thiers, France

2- Department of Surgery, General Hospital of Thiers, Thiers, France

3- Department of Anesthesiology and Critical Care Medicine, General Hospital of Thiers, Thiers, France

4- Department of Obstetrics and Gynecology, General Hospital of Grosseto, Grosseto, Italy

5- Department of Radiology, General Hospital of Thiers, Thiers, France

Abstract

Background: The Demons-Meigs syndrome should usually be evoked in case of presence of a typical triad: abdominopelvic mass, ascites and hydrothorax. Its diagnosis appears crucial to prevent the realization of unnecessary surgical procedures.

Case Presentation: A 32-year-old woman presented in April 2012 to the emergency department of our maternity unit (General Hospital, Thiers, France) with an abdominal distension mimicking the symptoms of a pregnancy at term. Physical examination revealed a voluminous painful abdominopelvic mass, extended from the pelvis to the upper abdomen with a large right pleural effusion. Ultrasound and computed tomography showed it was a tumor measuring more than 300 mm in diameter with a right hydrothorax. Serum CA-125 level was 289 U/ml. Cytologic analysis of the pleural effusion didn't show any malignant cells. In this study, Demons-Meigs syndrome was recognized. A laparoscopico-laparotomic management permitted an aspiration of 23 liters of a brownish liquid and an unilateral adnexectomy after pleural paracentesis was performed. Frozen section demonstrated benign mucinous cystadenoma. The final histologic findings objectified intracystic intestinal type ovarian mucinous borderline tumor. After multidisciplinary consultation, the patient was reoperated one month later. The exploration didn't reveal any suspected lesions and appendectomy and omentectomy were performed. The postoperative course was uneventful. Serum CA-125 level was normal at the time of the reoperation and 24 months after the initial surgery.

Conclusion: The preoperative recognition of a Demons-Meigs syndrome or a Demons' pseudosyndrome is essential to avoid useless surgical procedures.

Keywords: Abdominal mass, Demons-Meigs syndrome, Hydrothorax, Meigs, Ovarian benign tumor.

To cite this article: Nohuz E, Alaboud M, El-Drayi B, Tamburro S, Kachkach S, Varga J. Demons-Meigs Pseudosyndrome Mimicking the Symptoms of Pregnancy: A Case Report. *J Reprod Infertil.* 2014;15(4):229-232.

* Corresponding Author:
Erdogan Nohuz,
Department of Obstetrics
and Gynecology, General
Hospital, 63300 Thiers,
France
E-mail: enohuz@yahoo.fr

Received: Jan. 28, 2014

Accepted: May 28, 2014

Introduction

The Demons-Meigs syndrome should usually be evoked in case of presence of a typical triad: abdominopelvic mass, ascites and hydrothorax. Demons was the first, between 1887 and 1902, who indicated that removal of the tumor (benign ovarian cyst, solid ovarian tumor,

fibroma of the broad ligament) was essential for the patient to be cured from effusions (1, 2). In 1937, Meigs came to similar conclusion about ovarian fibromas and granulosa cell tumors. The name of Demons-Meigs was attributed to this syndrome. However, the physiopathology of the

ascites and the hydrothorax still remain obscure (1). Ascites occurs in 10-15% of the cases. Hydrothorax is present in only 1% of the cases and is mostly unilateral right-sided (2, 3). Ascitic and pleural fluids are similar in nature (exudative or transudative). The circumstances of discovery are variable and can be related to the consequences of the triad syndrome (weight gain, abdominal pain, respiratory distress). The patient can also be asymptomatic (fortuitous discovery) (2-5). The serum CA-125 level is not specific and does not always increase (6). Preoperative biologic (chemistry and cytologic study) and radiologic findings (ultrasound, computed tomography scan and magnetic resonance imaging) can be highly accurate in diagnosis (origin of the mass, no signs of distant metastases) and surgical management strategy (4-7). This preoperative recognition should be considered in the differential diagnosis and appears essential to prevent the realization of unnecessary surgical procedures. Final histologic findings which exclude malignancy and complete and definitive remission after surgery confirm this particular syndrome. For Brun, Demons' syndrome should include benign genital tumors, the Demons-Meigs eponym must be reserved for the description of ovarian fibromas and granulosa cell tumors, and the Demons' pseudosyndrome for all other entities (1). In this case report, the large ovarian tumor with right hydrothorax and elevated serum CA-125 level indicated a Demons-Meigs syndrome. The final histologic findings demonstrated Demons' pseudosyndrome which is an unusual situation when it's related to a borderline ovarian tumor (8). Surgical management consisted of a bilateral salpingo-oophorectomy with hysterectomy in postmenopausal women or unilateral (salpingo-) oophorectomy in young patients with desire for pregnancy (1, 4).

Case Presentation

A 32-year-old-woman was referred in April 2012 to the emergency department of our maternity unit (General Hospital of Thiers, France) for probable pregnancy at term with beginning of labor. The condition started 9 months before by the occurrence of progressive abdominal distension, dyspnea and secondary amenorrhea. Physical examination revealed a voluminous painful abdominopelvic mass, diffuse, extending from the pelvis to the upper abdomen and large right pleural effusion (Figure 1). On vaginal examin-

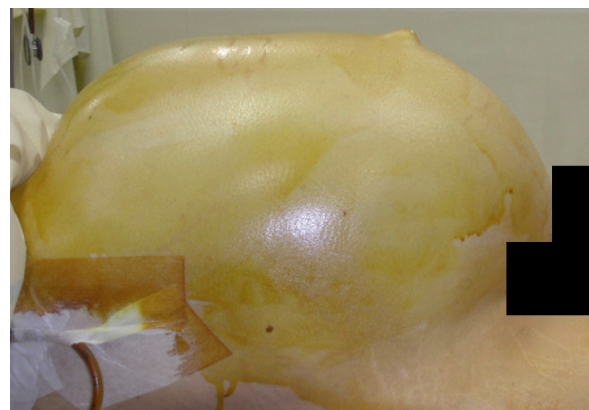


Figure 1. Preoperative appearance of the abdominal distension

ation, it was difficult to relate the mass to any obstetrico-gynecologic origin. Ultrasound showed a liquid predominant tumor measuring more than 300 mm in diameter and no pregnancy. Thoraco-abdominal CT-scan showed a right hydrothorax, confirmed the abdominopelvic mass which filled all the peritoneal cavity without signs of distant metastases or lymphadenopathy (Figures 2-4). Serum CA-125 was 289 U/ml and ACE was normal. Given the importance of dyspnea, pleural paracentesis (250 ml) was performed preoperatively. The chemistry and cytologic study of the pleural effusion was in favor of an exsudate without any suspected malignant cells. Therefore, an exploratory laparoscopy was performed. It revealed a voluminous ovarian cyst without vegetation

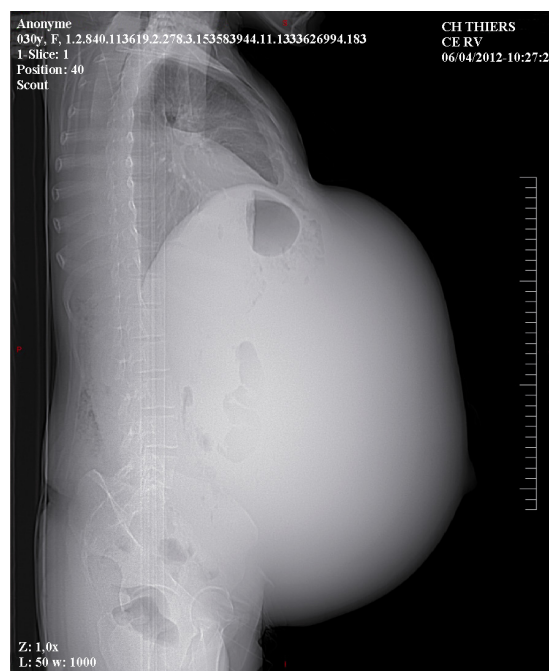

Figure 2. Scout view of the abdominopelvic mass

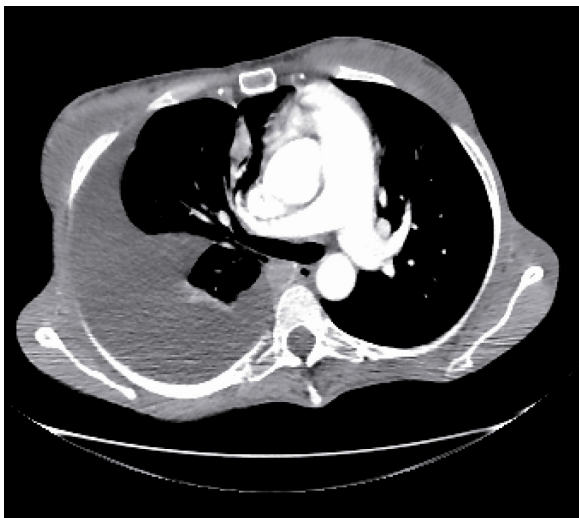

Figure 3. Thoracic axial CT-scan showing a right pleural effusion

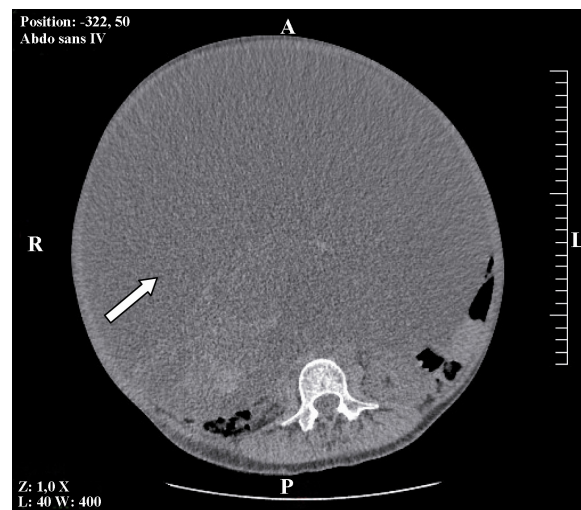


Figure 4. Abdominal axial CT-scan showing a voluminous ovarian cyst (white arrow)

or any suspected peritoneal implant. The liver was macroscopically normal. The visualization of the uterus was impossible. The aspiration of 15 liters of a brownish liquid permitted a midline laparotomy of limited size, under and above the umbilicus. The aspiration was completed (23 liters) and a right ovarian cyst was identified (Figures 5, 6). The uterus, the contralateral ovary, the bladder and the pelvic peritoneum were macroscopically normal. A right adnexectomy was performed and a frozen section pathologic exam demonstrated benign mucinous cystadenoma. The postoperative course was uneventful and the patient was discharged 5 days after the procedure. The final histologic examination objectified intracystic intestinal type ovarian mucinous borderline tumor which corresponded to a Demons' pseudosyn-

drome. After multidisciplinary consultation, the patient was re-operated a month later for a staging surgery. The exploration didn't reveal any suspected lesions and multiple biopsies, an appendectomy and an omentectomy were performed by laparoscopy. The patient recovered quickly. Serum CA-125 level was normal at the time of the re-operation and 24 months after the initial surgery.

Conclusion

An abdominopelvic mass associated to ascites, hydrothorax and elevated CA-125 serum level can imitate an advanced ovarian cancer. Nevertheless, a Demons-Meigs syndrome or a Demons' pseudosyn-

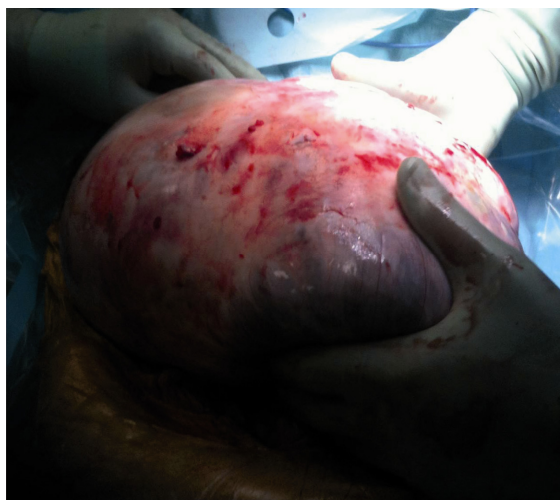

Figure 5. Extraction of the abdominopelvic mass

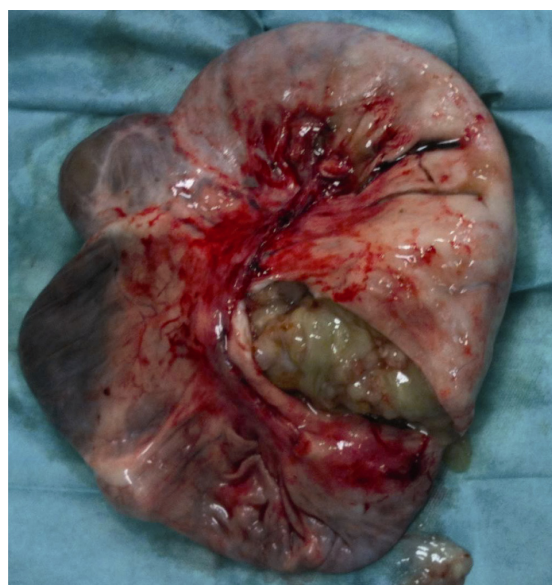


Figure 6. Macroscopic view of the ovarian tumor

negative cytologic analysis of the ascitic and pleural effusion and no peritoneal implant on CT-scan. This preoperative diagnosis enables us to avoid useless surgical procedures.

Acknowledgement

The authors thank Mrs Salles-Astier Huguette and El drayi Inga for their councils.

Conflict of Interest

The authors declare no conflict of interest.

References

1. Brun JL. Demons syndrome revisited: a review of the literature. *Gynecol Oncol.* 2007;105(3):796-800.
2. Loue VA, Gbary E, Kouli S, Akpa B, Kouassi A. Bilateral ovarian fibrothecoma associated with ascites, bilateral pleural effusion, and marked elevated serum CA-125. *Case Rep Obstet Gynecol.* 2013; 2013:189072.
3. Loizzi V, Cormio G, Resta L, Fattizzi N, Vicino M, Selvaggi L. Pseudo-Meigs syndrome and elevated CA125 associated with struma ovarii. *Gynecol Oncol.* 2005;97(1):282-4.
4. Tamburro S, Nohuz E, Mage G, Canis M. Laparoscopic surgical approach for a borderline ovarian tumour of more than 25 cm. *Gynecol Surg.* 2010;7(3):267-9.
5. Mui MP, Tam KF, Tam FK, Ngan HY. Coexistence of struma ovarii with marked ascites and elevated CA-125 levels: case report and literature review. *Arch Gynecol Obstet.* 2009;279(5):753-7.
6. Urban BA, Fishman EK. Spiral CT of the female pelvis: clinical applications. *Abdom Imaging.* 1995; 20(1):9-14.
7. Zhang H, Zhang GF, He ZY, Li ZY, Zhu M, Zhang GX. Evaluation of primary adnexal masses by 3T MRI: categorization with conventional MR imaging and diffusion-weighted imaging. *J Ovarian Res.* 2012;5(1):33.
8. Chen YY, Hsiao SM, Hsu YP, Lin HH, Wei MC. Borderline mucinous ovarian tumor presenting as pseudo-Meigs' syndrome. *J Obstet Gynaecol Res.* 2013;39(1):434-6.