

# Staged Deep Brain Stimulation of Ventral Intermediate Nucleus of the Thalamus for Suppression of Essential Tremors

## Abstract

Deep brain stimulation (DBS) of the ventral intermediate nucleus (VIM) of the thalamus is a powerful surgical option in the treatment of essential tremors (ETs). However, its therapeutic efficacy depends on the tremor distribution. DBS is highly efficient in the relief of distal appendicular tremor but not other types of tremor. We report a case of staged DBS of ventral intermediate nucleus (VIM) of thalamus for the suppression of ETs.

**Keywords:** *Deep brain stimulation, tremor, ventral intermediate nucleus of the thalamus*

## Introduction

Tremor is defined as a rhythmic, sinusoidal oscillation of a body part and has been reported as one of the most common movement disorders encountered in the clinical practice. The classification and differentiation of atypical, intricate, and uncommon tremors can be challenging, and the differential diagnosis hinges on the acquisition of a detailed examination that focuses attention on tremor topography, frequency, amplitude, and associated features.

Conventionally, the ventralis intermedius nucleus (VIM) of the thalamus has been considered the target for deep brain stimulation (DBS) for most tremor syndromes. This clinical practice of using VIM has been largely based on the excellent tremor outcomes in patients with refractory essential tremor (ET).<sup>[1]</sup> Nevertheless, despite the exceptional results observed in some patients, thalamic stimulation might not successfully treat all patients. In addition, uncommon forms of tremors remain a treatment challenge. Thalamic lesioning surgery and DBS for complex tremor syndromes have yielded mixed and in many cases disappointing results.<sup>[2,3]</sup> Larger lesions (e.g., thalamotomy) or areas of stimulation have been commonly required to treat both distal and the more difficult problem of proximal tremor.<sup>[4,5]</sup> Larger lesions or

wider zones of electrical stimulation can potentially lead to an increased risk of adverse events.<sup>[6,7]</sup>

## Case Report

A 68-year-old female presented with resting and positional tremors with no parkinsonian symptoms. Medical therapy with trihexyphenidyl HCl, levodopa/carbidopa hydrate, and arotinolol was prescribed for outpatient use but was not clearly effective. Institutional ethical clearance and patient's consent for publication were taken for the same. Left VIM thalamus DBS was performed in December 2016 with near abolition of tremors in her right hands and legs. She was later planned for right VIM thalamus DBS after 2½ months. Leksell frame was applied and affixed to the patient's head after administration of a local anesthetic (1% lidocaine). Computed tomography scan performed after marking the anterior commissure-posterior commissure (AC-PC) line. Target coordination was 14 mm lateral to AC-PC line, 6 mm posterior to midpoint, and 0 mm above the AC-PC line [Figure 1]. Microelectrode recording showed that unit activity was discriminated throughout the tract. VIM activity was obtained, including unit responded to the passive movement of hand. Two tremor-related cells were found in the ventral portion of VIM. Ventral capsule (Vc) activity was not recorded. Result was seen as abolition of tremors in hands, recording of rhythmic

**Riki Tanaka,  
Ahmed Ansari,  
Yasukazu Kajita<sup>1</sup>,  
Yasuhiro Yamada,  
T Kawase,  
Yoko Kato**

*Department of Neurosurgery,  
Fujita Health University,  
Banbuntane Hotokukai Hospital,  
<sup>1</sup>Department of Neurosurgery,  
National Hospital Organization,  
Nagoya Medical Center,  
Nagoya, Japan*

**Address for correspondence:**  
*Dr. Ahmed Ansari,  
Department of Neurosurgery,  
Fujita Health University,  
Banbuntane Hotokukai  
Hospital, 3-6-10, Otobashi,  
Nakagawa Ward, Nagoya City,  
Aichi, Japan.  
E-mail: ahmed.ansari2@gmail.  
com*

### Access this article online

**Website:** [www.asianjns.org](http://www.asianjns.org)

**DOI:** 10.4103/ajns.AJNS\_132\_17

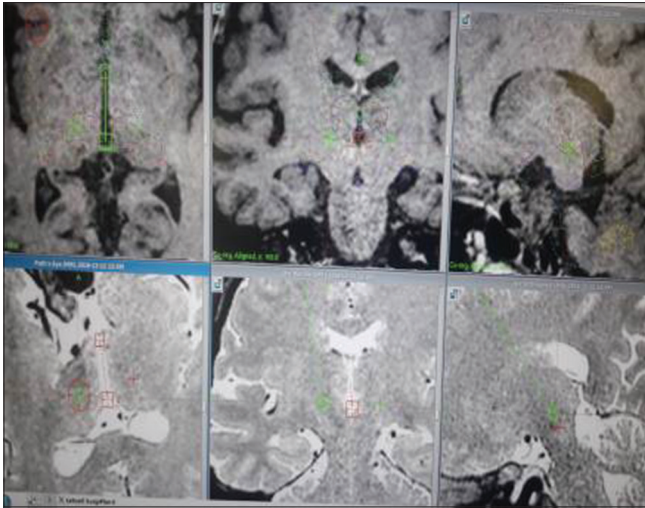
### Quick Response Code:



**How to cite this article:** Tanaka R, Ansari A, Kajita Y, Yamada Y, Kawase T, Kato Y. Staged deep brain stimulation of ventral intermediate nucleus of the thalamus for suppression of essential tremors. *Asian J Neurosurg* 2019;14:1030-2.

This is an open access journal, and articles are distributed under the terms of the Creative Commons Attribution-NonCommercial-ShareAlike 4.0 License, which allows others to remix, tweak, and build upon the work non-commercially, as long as appropriate credit is given and the new creations are licensed under the identical terms.

**For reprints contact:** [reprints@medknow.com](mailto:reprints@medknow.com)



**Figure 1: Coordinates for right ventral intermediate nucleus thalamic deep brain stimulation**

discharges, and anatomometry with X-rays, depicting the position of microelectrode. Stimulation was done with 3.2 mA and 180 Hz for a duration of 60  $\mu$ s. By combining microelectrode recording and stimulation technique with conventional X-ray, DBS lead was placed through the first track. Finally, a programmer was implanted in the chest in subcutaneous plane under general anesthesia, and its cable was connected to the DBS lead.

## Discussion

ET is a postural disability that is inherited in an autosomal dominant pattern in approximately two-thirds of cases, and the age at onset is most commonly in young adulthood. The tremor frequency is 4–12 Hz, and it usually resolves with limb support and at complete rest.<sup>[8]</sup> The upper extremity is affected in 90% of cases, the head in 40%, and the voice in 30%. Alcohol and beta- adrenergic receptor antagonists often adequately suppress ET.<sup>[9]</sup> Although the pathogenesis of this disorder is unknown, the olivo-cerebello-rubral loop and the cerebellum are believed to be critical in the development of ET.<sup>[8]</sup> DBS has become a standard therapy for the treatment of selected cases of medication-refractory ET. Conventionally, the ventralis intermedius nucleus (VIM) of the thalamus has been considered the main target for medically intractable tremors.

There are some drugs which have been tried in the treatment for ETs such as beta-blockers such as propranolol (Inderal) which help relieve tremors in some people. Beta-blockers may not be an option if you have asthma or certain heart problems. Side effects may include fatigue, lightheadedness, or heart problems. Other drugs as primidone (Mysoline) may be effective in people who do not respond to beta-blockers. Other medications that might be prescribed include gabapentin and topiramate. Side effects include drowsiness and nausea, which usually disappear within a short time. Alprazolam and clonazepam may be used to treat people, for

whom tension or anxiety worsens tremors. Side effects can include fatigue or mild sedation. These medications should be used with caution because they can be habit-forming. Botox injections might be useful in treating some types of tremors, especially head and voice tremors. Botox injections can improve tremors for up to 3 months at a time.

Physical therapists can teach exercises to improve muscle strength, control, and coordination.

Occupational therapists can help adapt to living with ET. Therapists might suggest adaptive devices to reduce the effect of tremors on your daily activities, including heavier glasses and utensils, wrist weights, and wider, heavier writing tools, such as wide-grip pens.

Benabid *et al.*<sup>[10]</sup> reported that tremor suppression by stimulation directed to the VIM was maintained over the long term (>2 years) and that such stimulation induced fewer adverse effects such as dysarthria, disequilibrium, limb ataxia, dystonia, and paresthesias. Control of these side effects is easily accomplished by reducing the intensity of the stimulator or stopping stimulation altogether.<sup>[8,9]</sup>

The physiological basis for VIM stimulation remains speculative, but the cerebellothalamic pathways may play a significant role in the development of ETs.<sup>[10]</sup> Autonomous neuronal activities have been recorded in the VIM and these “tremor” cells were found to have a bursting discharge pattern, with the burst frequency equal to the patient’s tremor frequency.<sup>[8]</sup> The VIM is considered to be a convergence point for both pallidal and cerebellar afferent pathways.<sup>[11]</sup> The therapeutic mechanism of thalamic DBS may involve an alteration or functional ablation of the firing center of the VIM or a desynchronization of overactive neurons seen in ET.<sup>[8,9]</sup> Stimulation could directly activate cells or axons by depolarization, but it could also inactivate cells or axons by depolarization blockade.<sup>[8]</sup> Activation of cells could also have effects similar to inactivation by increasing the release of inhibitory neurotransmitters such as  $\gamma$ -aminobutyric acid or by overriding abnormally patterned burst activity.

Registration is recorded along one to five trajectories in the volume of interest to identify the different structure boundaries. In general, these measurements are performed in millimeter steps before reaching the target and often measurements even go beyond the target structure. Most centers using microelectrode recording perform, as well, intraoperative stimulation along the trajectory using the microelectrodes stimulating in the micro-Ampere range,<sup>[12,13]</sup> or macroelectrodes stimulating in the milli-Ampere range, for example, using radiofrequency or DBS stimulation electrodes.<sup>[14,15]</sup> In general, this is done at the same measurement points as for micro electrode recording (MER), to evaluate the clinical effects with increasing stimulation voltage and to determine symptom reduction and the clinical therapeutic and side effect thresholds at each measurement point.

Staged surgery was performed in this female patient for two main reasons. One, extra precaution was taken as the particular case was being performed for the first time in the hospital. Second, the efficacy of VIM thalamic DBS needs to be ascertained before going into the other side as the tremors were still present at rest. This patient showed disabling resting and positional tremors and not intentional tremors. Her tremors do not respond to medical therapy, and DaTscan did not show typical finding of Parkinson's disease. Finally, her tremor was considered to be essential but not so typical. In subthalamic nucleus DBS surgery, staged bilateral procedure had less adverse effect than simultaneous one.<sup>[16]</sup>

## Conclusion

We performed a VIM thalamotomy in a patient with bilateral ETs. Using semi-microelectrode recordings, rhythmic discharges corresponding to the tremor rhythm were observed in a wide area around the VIM nucleus of the thalamus, suggesting involvement of this site in the tremors. The tremors resolved after coagulation of these thalamic neurons, which was done in a staged fashion.

## Declaration of patient consent

The authors certify that they have obtained all appropriate patient consent forms. In the form the patient(s) has/have given his/her/their consent for his/her/their images and other clinical information to be reported in the journal. The patients understand that their names and initials will not be published and due efforts will be made to conceal their identity, but anonymity cannot be guaranteed.

## Financial support and sponsorship

Nil.

## Conflicts of interest

There are no conflicts of interest.

## References

1. Alesch F, Pinter MM, Hellscher RJ, Fertl L, Benabid AL, Koos WT, *et al.* Stimulation of the ventral intermediate thalamic nucleus in tremor dominated Parkinson's disease and essential tremor. *Acta Neurochir (Wien)* 1995;136:75-81.
2. Foote KD, Seignourel P, Fernandez HH, Romrell J, Whidden E, Jacobson C, *et al.* Dual electrode thalamic deep brain stimulation for the treatment of posttraumatic and multiple sclerosis tremor. *Neurosurgery* 2006;58:ONS-280-5.
3. Berk C, Carr J, Sinden M, Martzke J, Honey CR. Thalamic deep brain stimulation for the treatment of tremor due to multiple sclerosis: A prospective study of tremor and quality of life. *J Neurosurg* 2002;97:815-20.
4. Hirai T, Miyazaki M, Nakajima H, Shibasaki T, Ohye C. The correlation between tremor characteristics and the predicted volume of effective lesions in stereotaxic nucleus ventralis intermedialis thalamotomy. *Brain* 1983;106(Pt 4):1001-18.
5. Nguyen JP, Degos JD. Thalamic stimulation and proximal tremor. A specific target in the nucleus ventrointermedialis thalami. *Arch Neurol* 1993;50:498-500.
6. Krauss JK, Mohadjer M, Nobbe F, Mundinger F. The treatment of posttraumatic tremor by stereotactic surgery. Symptomatic and functional outcome in a series of 35 patients. *J Neurosurg* 1994;80:810-9.
7. Wishart HA, Roberts DW, Roth RM, McDonald BC, Coffey DJ, Mamourian AC, *et al.* Chronic deep brain stimulation for the treatment of tremor in multiple sclerosis: Review and case reports. *J Neurol Neurosurg Psychiatry* 2003;74:1392-7.
8. Starr PA, Vitek JL, Bakay RA. Deep brain stimulation for movement disorders. *Neurosurg Clin N Am* 1998;9:381-402.
9. Vitek L. Stereotaxic surgery and deep brain stimulation for Parkinson's disease and movement disorders. In: Watts RL, Koller WC, editors. *Movement Disorders: Neurologic Principles and Practice*. New York: McGraw-Hill; 1997. p. 237-55.
10. Benabid AL, Pollak P, Gervason C, Hoffmann D, Gao DM, Hommel M, *et al.* Long-term suppression of tremor by chronic stimulation of the ventral intermediate thalamic nucleus. *Lancet* 1991;337:403-6.
11. Blond S, Caparros-Lefebvre D, Parker F, Assaker R, Petit H, Guieu JD, *et al.* Control of tremor and involuntary movement disorders by chronic stereotactic stimulation of the ventral intermediate thalamic nucleus. *J Neurosurg* 1992;77:62-8.
12. D'Haese PF, Cetinkaya E, Konrad PE, Kao C, Dawant BM. Computer-aided placement of deep brain stimulators: From planning to intraoperative guidance. *IEEE Trans Med Imaging* 2005;24:1469-78.
13. Finnis KW, Starreveld YP, Parrent AG, Sadikot AF, Peters TM. Three-dimensional database of subcortical electrophysiology for image-guided stereotactic functional neurosurgery. *IEEE Trans Med Imaging* 2003;22:93-104.
14. Bjartmarz H, Rehnrona S. Comparison of accuracy and precision between frame-based and frameless stereotactic navigation for deep brain stimulation electrode implantation. *Stereotact Funct Neurosurg* 2007;85:235-42.
15. Miyagi Y, Okamoto T, Morioka T, Tobimatsu S, Nakanishi Y, Aihara K, *et al.* Spectral analysis of field potential recordings by deep brain stimulation electrode for localization of subthalamic nucleus in patients with Parkinson's disease. *Stereotact Funct Neurosurg* 2009;87:211-8.
16. Tanei T, Kajita Y, Kaneoke Y, Takebayashi S, Nakatsubo D, Wakabayashi T, *et al.* Staged bilateral deep brain stimulation of the subthalamic nucleus for the treatment of Parkinson's disease. *Acta Neurochir (Wien)* 2009;151:589-94.