

Successful treatment of malignant pheochromocytoma with sacrum metastases

A case report

Shuzhong Liu, MD^a, Xi Zhou, MD^a, An Song, MD^b, William A. Li, MD^c, Radhika Rastogi, MD^c, Yipeng Wang, MD^{a,*}, Yong Liu, MD^{a,*}

Abstract

Rationale: Malignant pheochromocytoma in the spine is a rare disease without standard curative managements so far. The objective of this article is to report a very rare case of malignant pheochromocytoma with sacrum metastases causing severe lumbosacral pain, which was presented with acute radiculopathy and treated with three operations combined with cement augmentation and stabilization. The management of these unique cases has yet to be well-documented.

Patient concerns: A 58-year-old man presented with lumbosacral pain, radiating pain and numbness of the right extremity. The patient underwent excision of right adrenal pheochromocytoma in 2010. Imaging studies revealed the density of soft tissues, obvious bony destruction in the sacrum, and significant spinal cord obstruction.

Diagnoses: We believe this is the first report of malignant pheochromocytoma with sacrum metastases.

Interventions: The patient underwent tissue biopsy and osteoplasty after embolization of the internal iliac artery in January 2015, and exploratory surgery, circumferential spinal cord decompression, and a stabilization procedure via a posterior approach in June 2015 due to spinal canal stenosis caused by cement. Since the position of pedicle screw was not good enough, a revision surgery was performed the next day following the procedures in June 2015.

Outcomes: The patient's neurological deficits improved significantly after the third surgery, and the postoperative period was uneventful at the three-year follow-up visit.

Lessons: We recommend the posterior approach for spinal decompression of the metastatic pheochromocytoma when the tumor has caused neurological deficits. Osteoplasty by cement augmentation is also a good choice for surgical treatment. However, the potential risk of complications in bone cement applications need to be fully recognized.

Abbreviations: CT = computed tomography, ICU = intensive care unit, MIBG = metaiodobenzylguanidine, MRI = magnetic resonance imaging, T1WI = T1-weighted image, T2WI = T2-weighted image, VAS = visual analogue scale.

Keywords: cement augmentation, metastatic spinal pheochromocytoma, revision surgery, sacrum, stabilization, surgical treatment

1. Introduction

Pheochromocytomas are metabolically-active tumors originating from the chromaffin cells of the adrenal medulla. It was reported that 5-year survival rates range from 84% to 96% for benign pheochromocytoma, to about 40% for malignant form.^[1]

Malignant forms that can affect any part of the body, account for nearly 10% of all cases with the lymph nodes, liver, and lungs being the most common sites of metastasis.^[2] Metastatic spread to the spine, however, is extremely rare. In the spinal region, the most commonly affected segment is the thoracic region.

Editor: N/A.

SZL, XZ, and AS have contributed equally to this work.

Ethic statement: Written informed consent was obtained from the patient for publication of this article, a copy of which is available for review from the editors of Medicine. Because this article does not involve any human or animal trials, it did not require institutional ethical review and approval.

The authors have no conflicts of interest to disclose.

^a Department of Orthopaedic Surgery, Peking Union Medical College Hospital, Peking Union Medical College and Chinese Academy of Medical Sciences, ^b Department of Endocrinology, Key Laboratory of Endocrinology, National Health and Family Planning Commission, Peking Union Medical College Hospital, Chinese Academy of Medical Science & Peking Union Medical College, Beijing, People's Republic of China, ^c Department of Neurosurgery, Wayne State University School of Medicine, Detroit, Michigan.

* Correspondence: Yong Liu and Yipeng Wang, Department of Orthopaedic Surgery, Peking Union Medical College Hospital, Peking Union Medical College and Chinese Academy of Medical Sciences, No. 1 Shuaifuyuan Wangfujing, Beijing 100730, People's Republic of China (e-mails: liuyong_pumch@126.com; ypwang_pumch@163.com).

Copyright © 2018 the Author(s). Published by Wolters Kluwer Health, Inc.

This is an open access article distributed under the terms of the Creative Commons Attribution-Non Commercial License 4.0 (CCBY-NC), where it is permissible to download, share, remix, transform, and buildup the work provided it is properly cited. The work cannot be used commercially without permission from the journal.

Medicine (2018) 97:35(e12184)

Received: 30 April 2018 / Accepted: 10 August 2018

<http://dx.doi.org/10.1097/MD.00000000000012184>

Metastatic spread to the sacral spine is one of its rare manifestations. Recurrences and metastases are common to be seen in patients with malignant pheochromocytomas. In fact, only 18 cases of metastatic pheochromocytoma of the spine have been reported in literature so far.^[3–5]

To the best of our knowledge, this is the first reported case of metastatic pheochromocytoma to sacrum in a man presenting with back pain and radiculopathy, who underwent totally 3 operations combined with cement augmentation and stabilization. In the follow-up visit, the patient's conditions improved significantly postoperatively. After reviewing pertinent literatures, we discussed common perioperative considerations in patients with significant metastatic pheochromocytomas to the spine and management considerations for perioperative complications.

2. Case presentation

In November of 2014, a 58-year-old man presented to our hospital, with progressive back pain, radiating pain, and numbness of his right lower limb. The patient underwent excision of his right adrenal pheochromocytoma in another hospital in 2010. In the medical journal of his current illness, the patient stated he had been experiencing a worsening numbness and radiating pain of his right lower limb for approximately 10 days, and he had also experienced paroxysmal and severe back pain for approximately 2 months. The pain in his back can reach 6 to 7 points using visual analogue scale (VAS) and cannot be alleviated with rest and hot compresses. The patient denied experiencing any loss of consciousness, chest palpitations, diaphoresis, paresthesia, headaches, fatigue, facial flushing, and other constitutional symptoms. Upon further questioning,

he recalled a history of paroxysmal hypertension above 160/110 mmHg during the past 1 year. No pertinent family history was identified, including hypertension and cancer. Abdominal computed tomography (CT) revealed sacral lesions, with high suspicion of spinal metastases. After consulting the Department of Endocrinology, he was discharged from our hospital with a prescription of 10 mg of phenoxybenzamine twice a day to control his blood pressure until he could be admitted again for surgery.

On physical exam, the patient showed pressure pain and percussion pain in his sacral region, decreased sensation to pinprick and fine-touch of his right lower limb and exhibited an 5-/5 strength in his bilateral lower limbs. Deep tendon reflexes revealed normal for knee jerk and Achilles tendon reflexes bilaterally. Ataxia, cranial nerves, mini mental, and the rest of the neurological exam showed no abnormalities. Preoperative hemodynamic and cardiovascular assessments included electrocardiogram, echocardiogram, and chest radiography. Preoperative laboratory assessment was conducted, including routine laboratory tests (electrolytes, liver and kidney function tests, complete blood count), tumor markers, and endocrinological evaluation. The results of the laboratory studies were almost within normal range, except the urinary epinephrine levels were significantly elevated to 151.24 $\mu\text{g}/24\text{ h}$ (normal: 1.74–6.42 $\mu\text{g}/24\text{ h}$). Genetic investigation was negative for RET, VHL, SDHB, SDHC, SDHD mutations. Spinal CT were ordered to visualize the metastatic lesions, assess the stability of the vertebral column, and to aid in the formulation of a surgical approach. CT of the spine showed the density of soft tissue, obvious bony destruction in the sacrum, and spinal cord compression secondary to the mass, with increased metastatic marrow infiltration of the sacrum (Fig. 1A–D). Tumor infiltrated through the sacrum body into the posterior elements, thus

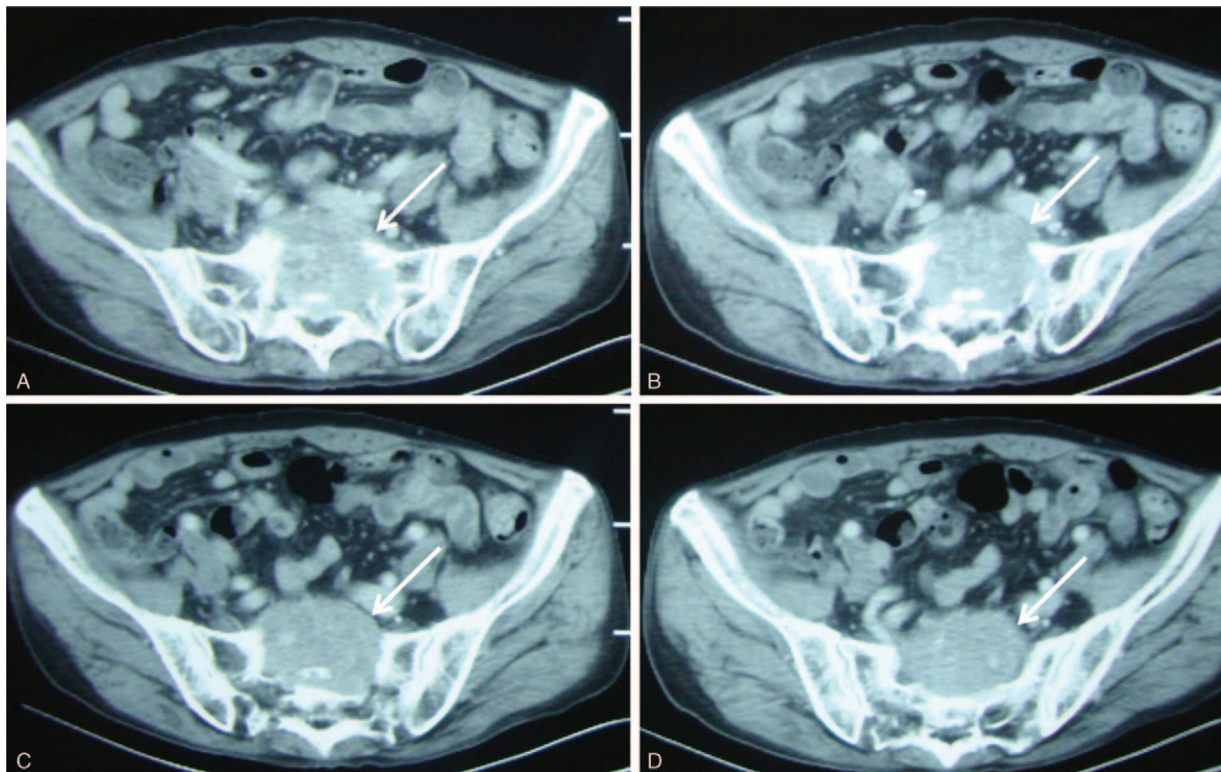


Figure 1. (A–D) Computed tomography revealed destruction of sacrum and spinal cord compressions caused by metastatic malignant pheochromocytoma.

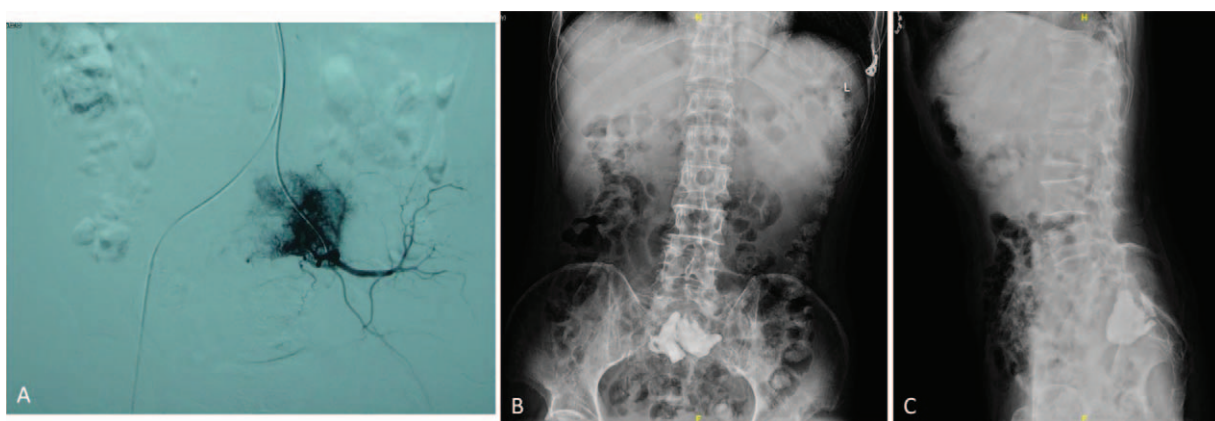


Figure 2. (A) Embolization of the internal iliac artery was performed under local anesthesia. (B) Posteroanterior (PA) x-ray image of the spine obtained postoperatively. (C) Lateral x-ray image of the spine obtained postoperatively.

extraosseously spread into the right lateral aspect of the epidural space extending posteriorly, resulting in spinal cord compression (Fig. 1A–D). The bone scanning revealed high intake in the sacral spine, with high suspicion of metastatic pheochromocytoma.

Subsequently, cement augmentation was performed to destroy the functional tumor and stabilize the spine the day after the embolization of the internal iliac artery under local anesthesia (Fig. 2A). The blood pressure and heart rate markedly increased to 220/150 mmHg and 140 beats/min, respectively, when the needle penetrated the tumor, and gradually decreased to normal within 5 minutes. Pathological examination confirmed the diagnosis of malignant pheochromocytoma. Postoperatively, x-ray and CT image of the spine revealed part of bone cement leaked into the spinal canal (Fig. 2B and C). Thus, the patient experienced pain relief but no improvement of leg numbness. The patient was unwilling to undertake any further treatments and was discharged and monitored on an outpatient basis.

The dosage of phenoxybenzamine was gradually reduced, and was stopped 2 months later. Six months later, due to the radiating pain and numbness of his lower limbs caused by the leakage of

bone cement into the spinal canal, surgical decompression was performed to improve the impairment caused by the cement (Fig. 3A–F). We performed a circumferential decompression procedure of the sacral metastasis to alleviate the symptoms caused by the spinal cord compression and subsequently stabilize the vertebral spine to prevent multiple vertebral bodies from collapse. In brief, posterior circumferential decompression, L4, L5, and ilium internal fixation were performed. After general anesthesia induction and intubation, the patient was placed in a prone position for dorsal access to the sacrum spine. For the posterior approach, the muscles were detached gently on each side after a midline longitudinal incision over the spinous processes. The pedicle entry points were exposed by step-by-step bilateral dissection. At the L5–S2 level, the stenosis of the spinal canal, the cohesion of the joint process on S1, the stenosis of bilateral lateral recess, and the epidural compression by the cement were found during operation. At first, we removed the upper articular process of S1, the residual bone protrusion in the spinal canal, the hyperplasia of ligamentum flavum, and the bone cement significantly compressing the S1 nerve root and dura

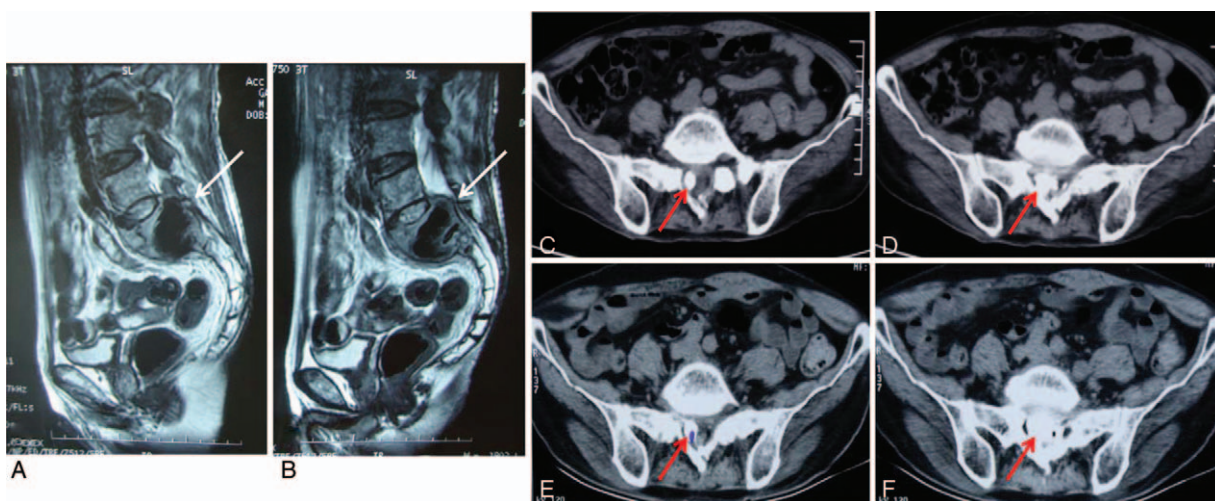


Figure 3. (A, B) Postoperative sagittal T2-weighted MRI scan in January, 2015. (C, D) Computed tomography of the sacral spine obtained postoperatively. (E, F) Computed tomography of the sacral spine obtained 6 months after the first surgery. MRI=magnetic resonance imaging.

mater. Then, the pedicle screws were placed bilaterally at L4 and L5, followed by pedicle screw insertion at ilium. Because the patient did not exhibit hemodynamic instability to the placement of the pedicle screws, fixation using a Moss SI screw-rod system was employed. Likewise, neither dissection nor screw insertion resulted in significant alterations of the blood pressure or cardiac dysfunction parameters. Visual inspection using the intraoperative fluoroscopy showed optimal position of all pedicle screws. The incision was closed afterwards. Perioperative blood pressure was stable, and intraoperative blood loss was approximately 800 mL, therefore, we used erythrocyte 4U.

After surgery, the patient showed evenly decreased sensation to pin-prick and fine-touch of bilateral lower limbs and exhibited a 2/5 strength in the right side, and 4/5 strength in the left side. An emergency lumbar de metal artifact CT examination showed that the position of the right pedicle screw at L5 was not good enough and might stimulate the nerve root (Fig. 4A–F). Then the revision and adjustment of the internal fixation were performed under general anesthesia. Visual inspection using the intraoperative fluoroscopy showed optimal position of all pedicle screws (Fig. 5A and B). The incision was closed. Perioperative blood pressure was stable, and intraoperative blood loss was

approximately 300 mL. Postoperatively, the patient was referred to the intensive care unit (ICU). The patient's course in the ICU was uneventful, and he was transferred to the regular ward on the second day. An x-ray after the surgery also confirmed the correct positioning of the implants and no signs of displacement of the screws and rods (Fig. 5C and D). The postoperative pathology report confirmed a malignant pheochromocytoma (Fig. 6A–H). Pathological analysis was positive for chromogranin A, synaptophysin, S-100, CD56 (NK-1), and p53 indicating pheochromocytoma from chromaffin cells of the adrenal medulla. Biopsy samples were negative for Melan-A, AE1/AE3, with 5% Ki-67 positive nuclei (Fig. 6I). Consequently, malignant pheochromocytoma with sacrum metastases was diagnosed via history taking, laboratory values, imaging results, and pathological studies.

One week after the third operation, the patient's muscle strength of lower extremities improved to grade V compared with the preoperative status, and the symptoms were relieved significantly. Moreover, VAS score of his back pain improved to 0 to 1 points compared with the preoperative status, 6 to 7 points. Postoperatively, the patient underwent rehabilitation therapy and was prescribed phenoxybenzamine, 10 mg TID for blood pressure management. As the patient did not develop

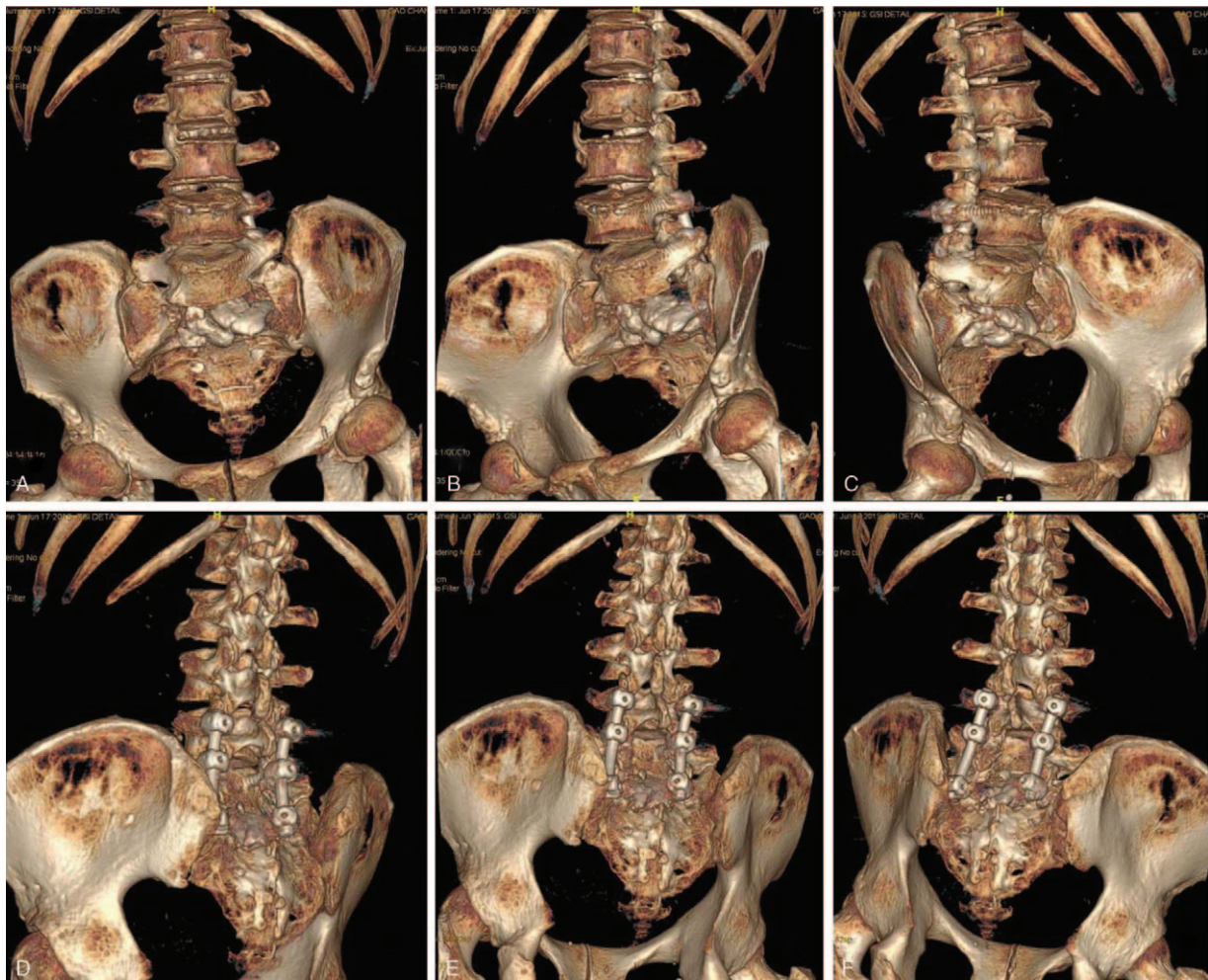


Figure 4. (A–F) An emergency lumbar de metal artifact CT examination showed that the position of the right pedicle screw at L5 was not good enough and might stimulate the nerve root. CT=computed tomography.

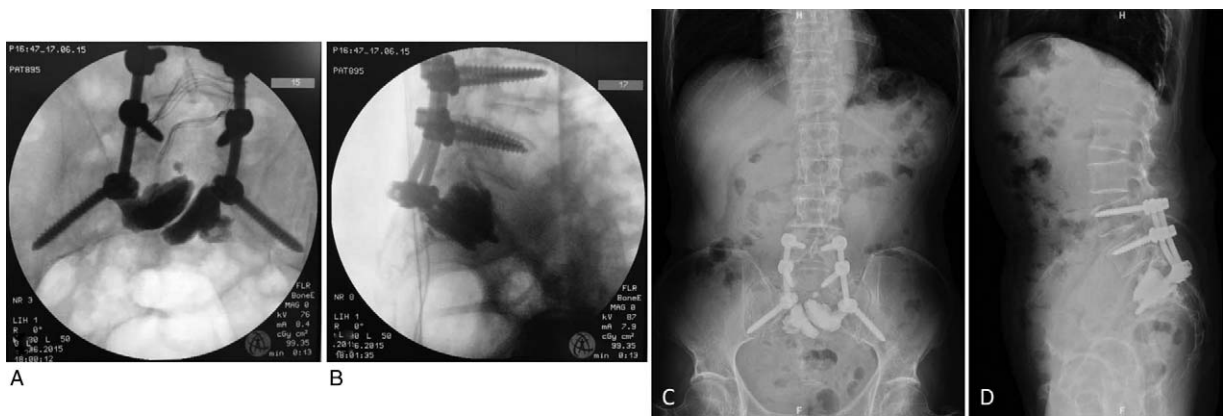


Figure 5. (A, B) Visual inspection using the intraoperative fluoroscopy showed optimal position of all pedicle screws. (C) Posteroanterior (PA) x-ray image of the sacrum obtained postoperatively. (D) Lateral x-ray image of the sacral spine obtained postoperatively.

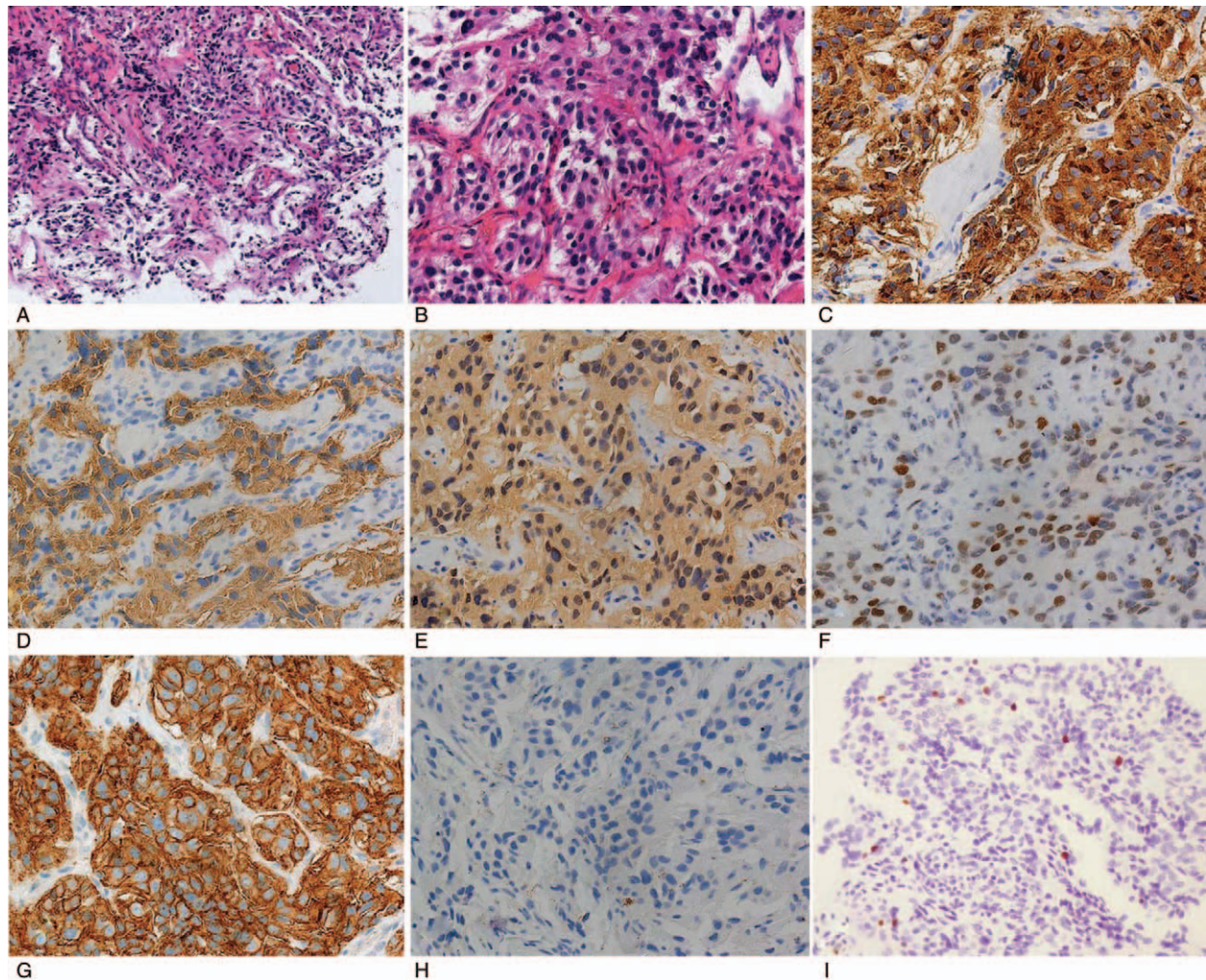


Figure 6. Pathologic histology of spinal metastases. (A, B) Microphotography showing characteristic nests of tumor cells separated by vascular septa (Zellballen) with cells showing significant nuclear pleomorphism with prominent nucleoli (H&E, original magnification 20 \times and 40 \times). (C) Chromogranin A immunostaining is strongly positive in the chromaffin cells. Chromogranin A is present in the secretory granules. (D) Synaptophysin immunostaining shows strong, diffuse cytoplasmic staining in the tumor cells. (E) The sustentacular cells of the spinal metastases of pheochromocytoma showing characteristic staining of S100. (F) P-53 immunostaining is sporadically positive. (G) The sustentacular cells of the spinal metastases of pheochromocytoma showing characteristic staining of CD56 (NK-1). (H) AE1/AE3 immunostaining is negative. (I) Ki-67 immunostaining shows 5% Ki-67 positive cells. Ki-67 staining is localized in the tumor nuclei.

severe adverse effects, he was discharged and was monitored as an outpatient. The postoperative 3-year follow-up visit showed no tumor progression and no new symptoms. The blood pressure remained stable (<140/90 mmHg), due to patient's compliance to the prescribed medications. To date, the patient has no recurrent symptoms in 3 years of follow-up. The latest urine catecholamine was 21.43 $\mu\text{g}/24\text{h}$. There were no other complications associated with these 3 operations during the follow-up period.

3. Discussion

Pheochromocytomas are rare tumors arising from the chromaffin cells predominantly within the adrenal glands. The incidence of pheochromocytomas is approximately 0.2 to 0.9 case per 100,000 individuals per year, and the malignant forms account for approximately 10% of all cases.^[1,2] Typical manifestations include headaches, palpitations, paresthesia, fatigue, flushing, perspiration, or paroxysmal hypertension. Among the above symptoms, paroxysmal hypertension can often mimic the most common cause of elevated blood pressure, making timely diagnosis of pheochromocytoma difficult without a high level of suspicion.^[6] Few reports of malignant pheochromocytomas metastatic spread to the spine causing clinical symptoms have been documented so far. The location of the spinal lesion determines the neurological deficits, and there is a great deal of variability. Moreover, back pain is also a common symptom and it may make the differential diagnosis more difficult. Pheochromocytoma may become malignant via their metastatic tendency, and the metastases can help us diagnose a malignant pheochromocytoma. Clinical studies looking at metastatic pheochromocytoma to the spine is lacking due to the extremely low incidence rate. Imaging studies including CT, magnetic resonance imaging (MRI), and bone scan are non-specific, making it difficult to differentiate metastatic spinal pheochromocytoma from other common spinal lesions. However, imaging studies may play a crucial role in the decision making of surgical intervention. The "gold-standard" diagnosis of pheochromocytoma relies on pathological findings. Based on our review of the 18 case reports on PubMed,^[3-5,6-14] metastatic pheochromocytoma of the spine is slightly more common in the thoracic region and are more commonly diagnosed during the fourth and the fifth decades of life for the sporadic form.^[15] There is yet a consensus on the treatment for metastatic pheochromocytomas in the spine due to insufficient amount of case studies.

Surgery is the best treatment for metastatic spinal pheochromocytomas causing back pain, radiculopathy, and paralysis.^[16-18] This protocol enables accomplishment of 2 objectives: it alleviates the neurological deficits by decompressing the stenosis while provides histopathological specimens for diagnosis at the same time.^[19] Nevertheless, there are several considerations to be kept in mind when deliberating on surgical intervention to malignant pheochromocytoma with spinal metastasis, including preoperative hemodynamic instability and cardiac arrhythmia control, possible incomplete tumor resection, intraoperative blood loss, and hemodynamic instability, as well as postoperative adjuvant therapy. During the preoperative period, patients should receive alpha blockade with phenoxybenzamine for at least 4 weeks with a blood pressure goal of 140/90 mmHg, and their cardiovascular functions should also be monitored.

As the tumor is highly vascular, there may be significant intraoperative blood loss which may influence the hemodynamic instability and necessitate blood transfusion. Intraoperative blood loss can be significantly minimized by applications of

preoperative alpha blockade and preoperative transarterial embolization of the main feeders.^[20,21] As seen in some studies, preoperative embolization used to reduce intraoperative blood loss and operative time is commonly performed under general anesthesia via a trans-arterial approach. Intraoperative blood loss and perioperative transfusion can be effectively reduced by preoperative embolization in patients with spinal metastatic pheochromocytomas.^[22,23] As reported in literature, surgery is recommended to be performed by surgeons within 24 hours after the embolization. A review of literature revealed that the risk of hemodynamic instability is prominent during the resection of an active lesion. Fluctuations in heart rate and blood pressure can result from anesthesia induction and tumor manipulation.^[13,14,24] Thus, unnecessary manipulation of the metastatic lesions should be avoided, as it can encourage the tumor to spread to adjacent tissues and promote catecholamine release, causing hemodynamic complications.

To date, surgical management of malignant pheochromocytoma of spine has remained under evaluation, with no standard criteria. Osteoplasty by cement augmentation may be a treatment option for patients with metastatic pheochromocytoma in the spine, who cannot undergo appropriate surgery or decline open surgery.^[25] However, we need to fully recognize the potential risk of complications in bone cement applications. The safety of this approach still needs to be confirmed in further studies with larger sample sizes and longer follow-up periods. One postoperative complication was cement leakage into the canal and subsequent spinal cord compression.^[13,25] Under this circumstance, surgical extent, cement volume, and postoperative complications are critical factors that need further investigation.^[25]

The survival benefit of resection of spinal metastases is still unproven. However, such a procedure does have the benefit aiming at controlling residual tumor.^[13,14] The improved survival benefited from reducing the tumor burden, decompressing the spinal stenosis to alleviate radiculopathy, and facilitating subsequent chemotherapy and radiation therapy. Due to its rarity, the chemotherapy regimes have not reached a consensus. Common chemotherapy drugs include Cisplatin, Etoposide, Cytosar, vincristine, and dacarbazine.^[1,14] Moreover, recurrence and metastasis are common postoperative complications, which we are anticipating may occur in our patient. They account for a significant percentage of morbidity following resection of metastatic pheochromocytoma in the spine.^[1]

In conclusion, we expect that this report can draw the attention from the research community to how we diagnosed and managed a patient with pheochromocytoma and secondary spinal cord metastases presenting with symptoms of compression caused by cement. Although uncommon, metastatic pheochromocytoma of the spine should be part of the differential diagnosis when the patient presents with back pain and neurological deficits together with hypertension, and pathological examination remain the "gold standard" for diagnosing malignant pheochromocytoma. As preoperative embolization is relatively safe and effective for controlling intraoperative bleeding, it is highly recommended for surgical treatment of spinal metastatic pheochromocytomas or paragangliomas.^[22,23] Moreover, osteoplasty by cement augmentation is also a good choice for surgical treatment. However, we need to take the potential risk of complications in bone cement applications into full consideration.^[13,25] To the best of our knowledge, this is the first report of malignant pheochromocytoma with sacrum metastases. Our patient was treated with 3 operations totally combined with cement augmentation and stabilization, and we also performed preoperative transarterial

embolization of the main feeders of the tumor to reduce intraoperative blood loss. The management of this unique disorder has yet to be well-documented. This case report has a number of limitations. Firstly, we did not perform a total resection of the spinal metastasis at one-stage operation, mainly due to the high risks associated with the surgical procedure. Secondly, multiple operations are likely to increase the risk of tumor metastasis and recurrence. Last, the combined treatment was not initiated in our patient because the patient chose not to undergo other further treatments. With a multidisciplinary team approach, proper planning, and adequate perioperative medical management, metastatic pheochromocytoma in the spine can be managed much more effectively.

Author contributions

Conceptualization: Shuzhong Liu, Yong Liu.

Investigation: Shuzhong Liu, Xi Zhou, An Song, Yong Liu.

Resources: Shuzhong Liu, Yong Liu.

Supervision: Yipeng Wang, Yong Liu.

Writing – original draft: Shuzhong Liu, Xi Zhou, An Song, William A. Li, Radhika Rastogi, Yong Liu.

Writing – review & editing: Shuzhong Liu, William A. Li, Yipeng Wang, Yong Liu.

References

- [1] Kaloostian PE, Zadnik PL, Kim JE, et al. High incidence of morbidity following resection of metastatic pheochromocytoma in the spine. *J Neurosurg Spine* 2014;20:726–33.
- [2] Kaloostian PE, Zadnik PL, Awad AJ, et al. En bloc resection of a pheochromocytoma metastatic to the spine for local tumor control and for treatment of chronic catecholamine release and related hypertension. *J Neurosurg Spine* 2013;18:611–6.
- [3] Kheir E, Pal D, Mohanlal P, et al. Cervical spine metastasis from adrenal pheochromocytoma. *Acta Neurochir (Wien)* 2006;148:1219–20.
- [4] Mori S, Okura T, Kitami Y, et al. A case of metastatic extra-adrenal pheochromocytoma 12 years after surgery. *Hypertens Res* 2002;25:141–4.
- [5] Yurt A, Arda MN, Vardar E. Metastatic pheochromocytoma of the thoracic spinal extradural space. Case report and review of the literature. *Kobe J Med Sci* 2005;51:49–53.
- [6] Teno S, Tanabe A, Nomura K, et al. Acutely exacerbated hypertension and increased inflammatory signs due to radiation treatment for metastatic pheochromocytoma. *Endocr J* 1996;43:511–6.
- [7] Yamaguchi S, Hida K, Nakamura N, et al. Multiple vertebral metastases from malignant cardiac pheochromocytoma - case report. *Neurol Med Chir (Tokyo)* 2003;43:352–5.
- [8] Siddiqui MZ, Von Eyben FE, Spanos G. High-voltage irradiation and combination chemotherapy for malignant pheochromocytoma. *Cancer* 1988;62:686–90.
- [9] Rittirsch D, Battagay E, Zimmerli LU, et al. Cement-augmented dorsal instrumentation of the spine as a safe adjunct to the multimodal management of metastatic pheochromocytoma: a case report. *Patient Saf Surg* 2012;6:1.
- [10] Kato H, Suzuki M, Mukai M, et al. Clinicopathological study of pheochromocytoma of the urinary bladder: immunohistochemical, flow cytometric and ultrastructural findings with review of the literature. *Pathol Int* 1999;49:1093–9.
- [11] Kasliwal MK, Sharma MS, Vaishya S, et al. Metachronous pheochromocytoma metastasis to the upper dorsal spine-6-year survival. *Spine J* 2008;8:845–8.
- [12] Hamdan A, Hirsch D, Green P, et al. Pheochromocytoma: unusual presentation of a rare disease. *Isr Med Assoc J* 2002;4:827–8.
- [13] Cai S, Kong X, Yan C, et al. Successful treatment of metastatic pheochromocytoma in the spine with cement augmentation. *Medicine (Baltimore)* 2017;96:e5892.
- [14] Liu S, Song A, Zhou X, et al. Malignant pheochromocytoma with multiple vertebral metastases causing acute incomplete paralysis during pregnancy: literature review with one case report. *Medicine (Baltimore)* 2017;96:e8535.
- [15] Guerrero MA, Schreinemakers JM, Vriens MR, et al. Clinical spectrum of pheochromocytoma. *J Am Coll Surg* 2009;209:727–32.
- [16] Lau D, La Marca F, Camelo-Piragua S, et al. Metastatic paraganglioma of the spine: case report and review of the literature. *Clin Neurol Neurosurg* 2013;115:1571–4.
- [17] Yang C, Li G, Fang J, et al. Clinical characteristics and surgical outcomes of primary spinal paragangliomas. *J Neurooncol* 2015;122:539–47.
- [18] Lee JH, Stein M, Roychowdhury S. Percutaneous treatment of a sacral metastasis with combined embolization, cryoablation, alcohol ablation and sacroplasty for local tumor and pain control. *Interv Neuroradiol* 2013;19:250–3.
- [19] Laufer I, Edgar MA, Hartl R. Primary intraosseous paraganglioma of the sacrum: a case report. *Spine J* 2007;7:733–8.
- [20] Bruynzeel H, Feelders RA, Groenland TH, et al. Risk factors for hemodynamic instability during surgery for pheochromocytoma. *J Clin Endocrinol Metab* 2010;95:678–85.
- [21] Ahlman H. Malignant pheochromocytoma: state of the field with future projections. *Ann N Y Acad Sci* 2006;1073:449–64.
- [22] Cernoch P, Hechelhammer L, von Hessling A, et al. Pre-operative embolisation of spinal metastasis: technique, complication rate and outcome-clinical experience. *Int Orthop* 2015;39:1399–404.
- [23] Pikiš S, Itshayek E, Barzilay Y, et al. Preoperative embolization of hypervascular spinal tumors: current practice and center experience. *Neurol Res* 2014;36:502–9.
- [24] Eisenhofer G, Schott M, Bornstein S. Pheochromocytoma and paraganglioma: recent progress and new vistas for improved patient care. *Horm Metab Res* 2012;44:325–7.
- [25] Liu S, Zhou X, Song A, et al. Successful treatment of Gorham-Stout syndrome in the spine by vertebroplasty with cement augmentation: a case report and literature review. *Medicine (Baltimore)* 2018;97:e11555.