



Case Report

Follicular thyroid carcinoma with tumour thrombus extending into superior vena cava and right atrium – A case report

Geetesh Manik^{a,*}, John Jose^b, B. Hygriv Rao^c^a Krishna Institute of Medical Sciences, Hyderabad, India^b Christian Medical College, Vellore, India^c Division of Pacing & Electrophysiology, Krishna Institute of Medical Sciences, Hyderabad, India

ARTICLE INFO

Article history:

Received 8 March 2016

Accepted 31 May 2016

Available online 11 June 2016

Keywords:

Tumour thrombus

Superior vena cava

Thyroid carcinoma

ABSTRACT

Intra-cardiac extension of tumour thrombus of follicular carcinoma of thyroid is uncommon. We report a case of advanced thyroid carcinoma where tumour thrombus was well profiled with CT scan and transesophageal echo images and extension was noted from SVC into right atrium, with clinical features of superior vena cava syndrome. The clinical significance of the “ring sign” is discussed.

© 2016 Cardiological Society of India. Published by Elsevier B.V. This is an open access article under the CC BY-NC-ND license (<http://creativecommons.org/licenses/by-nc-nd/4.0/>).

1. Introduction

According to the nationwide data from National Cancer Registry Program, thyroid carcinoma constitutes 0.1–0.2% of all cancers.¹ Follicular carcinoma, which is the second most common thyroid carcinoma, has microscopic characteristic of angioinvasion but direct extension of tumour thrombus, i.e. collective form of intra-vascular metastases with thrombotic elements into caval veins and heart via cervical veins, is extremely uncommon. In the literature, only few cases have been reported where the patient underwent successful surgical resection of tumour thrombus; most of them succumbed to death as a result of vascular or cardiac involvement.² We report a case where correlative images from transesophageal echo and CT scans profiled the angioinvasion and intra-cardiac extension of a follicular thyroid carcinoma, with the CT demonstrating the “ring sign” indicating freedom from local invasion, thereby making transcervical resection of tumour and avoiding radical excision.

2. Case report

A 65-year-old woman presented with a right-sided thyroid swelling of 6 months duration, associated with dyspnoea and dysphagia. Clinical examination showed a large lobulated mass on the right anterior neck with prominent dilated veins in the upper

chest. There was another palpable fusiform mass extending from the right jaw to the right clavicle. Fine needle aspiration cytology (FNAC) of the mass confirmed a follicular carcinoma of thyroid. Chest radiograph showed a soft tissue mass extending to the upper border of the sternum, but there was no obvious lung metastasis.

CT scan of the neck and chest showed an inhomogeneous mass extending from the right cervical region into the thoracic inlet and retrosternal area. There was an intra-luminal tumour extension into the SVC and the right atrium. The positive ring sign was noted on CT (Fig. 1A and B). Transesophageal echocardiography demonstrated the tumour thrombus projecting into right atrium from SVC (Fig. 2C and D).

The patient was advised transcervical surgical resection, but she opted for conservative treatment.

3. Discussion

The tumour thrombus is reported with certain malignant diseases like thyroid carcinoma, renal cell carcinoma, uterine carcinosarcoma, Wilm's tumour, testicular tumour, adrenal cortical carcinoma, lymphoma, pancreatic cancer, osteosarcoma and Ewing's sarcoma.³ Follicular carcinoma has the well known property of haematogenous spread; however, tumour thrombus has also been reported in papillary, follicular, insular and anaplastic cancers of thyroid.⁴ Tumour thrombus occurs by direct extension or by occult vascular spread. The tumour invades into the internal jugular vein through the thyroid veins and propagates, but the most distal portion is freely mobile and presents as a leaf-like structure similar to progression of venous thrombosis in deep

* Corresponding author.

E-mail address: geetesh.manik@gmail.com (G. Manik).

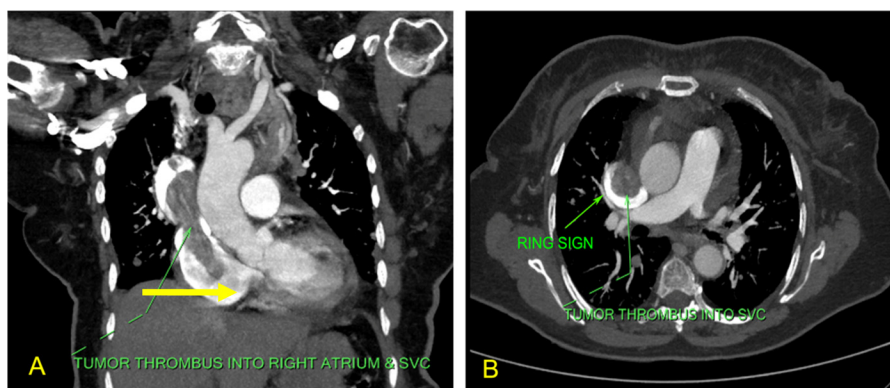


Fig. 1. (A) Computed tomography image in coronal view of the thorax showing tumour thrombus extending across the superior vena cava (SVC) into the right atrium. (B) Cross-sectional CT image of the chest showing the tumour thrombus in the SVC with the positive “Ring Sign”.

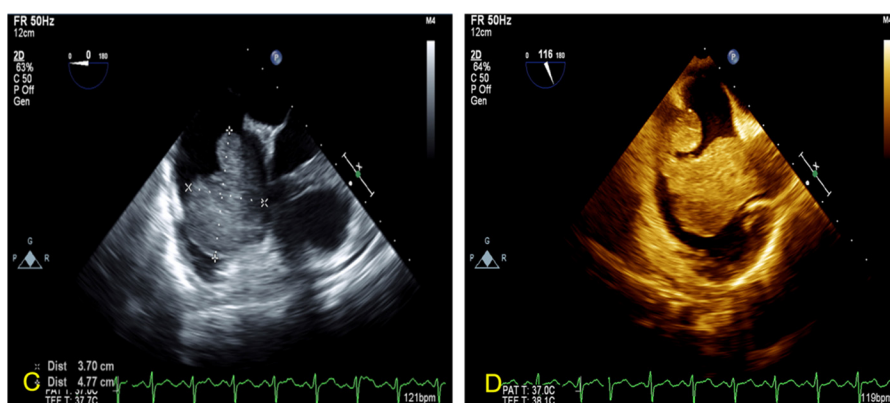


Fig. 2. (C, D) TEE image showing a 3.7 mm × 4.7 mm homogenous mass projecting into the right atrium from the SVC.

vein thrombosis. The high velocity flow in cervical veins prevent the invasion of endothelium of the great vessels, thus not allowing the tumour to lateralize and invade into the wall.⁵

The patients of thyroid carcinoma presenting with SVC obstruction should be evaluated with CT to differentiate intra-luminal extension from extrinsic compression. Radical surgery with SVC thrombectomy and reconstruction has been described in literature, but presently, transcervical approach to tumour thrombus is recommended based on the “ring sign” on CT scan. The ring sign refers to a rim of contrast demonstrable around the thrombus, which indicates that the thrombus is not adherent or invading into the endothelium lining of the great veins, thus allowing the tumour thrombus to be resected transcervically.⁵ CT images of our patient demonstrated the “ring sign” indicating that it was surgically resectable despite obvious intra-thoracic extension.

Conflicts of interest

The authors have none to declare.

Appendix A. Supplementary data

Supplementary data associated with this article can be found, in the online version, at [doi:10.1016/j.ihj.2016.05.016](https://doi.org/10.1016/j.ihj.2016.05.016).

References

- Unnikrishnan AG, Menon UV. Thyroid disorders in India: an epidemiological perspective. *Indian J Endocrinol Metab.* 2011;15(July (suppl 2)):S78–S81.
- Niederle B, Hausmaninger C, Kretschmer G, et al. Intraatrial extension of thyroid cancer: technique and results of a radical surgical approach. *Surgery.* 1990;108(December (6)):951–956. discussion 956–957.
- Lai P, Bomanji JB, Mahmood S, et al. Detection of tumour thrombus by 18F-FDG-PET/CT imaging. *Eur J Cancer Prev.* 2007;16(February (1)):90–94.
- Yoshimura M, Kawamoto A, Nakasone K, et al. Gallium-67 accumulation to the tumor thrombus in anaplastic thyroid cancer. *Ann Nucl Med.* 2003;17(December (8)):689–691.
- Taib NA, Hisham AN. Follicular thyroid carcinoma with direct tumour extension into the great cervical veins and right atrium: is transcervical thrombectomy a safe option? *Asian J Surg Asian Surg Assoc.* 2007;30(July (3)):216–219.