

# Ultrasonographically supported removal of foreign bodies of the eye lid and parapharyngeal space in a 13-year-old boy subjected to shot injuries in early childhood

## Ultraschallgestützte Entfernung von Fremdkörpern aus dem Augenlid und dem parapharyngealen Raum eines 13-jährigen Jungen mit Schussverletzungen aus der frühen Kindheit

### Abstract

**Background:** B-scan ultrasonography is widely used in diagnostics of head and neck pathologies. Ultrasonography can be applied intraoperatively to identify foreign materials.

**Case report:** This case report describes the ultrasonographic identification of foreign bodies of the eye lid and parapharyngeal space in an adolescent who was injured several years ago, obviously a victim of domestic violence. B-scan ultrasonography (small part transducer, emission frequency: 7.5 MHz) proved to be a reliable tool to locate the foreign bodies. Ultrasound imaging facilitated the decision-making of the surgical approach and thus reduced the surgical exploration time.

**Discussion:** B-scan ultrasonography is a valuable tool in oral and maxillofacial surgery. The use of B-scan ultrasonography in the head neck region requires the capacity of the surgeon to fuse the ultrasonographic picture with the topography of the head and neck. The advantages and limitations of B-scan ultrasonography in the head and neck region concerning foreign body identification are briefly discussed.

**Keywords:** domestic violence, ultrasound-guided foreign body removal, violence children, gun violence, foreign body children

### Zusammenfassung

**Hintergrund:** Die B-Bild-Ultraschalluntersuchung hat in der Kopf-Hals-Chirurgie ein weites Anwendungsfeld mehrerer chirurgischer Disziplinen. Der Ultraschall kann hier z.B. für die Lokalisation von Fremdkörpern genutzt werden.

**Fallbericht:** Dieser Fallbericht beschreibt die ultraschallgestützte Lokalisierung von Fremdkörpern des Augenlids und des parapharyngealen Raumes in einem Heranwachsenden, der bereits mehrere Jahre zuvor verletzt worden war, seinerzeit offenbar wiederholter familiärer Gewalt ausgesetzt. Die B-Bild-Sonographie unter Anwendung eines an die Untersuchungsregion angepassten Schallkopfes (Small-Part, 7,5 MHz) erwies sich als verlässliches Werkzeug der präoperativen Behandlungsplanung und der intraoperativen Lokalisierung der Fremdkörper, so dass die Anwendung des Hilfsmittels die Operationszeit verkürzte.

**Diskussion:** Die B-Bild-Sonographie ist ein wertvolles Hilfsmittel in der Kopf-Hals-Chirurgie. Die chirurgische Anwendung der B-Bild-Sonographie im Kopf-Hals-Bereich erfordert vom Behandler die Fusion des Bild-Bildes mit der Topographie der Untersuchungsregion. Vorteile und Grenzen der Ultraschallanwendung unter Bezug auf die Identifizierung von Fremdkörpern in diesem Gebiet werden kurz erörtert.

Reinhard E. Friedrich<sup>1</sup>

1 Oral and Cranio-Maxillofacial Surgery, Eppendorf University Hospital, University of Hamburg, Germany

## Introduction

B-scan ultrasound is a well established diagnostic tool in head and neck diagnostics and surgery, in particular for the diagnosis of soft tissue pathology [11], [14], [17]. High alterations of impedance of ultrasound take place at the interface of soft to hard tissues or air. This leads to a partial or complete remission of the ultrasound wave and an ultrasonographically 'shadow sign' distal to the ultrasound remitting objects. Emission frequencies of 5 to 15 MHz are typically used in the clinical setting and will usually not penetrate bone and cannot be transmitted through air. These properties would be an argument to refrain from this technique for hard tissue diagnostics. However, the remissions of ultrasound by solid objects can be used for the identification of foreign bodies. This property of ultrasound is routinely used in emergency departments and trauma surgery [1], [5], [6], [9], [11], [19].

In the head and neck region, ultrasound imaging was rapidly introduced to orbital diagnosis and surgery soon after the development of transducers applicable for this region [10]. There are only a few reports dealing with ultrasound imaging of foreign bodies of the head and neck region outside the orbital region [2], [15], [18].

This report describes the diagnostic support of ultrasonography in the treatment of a patient who was incidentally diagnosed to possess foreign bodies in the head and neck, obviously resulting from physical attacks during early childhood.

## Case report

The 13-year-old boy with no relevant medical history was presented at the oral and maxillofacial surgery department for determining the therapy for foreign bodies that were found on *alio loco* performed posterior-anterior and lateral radiographs of the skull (Figure 1A and B).

The patient was living at a children's home and the therapy had to be clarified with the youth welfare department. The child's guardian wanted to know whether the foreign bodies could cause harm to the patient, whether there were treatment risks and whether the removal of the foreign bodies was assessed to be mandatory.

On the radiographs a round foreign body with metallic absorption of X-rays was identified on the left medial border of the orbit. The lateral view suggested that the foreign body was retained in the orbital anterior part. This foreign body was presumed to be an air gun pellet.

A second foreign body was localized on the same side lateral to the vertebral column of the neck. This foreign body had also a complete absorption of X-rays as found from metallic artefacts. The shape of the foreign body in both views was that of a screw.

The medical history of the patient revealed no clear circumstances of trauma. However, the patient remembered that, at the age of about 4 years, his older brother had

shot at his head for several times from different sides, with a not identified weapon.

Physical examination of the patient revealed a firm and slightly moveable foreign body of the left medial eye lid's angle, covered by an unaffected skin (Figure 1C). Vision and movements of the eyes were unaffected. In the neck region no foreign body was palpable. However, on the dorsal left paramedian side of the neck an old scar was visible, about 15 mm in largest diameter and with irregular margins, probably an old wound that was healed by granulation without medical aid.

It was decided that these foreign bodies might give rise to an infection and that their removal should be anticipated. An additional imaging of the regions was worth striving for in order to define whether other organs might be affected during surgery. B-scan ultrasonography was chosen, as this diagnostic could be used without further X-ray exposure of the young patient. Further, B-scan ultrasound enables the imaging of soft tissues in high resolution and excellent contrast [13].

B-scan ultrasonography was carried out with a small-part transducer and an emission frequency of 7.5 MHz (Ultrasound equipment: Sonoline Omnia, Siemens AG, Erlangen, Germany; Printer CP 700, Matsushita, Kyoto, Japan). The focus of the scanner was adjusted to the region of interest.

In the left orbital region the ultrasonogram depicted a half-circled object, with the closest point of the body surface to the applicator in its geometrical midpoint. This phenomenon was reproducibly seen in different planes following several changes of the transducer's angulation to the skin. Therefore, it was likely that the foreign body had the geometrical characteristics of a sphere. It was suggested that the foreign body was an air gun pellet (Figure 2A).

In the left neck the foreign body was identified anterior and medial to the sternocleidomastoid muscle (Figure 2B). The foreign body was localized closely to the internal jugular vein. Ultrasound depicted the head of the screw that was measured to be of about 10 mm in diameter.

The skin landmark perpendicular to the screw was located about 5 cm anterior to the neck scar. Both foreign bodies were identified on the skin with landmarks.

Surgery was then performed in general anaesthesia. On the left neck a skin incision was made at the anterior border of the sternocleidomastoid muscle. The screw was lying in the fat tissue surrounding the internal jugular vein and it was attached to the inner layer of the muscle. The screw was easily removed. The eye lid's foreign body was removed after a horizontal lower eyelid incision. The spheric foreign body was embedded in a pseudocapsule. It was completely removed with this capsule (Figure 2C). Ultrasound-assisted surgical treatment planning reduced the operation time to 20 minutes. Healing was uneventful. Histology of the pseudocapsule revealed a scary tissue with strand-like calcifications, a foreign body reaction with formation of multinucleated giant-cells and a histiocyte infiltrate.

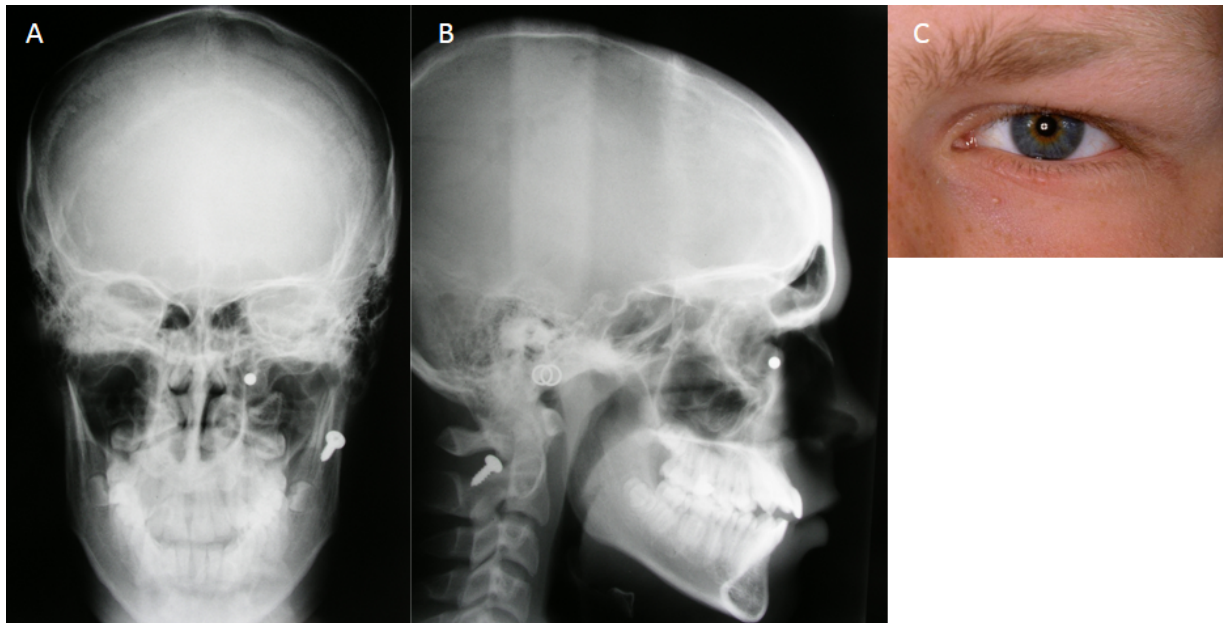


Figure 1: A. Posterior-anterior radiograph of the skull depicting the round and pellet-like radiopaque foreign body of the left orbital region and the radiopaque screw-shaped foreign body of the left paravertebral. B. Lateral radiograph of the skull indicates the position of orbital foreign body close to the infraorbital rim and the parapharyngeal screw caudal and slightly anterior to the mastoid. C. Detail of the en-face view shows that there is no visible scar indicating the entrance of the foreign body.

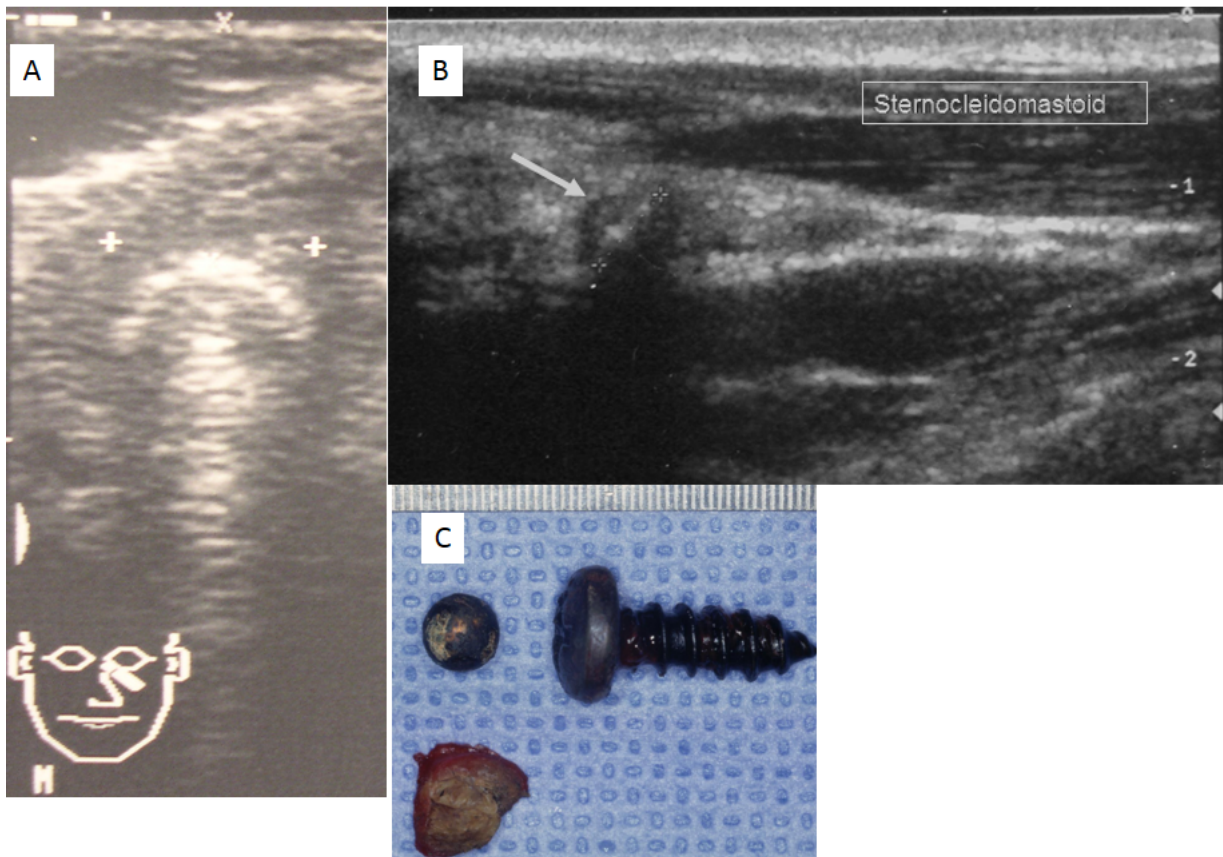


Figure 2: A. Ultrasonogram of the orbital foreign body. The skin-to-object distance is about 5 mm. The hemispheric diameter is about 9 mm. B. Ultrasonogram of the left parapharyngeal space reveals an ultrasound remitting surface in an oblique position to the surface of the applicator. Proximal to the applicator and covering the surface is a concave hypoechoic zone (arrow). C. The foreign bodies (left: airgun pellet, right: screw) and the fibrous bag that covered the screw (left below) with millimetre scale (total length of screw: 30 mm; diameter of screw head: 12 mm; pellet diameter: 9 mm).

## Discussion

This case report describes the successful application of B-scan ultrasonography in the topographic identification of foreign bodies in the head and neck region of an adolescent who was harmed about ten years ago. Ultrasonography supported the decision-making of the surgical approach and allowed a rapid intervention. This method is cost-effective and can be recommended in the treatment planning of patients with foreign bodies of the head and neck [18].

However, the application of ultrasonography in head and neck surgery is limited to areas where conduction of the applicator to the body surface is feasible and the transmission of ultrasound is not restricted. The alternate layers of soft and hard tissues, and air-filled spaces impair the application of ultrasound in craniomaxillofacial surgery. Therefore, X-ray based imaging methods are preferred in craniomaxillofacial surgery in treatment planning, intraoperative guidance and monitoring of treatment results [16], [20], [21], [23]. On the other hand, ultrasound-based imaging application can avoid (further) X-ray exposure of patients during the course of treatment.

B-scan ultrasonography uses piezoelectric transducers to generate ultrasonic waves. These waves are emitted with distinct emission frequencies at the surface of the applicator (or transducer). The transmission of the ultrasonic wave into the body is facilitated by a gel, placed on the transducer that is attached to the skin at the region of interest. The returning echoes are detected by the applicator, processed to visual analogues of ultrasound and displayed in real time on the monitor screen. Emission frequencies of 5 to 15 MHz are used for ultrasound imaging of the head and neck region [15], [17]. Ultrasound at frequencies of 5 to 15 MHz is usually not transmitted through hard tissues, e.g. bone or metal. At the interface of the transmitting body adjacent to the applicator and hard tissue a complete or partial remission of ultrasound takes place. On the monitor only the surface of the body opposite to the surface of the transducer can be seen that gives rise to ultrasound remittance [22]. In most cases this will be a small part of the structure of interest, emphasizing that clinical ultrasonography is a dynamic investigation. The details seen on B-scan ultrasonogram have to be taken *pars pro toto* to identify the structure, e.g. an osteosynthesis plate [5]. Three-dimensional ultrasound offers at least under certain circumstances a partial reconstruction of the surface of an object [14]. Ultrasonography has been also recommended to be used in the assisted removal of foreign bodies that are radiolucent [3], [7], [8], [12]. There are pathologic structures other than foreign bodies that might be radiolucent and that have to be differentiated on ultrasonograms, e.g. stones of salivary glands' ducts, calcified sinews, calcification of the carotid arteries, and remnants of head and neck surgery like vessel clips, non-resorbed sutures, further sclerosis of deep scars in the neck (in particular in irradiated patients) [4]. All these structures can cause

total or a partial reflection of the ultrasound with distal shadow formation.

Therefore, the X-ray imaging is the first-line diagnostic tool to search for foreign body in the head and neck region. X-rays allow the complete imaging of the skull, including organs and spaces that can not reliably be visualized with ultrasound, e.g. the paranasal sinuses, throat, and brain. On the other hand, ultrasonography may be the only diagnostic tool applicable in a patient, e.g. in the situation where the guardian does not allow the application of X-rays or in pregnant women. The knowledge of the appearance of physical bodies in ultrasound is mandatory prior to the application of ultrasound in diagnostics of the head and neck [22].

## Conclusions

B-scan ultrasonography is a valuable diagnostic tool to identify foreign bodies in the head and neck region. However, there are certain limitations of ultrasound, e.g. restriction to the imaging of the surface of solid foreign bodies only, and restriction to receive images in several planes perpendicular to each other in the head and neck region. Ultrasonography can be used as a complementary technique to standard radiological investigations. Application of ultrasonography is time and cost-effective. Ultrasonography supported the decision for the surgical approach [7].

## Notes

### Competing interests

The author declares that he has no competing interests.

## References

- Blankstein A, Cohen I, Heiman Z, Salai M, Heim M, Chechick A. Localization, detection and guided removal of soft tissue in the hands using sonography. *Arch Orthop Trauma Surg.* 2000;120:514-7. DOI: 10.1007/s004020000173
- Burrell M, Capurro S, Arguis P, Vilana R. Sonographic appearance of a retained surgical sponge in the neck. *J Clin Ultrasound.* 2000;28:311-3. DOI: 10.1002/1097-0096(200007/08)28:6<311::AID-JCU9>3.0.CO;2-L
- Crawford R, Matheson AB. Clinical value of ultrasonography in the detection and removal of radiolucent foreign bodies. *Injury.* 1989;20:341-3. DOI: 10.1016/0020-1383(89)90008-9
- de Oliveira Cde N, Amaral TM, Abdo EN, Mesquita RA. Bilateral tonsilloliths and calcified carotid atheromas: case report and literature review. *J Craniomaxillofac Surg.* 2013 Mar;41(2):179-82. DOI: 10.1016/j.jcms.2012.07.011
- Friedrich RE, Heiland M, Bartel-Friedrich S. Potentials of ultrasound in the diagnosis of midfacial fractures. *Clin Oral Investig.* 2003 Dec;7(4):226-9. DOI: 10.1007/s00784-003-0232-5

6. Graham DD Jr. Ultrasound in the emergency department: detection of wooden foreign bodies in the soft tissues. *J Emerg Med.* 2002;22:75-9. DOI: 10.1016/S0736-4679(01)00440-1
7. Grammatopoulos E, Murtadha L, Nair P, Holmes S, Makdissi J. Ultrasound guided removal of an airgun pellet from a patient's right cheek. *Dentomaxillofac Radiol.* 2008 Dec;37(8):473-6. DOI: 10.1259/dmfr/55307373
8. Grippaudo FR, Spalvieri C, Rossi A, Onesti MG, Scuderi N. Ultrasound-assisted liposuction for the removal of siliconomas. *Scand J Plast Reconstr Surg Hand Surg.* 2004;38:21-6. DOI: 10.1080/02844310310004686
9. Höllerhage HG, Dorfmueller G. Ausgedehnte Hirnverletzung durch Suizidversuch mit Luftgewehr und ultraschallgestützte Entfernung des tief intrakraniellen Projektils [Extensive brain injury caused by attempted suicide with an airgun and ultrasound controlled removal of the deep intracranial projectile]. *Nervenarzt.* 1992 Oct;63(10):641-3.
10. Karcioglu ZA, Nasr AM. Diagnosis and management of orbital inflammation and infections secondary to foreign bodies: a clinical review. *Orbit.* 1998;17:247-69. DOI: 10.1076/orbi.17.4.247.2737
11. Kaya K, Dulgeroglu D, Unsal-Delialioglu S, Babadag M, Tacal T, Barlak A, Ozel S. Diagnostic value of ultrasonography in the evaluation of the temporomandibular joint anterior disc displacement. *J Craniomaxillofac Surg.* 2010 Jul;38(5):391-5. DOI: 10.1016/j.jcms.2009.10.017
12. Leung A, Patton A, Navoy J, Cummings RJ. Intraoperative sonography-guided removal of radiolucent foreign bodies. *J Pediatr Orthop.* 1998;18:259-61. DOI: 10.1097/01241398-199803000-00024
13. Makdissi J. Ultrasound guided removal of an air gun pellet from the temporal fossa: a technical note. *Int J Oral Maxillofac Surg.* 2004 Apr;33(3):304-6. DOI: 10.1006/ijom.2002.0482
14. Mann W, Welkoborsky HJ, Maurer J. *Kompandium Ultraschall im Kopf-Hals-Bereich.* Stuttgart: Thieme; 1997. p. 49.
15. Ng SY, Songra AK, Bradley PF. A new approach using intraoperative ultrasound imaging for the localization and removal of multiple foreign bodies in the neck. *Int J Oral Maxillofac Surg.* 2003 Aug;32(4):433-6. DOI: 10.1054/ijom.2002.0376
16. Park SS, Yang HJ, Lee UL, Kwon MS, Kim MJ, Lee JH, Hwang SJ. The clinical application of the dental mini C-arm for the removal of broken instruments in soft and hard tissue in the oral and maxillofacial area. *J Craniomaxillofac Surg.* 2012 Oct;40(7):572-8. DOI: 10.1016/j.jcms.2011.10.013
17. Senchenkov A, Staren ED. Ultrasound in head and neck surgery: thyroid, parathyroid, and cervical lymph nodes. *Surg Clin North Am.* 2004 Aug;84(4):973-1000. v. DOI: 10.1016/j.suc.2004.04.007
18. Sharma PK, Songra AK, Ng SY. Intraoperative ultrasound-guided retrieval of an airgun pellet from the tongue: a case report. *Br J Oral Maxillofac Surg.* 2002;40:153-5. DOI: 10.1054/bjom.2001.0733
19. Shiels WE 2nd, Babcock DS, Wilson JL, Burch RA. Localization and guided removal of soft-tissue foreign bodies with sonography. *AJR Am J Roentgenol.* 1990 Dec;155(6):1277-81. DOI: 10.2214/ajr.155.6.2122680
20. Shuker ST. Management of penetrating medial and retro-bulbar orbital shrapnel/bullet injuries. *J Craniomaxillofac Surg.* 2012 Dec;40(8):e261-7. DOI: 10.1016/j.jcms.2011.12.004
21. Siessegger M, Mischkowski RA, Schneider BT, Krug B, Klesper B, Zöller JE. Image guided surgical navigation for removal of foreign bodies in the head and neck. *J Craniomaxillofac Surg.* 2001 Dec;29(6):321-5. DOI: 10.1054/jcms.2001.0254
22. Teisen HG, Torfing KF, Skjødt T. Sonographische Feinlokalisierung von Fremdkörpern. Eine In-vitro-Untersuchung [Ultrasound pinpointing of foreign bodies. An in vitro study]. *Ultraschall Med.* 1988 Jun;9(3):135-7. DOI: 10.1055/s-2007-1011612
23. Yu H, Shen SG, Wang X, Zhang L, Zhang S. The indication and application of computer-assisted navigation in oral and maxillofacial surgery – Shanghai's experience based on 104 cases. *J Craniomaxillofac Surg.* 2013;41(8):770-4. DOI: 10.1016/j.jcms.2013.01.016

#### Corresponding author:

Prof. Reinhard E. Friedrich, MD, DMD, PhD, FEBOMFS  
 Oral and Cranio-Maxillofacial Surgery, Eppendorf  
 University Hospital, University of Hamburg, 20246  
 Hamburg, Germany, Phone: +49-(0)40-741053259  
 rfriedri@uke.uni-hamburg.de

#### Please cite as

Friedrich RE. Ultrasonographically supported removal of foreign bodies of the eye lid and parapharyngeal space in a 13-year-old boy subjected to shot injuries in early childhood. *GMS Interdiscip Plast Reconstr Surg DGPW.* 2013;2:Doc19.  
 DOI: 10.3205/iprs000039, URN: urn:nbn:de:0183-iprs0000399

#### This article is freely available from

<http://www.egms.de/en/journals/iprs/2013-2/iprs000039.shtml>

**Published:** 2013-11-29

#### Copyright

©2013 Friedrich. This is an Open Access article distributed under the terms of the Creative Commons Attribution License (<http://creativecommons.org/licenses/by-nc-nd/3.0/deed.en>). You are free: to Share – to copy, distribute and transmit the work, provided the original author and source are credited.