

## Case Report

# Ceftriaxone-induced encephalopathy in a patient with multicentric glioma

Mariette Anto<sup>1</sup>, Rajesh Shankar Iyer<sup>2</sup>, Adarsh Manuel<sup>1</sup> , Akarsh Jayachandran<sup>1</sup>, Rosmy Jose<sup>3</sup>, Nisha John<sup>3</sup>, Puja Shyam<sup>3</sup>, Anjitha Thankachan<sup>1</sup>, Santhosh George Thomas<sup>1</sup>, Biji Bahuleyan<sup>1</sup>

<sup>1</sup>Department of Neurosurgery, Lisie Hospital, Kochi, Kerala, <sup>2</sup>Department of Neurology, Kovai Medical Centre and Hospital, Coimbatore, Tamil Nadu,

<sup>3</sup>Department of Anaesthesia, Lisie Hospital, Kochi, Kerala, India.

E-mail: Mariette Anto - marietteanto@gmail.com; Rajesh Shankar Iyer - dr\_rsh@hotmail.com; Adarsh Manuel - adarshmanuel@gmail.com; Akarsh Jayachandran - akarshjayachandran@gmail.com; Rosmy Jose - rosmyj@gmail.com; Nisha John - nishjohnk@gmail.com; Puja Shyam - pujashyam28@gmail.com; Anjitha Thankachan - thankachananjitha31@gmail.com; Santhosh George Thomas - santhoshgeorgethomas@gmail.com; \*Biji Bahuleyan - drbijib@gmail.com



### \*Corresponding author:

Biji Bahuleyan,  
Department of Neurosurgery,  
Lisie Hospital, Kochi, Kerala,  
India.

drbijib@gmail.com

Received : 22 May 2022

Accepted : 29 June 2022

Published : 15 July 2022

### DOI

10.25259/SNI\_483\_2022

### Quick Response Code:



## ABSTRACT

**Background:** Ceftriaxone is a commonly used antibiotic in a wide range of local and systemic infections. Encephalopathy is a rare complication of ceftriaxone, often seen in older adults and those with renal insufficiency.

**Case Description:** A 73-year-old lady with prior history of hypertension and dyslipidemia presented with the complaints of slurred speech, gait imbalance, nocturnal vomiting, and progressively worsening headache. A magnetic resonance imaging of the brain revealed two intracerebral lesions involving the right frontal and temporal lobes, suggestive of multicentric glioma. She underwent craniotomy and excision of these lesions. The biopsy was reported as intra-axial tumors with features suggestive of the WHO Grade IV glioma. Postoperatively, she did not wake up. An electroencephalogram demonstrated triphasic waves suggestive of encephalopathy. The probable diagnosis of ceftriaxone-induced encephalopathy was made after ruling out other causes of delayed awakening after surgery. Ceftriaxone was discontinued and the patient improved within 2 days of withdrawal of ceftriaxone.

**Conclusion:** Drug-induced encephalopathy should be considered in the differential diagnosis of patients with delayed awakening after surgery. Discontinuation of the drug leads to the recovery of these patients.

**Keywords:** Ceftriaxone, Encephalopathy, Glioma, Surgery

## INTRODUCTION

On account of their broad microbial spectrum and excellent tissue penetration, cephalosporins are frequently used to treat a wide variety of local and systemic infections.<sup>[2]</sup> Ceftriaxone has a longer half-life,<sup>[3,7]</sup> mixed biliary and renal clearance,<sup>[3,9]</sup> fewer adverse effects,<sup>[3]</sup> and minimal drug interactions,<sup>[3]</sup> which makes it a preferred antibiotic in many clinical conditions.

Ceftriaxone is rarely known to cause central nervous system (CNS) complications.<sup>[3]</sup> Encephalopathy,<sup>[1,5,6,8-13,15]</sup> status epilepticus,<sup>[8]</sup> nonconvulsive status epilepticus (NCSE),<sup>[6]</sup> choreoathetosis,<sup>[3,6]</sup> seizures,<sup>[9]</sup> hallucinations,<sup>[8]</sup> or myoclonus<sup>[3,8]</sup> are the CNS complications reported to be caused by ceftriaxone.

This is an open-access article distributed under the terms of the Creative Commons Attribution-Non Commercial-Share Alike 4.0 License, which allows others to remix, transform, and build upon the work non-commercially, as long as the author is credited and the new creations are licensed under the identical terms.

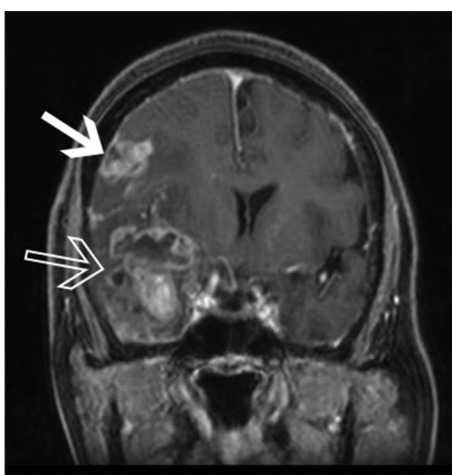
©2022 Published by Scientific Scholar on behalf of Surgical Neurology International

Encephalopathy is an uncommon complication of the third- and fourth-generation cephalosporins.<sup>[10,12]</sup> Among cephalosporins, cefepime is the most notorious.<sup>[3,6]</sup> Ceftriaxone is rarely reported to cause encephalopathy.<sup>[3,8,13]</sup>

In this report, we present a case of ceftriaxone-induced encephalopathy (CIE) in a patient following craniotomy for glioma, who was given ceftriaxone as perioperative antibiotic prophylaxis.

## CASE REPORT

A 73-year-old female patient with prior history of hypertension and dyslipidemia was admitted with a 2-week history of dysarthria, gait imbalance, nocturnal vomiting, and progressively worsening headache. She gave a history of recent weight loss. She had no history of chronic cough, breast lump, or blackish discoloration of stools. General physical examination was normal. There was no breast lump. Abdominal and chest examinations were normal. On neurological examination, she was conscious and oriented. Cranial nerve examination was normal. She had a power of Grade 5 in all limbs. She had gait instability with a slight tendency to sway toward the left. Soft pyramidal signs were absent. Sensory examination was normal. Reflexes were normal bilaterally. Magnetic resonance imaging (MRI) of the brain [Figure 1] showed two intracerebral lesions with mild perilesional edema, involving the right temporal and frontal lobes. The temporal lesion was larger and was partly cystic and solid, involving the neocortex and mesial temporal structures. The smaller one was in the frontal region. These lesions were hypointense on T1-weighted images, hyperintense on T2-weighted and FLAIR



**Figure 1:** Gadolinium-enhanced coronal T1-weighted magnetic resonance imaging image of the brain showing contrast-enhancing lesions in the right temporal lobe (empty white arrow) and the right frontal lobe (white arrow).

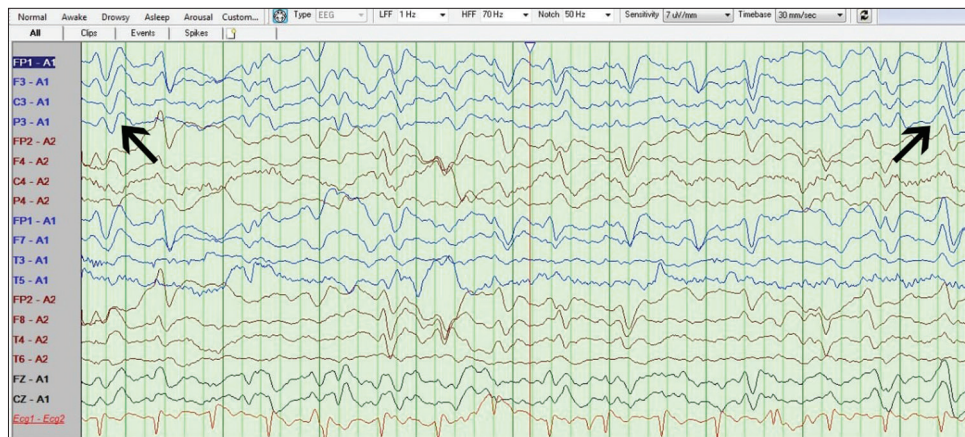
sequences, and showed heterogeneous enhancement with contrast.

Our preoperative radiological diagnosis was multicentric glioma. She was started on phenytoin sodium as a preoperative antiepileptic. Injection ceftriaxone 2 g was given intravenously as perioperative antibiotic prophylaxis. With neuronavigation guidance, she underwent right frontotemporal craniotomy, right anterior temporal lobectomy, amygdalohippocampectomy, and excision of the right frontal lesion. At surgery, the temporal lesion was found to be firmly attached to the dura with infiltration of the neocortex, hippocampus, and amygdala. The lesions were moderately vascular, suckable, and had cystic change, evidence of necrosis, and thrombosed veins within it. The surgery was uneventful with no intraoperative complications such as hypoxia or hypotension. The entire lesion in the frontal region, temporal neocortex, and hippocampus was removed. The lesion in the amygdala was only partially removed. The patient did not wake up fully after surgery. However, since her breathing was normal, she was extubated.

The following causes of delayed awakening after surgery were considered: (i) NCSE, (ii) hypoglycemia, (iii) operative site hematoma, (iv) thromboembolic cerebral infarcts, (v) electrolyte imbalance, (vi) metabolic encephalopathy, and (vii) extensive brain tissue resection. Considering NCSE as a probable cause for the delayed awakening, we administered an additional loading dose of phenytoin sodium in the immediate postoperative period in the operating room. We also added levetiracetam as an add-on antiepileptic. An emergency MRI brain done in the immediate postoperative period confirmed total excision of the right frontal and temporal lesions with no postoperative hematoma or infarcts that would explain her altered sensorium. Blood tests were done to rule out all possible causes of encephalopathy including liver function tests, renal function tests, and serum electrolyte panel, all of which were normal. A bedside electroencephalogram (EEG) showed a background activity of 4–5 Hz over posterior head regions. Triphasic waves with anteroposterior lag were seen [Figure 2], suggestive of encephalopathy. Hence, CIE was presumed to be the cause of delayed awakening. Ceftriaxone and levetiracetam were stopped and the dose of phenytoin sodium was reduced to preoperative status. The patient showed gradual improvement in neurological status within 48 h and she went back to normal sensorium in 4 days.

## DISCUSSION

The exact pathophysiology by which ceftriaxone causes encephalopathy remains unidentified.<sup>[1]</sup> One proposed theory is that ceftriaxone, like other cephalosporins, causes a competitive blockade of inhibitory neurotransmitters like gamma-aminobutyric acid in the brain, leading to increased



**Figure 2:** Postoperative electroencephalogram showing triphasic waves with anteroposterior lag (black arrows).

firing of excitatory neurons.<sup>[2,9]</sup> An alternate hypothesis is that ceftriaxone causes the release of inflammatory cytokines like tumor necrosis factor- $\alpha$  which triggers neurotoxicity.<sup>[14]</sup>

Renal impairment<sup>[1,3,5,7,9,10,11,13,15]</sup> and old age<sup>[1,3,5,7,9,10,13,15]</sup> are the main predisposing factors observed in most patients diagnosed with CIE in the literature. Hepatic dysfunction,<sup>[5]</sup> impaired biliary excretion,<sup>[3]</sup> administration of high-dose ceftriaxone,<sup>[8]</sup> and preexisting neurological conditions<sup>[1,12]</sup> are the other risk factors associated with CIE. Cerebrovascular disease,<sup>[10,14]</sup> meningitis,<sup>[8]</sup> and cerebral contusion<sup>[15]</sup> are the neurological conditions that have been reported to predispose to CIE. The risk factors in the case we present are old age and the presence of a multicentric glioma. In multicentric glioma, the diffuse infiltration of the brain by the neoplastic cells could be the triggering factor that induced CIE.

In the literature, the onset of ceftriaxone-induced neurotoxicity (CIN) is between 1 and 10 days after starting the drug.<sup>[4]</sup> The onset of this neurological complication was observed immediately after a 6 h surgery in our patient.

Diagnosis of this complication is often difficult as ceftriaxone is an underrecognized cause of neurotoxicity.<sup>[1,3,5,8]</sup> Moreover, neither imaging nor cerebrospinal fluid (CSF) analysis can confirm the condition.<sup>[3]</sup> The diagnosis of CIE is mainly clinical with a high degree of suspicion,<sup>[3,9,11]</sup> as seen in our patient. EEG commonly shows generalized slowing and triphasic waves, suggestive of encephalopathy.<sup>[8,13]</sup> In CIE, patients tend to have a higher concentration of ceftriaxone in their blood and CSF.<sup>[9,13]</sup> This can be measured using high-performance liquid chromatography with ultraviolet detection.<sup>[13]</sup>

An important differential diagnosis to consider in delayed awakening after surgery is NCSE. As seen in our case, CIE should also be considered in a similar scenario. The presence of triphasic waves, as seen in our case, clearly suggests

metabolic encephalopathy than NCSE.<sup>[1,8,10]</sup> Distinguishing between these two entities is necessary as excessive administration of antiepileptic drugs with a wrong diagnosis of NCSE can delay patients' recovery and invite associated complications.<sup>[15]</sup>

In CIN, spontaneous improvement in patients' clinical status is observed within 1–12 days of withholding ceftriaxone.<sup>[4]</sup> Our patient recovered within 4 days.

In 2021, Lacroix *et al.*<sup>[8]</sup> used the French Pharmacovigilance Database and described the largest case series of ceftriaxone-induced CNS complications. They analyzed 216 patients with CNS adverse drug reactions related to ceftriaxone and identified 45 cases (20.8%) of CIE. They acknowledged encephalopathy as the most common CNS complication related to ceftriaxone. In this article, they have also reviewed six previously reported cases of CIE published in the literature. Our literature review yielded three more cases of CIE in addition to the cases reported by Lacroix *et al.* We were able to identify an additional three cases of CIE. Table 1 summarizes all the reported cases of CIE except the ones identified by Lacroix *et al.* Old age and renal dysfunction were recognized as the most common predisposing factors. The median time of onset of CNS adverse drug reactions was 4 days and the mean duration of clinical manifestation was 4.5 days.

Table 1 summarizes all the cases of CIE in the literature, except the ones identified in the French Pharmacovigilance Database.<sup>[1,5,9-13,15]</sup> The age of these patients ranges from 8 to 86 years with the majority of the patients above the age of 60.

Renal dysfunction was the most common risk factor. Renal dysfunction is seen in all the published articles except in the case reported by Sharma *et al.* Our patient was also similar to the one referred to by Sharma *et al.*<sup>[12]</sup> with regard to normal renal function. Old age is also a common risk factor observed

**Table 1:** Summary of all the previously published cases of CIE in the literature.

Reference	Age	Risk factors	Neurological manifestation	Onset	Recovery
Roncon-Albuquerque <i>et al.</i> <sup>[10]</sup>	60	T2DM, HTN, dyslipidemia, CVD, CAD, PVD, and acute renal failure	Progressive apathy and insomnia	4 days	3 days
Sharma <i>et al.</i> <sup>[12]</sup>	8	None	Progressive apathy, insomnia	3 days	3 days
Jadot <i>et al.</i> <sup>[5]</sup>	64	NASH-related cirrhosis complicated by hepatocellular carcinoma, T2DM, HTN, CAD, and chronic renal insufficiency	Encephalopathy	22 days	3 days
Suzuki <i>et al.</i> <sup>[13]</sup>	86	ESRD on HD, RA, hypothyroidism, and HTN	Altered mental state, myoclonic jerks	13 days	4 days
Nishioka <i>et al.</i> <sup>[9]</sup>	78	HTN and ESRD	Encephalopathy	9 days	5 days
Dubin and Schattner <sup>[1]</sup>	76	Vascular disease s/p mitral valve repair and renal dysfunction	Coma	14 days	2 days
Triplett <i>et al.</i> <sup>[15]</sup>	70	DM and acute renal failure	Encephalopathy	3 days	UK
Triplett <i>et al.</i> <sup>[15]</sup>	80	Head injury with cerebral contusions	Encephalopathy	2 days	UK
Safadi <i>et al.</i> <sup>[11]</sup>	37	ESRD due to lupus nephritis	Agitation, paranoia, and hallucination	3 days	1.5 days

T2DM: Type 2 diabetes mellitus, HTN: Hypertension, CVD: Cerebrovascular disease, CAD: Coronary artery disease, PVD: Peripheral vascular disease, NASH: Nonalcoholic steatohepatitis, ESRD: End-stage renal disease, HD: Hemodialysis, RA: Rheumatoid arthritis

in most of the published articles, except in the cases reported by Sharma *et al.*<sup>[12]</sup> and Safadi *et al.*<sup>[11]</sup>

CIE is an underdiagnosed and underreported clinical entity. Considering the risk of neurotoxicity, the use of ceftriaxone as perioperative antibiotic prophylaxis should not be considered in older adults and/or in patients with renal dysfunction. Instead, antibiotics such as cefoperazone or amoxiclav that are very rarely reported to cause neurotoxicity should be contemplated as an alternative for perioperative antibiotic prophylaxis in such cases.

A limitation of our case report is that we were unable to measure the CSF level of ceftriaxone.

Our case is novel in that; (i) it is the first reported case of CIE in a neurosurgical patient diagnosed with multicentric glioma and (ii) the onset of encephalopathy was observed in less than a day.

## CONCLUSION

CIE is a rare complication most commonly seen in older adults with renal failure. Ceftriaxone should be considered a cause of encephalopathy in patients who were administered the drug with delayed awakening after surgery. Since this complication is underdiagnosed and altered mental status has multiple differentials, the diagnosis of this condition remains clinically challenging. Clinical vigilance of the condition, EEG findings, and when possible, measurement of ceftriaxone concentration in serum and CSF can aid in diagnosing this condition. Neurological conditions as a risk factor need further

exploration to help us better understand and prevent this complication. Prompt diagnosis and cessation of the drug can revert this condition. Clinicians should be more aware of this iatrogenic complication.

## Declaration of patient consent

The authors certify that they have obtained all appropriate patient consent.

## Financial support and sponsorship

Nil.

## Conflicts of interest

There are no conflicts of interest.

## REFERENCES

- Dubin I, Schattner A. Iatrogenic coma: Ceftriaxone-associated encephalopathy. *Postgrad Med J* 2018;94:357-8.
- Grill MF, Maganti R. Cephalosporin-induced neurotoxicity: Clinical manifestations, potential pathogenic mechanisms, and the role of electroencephalographic monitoring. *Ann Pharmacother* 2008;42:1843-50.
- Hagiya H, Miyawaki K, Yamamoto N, Yoshida H, Kitagawa A, Asaoka T, *et al.* Ceftriaxone-induced neurotoxicity in a patient after pancreas-kidney transplantation. *Intern Med* 2017;56:3103-7.
- Inoue Y, Doi Y, Arisato T, Sugioka S, Koga K, Nishioka K, *et al.* Three cases of hemodialysis patients receiving high-dose ceftriaxone: Serum concentrations and its neurotoxicity.

- Kidney Int Rep 2017;2:984-7.
5. Jadot L, Judong A, Canivet JL, Lorenzo-Villalba N, Damas P. Ceftriaxone-induced encephalopathy: A pharmacokinetic approach. *Eur J Case Rep Intern Med* 2021;8:003011.
  6. Kim KB, Kim SM, Park W, Kim JS, Kwon SK, Kim HY. Ceftriaxone-induced neurotoxicity: Case report, pharmacokinetic considerations, and literature review. *J Korean Med Sci* 2012;27:1120-3.
  7. Kotani A, Hirai J, Hamada Y, Fujita J, Hakamata H. Determination of ceftriaxone concentration in human cerebrospinal fluid by high-performance liquid chromatography with UV detection. *J Chromatogr B Analyt Technol Biomed Life Sci* 2019;1124:161-4.
  8. Lacroix C, Bera-Jonville AP, Montastruc F, Velly L, Micallef J, Guilhaumou R. Serious neurological adverse events of ceftriaxone. *Antibiotics (Basel)* 2021;10:540.
  9. Nishioka H, Cho Y, Irie K, Kanamori M. Ceftriaxone-associated encephalopathy in a patient with high levels of ceftriaxone in blood and cerebrospinal fluid. *Int J Infect Dis* 2022;116:223-5.
  10. Roncon-Albuquerque R Jr., Pires I, Martins R, Real R, Sousa G. Ceftriaxone-induced acute reversible encephalopathy in a patient treated for a urinary tract infection. 2009;67:72-5.
  11. Safadi S, Mao M, Dillon JJ. Ceftriaxone-induced acute encephalopathy in a peritoneal dialysis patient. *Case Rep Nephrol* 2014;2014:108185.
  12. Sharma N, Batish S, Gupta A. Ceftriaxone-induced acute reversible encephalopathy in a patient with enteric fever. *Indian J Pharmacol* 2012;44:124-5.
  13. Suzuki S, Naito S, Numasawa Y, Asada M, Shoji N, Zeniya M, *et al.* encephalopathy induced by high plasma and cerebrospinal fluid ceftriaxone concentrations in a hemodialysis patient. *Intern Med* 2019;58:1775-9.
  14. Tan ML, Tun WW. Reversible choreoathetosis in a patient with end-stage renal disease from administration of ceftriaxone. *Cureus* 2019;11:e5764.
  15. Triplett JD, Lawn ND, Chan J, Dunne JW. Cephalosporin-related neurotoxicity: Metabolic encephalopathy or non-convulsive status epilepticus? *J Clin Neurosci* 2019;67:163-6.

**How to cite this article:** Anto M, Iyer RS, Manuel A, Jayachandran A, Jose R, John N, *et al.* Ceftriaxone-induced encephalopathy in a patient with multicentric glioma. *Surg Neurol Int* 2022;13:303.