




ELSEVIER

Contents lists available at ScienceDirect

Urology Case Reports

journal homepage: www.elsevier.com/locate/eucr

Oncology

Metastatic clear cell renal cell carcinoma to the forearm without identifiable primary renal mass

John Walton^a, Jinhong Li^b, Marisa M. Clifton^{a,*}, Ryan L. Mori^a, Alyssa M. Park^a, Joel M. Sumfest^a^a Dept. of Urology, Geisinger, Danville, PA, USA^b Dept. of Pathology, Geisinger, Danville, PA, USA

ARTICLE INFO

Keywords:

Kidney cancer
Renal cell carcinoma

ABSTRACT

Kidney cancer is the ninth most common malignancy in the United States. Most kidney cancers are clear cell renal cell carcinoma (RCC) and arise as solid tumors from kidney parenchyma. In the setting of metastatic disease, a primary renal tumor is usually identified, and metastases are often to lung, bone, liver, and brain. Metastatic RCC without an identifiable solid kidney tumor is exceedingly rare. We report the case of a 52 year old male with a rare cutaneous RCC metastasis without an identifiable primary renal tumor.

Introduction

Kidney cancer is the ninth most common cancer in the United States, and 75% are clear cell renal cell carcinomas (RCC) arising from renal parenchyma. At diagnosis, 16% of kidney cancers are metastatic with the most common sites being lung, bone, liver, and brain.¹ Hematogenous spread may result in an unusual metastatic pattern such as muscular or cutaneous disease. We report the case of a 52 year old male with metastatic RCC to the forearm in the setting of no identifiable primary renal tumor.

Case presentation

A 52 year old male presented with a painless, enlarging 1.5 cm mass on the right forearm. Magnetic resonance imaging (MRI) of the right upper extremity with and without contrast revealed an enhancing mass with involvement of the forearm extensor muscles (Fig. 1). Aside from the forearm finding, physical exam was unremarkable. A biopsy of the mass demonstrated metastatic clear cell renal cell carcinoma (RCC). Computed tomography (CT) imaging of the chest, abdomen, and pelvis with intravenous contrast showed a 2.0 cm hyperdense, non-enhancing, simple left renal cyst with no solid components or calcifications and minimal wall thickening. No lymphadenopathy or metastases were found in the chest, abdomen, or pelvis. A renal mass protocol MRI showed the previously identified 2 cm left renal cyst consistent with a Bosniak 2F renal cyst (Fig. 2). The patient underwent forearm mass

resection with skin graft reconstruction by orthopedic surgery.

Pathology from resection showed metastatic clear cell RCC, Fuhrman nuclear grade IV, focal rhabdoid features, and negative margins. The gross specimen was an ovoid, pink-tan, hair-bearing portion of skin and underlying tissue with a centrally located tumor mass measuring approximately 3.5 × 3.3 cm. On cut section, the tumor had a pink-yellow focally congested glistening gross appearance. Under microscopic examination, HE stained tissue sections revealed a malignant tumor with high nuclear grade and clear cytoplasm with focal rhabdoid features sitting in a vascular stroma (Fig. 3). Immunohistochemical study revealed that the tumor cells were positive for both Pax-8 and CD10, common markers used for RCC.

Following resection, he underwent PET CT which was negative for residual disease in the forearm or evidence of metastatic disease to other sites. The patient has undergone close follow up with physical exam and CT chest, abdomen pelvis every 6 months. At 27 months of follow up, he remains without evidence of disease. The left renal cyst minimally increased in size to 3.3cm.

Discussion

Cutaneous and musculoskeletal clear cell RCC metastases are rare and are typically located in the head and neck region. Physical exam findings vary from small vascular-appearing tumors to large ulcerated lesions. Renal cell metastases to muscle are also rare with an estimated incidence of less than 1% of cases of metastatic RCC from case series.²

Abbreviations: FDG PET, fluorodeoxyglucose positron emission tomography; CT, computed tomography; MRI, magnetic resonance imaging; RCC, renal cell carcinoma

* Corresponding author. Dept. of Urology Geisinger, 100 N. Academy Avenue, Mail Code 01-27, Danville, PA, 17822, USA.

E-mail address: marisameyerclifton@gmail.com (M.M. Clifton).

<https://doi.org/10.1016/j.eucr.2019.100989>

Received 31 July 2019; Accepted 5 August 2019

Available online 06 August 2019

2214-4420/© 2019 The Authors. Published by Elsevier Inc. This is an open access article under the CC BY-NC-ND license

(<http://creativecommons.org/licenses/by-nc-nd/4.0/>).

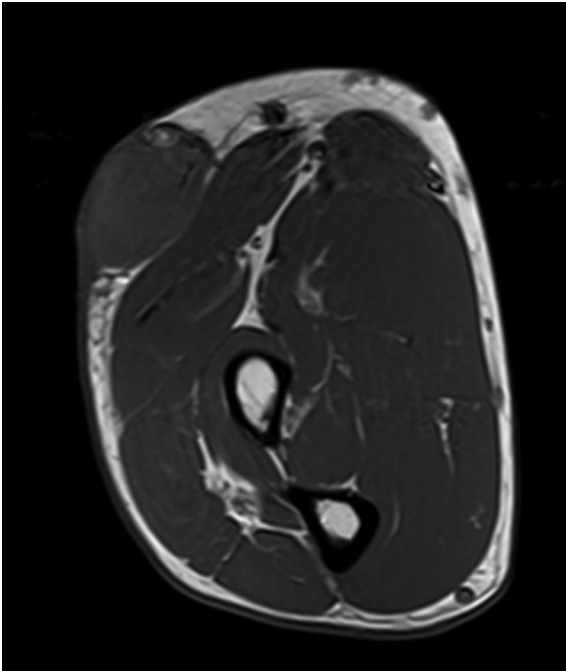


Fig. 1. T1 weighted MRI showing a large right forearm mass.

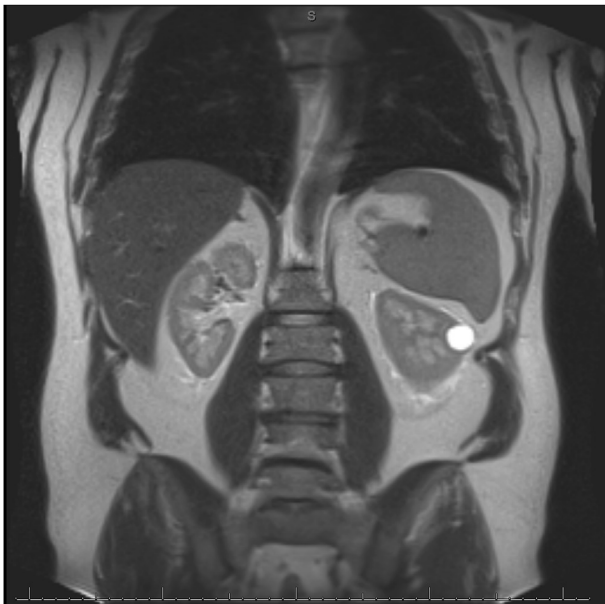

Fig. 2. T2 weighted MRI of the abdomen showing a Bosniak 2F cyst.

As a result, data are limited regarding prognosis in patients with these sites of involvement. Resection of solitary metastases is standard in RCC, and case series suggest good local control following resection of solitary osseous and soft tissue metastases from renal cell carcinoma.³

Metastatic RCC without an identifiable primary renal mass is exceedingly rare with only case reports and series. For example, a 66 year old male with a cutaneous RCC metastasis to the nose and no evidence of a primary RCC remained without evidence of recurrence or renal mass at 1 year of follow up after excision of the cutaneous mass.⁴ In another case reported by Johnson et al., a 71 year old male with a solitary adrenal RCC metastasis without identifiable primary tumor remained without evidence of disease 3 years following adrenalectomy. The cause of metastatic cancer in the absence of an identifiable primary tumor is unknown, and the recommended evaluation includes a history

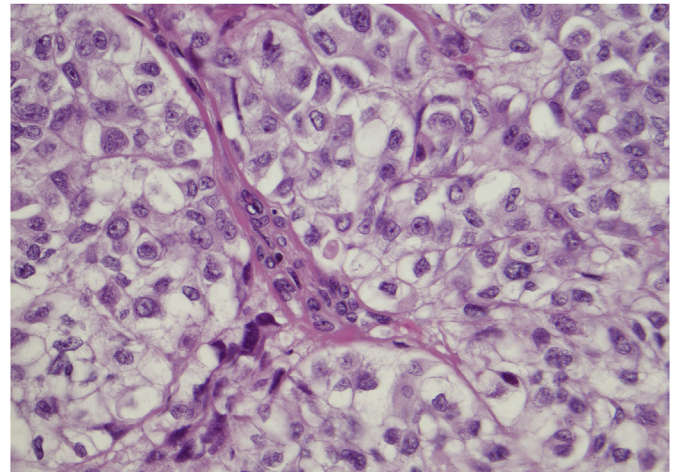


Fig. 3. High power (40x) shows tumor cells with clear cytoplasm in vascular rich stroma.

and physical, labs, and CT of the chest, abdomen, and pelvis, followed by further studies tailored to the individual.

For patients without an identifiable kidney primary, obtaining tissue from the metastatic site is critical for diagnosis. Prognosis is heterogeneous, with one series of 10 patients demonstrating a median survival of 5.7 months with targeted systemic regimens.⁵ Other case reports suggest a robust progression-free response after excision of metastatic lesions. The treatment options for patients with metastatic RCC with no primary renal tumor are also variable, with case reports and case series describing treatment with systemic targeted therapy and/or local excision. The retrospective nature of these sporadic reports and heterogeneity of metastasis sites prevents delineation of standardized treatment options and follow up strategies. Individualized strategies based on the specifics of each patient's situation is recommended.

In our patient, there is concern that the renal cyst is a possible primary source of his metastatic disease, as clear cell RCC may arise from cystic lesions. However, suspicious cystic lesions have concerning features such as nodularity, septations, and calcifications which are absent in this particular case. There is a small overall risk of malignancy in a Bosniak 2F cyst of approximately 10%. However, with a low risk of malignancy and continued stability, we opted for continued surveillance.

Conclusion

Metastatic renal cell carcinoma to cutaneous and muscular sites is a rare occurrence, especially in the absence of a radiographically identifiable primary kidney tumor. Excision of the solitary metastatic site followed by close surveillance with history, physical exam, and cross-sectional imaging is recommended to monitor for new renal masses and metastases.

Funding sources

This research did not receive any specific grant from funding agencies in the public, commercial, or not-for-profit sectors. Acknowledgements

The authors would like to thank Dr. Tullika Garg for language and proofreading assistance on this manuscript.

Conflicts of interest

None.

Appendix A. Supplementary data

Supplementary data to this article can be found online at <https://doi.org/10.1016/j.eucr.2019.100989>.

References

1. Kane CJ, Mallin K, Ritchey J, Cooperberg MR, Carroll PR. Renal cell cancer stage migration: analysis of the National Cancer Data Base. *Cancer*. 2008;113(1):78–83.
2. Kozak O, Turzynski P, Markiet K, Pienkowska J, Skrobisz-Balandowska K, Studniarek M. Uncharacteristic metastasis of a renal clear-cell carcinoma to the muscles of the forearm—case report. *BJR Case Rep*. 2017;3(3):20150495.
3. Higuchi T, Yamamoto N, Hayashi K, et al. Long-term patient survival after the surgical treatment of bone and soft-tissue metastases from renal cell carcinoma. *Bone Joint Lett J*. 2018;100-B:1241–1248.
4. Bhatia S, Ng S, Hodder SC. Metastatic cutaneous head and neck renal cell carcinoma with no known primary: case report. *Br J Oral Maxillofac Surg*. 2010;48(3):214–215.
5. Overby A, Duval L, Ladekarl M, Laursen BE, Donskov F. Carcinoma of unknown primary site with metastatic renal-cell carcinoma histologic and immunohistochemical characteristics: results from consecutive patients treated with targeted therapy and review of literature. *Clin Genitourin Cancer*. 2019;17(1):e32–e37.