




Contents lists available at ScienceDirect

## Trauma Case Reports

journal homepage: <http://www.journals.elsevier.com/trauma-case-reports/>



### Case Report

# Patterns of retroperitoneal trauma following gunshot violence: A case series<sup>☆</sup>

V.E. Onwochei<sup>a</sup>, J.C. Bolger<sup>a</sup>, M.E. Kelly<sup>a</sup>, S. Murphy<sup>a</sup>, I. Khan<sup>a</sup>, K. Barry<sup>a,b,\*</sup>

<sup>a</sup> Department of Surgery, Mayo General Hospital, Saolta University Hospital Group, Ireland

<sup>b</sup> Discipline of Surgery, National University of Ireland, Galway

#### ARTICLE INFO

##### Article history:

Accepted 19 October 2015

Available online 7 November 2015

##### Keywords:

Retroperitoneal  
trauma  
gunshot  
management

#### ABSTRACT

**Introduction:** Abdominal trauma is defined as any injury to the abdomen and its containing viscera. Common penetrating injuries including gunshot or stab injuries are increasing worldwide. However, retroperitoneal gunshot injuries have a lower incidence than trans-abdominal trauma and can have substantially different outcomes.

**Case report** We report a series of three family members involved in gunshot violence over an 18-month period. Each sustained retroperitoneal gunshot injuries with varying injury patterns and treatment courses. Interestingly, one patient had a delayed small bowel perforation on day 6 post injury.

**Discussion:** Retroperitoneal trauma following gun violence has a lower incidence than trans-abdominal trauma. There is a paucity of literature describing injury patterns following this type of injury and their subsequent management. In the context of penetrating retroperitoneal trauma, the retroperitoneal organs are at risk and therefore serial clinical and/or radiological assessment is necessary. Delayed small bowel injury as a consequence of retroperitoneal gunshot is an unusual finding, with no reports to our knowledge in the literature.

**Conclusion:** this case series highlight that penetrating retroperitoneal trauma can produce a variety of injury patterns. Therefore a wide clinical acumen is needed to ensure a successful outcome. The trajectory of the bullet may help ascertain potential injuries, but serial assessment and observation are also important. Ultimately, individual cases must be treated accordingly, based on clinical stability, severity of injury and

<sup>☆</sup> All authors declare no conflict of interests.

\* Corresponding author at: Department of Surgery, Mayo General Hospital, Castlebar, Republic of Ireland. Discipline of Surgery, National University of Ireland, Galway, Republic of Ireland. Tel.: +353 94 902 1733; fax: +353 94 902 1454.

E-mail address: [kbarsurg@gmail.com](mailto:kbarsurg@gmail.com) (K. Barry).

radiological findings. Despite initial stability, patients should always be observed for delayed complications.

© 2015 The Authors. Published by Elsevier Ltd. This is an open access article under the CC BY-NC-ND license (<http://creativecommons.org/licenses/by-nc-nd/4.0/>).

## Introduction

Abdominal trauma may be defined as any injury to the abdomen and its containing viscera. It can be classified as blunt or penetrating, with blunt being the more common [1]. Alternatively, penetrating injuries are further sub-classified as missile or non-missile. The most common penetrating injuries worldwide are gunshot or stab injuries.

Despite increasing gun related trauma over recent years in the Republic of Ireland, it remains relatively low in comparison to other western countries. Ireland's homicidal rate of firearm injury is 0.32 per 100,000 population, while America and South Africa have rates of 2.9 and 80 per 100,000 population respectively [1]. Worldwide, males are more common victims, with mean age ranging from 18–25years [2].

The distribution of gunshot injuries to the body is very variable, with significant differences in extent of injury. Frequently, it involves the lower trunk or the abdomen. Missile injuries to the abdomen most commonly result in trauma to the small intestine and specifically the distal ileum [1].

Management of penetrating trauma has evolved over the last century. Expectant management was commonplace during the First World War. With better sterilization, antimicrobials and surgical techniques a considerable shift to operative management, including mandatory laparotomy during the Second World War occurred. However, the role of selective laparotomy became more established during the Vietnam War [3]. In recent decades, improved diagnostics including laparoscopy, computerized tomography imaging and focused ultrasound scans help to better delineate those patients that require earlier surgical intervention. Overall, such modalities have resulted in improved overall survival for those patients presenting with penetrating abdominal injuries [3,4].

This case series describes a variation of penetrating (gunshot) injuries inflicted on three family members over an 18-month period, each presenting to the same general hospital. They had a common pattern of retroperitoneal bullet entry but with varying outcome.

## Presentation of cases

**Table 1.** Summarizes each case, including demographics, mechanism of injury, assessment and treatment, imaging, management approach and outcome.

## Discussion

Worldwide gun-related violence is increasing [5]. As a result, there have been increased publications discussing management. Many high-volume centers are increasingly employing selective non-operative management for abdominal gunshot injuries [6]. This has been largely based on data relating to anterior/trans-abdominal injuries. Retroperitoneal trauma following gun violence is uncommon compared to trans-abdominal trauma, but is largely managed using similar guidelines as anterior gunshot wounds [7]. Studies have observed that injury severity is directly related to bullet type and trajectory, type of weapon (low versus high velocity) and distance from the victim [4].

There is paucity in the literature describing the pattern or frequency of organ involvement in retroperitoneal penetrating injuries. Traditionally, any penetrating injuries to the torso, whether trans-abdominal or retroperitoneal required a mandatory operation [3]. However, with better radiological imaging there has been a shift to more conservative management strategies, reserving surgical exploration for any patient that presents or develops clinical instability or peritonism [7].

*Velmahos et al.* reported on 203 consecutive patients with gunshots to the back. 31% of patients had emergency laparotomy performed from the outset, while 69% were observed clinically. Only 3% of those managed conservatively required subsequent laparotomy, while 3.4% of those initially managed operatively had negative findings [7]. Other series have shown negative laparotomy rates for all types of penetrating abdominal

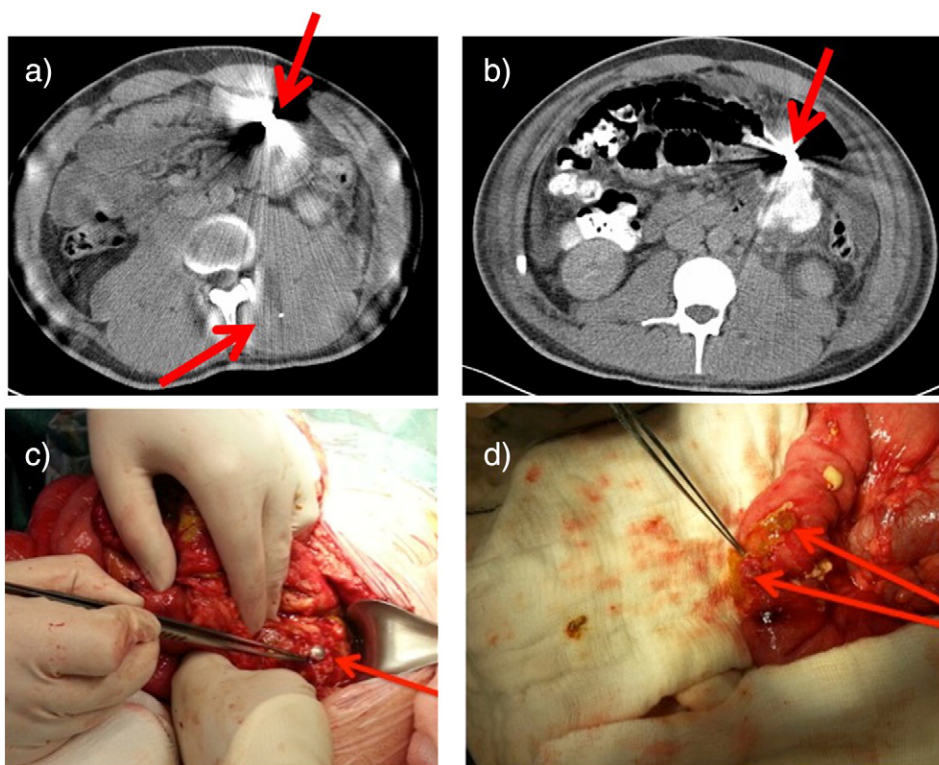
**Table 1**  
Case Summary.

	Case 1	Case 2	Case 3
<b>Age</b>	20 years	29 years	31 years
<b>Time between assault and presentation to the hospital</b>	20mins	15mins	1 hour
<b>Distance from weapon and type</b>	2 Metres Low velocity	3 Metres High velocity	5 Metres Low velocity
<b>Description of wound site</b>	2 bullet wounds to the back: Left level of L3 vertebrae Right level of L4 vertebrae No exit wound	3 bullet wounds: Mid upper back Right mid chest Right flank No exit wound	Single bullet wound Right flank at level of iliac crest No exit wound
<b>Findings on initial abdominal examination</b>	Soft Some tenderness Left flank Bowel sounds absent	Soft Distended Bowel sounds present	Soft Non tender Bowels sounds present
<b>Initial resuscitation/ Treatment</b>	Two wide bore cannula Crystalloids NPO NGT Catheter Intravenous antibiotics Tetanus Toxoid	Two wide bore cannula Crystalloids, Colloids, RBC, Octoplex 100% oxygen Needle decompression right pneumothorax Right chest drain Intravenous antibiotics	Two wide bore cannula NPO Crystalloids Analgesia Intravenous antibiotics Urinary catheter Tetanus toxoid
<b>Investigations</b>	HB 14.6, lactate 0.9	HB 12.4	HB 15
<b>Blood</b>	Not performed	Right haemothorax with left midline shift	Comminuted Right iliac crest fracture
<b>Xray</b>	Haematoma of erector spinae, Psoas, Iliacus, and quadratus Lumborum	Right haemothorax moderate	No free fluid
<b>CT finding</b>	Small bowel intramural haematoma Free air in peritoneum and para renal space in follow up computerized tomographic scan No solid organ injury	Left haemothorax Acute bleeding from right vertebral vessels Acute bleeding from the right kidney Moderate left perirenal Haematoma Multiple rib fractures Fracture 4th lumbar vertebrae Spinal cord injury	No free air No viscera injury Fracture of iliac crest Bullet lodged in right psoas muscle just beside right common iliac vein
<b>Management</b>	Exploratory laparotomy	Aggressive Resuscitation – unsuccessful	Conservative
<b>Intra operative findings</b>	Small bowel content in peritoneal cavity Two 0.5 cm perforation in the proximal jejunum 10 cm distal to the duodeno-jejunal flexure Both sites closed primarily with 3/0 PDS Single bullet fragment retrieved	N/A	N/A
<b>Total number of days in Hospital</b>	11 days	2 hours	3 days
<b>Final outcome:</b>	Unremarkable post operative recovery Discharged day 11	Fatal	Discharged on oral antibiotics. Complete recovery

trauma ranging from 6–21% [8]. Therefore many conclude that mandatory laparotomy is not required for all posterior gunshot wounds, and that clinical monitoring with appropriate imaging is suitable for a cohort of patients that present haemodynamically stable.

Penetrating injuries to the back/flank place many retroperitoneal structures at risk including the proximal duodenum, pancreas, kidneys, ureters, bladder, ascending and descending colon, major abdominal vessels, and rectum [4]. Due to the thickness of the back muscles, interposed bony structures and overlying subcutaneous tissues planes, there is considerable protection for intra-abdominal organs [7]. Therefore, such injuries can be subtle and may have delayed clinical signs [7]. To date, there are only sporadic reports in the literature that focus entirely on retroperitoneal trauma secondary to gunshot injuries [4]. Additionally, injuries to the small bowel from the retroperitoneal trajectory are relatively rare, and therefore easily overlooked. This case series highlights a variation of retroperitoneal gunshot injuries that occurred to three family members with considerable differences in clinical presentation, severity of injury and outcome.

*Case 1* involved a male who sustained two low-velocity shots to the back. On presentation he was haemodynamically stable, with no evidence of intra-abdominal injury and deemed suitable for conservative management (Fig. 1a Outlines initial CT scan). He developed a delayed small bowel perforation that occurred on day 6, which was evident both clinically and radiologically (Fig. 1b). He underwent laparotomy and two adjacent small bowel perforations involving the jejunum just distal to the duodeno-jejunal flexure were noted (Fig. 1c & d). These perforation sites were closed primarily with absorbable sutures. Post-operatively he made an excellent recovery. This is a rare occurrence, with no reports in the literature to our knowledge of a delayed small bowel perforation occurring with retroperitoneal gunshot injury. It highlights the high degree of caution that surgeons must have, and that clinical observation over several days may be required in some cases.



**Fig. 1.** a) Initial CT scan showing retained pellet fragment inferior to transverse colon. No bowel perforation was visualised at this time. There are also retained pellets in the posterior musculature of the back. b) Interval CT scan day 6 post admission showed significant free fluid intra-abdominally, likely originating from small bowel at the level of the foreign body, consistent with a delayed perforation of small bowel. c) Laparotomy demonstrating bullet fragment. d) Laparotomy demonstrating two small bowel perforations.

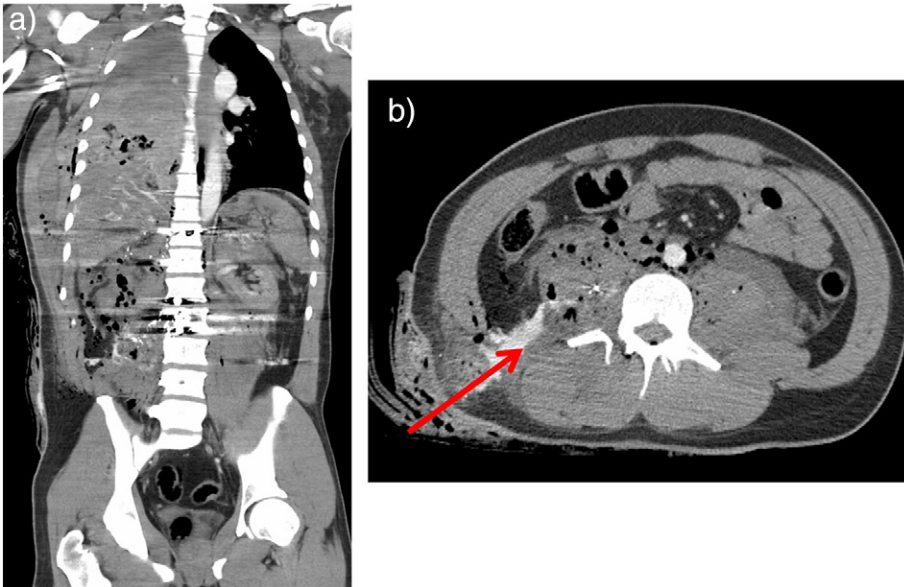
Case 2 describes a fatality. The patient presented with multiple high-velocity bullet wounds to the mid-upper back, chest and posterior flank. At presentation he was hemodynamically unstable. He had bilateral hemothorax, left-sided pneumothorax, hemorrhage from the right intervertebral vessels, multiple rib fractures and a severe spinal cord injury (Fig. 2a and b). Despite aggressive resuscitation he died prior to surgical intervention. He had three entry wounds, which resulted in substantial destructive nature for all structures in their path (especially due to the high velocity nature of the injury). Hemorrhage remains the leading cause of death in the first-hour after injury, accounting for >40% of all trauma deaths, as presented here.

Case 3 in contrast was a single low velocity bullet wound to the right flank at the level of the iliac crest. The patient was stable at presentation. CT imaging showed comminuted fracture of the anterior superior iliac spine, with the bullet fragment lodged in the right psoas muscle close to the common iliac vein (Fig. 3). It highlights how bullet trajectory can impact overall outcome. As previously documented, the presence of bony structures and muscles can create enough impedance to prevent significant injury, such as injury to common iliac vein in this case. This patient was managed conservatively, and discharged well 72-hours later.

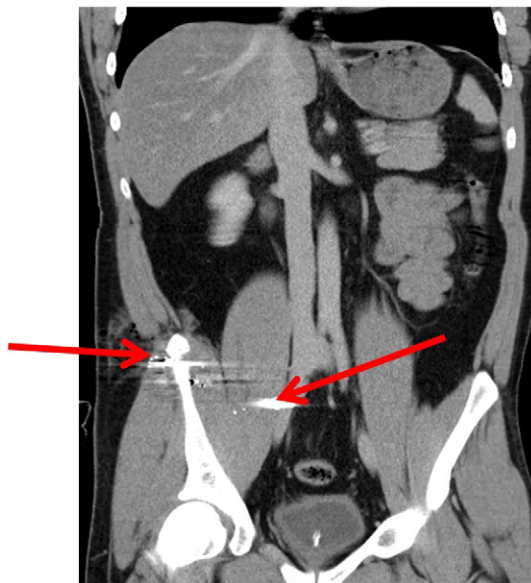
These cases highlight the considerable variability and degree of destruction that is inflicted by gunshot injuries. The need for accessible diagnostic imaging at presentation cannot be overstated. In addition, management of such injuries is expensive and requires good clinical judgment and surgical skills [9,10]. Overall, conservative management is advocated when patients present stable. Serial clinical examination with/without repeat imaging has been shown to be 'key' in defining those that require surgical intervention.

## Conclusion

Retroperitoneal trauma produces a wide array of injury patterns, resulting in considerable variation in management strategies. Though bullet trajectory is not always accurate at predicting injury pattern, it can aid in radiological assessment and management. There is paucity in the literature regarding retroperitoneal gunshot injuries. The occurrence of delayed small bowel injury is rare, and we highlight this case to potential treating surgeons. Ultimately, individual cases must be treated based on clinical stability, severity of injury and radiological findings. We believe patients must be observed for delayed complications.



**Fig. 2.** a) Right haemopneumothorax. Thoracostomy tube in situ (not demonstrated on this slice). Artefact is due to multiple bullet fragments. b) Cross-sectional image from CT shows extravasation of blood via entry wound.



**Fig. 3.** Coronal CT scan showing comminuted fracture of the anterior superior iliac spine and a bullet lodged in the psoas muscle in close proximity to the right common iliac vein.

## References

- [1] F. O'Kelly, T.K. Gallagher, K.T. Lim, et al., Gun Shot-101: an 8-year review of gunshot injuries in an Irish teaching hospital from a general surgical perspective, *Ir. J. Med. Sci.* 179 (2) (2010) 239–243.
- [2] D.C. Moore, Z.T. Yoneda, M. Powell, et al., Gunshot Victims at a Major Level I Trauma Center: A Study of 343,866 Emergency Department Visits, *J. Emerg. Med.* 44 (3) (2013) 585–591.
- [3] P.H. Navsaria, A.J. Nicol, R. Gandhi, et al., Selective Nonoperative Management in 1106 Patients With Abdominal Gunshot Wounds, *Ann. Surg.* 261 (4) (2015) 760–764.
- [4] R.K. Burns, H.S. Sariol, S.E. Ross, et al., Penetrating posterior abdominal trauma, *Injury* 25 (7) (1994) 429–431.
- [5] D.H. Livingston, R.F. Lavery, M.C. Lopreiato, et al., Unrelating violence: an analysis of 6,322 gunshot wound patients at a Level I trauma center, *J. Trauma Acute Care Surg.* 76 (1) (2013) 2–11.
- [6] K. Inaba, D. Demetriades, The nonoperative management of penetrating abdominal trauma, *Adv. Surg.* 41 (2007) 51–62.
- [7] G.C. Velmahos, D. Demetriades, E. Foianini, et al., A selective approach to the management of gunshot wounds to the back, *Am. J. Surg.* 174 (1997) 342–346.
- [8] J. Haan, K. Kole, A. Brunetti, et al., Nontherapeutic laparotomies revisited, *Am. J. Surg.* 69 (2003) 562–565.
- [9] C.A. Ordonez, M. Badiel, L.F. Pino, et al., Damage control resuscitation: Early decision strategies in the abdominal gunshot wounds using an easy “ABCD” mnemonic, *J. Trauma Acute Care Surg.* 73 (5) (2012) 1074–1107.
- [10] A. Cowey, P. Mitchell, J. Gregory, et al., A review of 187 gunshot wound admissions to a teaching hospital over a 54-month period: training and service implications, *Ann. R. Coll. Surg. Engl.* 86 (2004) 104–107.