

Locally Advanced Oral Tongue Cancer: Is Organ Preservation a Safe Option in Resource-Limited High-Volume Setting?

Muntazir Hussain¹, Muhammad Faisal^{1,2}, Muhammad Abu Bakar³, Tahir Muhammad¹, Saman Qadeer¹, Sameen Mohtasham¹, Raza Hussain¹, Arif Jamshed⁴

¹Department of Surgical Oncology, Division of Head and Neck Surgery, Shaukat Khanum Memorial Cancer Hospital and Research Centre, ⁴Department of Radiation Oncology, Shaukat Khanum Memorial Cancer Hospital and Research Centre, ³Department of Cancer Registry and Clinical Data Management, Shaukat Khanum Memorial Cancer Hospital and Research Centre, Lahore, Pakistan, ²Department of Head and Neck Surgery, Institute of Head and Neck Diseases, Evangelical Hospital, Vienna, Austria

Abstract

Background: Oral tongue is found to be the most common intraoral subsite with worse prognosis despite the use of multimodality treatments. Extensive resections have resulted in loss of form and function of tongue in advanced tumors. The objective of the study was to analyze the role of induction chemotherapy (IC) in intermediate to advanced staged oral tongue cancer for organ preservation and survival outcome in a developing country. **Materials and Methods:** The records of oral tongue cancer patients treated from 2007 to 2016 were retrospectively analyzed. **Results:** Eighty-one oral tongue cancer patients with advanced stage were treated using induction arm in 10 years. The median follow-up was 24 months with 3- and 5-year survival of 77% and 58%, respectively. IC has an overall response in 87% of the patients at primary site. The chemotherapy has completely resolved the nodal disease in 17% of the patients, but 23% of the patients had failed to respond. Only 21% of the patients received reconstruction using local or regional flaps. **Conclusion:** IC has shown encouraging results in advanced staged oral tongue cancers with function preservation and improved survival outcome in less privileged high-volume centers.

Keywords: High-volume center, induction chemotherapy, oral tongue, organ preservation, survival outcome

INTRODUCTION

Head-and-neck cancers are on the rising trend in third world countries and account for more than 550,000 cases diagnosed annually with a male-to-female ratio rising to 4:1.^[1,2] Conventionally advanced oral cancers have been treated with surgery followed by postoperative adjuvant radiation with or without chemotherapy based on adverse histopathological features. A major apprehension in this regard is excessive loss of tissue following surgery which translates into loss of function.^[3] Oral tongue has two vital functions, namely speech and swallowing. If a large part of oral tongue is removed, this leads to impairment of these functions.^[4] Oral tongue is found to be the most common intraoral subsite with worse prognosis despite the use of multimodality treatments.^[5] Locoregional recurrences (30%) and distant metastasis (25%) have still remained challenging with a dismal 5-year survival (50%).^[6,7] Many studies have shown promising results based on response to induction chemotherapy (IC) with an objective to increase overall and disease-free survival (DFS).^[8-10] Although multiple

trials afterward have not depicted expected results in terms of overall survival, the interest in using the induction arm as modality of treatment has resurfaced by studies in recent times.^[11-16] The aim of this study was to report the survival outcome in intermediate to advanced oral tongue cancer patients using IC followed by surgery and postoperative adjuvant treatment with effective tissue preservation.

MATERIALS AND METHODS

The retrospective records of 100 patients treated at a tertiary cancer hospital and research center, Lahore, Pakistan, from

Address for correspondence: Dr. Muhammad Faisal,
Shaukat Khanum Memorial Cancer Hospital, Lahore, Pakistan.
E-mail: maxfas@live.com

Received: 24-07-2019

Revised: 17-12-2019

Accepted: 31-01-2020

Published: 08-06-2020

This is an open access journal, and articles are distributed under the terms of the Creative Commons Attribution-NonCommercial-ShareAlike 4.0 License, which allows others to remix, tweak, and build upon the work non-commercially, as long as appropriate credit is given and the new creations are licensed under the identical terms.

For reprints contact: WKHLRPMedknow_reprints@wolterskluwer.com

How to cite this article: Hussain M, Faisal M, Abu Bakar M, Muhammad T, Qadeer S, Mohtasham S, *et al.* Locally advanced oral tongue cancer: Is organ preservation a safe option in resource-limited high-volume setting? *Ann Maxillofac Surg* 2020;10:158-63.

Access this article online

Quick Response Code:



Website:
www.amsjournal.com

DOI:
10.4103/ams.ams_166_19

2007 to 2016 have been analyzed. The inclusion criteria were previously untreated, biopsy-proven, and clinically intermediate to advanced staged (Stages II–IV) oral tongue squamous cell carcinoma. Those with incomplete medical record, lost to follow-up, and not completing treatment due to chemotherapy-related toxicity were excluded. The study has finally enrolled Eighty one (81) patients who were evaluated in a multidisciplinary tumor board setting. The diagnostic workup included history, physical examination, dental radiographs such as orthopantomogram, contrast-enhanced magnetic resonance imaging (MRI), chest X-ray, and baseline blood investigations. The study was granted permission from the institutional review board.

Treatment protocol

The eligible candidates received two cycles of IC followed by surgery and adjuvant treatment based on histopathological features. IC regimen consisted of two-drug combination: intravenous gemcitabine (1000 mg/m²) on days 1 and 8 and cisplatin (75 mg/m²) on day 1. The response to therapy (assessed in terms of reduction in tumor size and nodal disease) was measured by repeat MRI 2 weeks after completion of the last cycle and surgery performed within 4–6 weeks of IC. The patients who were nonresponders (no change or increase in size after two cycles of chemotherapy assessed by MRI) to chemotherapy were subjected to surgical resection followed by adjuvant treatment. The surgical treatment comprised partial glossectomy and neck dissection (Level 1–3) with flap reconstruction reserved only for those with loss of more than 30% of tongue musculature. The extent of resection was determined by clinical tumor palpation reinforced by postinduction MRI for tumor delineation. Following surgery, adjuvant treatment was offered based on adverse features (close or positive margins, extracapsular extension, multiple levels of nodal involvement, poor grade, and perineural or lymphovascular invasion). The response to IC was categorized into three groups and assessed on the final histopathology with no residual disease as complete responders, microscopic disease with reduction in size as major responders, and gross disease (minimal change in size) as partial responders. Response in the neck was categorized as responders (N0 from N+) or nonresponders (N + from N+).

Statistical analysis

SPSS software (version 23.0; SPSS, Chicago, IL, USA) was used for statistical analysis of the data. Mean \pm standard deviation (SD) was used for continuous variables, whereas frequencies and percentages were used for categorical variables. A paired *t*-test was used to check the mean difference between pre- and posttreatment tumor sizes. The Kaplan–Meier method was used to estimate survival as a function of time, and survival differences were analyzed by the log-rank test. Statistical significance was defined as a two-tailed *P* = 0.05.

Table 1: Baseline patients' characteristics

Variables	Categories	Total, n* (%)
Age (years)	Mean \pm SD	49.15 \pm 12.70
Sex	Male	45 (55.6)
	Female	36 (44.4)
Risk factors	No	49 (60.5)
	Yes	32 (39.5)
Grade	Poor	10 (12.3)
	Moderate	39 (48.1)
	Well	32 (39.5)
Neck dissection	Bilateral	17 (21.0)
	Ipsilateral	64 (79.0)
PNI	No	68 (84.0)
	Yes	13 (16.0)
LVI	No	79 (97.5)
	Yes	2 (2.5)
ENE	NA	1 (1.2)
	No	78 (96.3)
Status	Alive	58 (72)
	Death	23 (28)
Cause of death	Primary disease	22 (95.6)
	Other cause	1 (4.4)
Recurrence	No	56 (69.1)
	Yes	25 (30.9)
Site of recurrence	Local	10 (40.0)
	Locoregional	6 (24.0)
	Regional	6 (24.0)
	Distant	3 (12.0)

*81. SD=Standard deviation; PNI=Perineural invasion; LVI=Lymphovascular invasion; ENE=Extranodal extension; NA=Not available

RESULTS

Table 1 represents the baseline descriptions of 81 oral tongue squamous cell carcinoma patients, with a mean age of 49.10 \pm 13.04 years. There were 45 male and 36 female patients, and majority of them (60%) had a risk factor in the form of smoking, betel nut, and snuff dipping. Histopathology showed most of the cases to be either well or moderately differentiated, but poor differentiation has shown an adverse impact on survival. Ipsilateral neck dissection (Level 1–3) was performed in 64 (79%) patients, whereas 17 (21%) underwent bilateral neck dissection. The reason for bilateral neck dissection was the tumor crossing the midline in the preinduction period. During the last follow-up, 58 (72%) patients are alive, whereas 23 (28%) have died mostly of the primary disease. Only one patient has died of cardiac disease (myocardial infarction). Recurrence was reported in 31% of the patients. The most common pattern of failure was locoregional (88%), whereas only three patients had encountered a distant spread of the disease. No treatment-related deaths occurred. Hematological G3/G4 toxicity included neutropenia (13%/7%) and thrombocytopenia (5%/0%). The nonhematological toxicity observed (nausea, vomiting, and diarrhea) was only G1/G2.

Preinduction characteristics

Table 2 shows preinduction patients' characteristics. The tumor, node, metastasis (TNM) classification showed that 20 (25%) had Stage II disease, 31 (38%) had Stage III disease, and 29 (36%) had Stage IV disease. The T category presented 4 (5%) patients to be T1, 35 (43%) patients to be T2, 31 (38%) patients to be T3, and 11 (14%) to be T4. The mean pretreatment tumor size was found to be 3.96 ± 1.10 . Nodal staging has been further categorized into N0 46 (57%) and N+ 35 (43%).

Postinduction characteristics

Table 3 shows postinduction and surgery patients' characteristics. The mean postinduction tumor size was 2.33 ± 1.03 . The TNM staging showed that 12 (15%) patients had Stage 0 (T0N0M0), 27 (33%) had Stage I, 7 (9%) had Stage II, 18 (22%) had Stage III, and 17 (21%) had Stage IV disease. The T category has also shown a significant drift toward size reduction. Among them, there were 10 (12%) T0, 25 (31%) T1, 24 (30%) T2, 21 (26%) T3, and 1 (1%) T4 patients. The N category has been N0 53 (65%) and N+ 28 (35%).

The mean nodal yield was found to be 55.90 ± 26.79 , whereas the mean depth of invasion was 7.21 ± 5.22 . The mean tumor size observed postsurgery was 1.77 ± 1.37 . There was a statistical significant mean difference in pretreatment tumor size ($M = 3.96$, $SD = 1.10$) and posttreatment tumor size ($M = 2.33$, $SD = 1.03$), $P = 0.001$ [Table 4].

DISCUSSION

IC has a documented role in reducing the risk of micrometastasis and thus increasing progression-free and overall survival. Further, it can also predict the tumor's sensitivity to chemotherapy and helps differentiate the patients who can actually benefit from chemotherapy in the future or need radical surgery. Traditionally, IC using cisplatin (100 mg/m^2 on day 1) and fluorouracil (1000 mg/m^2 per day as continuous infusion for 5 days) has been the commonly used combination (plus fluorouracil [PF]) with potential benefit as indicated by meta-analysis of chemotherapy in head-and-neck cancer meta-analysis. The introduction of taxanes in PF regimen Taxanes, Platinum and 5-Fluorouracil (TPF) has shown a significant decrease in locoregional and distant failure documented by Blanchard *et al.*^[14] IC can also result in cytoreduction of gross tumors creating window for operability when surgery is otherwise more devastating. The concept of organ preservation (larynx) using IC was later introduced by VETERANS trial showing no survival difference but larynx preservation in 64% of the patients. The concept was further strengthened by EORTC trial with larynx preservation rate of 42% at 3 years. A series of trials afterward such as RTOG 91-11, GORTEC 200-2001, and TAX 324 have concluded that TPF have a role in functional larynx preservation. Several meta-analyses have demonstrated a decreased distant metastatic rate of about 7% and better progression-free survival in IC arm when compared with concurrent chemoradiotherapy (CRT).^[12,17-19]

Table 2: Pretreatment patients' characteristics

Variables	Categories	Total, n* (%)
Pretreatment tumor size (cm)	Mean±SD	3.96±1.10
Neoadjuvant chemotherapy cycles	Mean±SD	2.49±0.65
cT	1	4 (5)
	2	35 (43)
	3	31 (38)
	4	11 (14)
cN	0	46 (57)
	1	24 (30)
	2	11 (13)
cS	1	1 (1)
	2	20 (25)
	3	31 (38)
	4	29 (36)

*81. SD=Standard deviation

Table 3: Posttreatment patients' characteristics

Variables	Categories	Total, n* (%)
Posttreatment tumor size (cm)	Mean±SD	2.33±1.03
Postsurgery tumor size (cm)	Mean±SD	1.77±1.37
Closest margin (mm)	Mean±SD	3.74±2.93
Nodes removed	Mean±SD	55.90±26.79
DOI (mm)	Mean±SD	7.21±5.22
Pt	0	10 (12)
	1	25 (31)
	2	24 (30)
	3	21 (26)
	4	1 (1)
PN	0	53 (65)
	1	11 (14)
	2	17 (21)
PS	0	12 (15)
	1	27 (33)
	2	7 (9)
	3	18 (22)
	4	17 (21)

DOI=Depth of invasion; SD=Standard deviation; Pt=Pathological tumor size; PS=Pathological stage; PN=Pathological nodal size

Table 4: Mean difference of tumor size after induction chemotherapy

Variables	Categories	Total	P
Pre- and posttreatment tumor size (cm)	Mean difference±SD	1.63±1.11	0.001

SD=Standard deviation

Benasso *et al.* have performed a trial inducing gemcitabine as a part of alternating regimen to traditional cisplatin-5-fluorouracil combination in Stage IV head-and-neck tumors. The results have shown a complete response rate of 72% as

compared to 42% of the PF arm with an additional benefit of radiosensitization at the cost of Grade III and IV toxicities. Later, he reported low toxicity by reduced doses without affecting the survival.^[20,21]

Our hospital is among the few cancer centers in the country where we treat about 500 head-and-neck cancer patients a year with more than 200 patients treated by surgery with curative intent. This high volume combined with limited resources has put many restraints in terms of providing prolonged hospital stay, extensive reconstructive options, and financial cost. Based on our hospital's retrospective experience with the use of gemcitabine and cisplatin as an induction protocol in 2006, we have reported promising results in terms of overall response (86%) and low toxicity.^[22] Previous literature was more focused to address the role of IC in oral cavity and oropharyngeal cancers combined without taking into consideration the different entities of oral cavity tumors (human papillomavirus [HPV]- and treated primarily by surgery) and oropharynx (HPV + and treated primarily by radiation).^[23] The primary purpose of incorporating induction arm in our patients was to reduce the bulk of the disease followed by surgical resection without compromising much of the tongue musculature to maintain its form and function. The major concern was to look for safety margins and impact of IC on overall and DFS. The IC has resulted in complete resolution of tumor at primary site in 13% of the patients (complete responders), whereas 75% have shown major response. Only 12% have shown partial response in the final histopathology [Table 5].

In our study, with a median follow-up of 24 months, the 3- and 5-year survival was 77% and 58%, respectively [Figure 1]. The 3- and 5-year DFS was 68% and 62%, respectively [Figure 2]. The mean time to recurrence was 9 months, and 80% of the recurrences have been observed within 12 months of the completion of the treatment. The survival of oral tongue cancer patients has been reported to be poor (26%–40%) in intermediate to advanced staged (Stage III and IV) disease with conventional treatment modalities (surgery followed by CRT in operable or CRT upfront for inoperable tumors).^[24,25]

In general, the accepted criteria for oral tongue reconstruction is loss of more than 40% of tongue tissue, associated involvement of the floor of the mouth, and risk of orocervical communication following tumor resection in advanced tumors. There have been no randomized trials comparing flap versus no flap reconstruction. Functional outcomes are good following surgery irrespective of reconstructive method in smaller resections.^[26]

Table 5: Response to chemotherapy

Response to induction chemotherapy	n (%)	Recurrences (%)
Complete responders	10 (13)	2 (20)
Major responders	61 (75)	15 (28)
Partial responders	10 (12)	6 (60)

The cytoreduction of tumor volume has not been circumferentially uniform. It was important to know the margin status postsurgery and its impact on prognosis. The data showed margins to be clear in 22 (27%), close in 38 (47%), and involved in 21 (26%)

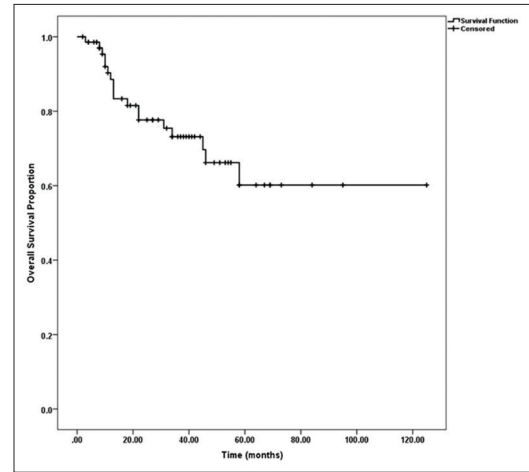


Figure 1: Overall survival

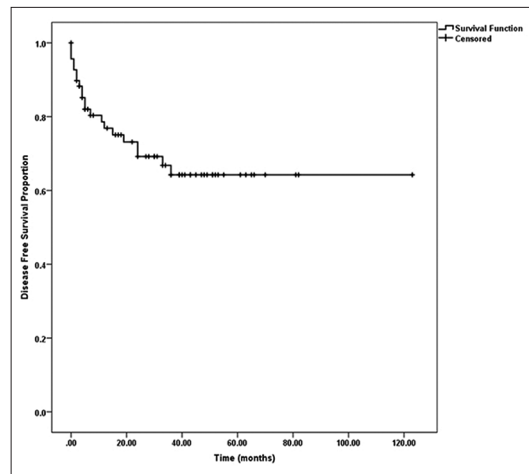


Figure 2: Disease-free survival

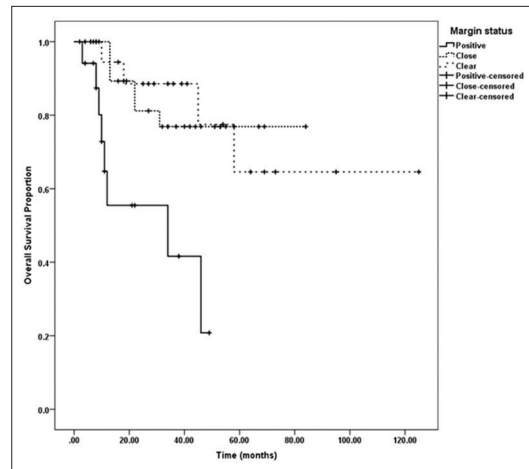


Figure 3: Overall survival graph (margin status)

Table 6: Margin status and recurrences

Margin status (mm)	n (%)	Recurrences (%)
Clear (>5)	22 (27)	5 (22)
Close (2-5)	38 (47)	5 (13)
Involved (≤1)	21 (26)	8 (38)

patients [Table 6]. Among those with close margins, 5 (22%) patients developed local recurrence which is not different from the ones with clear margins. Local recurrence with poor survival outcome [Figure 3] has found to be a concerning factor in those with involved margins where 8 (38%) patients have failed. The rate of occult metastasis was 10% ($n = 8$) where patients were N0 before the treatment, but histopathology showed occult nodal disease (N+). The chemotherapy has completely resolved the nodal disease in 14 (17%) patients, but on the other hand, 19 (23%) patients have shown persistent nodal disease (N+) despite showing reduction in primary tumor size post-IC. Almost 50% of these patients had high nodal disease volume, and half of them have encountered regional failure. All the patients who have shown complete nodal response were the ones with low-volume nodal disease.

Of all 13 regional recurrences, 10 (77%) occur in those patients who were node positive (N+) before the start of induction therapy, and among them, 50% had more than one node involved before treatment. In our series, only 22 patients were categorized as T2 and above after completion of IC. These were reconstructed using free or regional flaps. The modification of extent of surgery not resulting in larger defects has been a subject of interest in the future for these resectable intermediate to advanced staged tumors. Keeping in view the dynamic nature of tongue musculature, this approach may result in avoidance of reconstruction using nonsensate free flap without compromising speech dysfunction. Obviously, these patients return to intelligible speech and swallowing function but with prolonged rehabilitation.

Our study has several limiting factors. First, the prospective comparative study using surgery followed by radiation in the same subset of patients is missing. Second, biomarkers need to be identified to select the subset of patient respondents to chemotherapy. Third, this approach needs further validation in clinical trials.

CONCLUSION

IC has shown promising results in locally advanced low nodal volume intermediate to advanced staged oral tongue cancer with functional tongue preservation and improved overall survival. The reduction in tumor volume is more significant at primary site, but the response at high-volume nodal disease has been dismal. Our study has recommended the selected group of patients who can benefit from induction arm for functional and survival outcome in less privileged high-volume centers.

Financial support and sponsorship

Nil.

Conflicts of interest

There are no conflicts of interest.

REFERENCES

- Jemal A, Siegel R, Ward E, Murray T, Xu J, Thun MJ. Cancer statistics, 2007. *CA Cancer J Clin* 2007;57:43-66.
- Ferlay J, Shin HR, Bray F, Forman D, Mathers C, Parkin DM. Estimates of worldwide burden of cancer in 2008: GLOBOCAN 2008. *Int J Cancer* 2010;127:2893-917.
- Robbins KT, Samant S, Vieira F, Kumar P. Presurgical cytoreduction of oral cancer using intra-arterial cisplatin and limited concomitant radiation therapy (Neo-RADPLAT). *Arch Otolaryngol Head Neck Surg* 2004;130:28-32.
- Youmans SR, Stierwalt JA. Measures of tongue function related to normal swallowing. *Dysphagia* 2006;21:102-11.
- Gosselin BJ. Malignant Tumours of the Mobile Tongue: Medscape; 2015. Available from: <http://emedicine.medscape.com/article/847428-overview#showall>. [Last accessed on 2016 Jul 03].
- Warnakulasuriya S. Global epidemiology of oral and oropharyngeal cancer. *Oral Oncol* 2009;45:309-16.
- Gyawali B, Shimokata T, Honda K, Ando Y. Chemotherapy in locally advanced head and neck squamous cell carcinoma. *Cancer Treat Rev* 2016;44:10-6.
- Vidal L, Ben Aharon I, Limon D, Cohen E, Popovtzer A. Role of induction chemotherapy prior to chemoradiation in head and neck squamous cell cancer-systematic review and meta-analysis. *Cancer J* 2017;23:79-83.
- Kim R, Hahn S, Shin J, Ock CY, Kim M, Keam B, *et al.* The effect of induction chemotherapy using docetaxel, cisplatin, and fluorouracil on survival in locally advanced head and neck squamous cell carcinoma: A meta-analysis. *Cancer Res Treat* 2016;48:907-16.
- Busch CJ, Tribius S, Schafhausen P, Knecht R. The current role of systemic chemotherapy in the primary treatment of head and neck cancer. *Cancer Treat Rev* 2015;41:217-21.
- Blanchard P, Baujat B, Holostenco V, Bourredjem A, Baey C, Bourhis J, *et al.* Meta-analysis of chemotherapy in head and neck cancer (MACH-NC): A comprehensive analysis by tumour site. *Radiother Oncol* 2011;100:33-40.
- Ma J, Liu Y, Yang X, Zhang CP, Zhang ZY, Zhong LP. Induction chemotherapy in patients with resectable head and neck squamous cell carcinoma: A meta-analysis. *World J Surg Oncol* 2013;11:67.
- Marta GN, Riera R, Bossi P, Zhong LP, Licitra L, Macedo CR, *et al.* Induction chemotherapy prior to surgery with or without postoperative radiotherapy for oral cavity cancer patients: Systematic review and meta-analysis. *Eur J Cancer* 2015;51:2596-603.
- Blanchard P, Bourhis J, Lacas B, Posner MR, Vermorken JB, Cruz Hernandez JJ, *et al.* Taxane-cisplatin-fluorouracil as induction chemotherapy in locally advanced head and neck cancers: An individual patient data meta-analysis of the meta-analysis of chemotherapy in head and neck cancer group. *J Clin Oncol* 2013;31:2854-60.
- Qian X, Ma C, Hoffmann TK, Kaufmann AM, Albers AE. Taxane-cisplatin-fluorouracil as induction chemotherapy for advanced head and neck cancer: A meta-analysis of the 5-year efficacy and safety. *Springerplus* 2015;4:208.
- Zhang L, Jiang N, Shi Y, Li S, Wang P, Zhao Y. Induction chemotherapy with concurrent chemoradiotherapy versus concurrent chemoradiotherapy for locally advanced squamous cell carcinoma of head and neck: A meta-analysis. *Sci Rep* 2015;5:10798.
- Gau M, Karabajakian A, Reverdy T, Neidhardt EM, Fayette J. Induction chemotherapy in head and neck cancers: Results and controversies. *Oral Oncol* 2019;95:164-9.
- Pignon JP, Le Maître A, Maillard E, Bourhis J; MACH-NC Collaborative Group. Meta-analysis of chemotherapy in head and neck cancer (MACH-NC): An update on 93 randomised trials and 17,346 patients. *Radiother Oncol* 2009;92:4-14.

19. Ma J, Liu Y, Huang XL, Zhang ZY, Myers JN, Neskey DM, *et al.* Induction chemotherapy decreases the rate of distant metastasis in patients with head and neck squamous cell carcinoma but does not improve survival or locoregional control: A meta-analysis. *Oral Oncol* 2012;48:1076-84.
20. Benasso M, Merlano M, Sanguineti G, Corvò R, Numico G, Ricci I, *et al.* Gemcitabine, cisplatin, and radiation in advanced, unresectable squamous cell carcinoma of the head and neck: A feasibility study. *Am J Clin Oncol* 2001;24:618-22.
21. Benasso M, Vigo V, Bacigalupo A, Ponzanelli A, Marcenaro M, Corvò R, *et al.* A phase II trial of low-dose gemcitabine and radiation alternated to cisplatin and 5-fluorouracil: An active and manageable regimen for Stage IV squamous cell carcinoma of the head and neck. *Radiother Oncol* 2008;89:44-50.
22. Jamshed A, Hussain R, Ahmed S. Cisplatin plus gemcitabine (GC) as induction chemotherapy in locally advanced head and neck cancer (HANC). *J Clin Oncol* 2007;18 Suppl 25:6073-73.
23. Furness S, Glenny AM, Worthington HV, Pavitt S, Oliver R, Clarkson JE, *et al.* Interventions for the treatment of oral cavity and oropharyngeal cancer: Chemotherapy. *Cochrane Database Syst Rev* 2010;9:CD006386.
24. Spiotto MT, Jefferson G, Wenig B, Markiewicz M, Weichselbaum RR, Koshy M. Differences in survival with surgery and postoperative radiotherapy compared with definitive chemoradiotherapy for oral cavity cancer: A national cancer database analysis. *JAMA Otolaryngol Head Neck Surg* 2017;143:691-9.
25. Piccirillo JF, Costas I, Reichman ME. Cancers of the head and neck in SEER survival monograph: Cancer survival among adults: Us SEER program, 1988-2001. In: Lag RY, Keel GE, Eisner MP, editors. *Patient and Tumor Characteristics*. Bethesda, MD: National Cancer Institute, SEER Program, NIH; 2007.
26. Lam L, Samman N. Speech and swallowing following tongue cancer surgery and free flap reconstruction – A systematic review. *Oral Oncol* 2013;49:507-24.