

# Keloids and Hypertrophic Scars: Update and Future Directions

Chenyu Huang, MD, PhD\*†  
 George F. Murphy, MD‡  
 Satoshi Akaishi, MD, PhD\*§  
 Rei Ogawa, MD, PhD, FACS\*

**Summary:** The development of cutaneous pathological scars, namely, hypertrophic scars (HSs) and keloids, involves complex pathways, and the exact mechanisms by which they are initiated, evolved, and regulated remain to be fully elucidated. The generally held concepts that keloids and HSs represent “aberrant wound healing” or that they are “characterized by hyalinized collagen bundles” have done little to promote their accurate clinicopathological classification or to stimulate research into the specific causes of these scars and effective preventative therapies. To overcome this barrier, we review here the most recent findings regarding the pathology and pathogenesis of keloids and HSs. The aberrations of HSs and keloids in terms of the inflammation, proliferation, and remodeling phases of the wound healing process are described. In particular, the significant roles that the extracellular matrix and the epidermal and dermal layers of skin play in scar pathogenesis are examined. Finally, the current hypotheses of pathological scar etiology that should be tested by basic and clinical investigators are detailed. Therapies that have been found to be effective are described, including several that evolved directly from the aforementioned etiology hypotheses. A better understanding of pathological scar etiology and manifestations will improve the clinical and histopathological classification and treatment of these important lesions. (*Plast Reconstr Surg Glob Open* 2013;1:e25; doi:10.1097/GOX.0b013e31829c4597; Published online 2 July 2013.)

The development of cutaneous pathological scars, namely, hypertrophic scars (HSs) and keloids, involves complex pathways, and the exact mechanisms by which they are initiated, evolved, and

are regulated remain to be fully elucidated. The efforts to understand the pathogenesis of these scars are complicated further by the fact that the clinical diagnosis does not always correlate with the histological diagnosis. This is because there is conflict regarding the precise histopathological criteria that distinguish keloids from HS, which arises from the fact that the pathological manifestations of these lesions overlap.<sup>1</sup> Thus, the generally held concepts that keloids and HSs represent “aberrant wound healing” or that they are “characterized by hyalinized collagen bundles” have done little to promote their accurate clinicopathological classification or to stimulate research into the specific causes of these scars and effective interventions.

To overcome this barrier, it is necessary to elucidate the relevant clinical and histopathological manifestations of these important lesions and to understand

*From the \*Department of Plastic, Reconstructive and Aesthetic Surgery, Nippon Medical School, Tokyo, Japan; †Department of Plastic Surgery, Meitan General Hospital, Beijing, China; ‡Program in Dermatopathology, Department of Pathology, Brigham and Women’s Hospital, Harvard Medical School, Boston, Mass.; and §Division of Plastic and Reconstructive Surgery, Department of Surgery, Stanford University, Stanford, Calif.*

*Received for publication February 27, 2013; accepted May 16, 2013.*

*Copyright © 2013 American Society of Plastic Surgeons. Unauthorized reproduction of this article is prohibited. This is an open-access article distributed under the terms of the Creative Commons Attribution-NonCommercial-NoDerivatives 3.0 License, where it is permissible to download and share the work provided it is properly cited. The work cannot be changed in any way or used commercially.*

DOI: 10.1097/GOX.0b013e31829c4597

**Disclosure:** *The authors have no financial interest to declare in relation to the content of this article. The Article Processing Charge was paid by the authors.*

how these manifestations relate to each other. In this article, we review the most recent findings regarding the pathology and pathogenesis of keloids and HSs. In particular, the significant roles of the extracellular matrix (ECM) and the epidermal and dermal layers of skin in scar pathogenesis are examined. The aberrations of HSs and keloids in terms of the inflammation, proliferation, and remodeling phases of the wound healing process are also described. Finally, the current hypotheses of pathological scar etiology that should be tested by basic and clinical investigators are detailed. Effective therapies, including several that evolved directly from the aforementioned etiology hypotheses, are also described.

### PHASES IN PATHOLOGICAL SCAR FORMATION

Pathological scars are generally accepted to be the result of prolonged, aberrant wound healing that involves excessive fibroblast participation and collagen deposition. In normal wound healing, wounding is rapidly followed by an initial inflammatory phase where the fibrin clot releases chemotactic factors that initiate leukocyte migration into the wounded area. Neutrophils are among the earliest cells to infiltrate. They are eventually replaced with macrophages; this event marks the end of the early inflammatory phase and the beginning of the late inflammatory phase.<sup>2</sup> The proliferation phase then follows. In abnormal wound healing, abundant macrophages inappropriately release cytokines during the transition between the late inflammatory and proliferation phases. This prolongs inflammation and delays the healing response. This is a key event that drives the formation of keloids and HSs.<sup>1,3</sup> Notably, wounds devoid of neutrophils heal normally,<sup>4</sup> which suggests that neutrophils are not necessary for the participation of macrophages in normal wound healing. The proliferation phase is followed by the remodeling phase. Here, new ECM molecules are deposited in an orderly sequence: fibronectin, followed by collagen type III, and then collagen type I.<sup>5</sup> Because of this collagen remodeling, the strength of the scar tissue increases gradually, and it reaches a plateau about 7 weeks after wounding. The resulting maximum scar tissue tensile strength is 70% that of normal skin (Fig. 1).<sup>6,7</sup>

### CELLULAR AND EXTRACELLULAR ALTERATIONS IN EPIDERMAL AND DERMAL LAYERS

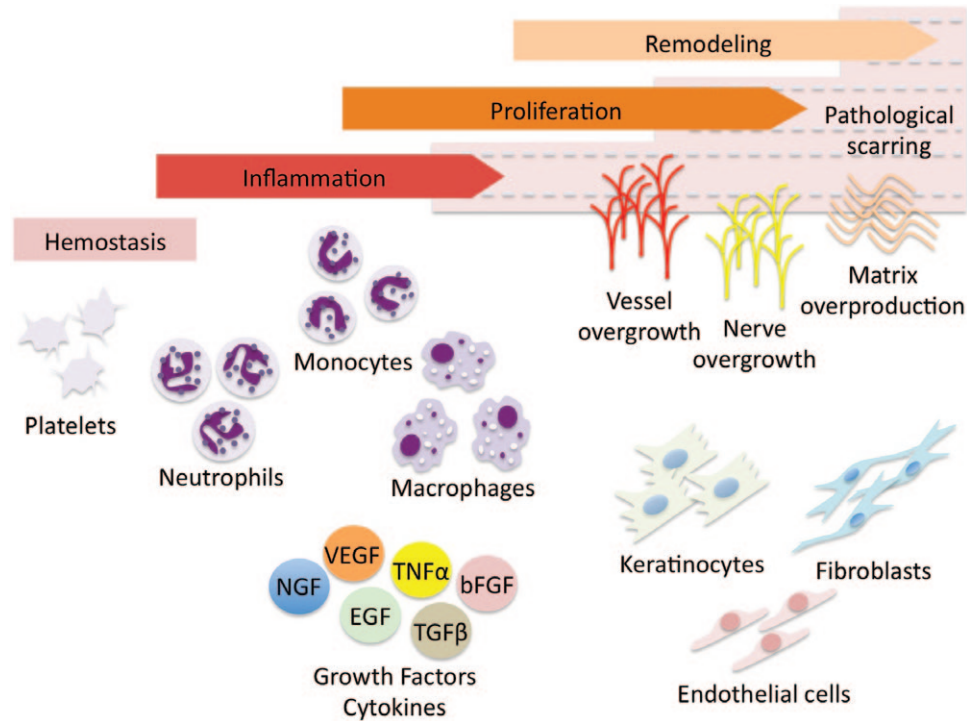
The typical pathognomonic characteristics of keloids are the presence of thickened and hyalinized (“keloidal”) collagen.<sup>8</sup> By contrast, HSs are con-

trasted by the expression of  $\alpha$ -smooth muscle actin ( $\alpha$ -SMA) and whorl-like or nodular arrangements of collagen fibers.<sup>9</sup> These features of HSs and keloids are associated with important changes in cells and the ECM in the epidermal and dermal layers.

#### The Epidermal Layer

The primary event in the formation of HSs and keloids is traditionally regarded to be fibrosis in the dermal layer. However, recent work suggests that the epidermis and its cross talk with the underlying dermis play a significant role in cutaneous scar pathology. The epidermis of HSs overexpresses cyclooxygenase-1 compared to the epidermis of normal skin and keloid specimens, whereas the epidermis of keloids overexpresses cyclooxygenase-2 compared to the epidermis of normal skin and HS samples. These findings underline the importance of epithelial–mesenchymal interactions in cutaneous scar pathogenesis.<sup>10</sup>

Growing evidence shows that epidermal Langerhans cells (LCs) and keratinocytes participate actively in scar pathogenesis. Relative to normal scars, HSs have increased numbers of epidermal LCs, increased epidermal interleukin-4 expression, and reduced epidermal interleukin-1 $\alpha$  expression, which indicates that the epidermal regulation of dermal remodeling is aberrant in HS formation.<sup>11,12</sup> By contrast, in keloids, the intraepidermal LC numbers do not differ significantly from those in normal scars or normal skins but increased infiltration of cells such as T cells, B cells, and alternative macrophages (M2) is observed. This supports the notion that keloids may be driven in part by T cell–keratinocyte–fibroblast interactions.<sup>13</sup> Epidermal keratinocytes intercommunicate with underlying fibroblasts, and this intercommunication plays an important role in HS and keloid formation. In keloids, keratinocytes induce fibroblasts to secrete connective tissue growth factor in a paracrine fashion.<sup>14</sup> Connective tissue growth factor is a cofactor or a downstream mediator of the role of transforming growth factor  $\beta$  in enhancing fibrosis. Keratinocytes also directly increase the proliferation of underlying dermal fibroblasts while decreasing their collagen production.<sup>15</sup> In HS, the keratinocytes are activated, with enhanced expression of keratins K6 and K16. This activation may delay reepithelialization, prolong epidermal inflammation, and invoke abnormal epidermal–mesenchymal interactions.<sup>16</sup> These observations suggest that wounds such as severe thermal injuries may tend to become hypertrophic because the collagen production of the fibroblasts is not adequately regulated by keratinocytes and their products; this ultimately results in excessive collagen production.



**Fig. 1.** Wound healing in pathological scars is characterized by a prolonged and stronger inflammation phase with inappropriately released cytokines followed by a subsequent delay in the healing response. bFGF, basic fibroblast growth factor; EGF, epithelial growth factor; NGF, nerve growth factor; TGF $\beta$ , transforming growth factor  $\beta$ ; TNF $\alpha$ , tumor necrosis factor  $\alpha$ ; VEGF, vascular endothelial growth factor.

### The Dermal Layer

#### *Dermal Constituents: Collagen, Hyaluronan, and Fibronectin*

Collagen forms most of the 2 dermal layers (papillary and reticular dermis) and is the main component in both HSs and keloids. In HSs, the collagen fibers that run parallel to the epithelial surface in normal skin are replaced by an expanded dermis that is composed of flatter and less clearly demarcated, loosely arrayed wavy collagen bundles that are somewhat fragmented and shortened (although the majority of the bundles still run parallel to the epithelial surface).<sup>17</sup> In keloids, the dermis is even more expanded. The collagen bundles and the fibers, which are composed of numerous fibrils that are closely packed together, are thicker and have larger bundle distances (the average distance between the centers of the collagen bundles) than those in normal skin, normotrophic scars, and HSs.<sup>18</sup> Moreover, the large, hyalinized, and strongly eosinophilic collagen (keloidal) fibers are randomly oriented in swirls and whorls and vary in their length.<sup>17,19</sup> This thickened, hyalinized collagen is used for differential diagnosis even though it is only detected in 55% of keloid specimens.<sup>8</sup> Keloid scars that lack detectable hyalinized collagen can be diagnosed instead on the basis of other characteristic features, namely, a non-

flattened epidermis, a non-fibrotic papillary dermis, a tongue-like advancing edge, horizontal cellular fibrous bands in the upper reticular dermis, and the presence of prominent fascia-like bands.<sup>8</sup>

Differential diagnosis can also be made on the basis of the collagen fiber composition: in keloids, type I procollagen levels are increased (compared to normal skin), and this is paralleled with an increase in its messenger RNA (mRNA) levels. However, type III procollagen mRNA levels are unaltered. Thus, the type I/III procollagen mRNA ratio in keloids is markedly elevated (22.1) relative to the ratio in normal skin (5.2).<sup>20</sup> By contrast, as shown by another study, in HS, the type I/III collagen ratio is on average 7.73; this is significantly lower than the ratio of keloids (17.28) and similar to the ratio of normal skin (6.28). The pretranscriptional regulation of collagen I production is impaired in both scar types, whereas the posttranscriptional regulation is impaired in keloids only.<sup>21</sup>

Notably, keloid cell cultures also show lower degradation of newly synthesized collagen polypeptides than normal controls, which suggests that the accumulation of collagen may also be due to the reduced degradation of these polypeptides.<sup>22</sup> Similarly, there is a significant reduction in collagenase mRNA and activity in HS fibroblasts; this supports the possibility that these factors contribute to the

excessive deposition of collagen in these aberrant scars.<sup>23</sup>

Unlike normal skin, both keloids and HSs have dermal nodules that are composed of focal aggregates of fibroblasts and randomly oriented collagen fibers. One study showed that the borders of these dermal nodules are well demarcated in HSs but less distinct in keloids.<sup>24</sup> Another study suggested that dermal nodules are a histological characteristic of HSs that are absent in keloids.<sup>9</sup>

Hyaluronan and fibronectin are also indispensable dermal ECM ingredients in pathological scars. In HSs, hyaluronan is mainly found as a narrow strip in the papillary dermis, whereas in keloids it is primarily detected in the thickened granular and spinous layers of the epidermis.<sup>25</sup> With regard to fibronectin, both keloids and HS have more fibronectin than normal skin. In HSs, it is diffusely located in a linear or curling arrangement throughout the dermis,<sup>26</sup> whereas in keloids it is found intensely positive in the intercellular matrix.<sup>27</sup>

#### ***Roles of Dermal Fibroblasts***

The excessive ECM in HSs and keloids is caused by the accumulation of dermal fibroblasts. This is the result of imbalances between fibroblast proliferation and apoptosis and between the subsequent protein products of fibroblasts. With regard to fibroblast proliferation, while fibroblasts are the main cellular ingredients in normal dermal scars, they occur at higher densities in HSs and keloids. Keloids differ from HSs in having a higher proliferating cell nuclear antigen expression, which indicates that the fibroblasts in keloids are more proliferative.<sup>28</sup> With regard to fibroblast apoptosis, keloid-derived fibroblasts are significantly resistant to Fas-mediated apoptosis, in contrast to HS-derived fibroblasts.<sup>29</sup> This is supported by the fact that HSs can be induced in mice by applying mechanical stress early during the proliferative phase of wound healing: this upregulates the expression of the pro-survival marker Akt and inhibits cellular apoptosis.<sup>30</sup> Delayed fibroblast apoptosis may be responsible for the characteristic paucity of fibroblasts in the center of keloids: it is possible that this delay allows the cells to produce vast amounts of ECM before they eventually disappear, leaving only an acellular collagenous mass.

#### ***Roles of Dermal Mast Cells***

Many studies have examined how the numbers and activities of mast cells (MCs) change in pathological scarring and how they interact with fibroblasts. In keloids, MCs are activated, as indicated by the upregulated expression of their specific activation marker MC  $\beta$ -tryptase.<sup>31</sup> In HSs, the number of MCs is not increased compared to the number in normal scars.<sup>11</sup>

MC activation leads to the release via degranulation of biological mediators that are known to promote fibrogenesis in scars. These mediators include histamine, which can stimulate the collagen synthesis of keloid fibroblasts<sup>32,33</sup>; tryptase, which can promote the procollagen mRNA synthesis of normal dermal fibroblasts and stimulate their chemotaxis<sup>34</sup>; and chymase, which can cleave procollagen type I and thereby facilitate collagen fibril formation.<sup>35</sup> A number of interactions between MCs and fibroblasts may also participate in the induction of fibrosis. For example, fibroblast-derived stem cell factor upregulates the expression and synthesis in MCs of monocyte chemoattractant protein-1, which in turn enhances collagen  $\alpha 1$ (I) mRNA expression in fibroblasts.<sup>36</sup> In addition, MCs may activate fibroblasts through gap junction intercellular communication, thereby promoting profibrotic fibroblast activities.<sup>37</sup> Such heterocellular gap junction intercellular communication between MCs and fibroblasts may also upregulate  $\alpha$ -SMA and thereby induce the transformation of fibroblasts into myofibroblasts. Indeed, knockdown in MCs of connexin-43 (the gap junction channel structural protein) retards that transformation.<sup>38</sup> Notably, in pigs that produce some features of human HSs after they are wounded, the MC stabilizer ketotifen reduces scar formation and wound contraction: the ketotifen-treated pigs exhibit thinner and less dense collagen fibers and lower numbers of  $\alpha$ -SMA<sup>+</sup> myofibroblasts than the untreated pigs.<sup>39</sup>

### **HYPOTHESES ON THE ETIOLOGY OF PATHOLOGICAL SCARRING**

Many studies have sought to describe and explain the pathogenesis of pathological scars, mainly from the perspectives of genetics, mechanics, endocrinology, metabolism, circulation, immunology, and nutrition.

#### **Keloid Genetics**

The involvement of familial inheritance is indicated by clinical evidence showing that patients with darker skin are 15 times more likely to develop pathological scars, primarily keloids, and that these scars are absent in albinos.<sup>6</sup> To date, potential keloid-associated loci in Japanese, African-American, and Han Chinese families have been identified on chromosomes 2q23, 7p11,<sup>40</sup> and 10q23.31,<sup>41</sup> respectively, although the responsible genes have not yet been identified. Moreover, genome-wide association studies have shown that in the Japanese population, 4 SNP (single nucleotide polymorphism) loci (rs873549, rs1511412, rs940187, and rs8032158) in 3 chromosomal regions (1q41, 3q22.3–23, and 15q21.3) exhibit significant

associations with keloids. Of these, rs873549 demonstrated the most significant association.<sup>42</sup>

### Mechanics Theory

The skin injury-wound tension theory is a milestone in our understanding of keloid formation. Keloids are frequently seen on the anterior chest and scapular regions but rarely on the scalp and anterior lower legs; this pattern correlates closely with the frequencies with which these body regions are subjected to local physical tension or movement.<sup>43,44</sup> Such site specificity can change when circumstances alter the local mechanics. For example, Africans and African-Americans often develop scalp keloids because their tightly braided hair styles result in increased skin tension.<sup>45</sup> In addition, the characteristic shapes of keloid scars, namely, the butterfly, crab's claw, and dumbbell shapes, are largely determined by the direction of the local mechanical forces on the skin.<sup>46</sup> Our previous review has described the potential molecular signaling pathways behind this phenomenon.<sup>47</sup>

### Endocrinological Hypothesis

Endocrinology-based theories suggest that pathological scarring may be caused by physiological hyperactivity of the sebaceous gland. The sebum or sebocyte hypothesis is particularly attractive as it explains the distribution and behavior of keloids. Keloids are rare in parts of the body that lack sebaceous glands, such as the palms and soles; they are also rare in animals that lack sebaceous glands. Moreover, sebum production is highly active in adolescence and early adulthood, which are periods that are associated with high incidences of keloids.<sup>48</sup>

### Metabolic, Circulatory, Immunological, and Nutritional Points of View

Several theories revolving around metabolic, circulatory, immunological, and nutritional issues have been proposed. Abnormal metabolic products have been detected in HSs and keloids. Keloids and HSs have higher adenosine triphosphate (ATP) levels; moreover, ATP levels in keloids are still high 10 years after the injury, although as time passes after the trauma these ATP levels drop.<sup>49</sup> The possibility that abnormal scarring is associated with increased metabolic activity is supported by the high oxygen consumption rate and insufficient oxygen diffusion in HSs and keloids.<sup>50</sup> However, it is unclear how these metabolic changes, including hypoxia in the central part of keloids, contribute to the formation of pathological scars and whether they are causes or results.

With regard to circulation dynamics, many cases of severe keloid are associated with high blood pressure (hypertension).<sup>51,52</sup> An analysis of 100 consecu-

tive patients with keloid in our department revealed that patients with large keloids (more than 10 cm<sup>2</sup>) were significantly more likely to have hypertension than patients with mild keloids (less than 10 cm<sup>2</sup>).<sup>51</sup> This study suggests that either hypertension adversely affects keloid tissues at a physiological level (eg, by elevating tissue pressure, capillary growth, or endothelial damage) or keloids and hypertension share an etiological mechanism.

Immunological mechanisms may also contribute to scar pathogenesis: the eluates of keloids but not HSs contain antinuclear antibodies against fibroblasts.<sup>53</sup> However, the precise role that these antinuclear antibodies play in scar pathogenesis is unclear. In the nutritional hypothesis, it is suggested that pathogenic scars are caused by inadequate fatty acid nutrition. This hypothesis is still being developed by assessing patients with keloids for associations between immune or inflammatory responses and nutrition with fatty acids.<sup>19</sup>

It should be noted that the cause-effect relationship between the various proposed causes in these hypotheses and pathological scar formation remains to be verified and further delineated by future studies.

## CURRENT CLINICAL THERAPIES FOR PATHOLOGICAL SCARRING

Several clinical approaches have proved to be effective for treating HSs and keloids and preventing their recurrence. The most popular methods are direct surgical excision with postsurgical radiotherapy, cryotherapy, and laser therapy. These methods focus on directly removing the accumulated cells and ECM in the pathogenic scars. Other approaches are based on cytotoxic agents such as bleomycin-puncture<sup>54</sup> or 5-fluorouracil-tattoo.<sup>55</sup> The aim of the latter methods is to reduce cellular division and scar bulk. Several other effective methods have been devised on the basis of the etiological theories described above. These include methods that are directly based on the mechanics theory. These tension-reduction or shielding methods aim to prevent the development of scars and include the use of z-plasties, w-plasties, and small-wave incision design,<sup>56</sup> local flaps to cover the wound, subcutaneous/fascial sutures,<sup>57</sup> and silicon sheeting.<sup>58</sup> Similarly, another approach, the application of snake oil in traditional African medicine, is a nutrition-based therapy that seems to have some efficacy.<sup>59</sup> Finally, other interventions relate to some extent to the immunomodulation theory described above: they include imiquimod 5% cream application.<sup>60</sup> However, the exact mechanisms involved remain to be clarified.

## FUTURE PERSPECTIVES

Pathologists and surgeons share a number of questions and interests regarding pathological scars: (1) Can a deeper understanding of aberrant scar pathogenesis be obtained by comparing pathological scars to local tumors such as basal cell carcinomas? Keloids seem to share several features with tumors. These include their ability to “invade” into adjacent healthy tissue without spontaneous regression, their strong resistance to apoptosis, and their tendency to recur after surgical excision. In addition, like basal cell carcinoma, keloids are aggressive locally: they generally do not have the malignant potential for metastasis. It would be of interest to identify the key factors that keep keloids and basal cell carcinoma confined vertically in the dermis. (2) Could comparative studies with stem cells shed light on the pathogenic mechanisms behind keloids/HSs? A recent study showed that keloid-derived mesenchymal-like stem cells isolated from keloid scalp tissues could differentiate into adipocytes, osteoblasts, chondrocytes, smooth muscle cells, and angiogenic endothelial cells.<sup>61</sup> It has also been proposed that mesenchymal stem cells may participate in keloid pathogenesis by differentiating toward keloid formation and progression.<sup>62</sup> Thus, could the initiation of pathological scars relate to stem cell-like functions of keloid cells?

In summary, HSs and keloids are the result of aberrant wound healing. The pathogenesis of these pathological scars involves cellular and ECM components in both the epidermal and dermal layers that are regulated by a wide array of interfering factors in the inflammation, proliferation, and remodeling phases. Concerted efforts by pathologists and plastic surgeons are needed to fuel the research that will unravel the mechanisms that underlie the formation of HS and keloids. This research is likely to be extremely beneficial in terms of identifying further preventative and therapeutic methods.

**Rei Ogawa, MD, PhD, FACS**  
 Department of Plastic  
 Reconstructive, and Aesthetic Surgery  
 Nippon Medical School  
 1-1-5 Sendagi Bunkyo-ku  
 Tokyo 113-8603, Japan  
 E-mail: r.ogawa@nms.ac.jp

## REFERENCES

- Huang C, Akaishi S, Hyakusoku H, et al. Are keloid and hypertrophic scar different forms of the same disorder? A fibroproliferative skin disorder hypothesis based on keloid findings. *Int Wound J*. 2012 Nov 22. [Epub ahead of print].
- Sahl WJ Jr, Clever H. Cutaneous scars: part I. *Int J Dermatol*. 1994;33:681-691.
- Wahl SM, Wahl LM, McCarthy JB. Lymphocyte-mediated activation of fibroblast proliferation and collagen production. *J Immunol*. 1978;121:942-946.
- Simpson DM, Ross R. The neutrophilic leukocyte in wound repair: a study with antineutrophil serum. *J Clin Invest*. 1972;51:2009-2023.
- Clark RAF. Wound repair: overview and general consideration. In: Clark RAF, ed. *The Molecular and Cellular Biology of Wound Repair*. 2nd ed. New York: Plenum Press; 1996:3-50.
- Miller MC, Nanchahal J. Advances in the modulation of cutaneous wound healing and scarring. *BioDrugs*. 2005;19:363-381.
- Levenson SM, Geever EF, Crowley LV, et al. The healing of rat skin wounds. *Ann Surg*. 1965;161:293-308.
- Lee JY, Yang CC, Chao SC, et al. Histopathological differential diagnosis of keloid and hypertrophic scar. *Am J Dermatopathol*. 2004;26:379-384.
- Ehrlich HP, Desmoulière A, Diegelmann RF, et al. Morphological and immunochemical differences between keloid and hypertrophic scar. *Am J Pathol*. 1994;145:105-113.
- Rossiello L, D'Andrea F, Grella R, et al. Differential expression of cyclooxygenases in hypertrophic scar and keloid tissues. *Wound Repair Regen*. 2009;17:750-757.
- Niessen FB, Schalkwijk J, Vos H, et al. Hypertrophic scar formation is associated with an increased number of epidermal Langerhans cells. *J Pathol*. 2004;202:121-129.
- Niessen FB, Andriessen MP, Schalkwijk J, et al. Keratinocyte-derived growth factors play a role in the formation of hypertrophic scars. *J Pathol*. 2001;194:207-216.
- Bagabir R, Byers RJ, Chaudhry IH, et al. Site-specific immunophenotyping of keloid disease demonstrates immune upregulation and the presence of lymphoid aggregates. *Br J Dermatol*. 2012;167:1053-1066.
- Khoo YT, Ong CT, Mukhopadhyay A, et al. Upregulation of secretory connective tissue growth factor (CTGF) in keratinocyte-fibroblast coculture contributes to keloid pathogenesis. *J Cell Physiol*. 2006;208:336-343.
- Garner WL. Epidermal regulation of dermal fibroblast activity. *Plast Reconstr Surg*. 1998;102:135-139.
- Machesney M, Tidman N, Waseem A, et al. Activated keratinocytes in the epidermis of hypertrophic scars. *Am J Pathol*. 1998;152:1133-1141.
- Rockwell WB, Cohen IK, Ehrlich HP. Keloids and hypertrophic scars: a comprehensive review. *Plast Reconstr Surg*. 1989;84:827-837.
- Verhaegen PD, van Zuijlen PP, Pennings NM, et al. Differences in collagen architecture between keloid, hypertrophic scar, normotrophic scar, and normal skin: an objective histopathological analysis. *Wound Repair Regen*. 2009;17:649-656.
- Louw L. The keloid phenomenon: progress toward a solution. *Clin Anat*. 2007;20:3-14.
- Uitto J, Perejda AJ, Abergel RP, et al. Altered steady-state ratio of type I/III procollagen mRNAs correlates with selectively increased type I procollagen biosynthesis in cultured keloid fibroblasts. *Proc Natl Acad Sci U S A*. 1985;82:5935-5939.
- Friedman DW, Boyd CD, Mackenzie JW, et al. Regulation of collagen gene expression in keloids and hypertrophic scars. *J Surg Res*. 1993;55:214-222.
- Abergel RP, Pizzurro D, Meeker CA, et al. Biochemical composition of the connective tissue in keloids and analysis of collagen metabolism in keloid fibroblast cultures. *J Invest Dermatol*. 1985;84:384-390.
- Ghahary A, Shen YJ, Nedelec B, et al. Collagenase production is lower in post-burn hypertrophic scar fibroblasts than in normal fibroblasts and is reduced by insulin-like growth factor-1. *J Invest Dermatol*. 1996;106:476-481.
- Clark JA, Turner ML, Howard L, et al. Description of familial keloids in five pedigrees: evidence for autosomal

- dominant inheritance and phenotypic heterogeneity. *BMC Dermatol.* 2009;9:8.
25. Bertheim U, Hellström S. The distribution of hyaluronan in human skin and mature, hypertrophic and keloid scars. *Br J Plast Surg.* 1994;47:483–489.
  26. Nagata H, Ueki H, Moriguchi T. Fibronectin. Localization in normal human skin, granulation tissue, hypertrophic scar, mature scar, progressive systemic sclerotic skin, and other fibrosing dermatoses. *Arch Dermatol.* 1985;121:995–999.
  27. Kischer CW, Hendrix MJ. Fibronectin (FN) in hypertrophic scars and keloids. *Cell Tissue Res.* 1983;231:29–37.
  28. Nakaoka H, Miyauchi S, Miki Y. Proliferating activity of dermal fibroblasts in keloids and hypertrophic scars. *Acta Derm Venereol.* 1995;75:102–104.
  29. Lu F, Gao J, Ogawa R, et al. Fas-mediated apoptotic signal transduction in keloid and hypertrophic scar. *Plast Reconstr Surg.* 2007;119:1714–1721.
  30. Aarabi S, Bhatt KA, Shi Y, et al. Mechanical load initiates hypertrophic scar formation through decreased cellular apoptosis. *FASEB J.* 2007;21:3250–3261.
  31. Ong CT, Khoo YT, Mukhopadhyay A, et al. Comparative proteomic analysis between normal skin and keloid scar. *Br J Dermatol.* 2010;162:1302–1315.
  32. Cohen IK, Beaven MA, Horáková Z, et al. Histamine and collagen synthesis in keloid and hypertrophic scar. *Surg Forum.* 1972;23:509–510.
  33. Smith CJ, Smith JC, Finn MC. The possible role of mast cells (allergy) in the production of keloid and hypertrophic scarring. *J Burn Care Rehabil.* 1987;8:126–131.
  34. Gruber BL, Kew RR, Jelaska A, et al. Human mast cells activate fibroblasts: tryptase is a fibrogenic factor stimulating collagen messenger ribonucleic acid synthesis and fibroblast chemotaxis. *J Immunol.* 1997;158:2310–2317.
  35. Kofford MW, Schwartz LB, Schechter NM, et al. Cleavage of type I procollagen by human mast cell chymase initiates collagen fibril formation and generates a unique carboxyl-terminal propeptide. *J Biol Chem.* 1997;272:7127–7131.
  36. Yamamoto T, Hartmann K, Eckes B, et al. Role of stem cell factor and monocyte chemoattractant protein-1 in the interaction between fibroblasts and mast cells in fibrosis. *J Dermatol Sci.* 2001;26:106–111.
  37. Moyer KE, Sagers GC, Ehrlich HP. Mast cells promote fibroblast populated collagen lattice contraction through gap junction intercellular communication. *Wound Repair Regen.* 2004;12:269–275.
  38. Pistorio AL, Ehrlich HP. Modulatory effects of connexin-43 expression on gap junction intercellular communications with mast cells and fibroblasts. *J Cell Biochem.* 2011;112:1441–1449.
  39. Gallant-Behm CL, Hildebrand KA, Hart DA. The mast cell stabilizer ketotifen prevents development of excessive skin wound contraction and fibrosis in red Duroc pigs. *Wound Repair Regen.* 2008;16:226–233.
  40. Marneros AG, Norris JE, Watanabe S, et al. Genome scans provide evidence for keloid susceptibility loci on chromosomes 2q23 and 7p11. *J Invest Dermatol.* 2004;122:1126–1132.
  41. Chen Y, Gao JH, Yan X, et al. [Location of predisposing gene for one Han Chinese keloid pedigree]. *Zhonghua Zheng Xing Wai Ke Za Zhi.* 2007;23:137–140.
  42. Nakashima M, Chung S, Takahashi A, et al. A genome-wide association study identifies four susceptibility loci for keloid in the Japanese population. *Nat Genet.* 2010;42:768–771.
  43. Ogawa R, Okai K, Tokumura F, et al. The relationship between skin stretching/contraction and pathologic scarring: the important role of mechanical forces in keloid generation. *Wound Repair Regen.* 2012;20:149–157.
  44. Ogawa R. Keloid and hypertrophic scarring may result from a mechanoreceptor or mechanosensitive nociceptor disorder. *Med Hypotheses* 2008;71:493–500.
  45. Louw L. Keloids in rural black South Africans. Part 1: general overview and essential fatty acid hypotheses for keloid formation and prevention. *Prostaglandins Leukot Essent Fatty Acids* 2000;63:237–245.
  46. Akaishi S, Akimoto M, Ogawa R, et al. The relationship between keloid growth pattern and stretching tension: visual analysis using the finite element method. *Ann Plast Surg.* 2008;60:445–451.
  47. Huang C, Akaishi S, Ogawa R. Mechanosignaling pathways in cutaneous scarring. *Arch Dermatol Res.* 2012;304:589–597.
  48. Fong EP, Bay BH. Keloids—the sebum hypothesis revisited. *Med Hypotheses* 2002;58:264–269.
  49. Ueda K, Furuya E, Yasuda Y, et al. Keloids have continuous high metabolic activity. *Plast Reconstr Surg.* 1999;104:694–698.
  50. Ichioka S, Ando T, Shibata M, et al. Oxygen consumption of keloids and hypertrophic scars. *Ann Plast Surg.* 2008;60:194–197.
  51. Arima J, Ogawa R, Iimura T, et al. Relationship between keloid and hypertension. *J Nippon Med Sch.* 2012;79:494–495.
  52. Ogawa R, Arima J, Ono S, et al. Total management of a severe case of systemic keloids associated with high blood pressure (hypertension)—clinical symptoms of keloids may be aggravated by hypertension. *ePlasty* 2013;13:e25.
  53. Janssen de Limpens AM, Cormane RH. Studies on the immunologic aspects of keloids and hypertrophic scars. *Arch Dermatol Res.* 1982;274:259–266.
  54. Aggarwal H, Saxena A, Lubana PS, et al. Treatment of keloids and hypertrophic scars using bleom. *J Cosmet Dermatol.* 2008;7:43–49.
  55. Sadeghinia A, Sadeghinia S. Comparison of the efficacy of intralesional triamcinolone acetonide and 5-fluorouracil tattooing for the treatment of keloids. *Dermatol Surg.* 2012;38:104–109.
  56. Huang C, Ono S, Hyakusoku H, et al. Small-wave incision method for linear hypertrophic scar reconstruction: a parallel-group randomized controlled study. *Aesthetic Plast Surg.* 2012;36:387–395.
  57. Ogawa R, Akaishi S, Huang C, et al. Clinical applications of basic research that shows reducing skin tension could prevent and treat abnormal scarring: the importance of fascial/subcutaneous tensile reduction sutures and flap surgery for keloid and hypertrophic scar reconstruction. *J Nippon Med Sch.* 2011;78:68–76.
  58. Akaishi S, Akimoto M, Hyakusoku H, et al. The tensile reduction effects of silicone gel sheeting. *Plast Reconstr Surg.* 2010;126:109e–111e.
  59. Louw L. Keloids in rural black South Africans. Part 3: a lipid model for the prevention and treatment of keloid formations. *Prostaglandins Leukot Essent Fatty Acids* 2000;63:255–262.
  60. Martín-García RF, Busquets AC. Postsurgical use of imiquimod 5% cream in the prevention of earlobe keloid recurrences: results of an open-label, pilot study. *Dermatol Surg.* 2005;31(11, Part 1):1394–1398.
  61. Moon JH, Kwak SS, Park G, et al. Isolation and characterization of multipotent human keloid-derived mesenchymal-like stem cells. *Stem Cells Dev.* 2008;17:713–724.
  62. Akino K, Akita S, Yakabe A, et al. Human mesenchymal stem cells may be involved in keloid pathogenesis. *Int J Dermatol.* 2008;47:1112–1117.