



Published in final edited form as:

*J Clin Transl Pathol.* 2021 December ; 1(1): 16–20.

## Expression of NKX3.1, Prostatic Specific Antigen and Prostatic Specific Alkaline Phosphatase in Cytology Specimens of Metastatic Prostatic Carcinoma

Minhua Wang<sup>1,\*</sup>, Rita Abi-Raad<sup>1</sup>, Adebowale J. Adeniran<sup>1</sup>, Guoping Cai<sup>1,2</sup>

<sup>1</sup>Department of Pathology, Yale School of Medicine, New Haven, CT, USA

<sup>2</sup>Yale Cancer Center, Yale School of Medicine, New Haven, CT, USA

### Abstract

**Background and objectives:** NKX3.1 is an emerging marker for tumors of prostatic origin; however, the utility and diagnostic values of NKX3.1 have not been broadly studied in cytology specimens. The purpose of this study is to determine the performance of NKX3.1, compared to prostatic specific antigen (PSA) and prostatic specific alkaline phosphatase (PSAP), as an organ-specific marker of metastatic prostatic adenocarcinoma (MPAC) in cytology specimens.

**Methods:** The cytology specimens, which had been evaluated to include or exclude MPAC, were collected from our pathology database. Immunostains for PSA, PSAP, and NKX3.1 were performed on cell block sections.

**Results:** A total of 118 cases were collected. In 37 MPACs, NKX3.1 was diffusely positive in 34 cases (92%) and focally positive in 3 cases (8%). PSA indicated diffuse positivity in 16 cases (43%), focal positivity in 13 (35%) cases, and was negative in 8 (22%) cases. PSAP immunostain was performed in only 12 MPACs, showing diffuse positivity in 5 (42%), focal positivity in 3 (25%), and negativity in 4 (33%) cases. Among the 81 non-metastatic prostatic adenocarcinoma cases, NKX3.1 was negative in 80 (99%) cases and focally positive in only 1 (1%) case; all cases with available PSA and PSAP staining were negative. The calculated sensitivities for NKX3.1, PSA, and PSAP were 100%, 78%, and 67%, respectively, while the specificities were 99%, 100%, and 100%, respectively.

---

This article has been published under the terms of [Creative Commons Attribution-Noncommercial 4.0 International License \(CC BY-NC 4.0\)](https://creativecommons.org/licenses/by-nc/4.0/), which permits noncommercial unrestricted use, distribution, and reproduction in any medium, provided that the following statement is provided.

\***Correspondence to:** Minhua Wang, Department of Pathology, Yale School of Medicine, 20 York Street, CB506, New Haven, CT 06510, USA. Tel: +1 (203) 737-5445, Fax: +1 (203) 785-3255, minhua.wang@yale.edu.

Author contributions

Study concept and design (GC), acquisition of data (MW, RA, AA, GC), analysis and interpretation of data (MW, RA, AA, GC), drafting of the manuscript (MW), critical revision of the manuscript for important intellectual content (MW, GC). All authors have made a significant contribution to this study and have approved the final manuscript.

Data sharing statement

No additional data are available.

Conflict of interest

Dr. Adeniran has been an editorial board member (since May 2021) and Dr. Cai has been an editor-in-chief (since March 2021) of *Journal of Clinical and Translational Pathology*. The authors have no conflict of interest related to this publication.

**Conclusions:** Compared to PSA and PSAP, NKX3.1 is more reliable as an individual marker for MPAC in cytology specimens. Combining NKX3.1 and PSA can be useful in some cases to enhance diagnostic utility.

### Keywords

NKX3.1; PSA; PSAP; Prostatic adenocarcinoma; Metastatic

---

### Introduction

Immunohistochemical studies using organ-specific markers have been widely used for identifying tumor origin in the workup for metastatic carcinomas. Prostatic specific antigen (PSA) and prostatic specific alkaline phosphatase (PSAP) are often considered as prostatic markers; however, their sensitivities and/or specificities are less than optimal in cytology specimens.<sup>1-5</sup>

NKX3.1, a recently emerged prostatic-specific, androgen-regulated homeobox gene product, has been shown in surgical specimens to have high sensitivity and/or specificity as a prostatic marker even in poorly differentiated metastatic prostatic carcinomas or in the setting of neoadjuvant therapy.<sup>1,2,6</sup> Therefore, NKX3.1 is considered as a promising marker in the cytological workup for metastases. However, to date, the performance of NKX3.1 as a marker of prostatic origin in comparison to PSA and PSAP in cytology specimens has not been sufficiently evaluated due to the paucity of studies in this setting. In the current study, we aimed to assess the diagnostic values of NKX3.1, PSA, and PSAP in cytological specimens submitted for metastatic workup to rule in or out metastatic prostatic carcinoma.

### Materials and methods

The current study was conducted after approval by the institutional review board of Yale University. We searched our pathology electronic database for cytology cases that had been evaluated to include or exclude metastatic prostatic adenocarcinoma (PAC) from 2013 to 2020. Data were collected regarding patient demographics, clinical presentation, cytology diagnosis, surgical diagnosis, and immunohistochemical results. All the cases were obtained through fine needle aspiration (FNA) procedures or exfoliative fluid/effusion sampling. For FNA cases, the needles were rinsed in CytoRich Red fixative (Thermo Fischer) following direct smear preparation. For effusion specimens, a ThinPrep liquid-based cytology slide was prepared (Hologic). The FNA rinse material or remaining effusion specimen was centrifuged and a cell block was prepared from the pellet in all cases using a HistoGel-based technique. All the cell blocks contained sufficient cellularity. Cell blocks sections were used for H&E stains and immunohistochemistry (Ventana). The validation studies have been done to validate all immunohistochemical markers on cell block sections of cytology specimens in our institution. The immunohistochemical workup was performed either due to patients' known prior history of prostate cancer or presence of cytomorphologic features suggestive of possible prostatic origin. Immunostains for NKX3.1 (1:50, Biocare), PSA (1:1, Dako), and PSAP (1:1, Leica) were performed as a part of metastatic workup for diagnosis or retrospectively.

The results of NKX3.1, PSA, and PSAP immunostains were classified as negative, focally positive (< 20% cells staining), and positive (>20% cells staining). For each marker, the sensitivity, specificity, positive predictive value (PPV), and negative predictive value (NPV) were calculated with Microsoft Excel.

## Results

A total of 118 cases were retrieved from the database, including 37 metastatic PAC cases from the patients with a mean age of 72 years old (ranging from 56–90 years old) and 81 non-metastatic PAC cases (including negative and metastatic carcinomas other than PAC) from the patients with a mean age of 73 years old (ranging from 51–93 years old) (Table 1). Among the 37 metastatic PAC cases, 34 (92%) had a history of PAC. Among the 3 patients without prior PAC history, the diagnosis of metastatic PAC was confirmed by follow-up prostate biopsies in two patients, and the remaining patient had an enlarged prostate in an imaging study with an elevated serum PSA level. In our cohort, the highest Gleason scores of primary PACs in multiple core biopsy or resection cases were obtained from pathology reports, including 3 cases with 5+5, 8 cases with 5+4, 6 cases with 4+5, 3 cases with 4+4, 2 cases with 4+3, 5 cases with 3+4, and 7 cases with unknown scores. The cytology cases with metastatic PAC were obtained from a variety of metastatic sites, including 19 (51%) from lymph node, 9 (24%) from pleural effusion, 4 (11%) from lung, 4 (11%) from bone, and 1 (3%) from ascites (Table 1).

Out of the 81 non-metastatic PAC cases, 12 were diagnosed as negative and 69 as metastatic carcinomas with the primary sites being lung (44, 54%), bladder (6, 7%), gastrointestinal tract (5, 6%), pancreas (4, 5%), kidney (4, 5%), soft tissue sarcoma (2, 2%), breast (1, 1%), liver (1, 1%), skin (1, 1%), salivary gland (1, 1%) (Table 1). Of note, among these nonmetastatic PAC cases, 39 (48%) had a history of PAC. This sample group was also obtained from a variety of metastatic sites, including lymph node (27, 33%), pleural effusion (28, 35%), lung (7, 9%), bone (1, 1%), ascites (4, 5%), pericardial effusion (5, 6%), pancreas (4, 5%), soft tissue (2, 2%), neck (1, 1%), duodenum (1, 1%), and pelvis (1, 1%).

As shown in Table 2, of the 37 metastatic PACs, NKX3.1 was diffusely positive in 34 cases (92%) and focally positive in 3 cases (8%). PSA showed diffuse positivity in 16 cases (43%), focal positivity in 13 (35%) cases, and negativity in 8 (22%) cases. PSAP immunostain was performed in only 12 out of the 37 metastatic PACs, showing diffuse positivity in 5 (42%), focal positivity in 3 (25%), and negativity in 4 (33%) cases. In summary, 29 metastatic PACs were positive for both NKX3.1 and PSA (Fig. 1a–c), while 8 cases were positive for NKX3.1 but negative for PSA (Fig. 1d–f). Among the 81 non-metastatic PAC cases, NKX3.1 was negative in 80 (99%) cases and focally positive in only 1 (1%) case which was poorly differentiated lung carcinoma (Fig. 1g–i). Among the non-PAC group, PSA immunostain was performed on 20 cases and PSAP immunostain on 5 cases. All of them showed negative PSA/PSAP expression.

The calculated sensitivities for NKX3.1, PSA, and PSAP were 100%, 78%, and 67%, respectively, while the calculated specificities were 99%, 100%, and 100%, respectively. The

PPVs were 97%, 100%, and 100%, and the NPVs were 100%, 71%, and 56%, respectively for NKX3.1, PSA and PSAP (Table 3).

## Discussion

Accurately identifying the origin of metastatic carcinoma is important for appropriate patient management. Cytology specimens, including FNA and effusion fluid, may be the only samples available for metastatic workup. This can be challenging due to the absence of architecture in cytology specimens and overlapping cytomorphologic features among the entities that fall within the differential diagnosis. Almost certainly, organ-specific immunomarkers are required for determining the origin of the tumor.

PAC is the most common carcinoma in male patients. PSA and PSAP have widely been used to establish a tumor's prostatic origin. It has been reported that PSA and PSAP have high sensitivity in benign prostate tissue and low-grade prostatic cancer but they lose significant expression and show focal positivity even negativity in high-grade tumors.<sup>1,7,8</sup> The reported sensitivities of PSA and PSAP in detecting metastatic prostatic carcinoma range from 81% to 94% for PSA and from 66% to 99% for PSAP depending on how positivity is defined.<sup>1-3</sup> NKX3.1 has been reported to have a high sensitivity ranging from 92% to 100% in primary and 99% to 100% in metastatic prostatic carcinoma.<sup>2,9</sup> In histology tissue, these 3 markers are comparable in terms of their effectiveness in determining the tumor's prostatic origin.

However, limited data on cytology specimens suggest that NKX3.1 shows a better performance than PSA and PSAP because the sensitivity of the latter two markers could be significantly reduced in the cytological setting. In one study, when immunohistochemistry was performed on cytology cell block sections, NKX3.1 was reported to be expressed in only 68% of metastatic PAC, compared with 41% for PSA and 41% for PSAP.<sup>5</sup> In another study, NKX3.1 showed a 100% detection rate on smear specimens, which is much better than PSA (26%) and PSAP (0%).<sup>4</sup> In our study, the sensitivity of detecting metastatic PAC for NKX3.1 was 100%, superior to that of PSA (78%) and PSAP (67%). The low sensitivities of PSA and PSAP are probably due to the limited cytology sampling, as well as the two markers' cytoplasmic staining pattern and focal positivity. In the current study, NKX3.1 showed diffuse positivity in 34 out of 37 (92%) cases and focal positivity in 3 (8%) cases. By comparison, PSA showed diffuse positivity in 16 out of 37 (43%) cases and focal positivity in 13 (35%) cases; PSAP was diffusely positive in 5 out of 12 (42%) cases and focally positive in 3 (25%) cases. A likely explanation is that given limited amount of cytology tissue, metastatic PAC may be interpreted as negative for PSA or PSAP owing to their focal positive staining pattern. The decreased sensitivity suggests that PSA and PSAP are suboptimal for cytology specimens and may necessitate the application of additional antibodies. NKX3.1 showed nuclear and diffuse staining patterns in the most specimens, which is advantageous for interpreting cytology specimens and may contribute to their high sensitivity.

PSA and PSAP are specific markers of prostatic origin. In our study, PSA and PSAP were negative in all available non-metastatic PAC cases, which is consistent with previous reports. However, it is well known that both PSA and PSAP can be rarely expressed in a small subset

of non-prostatic tumors, including breast carcinoma, salivary gland neoplasms, urinary bladder adenocarcinoma, colon adenocarcinoma, melanoma, and acinar cell carcinoma.<sup>1</sup> As for NKX3.1, it has been shown to be generally highly specific for prostatic origin. In our study, only one non-prostatic tumor showed focal NKX3.1 positivity, which was eventually diagnosed as poorly differentiated lung cancer after extensive workup (Fig. 1g–i). The high specificity showed in our study is consistent with those reported in the literature. In one previous study, NKX3.1 had a specificity of 99%, with only one invasive lobular carcinoma (1/349) showing false positivity.<sup>9</sup> Another study demonstrated that NKX3.1 was positive in 2% of invasive ductal carcinomas and 27% of invasive lobular carcinomas, all of which showed weak staining intensity.<sup>10</sup> As breast carcinoma is rare in male patients, and lobular carcinoma is extremely rare, breast ductal and lobular carcinomas are usually not in the closer differential diagnosis when dealing with metastatic PAC in clinical practice.<sup>2</sup> As for our false positive case, although NKX3.1 showed focal positivity, the addition of PSA helped reduce the possibility of a prostatic origin. Therefore, a combination of NKX3.1 and PSA can be useful in some uncertain cases to help reduce false positivity.

Our study is limited by the absence of prostatic small cell carcinoma (SmCC). It is well known that prostatic SmCC morphologically resembles SmCC from other sites. PSA and NKX3.1 have been reported to be positive in about only 20% of prostatic SmCC.<sup>11–13</sup> In the only cytology study to date, Gan *et al* found that NKX3.1, PSA, and PSAP were all negative in 19 metastatic prostatic SmCC cases when immunostains were performed on direct smears, lending evidence to limited diagnostic utility of these markers in confirming prostatic origin for a metastatic SmCC.

## Conclusions

Our study demonstrates that NKX3.1 maintained high sensitivity and specificity in detecting metastatic PAC in cytology specimens, while PSA and PSAP had 100% specificity but reduced sensitivity. Compared to PSA and PSAP, NKX3.1 is a more reliable marker when applied individually. NKX3.1 is also preferable in cytology specimens due to the easy interpretability of its nuclear and diffuse staining patterns. PSA and PSAP remain optional markers when additional prostatic markers are needed. Combining NKX3.1 and PSA can be useful in some uncertain cases to help reduce false positivity.

## Acknowledgments

### Funding

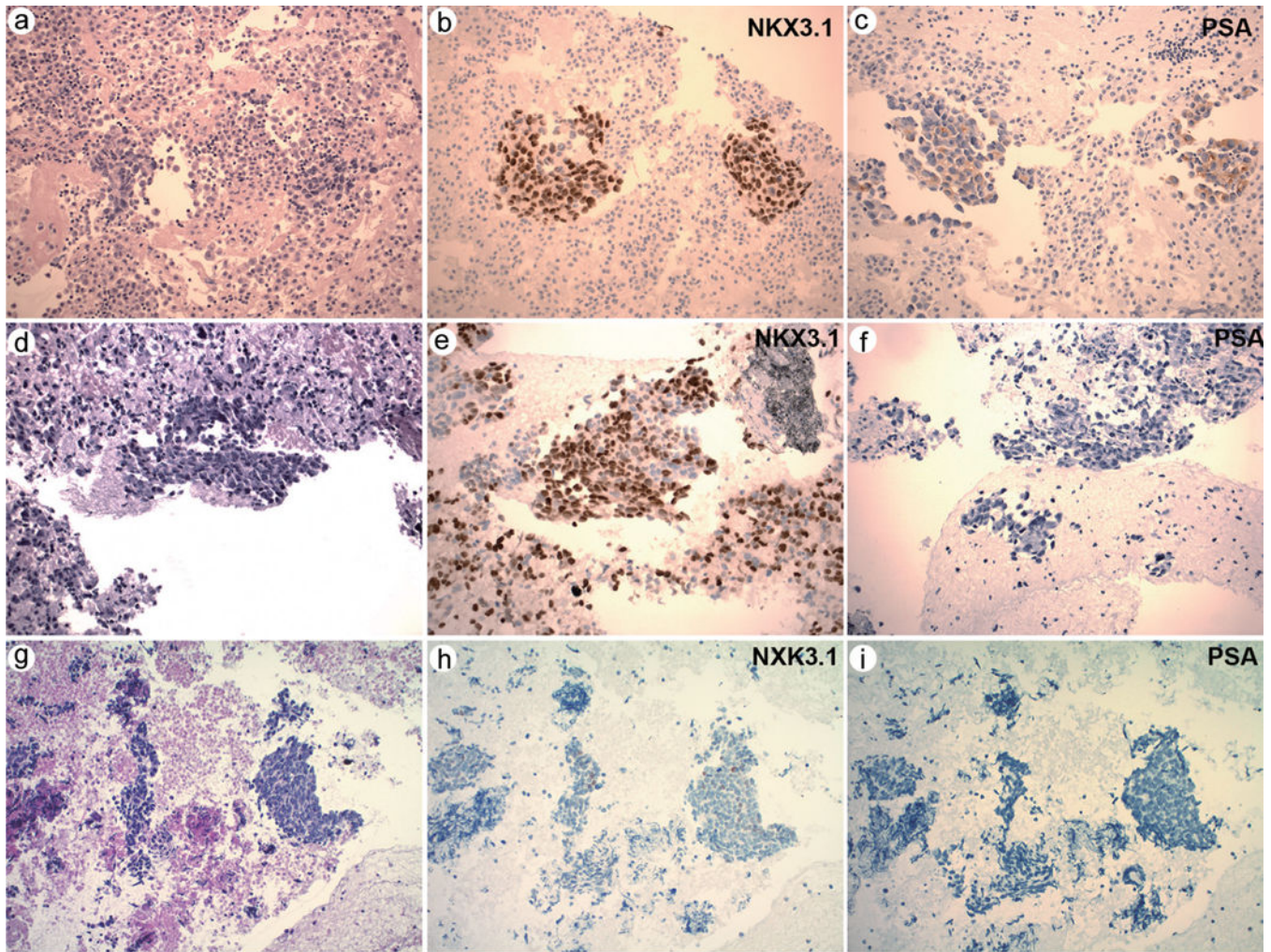
The work was supported in part by a NIH research grant from the National Institutes of Health (P30CA016359).

## Abbreviations:

|             |   |
|-------------|---|
| <b>PSA</b>  | prostatic specific antigen              |
| <b>PSAP</b> | prostatic specific alkaline phosphatase |
| <b>PAC</b>  | prostatic adenocarcinoma                |
| <b>MPAC</b> | metastatic prostatic adenocarcinoma     |

## References

- [1]. Varma M, Jasani B. Diagnostic utility of immunohistochemistry in morphologically difficult prostate cancer: review of current literature. *Histopathology* 2005;47(1):1–16. doi:10.1111/j.1365-2559.2005.02188.x, PMID:15982318. [PubMed: 15982318]
- [2]. Kristiansen I, Stephan C, Jung K, Dietel M, Rieger A, Tolkach Y, et al. Sensitivity of HOXB13 as a Diagnostic Immunohistochemical Marker of Prostatic Origin in Prostate Cancer Metastases: Comparison to PSA, Prostein, Androgen Receptor, ERG, NKX3.1, PSAP, and PSMA. *Int J Mol Sci* 2017;18(6):1151. doi:10.3390/ijms18061151, PMID:28555048.
- [3]. Aihara M, Lebovitz RM, Wheeler TM, Kinner BM, Otori M, Scardino PT. Prostate specific antigen and gleason grade: an immunohistochemical study of prostate cancer. *J Urol* 1994;151(6):1558–1564. doi:10.1016/s0022-5347(17)35302-8, PMID:7514688. [PubMed: 7514688]
- [4]. Gan Q, Joseph CT, Guo M, Zhang M, Sun X, Gong Y. Utility of NKX3.1 Immunostaining in the Detection of Metastatic Prostatic Carcinoma on Fine-Needle Aspiration Smears. *Am J Clin Pathol* 2019;152(4):495–501. doi:10.1093/ajcp/aqz063, PMID:31175351. [PubMed: 31175351]
- [5]. Jia L, Jiang Y, Michael CW. Performance of different prostate specific antibodies in the cytological diagnosis of metastatic prostate adenocarcinoma. *Diagn Cytopathol* 2017;45(11):998–1004. doi:10.1002/dc.23809, PMID:28888085. [PubMed: 28888085]
- [6]. Kehr E, Masry P, Lis R, Loda M, Taplin ME, Hirsch MS. Detecting metastatic prostate carcinoma in pelvic lymph nodes following neoadjuvant hormone therapy: the eyes have it!. *Histopathology* 2016;68(2):303–307. doi:10.1111/his.12739, PMID:26018610. [PubMed: 26018610]
- [7]. Chuang AY, DeMarzo AM, Veltri RW, Sharma RB, Bieberich CJ, Epstein JI. Immunohistochemical differentiation of high-grade prostate carcinoma from urothelial carcinoma. *Am J Surg Pathol* 2007;31(8):1246–1255. doi: 10.1097/PAS.0b013e31802f5d33, PMID:17667550. [PubMed: 17667550]
- [8]. Goldstein NS. Immunophenotypic characterization of 225 prostate adenocarcinomas with intermediate or high Gleason scores. *Am J Clin Pathol* 2002;117(3):471–477. doi:10.1309/g6pr-y774-x738-fg2k, PMID:11888088. [PubMed: 11888088]
- [9]. Gurel B, Ali TZ, Montgomery EA, Begum S, Hicks J, Goggins M, et al. NKX3.1 as a marker of prostatic origin in metastatic tumors. *Am J Surg Pathol* 2010;34(8):1097–1105. doi:10.1097/PAS.0b013e3181e6cbf3, PMID:20588175. [PubMed: 20588175]
- [10]. Asch-Kendrick RJ, Samols MA, Lilo MT, Subhawong AP, Sharma R, Illei PB, et al. NKX3.1 is expressed in ER-positive and AR-positive primary breast carcinomas. *J Clin Pathol* 2014;67(9):768–771. doi:10.1136/jclin-path-2014-202272, PMID:24996432. [PubMed: 24996432]
- [11]. Lotan TL, Gupta NS, Wang W, Toubaji A, Haffner MC, Chaux A, et al. ERG gene rearrangements are common in prostatic small cell carcinomas. *Mod Pathol* 2011;24(6):820–828. doi:10.1038/modpathol.2011.7, PMID: 21336263. [PubMed: 21336263]
- [12]. Wang W, Epstein JI. Small cell carcinoma of the prostate. A morphologic and immunohistochemical study of 95 cases. *Am J Surg Pathol* 2008;32(1):65–71. doi:10.1097/PAS.0b013e318058a96b, PMID:18162772. [PubMed: 18162772]
- [13]. Yao JL, Madeb R, Bourne P, Lei J, Yang X, Tickoo S, et al. Small cell carcinoma of the prostate: an immunohistochemical study. *Am J Surg Pathol* 2006;30(6):705–712. doi:10.1097/0000478-200606000-00005, PMID: 16723847. [PubMed: 16723847]



**Fig. 1. a–c:** A representative case of metastatic prostatic adenocarcinoma (a) with positive NKX3.1 (b) and positive PSA (c). d–f: A representative case of metastatic prostatic adenocarcinoma (d) with positive NKX3.1 (e) but negative PSA (f). g–i: The only non-metastatic prostatic carcinoma with focal weak NKX3.1 positivity but negative PSA. a–i: 200 $\times$ .

Clinicopathologic features of metastatic prostatic adenocarcinoma and non-metastatic prostatic adenocarcinoma

Table 1.

|                                      | Metastatic Prostatic Adenocarcinoma (n=37) | Non-metastatic Prostatic Adenocarcinoma (n=81) |
|--------------------------------------|--|--|
| Age (years)                          |  |  |
| Mean                                 | 72   | 73   |
| Range                                | 56–90                                      | 51–93  |
| History of Prostatic Cancer (n, %)   |  |  |
| Yes                                  | 34 (92%)                                   | 39 (48%)                                       |
| No                                   | 3 (8%)*                                    | 42 (52%)                                       |
| Specimen Source (n, %)               |  |  |
| Lymph node                           | 19 (51%)                                   | 27 (33%)                                       |
| Pleural effusion                     | 9 (24%)                                    | 28 (35%)                                       |
| Lung                                 | 4 (11%)                                    | 7 (9%)   |
| Bone                                 | 4 (11%)                                    | 1 (1%)   |
| Ascites                              | 1 (3%)                                     | 4 (5%)   |
| Pericardial effusion                 | 0  | 5 (6%)   |
| Pancreas                             | 0  | 4 (5%)   |
| Soft tissue                          | 0  | 2 (2%)   |
| Neck                                 | 0  | 1 (1%)   |
| Duodenum                             | 0  | 1 (1%)   |
| Pelvis                               | 0  | 1 (1%)   |
| Diagnosis of metastatic tumor (n, %) |  |  |
| Prostate                             | 37 (100%)                                  | –  |
| Lung                                 | –  | 44 (54%)                                       |
| Bladder                              | –  | 6 (7%)   |
| Gastrointestinal tract               | –  | 5 (6%)   |
| Pancreas                             | –  | 4 (5%)   |
| Kidney                               | –  | 4 (5%)   |
| Soft tissue sarcoma                  | –  | 2 (2%)   |
| Breast                               | –  | 1 (1%)   |
| Liver                                | –  | 1 (1%)   |



Author Manuscript

Author Manuscript

Author Manuscript

Author Manuscript

|                         | Metastatic Prostatic Adenocarcinoma (n=37) | Non-metastatic Prostatic Adenocarcinoma (n=81) |
|-------------------------|--|--|
| Skin                    | -  | 1 (1%)   |
| Salivary gland          | -  | 1 (1%)   |
| Negative for malignancy | -  | 12 (15%)                                       |

\* Two patients had prostate cancer confirmed on the follow-up prostate biopsy. One patient had enlarged prostate on imaging study.

Expression of NKX3.1, PSA, PSAP and AR in metastatic prostatic adenocarcinoma and non-metastatic prostatic adenocarcinoma

**Table 2.**

|                        | Metastatic Prostatic Adenocarcinoma | Non-metastatic prostatic adenocarcinoma |
|------------------------|-------------------------------------|---|
| NKX3.1 expression      |                                     |   |
| Total                  | 37                                  | 81                                      |
| Positive               | 34 (92%)                            | 0                                       |
| Focally positive       | 3 (8%)                              | 1 (1%)                                  |
| Negative               | 0                                   | 80 (99%)                                |
| PSA expression         |                                     |   |
| Total                  | 37                                  | 20                                      |
| Positive               | 16 (43%)                            | 0                                       |
| Focally positive       | 13 (35%)                            | 0                                       |
| Negative               | 8 (22%)                             | 20 (100%)                               |
| PSAP expression (n, %) |                                     |   |
| Total                  | 12                                  | 5                                       |
| Positive               | 5 (42%)                             | 0                                       |
| Focally positive       | 3 (25%)                             | 0                                       |
| Negative               | 4 (33%)                             | 5 (100%)                                |

Sensitivity, specificity, positive predictive value and negative predictive value of NKX3.1, PSA and PSAP for diagnosis of metastatic prostatic adenocarcinoma

Table 3.

|                                    | NKX3.1           | PSA                 | PSAP                |
|------------------------------------|------------------|---------------------|---------------------|
| Sensitivity (95% CI)               | 1 (0.88 to 1)    | 0.78 (0.61 to 0.90) | 0.67 (0.35 to 0.89) |
| Specificity (95% CI)               | 0.99 (0.92 to 1) | 1 (0.80 to 1)       | 1 (0.46 to 1)       |
| Positive Predictive Value (95% CI) | 0.97 (0.85 to 1) | 1 (0.85 to 1)       | 1 (0.60 to 1)       |
| Negative Predictive Value (95% CI) | 1 (0.94 to 1)    | 0.71 (0.51 to 0.86) | 0.56 (0.23 to 0.85) |