


# Unstable Bony Chance Fracture Successfully Treated With Teriparatide in Patient With Ankylosed Spine: A Case Report and Review of the Literature

Geriatric Orthopaedic Surgery  
& Rehabilitation  
Volume 12: 1–6  
© The Author(s) 2021  
Article reuse guidelines:  
[sagepub.com/journals-permissions](https://sagepub.com/journals-permissions)  
DOI: 10.1177/21514593211039024  
[journals.sagepub.com/home/gos](https://journals.sagepub.com/home/gos)  


Hyung-Youl Park, MD<sup>1</sup> , Kee-Yong Ha, MD, PhD<sup>2</sup>, Ki-Won Kim, MD, PhD<sup>3</sup>, Kee-Won Rhyu, MD, PhD<sup>4</sup>, Young-Hoon Kim, MD, PhD<sup>5</sup>, Jun-Seok Lee, MD, PhD<sup>1</sup> , Sang-Il Kim, MD, PhD<sup>5</sup>, and Soo-Bin Park, MD<sup>1</sup>

## Abstract

**Background:** Ankylosed spines with ankylosing spondylitis or diffuse idiopathic skeletal hyperostosis (DISH) are prone to fractures due to osteoporosis and fracture instability from long lever arm. In such cases, surgical management is the main treatment option. **Case presentation:** We report a first case of successful treatment of unstable bony Chance fracture at thoracolumbar junction in DISH patient using teriparatide and review previous literature on ankylosed spine fractures treated with teriparatide. An 82-year-old male patient presented with back pain after falling from a 3 m height 3 months ago. Imaging studies showed L1 unstable flexion-distraction injury (bony Chance fracture) and intravertebral vacuum cleft in ankylosed spine due to DISH. Conservative treatment, teriparatide and orthosis, was determined as the most appropriate approach because the patient declined surgery and presented with tolerable mechanical back pain without any neurologic deficits. Solid bony union was successfully achieved without any complications after 1-year treatment. **Conclusion:** Although surgical management is strongly recommended for unstable fracture in ankylosed spine, non-surgical treatment including teriparatide and orthosis might be safer and effective options in bony Chance fracture without neurologic deficits and intractable mechanical pain.

## Keywords

ankylosing spondylitis, diffuse idiopathic skeletal hyperostosis, spinal fractures, conservative treatment, teriparatide

## Introduction

An ankylosed spine with ankylosing spondylitis (AS) or diffuse idiopathic skeletal hyperostosis (DISH) is prone to fracture because of osteoporosis by disuse atrophy and long lever arms by multi-level vertebral bony fusions.<sup>1,2</sup> Moreover, ankylosed spine fractures are susceptible to low energy trauma and additional complications resulting from delayed presentation.<sup>2,3</sup>

Previous studies have recommended surgical management for ankylosed spine fractures due to their high susceptibility to neurologic deficits and unstable fracture configuration compared to fractures in general population.<sup>3,4</sup>

Although some studies have shown teriparatide to be effective in the management of ankylosed spine fractures,<sup>5-7</sup> we report a first case of successful use of teriparatide in the treatment of unstable flexion-distraction injury (bony Chance fracture) of the thoracolumbar junction in ankylosed spine resulting from DISH.

## Case Presentation

An 82-year-old male patient with underlying hypertension fell from a 3 m height, forward with flexion at the work place 3 months ago. The patient reported mild back pain but was neurologically intact. Plain radiograph and magnetic



Creative Commons Non Commercial CC BY-NC: This article is distributed under the terms of the Creative Commons Attribution-NonCommercial 4.0 License (<https://creativecommons.org/licenses/by-nc/4.0/>) which permits non-commercial use, reproduction and distribution of the work without further permission provided the original work is attributed as specified on the SAGE and Open Access pages (<https://us.sagepub.com/en-us/nam/open-access-at-sage>).

resonance imaging showed a L1 bony Chance fracture without canal encroachment (Figures 1A-1D). However, computed tomography scan was not taken. After 2 weeks of absolute bed rest, he was allowed to ambulate with thoracolumbosacral orthosis (TLSO) and perform minimal physical activities.

Even after the 3 months of conservative treatment, the back pain was persistent and aggravated while standing after sitting or lying. He was transferred to our hospital for further evaluation and treatment. Subsequent imaging studies showed further collapse and intravertebral vacuum cleft (IVC) formation at fracture site (Figures 1E-1H). Bone mineral density showed osteopenia, where total lumbar and femur neck were  $-1.4$  and  $-2.0$  in T-score, respectively. Moreover, he was diagnosed with DISH, where ossification of the anterior longitudinal ligament was present at more than 4 consecutive levels (Figure 2A) with no evidence of sacroiliitis or human leukocyte antigen-B27-related AS (Figure 2).<sup>8</sup>

Non-surgical treatment was carefully determined because he was elderly and presented with tolerable mechanical back pain without any neurologic deficits. A daily subcutaneous injection of 20 mg teriparatide (Forsteo<sup>®</sup>, rhPTH<sub>1-34</sub>, Eli Lilly) was prescribed to enhance fracture healing and reduce progressive collapse with pain relief.<sup>9</sup> TLSO was recommended because of fracture instability and removed when patient did not complain of mechanical back pain. IVC disappeared from 6 months after the initial treatment.

Serial imaging studies showed IVC regression and solid bony union after 12 months of daily teriparatide injection despite thoracolumbar kyphosis (Figure 3). The patient did not complain of any discomforts, and numeric rating scale for back pain was 2 at 1-year follow-up. This study was approved by our Institutional Review Board in

accordance with the Declaration of Helsinki (approval number: PC21ZASI0041).

## Discussion

Fractures in ankylosed spine with AS or DISH are unstable and difficult to be healed due to common 3 column injury and long lever arm formed by multi-level vertebral bony fusions.<sup>1,3</sup> Thus, surgical management is strongly recommended for stability of spinal column and fracture healing.<sup>10-12</sup> However, we report a first case of successful teriparatide treatment of unstable bony Chance fracture at thoracolumbar junction in DISH patient.

Teriparatide is a human recombinant protein composed of the first 34 amino acids of the parathyroid hormone (PTH<sub>1-34</sub>) and has been approved by the United States Food and Drug Administration as the first therapeutic anabolic agent. Bone-forming agent stimulates osteoblast to produce new bone, resulting in increased bone mass and reduced fracture risk in the patients with osteoporosis.<sup>13</sup> In addition, Min et al<sup>9</sup> reported anabolic agent significantly enhanced fracture healing, reduced progressive collapse, and presented good pain relief for acute osteoporotic spinal fractures.

Several studies have so far reported teriparatide as an effective treatment of ankylosed spine fractures (Table 1). Franco et al<sup>5</sup> reported successful treatment of pseudarthrosis after surgery for C7 fracture in a 52-year-old male patient with AS; solid bony fusion at pseudarthrosis and alleviation of pain were achieved after 2 months of teriparatide injection. Biro et al<sup>6</sup> also reported successful treatment of T2 vertebra fracture with teriparatide in a 56-year-old male patient with AS who had earlier declined surgery; after 6 months, the vertebral fracture was completely healed without any complications.

Similar to our case, Matsumoto et al<sup>7</sup> reported effective treatment of delayed union of lumbar vertebral fracture with teriparatide in patient with DISH. They reported hyperplastic bone formation around the fractured L2 vertebral body, pain relief, and functional scores after 6 months of teriparatide injection. However, the patient was bed-ridden and in a complete paraplegia state resulting from previous cord injury, and solid bony union was not observed even in relatively stable L2 vertebrae.

In the present case, a fracture developed at the thoracolumbar junction, which has been considered to be an unstable region because of the transition zone between long and stiff kyphotic thoracic spine and mobile lordotic lumbar spine.<sup>10</sup> Especially, IVC at 3 months after trauma suggested unstable fracture in this patient; this was different from previous reports and presented as collapsed anterior vertebral height in the standing position compared to the supine position (Figure 4).<sup>14</sup> In case of definite fracture instability as present case, conservative treatment including teriparatide could be considered because patient

<sup>1</sup>Department of Orthopedic Surgery, Eunpyeong St. Mary's Hospital, College of Medicine, The Catholic University of Korea, Seoul, Republic of Korea

<sup>2</sup>Department of Orthopedic Surgery, Kyung Hee University Hospital at Gangdong, Seoul, South Korea

<sup>3</sup>Department of Orthopedic Surgery, Yeouido St. Mary's Hospital, College of Medicine, The Catholic University of Korea, Seoul, Republic of Korea

<sup>4</sup>Department of Orthopedic Surgery, St. Vincent Hospital, College of Medicine, The Catholic University of Korea, Suwon, Korea

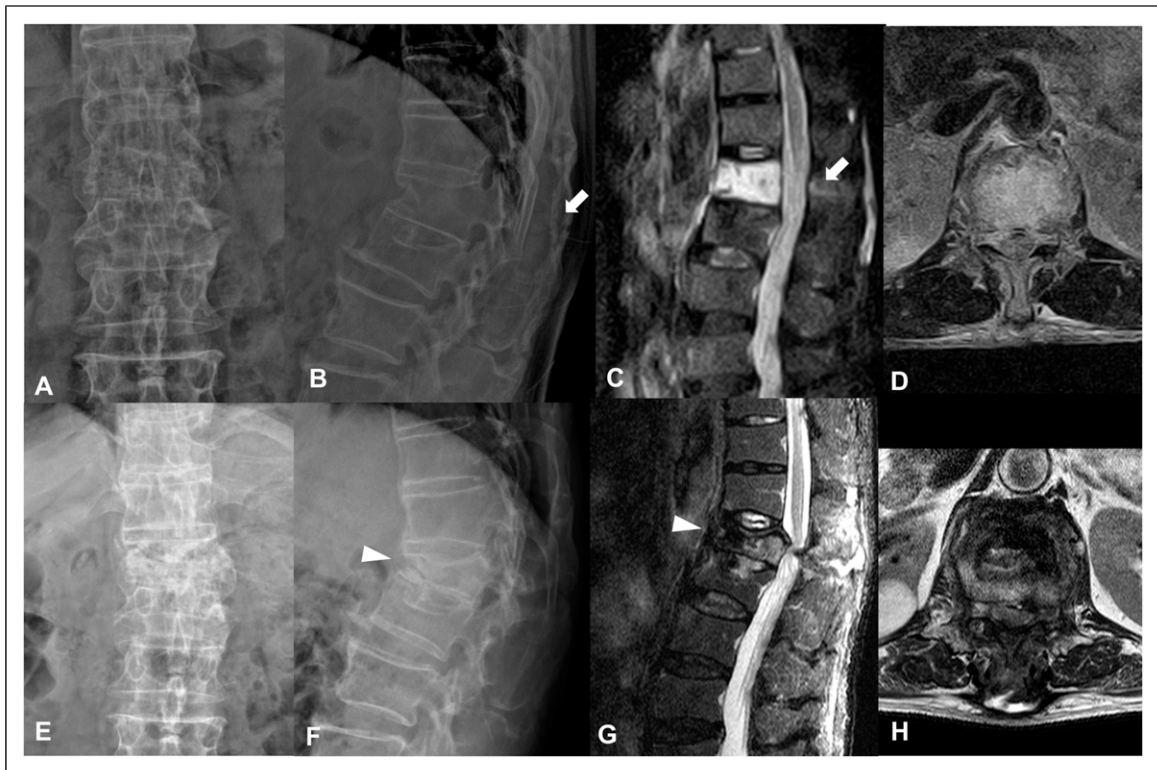
<sup>5</sup>Department of Orthopedic Surgery, Seoul St. Mary's Hospital, College of Medicine, The Catholic University of Korea, Seoul, Republic of Korea

Submitted May 6, 2021. Revised July 21, 2021. Accepted July 25, 2021

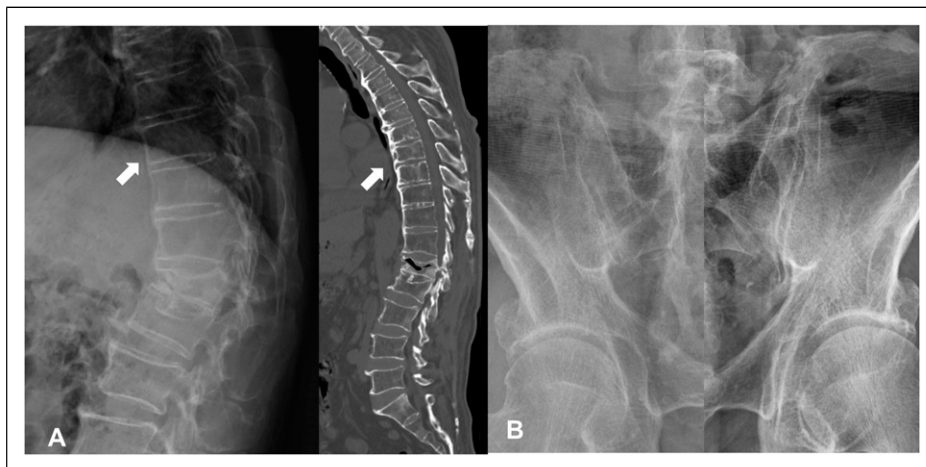
### Corresponding Author:

Hyung-Youl Park, MD, Department of Orthopedic Surgery, Eunpyeong St. Mary's Hospital, College of Medicine, The Catholic University of Korea, 1021, Tongil-Ro, Eunpyeong-gu, Seoul 03312, Republic of Korea.

Email: [matrixbest@naver.com](mailto:matrixbest@naver.com)



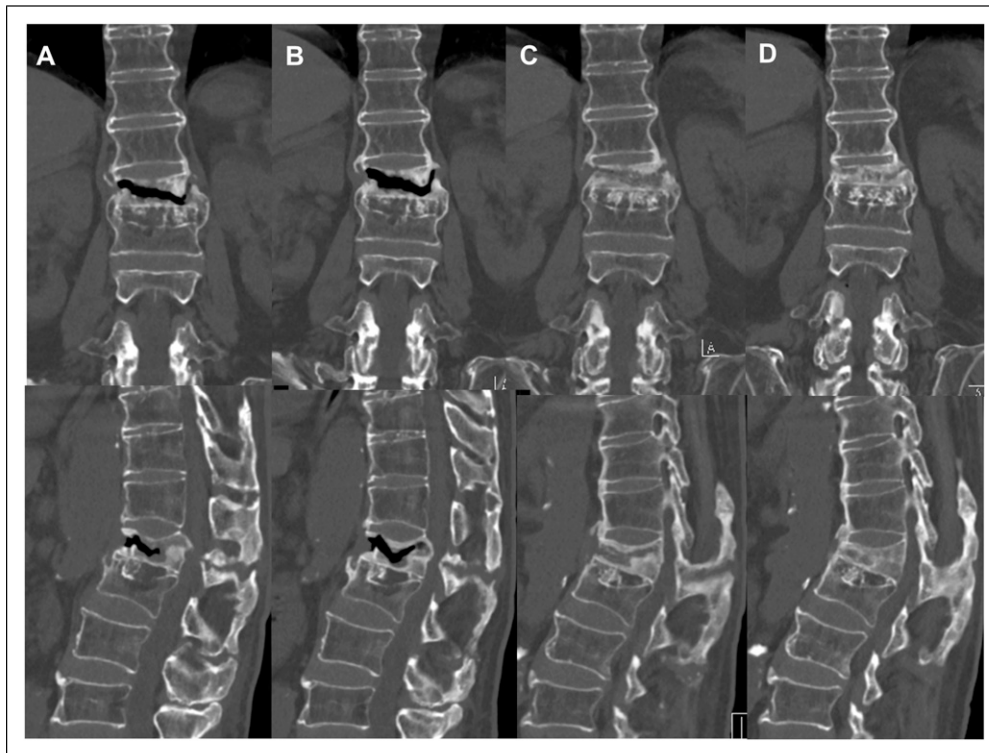
**Figure 1.** (A)-(D) Initial plain radiographs and MR images showing the L1 bony Chance fracture featured with spinous fracture (white arrow). (E)-(H) Subsequent plain radiographs and MR images showing vertebral body collapse and intravertebral vacuum cleft (white arrowhead) with canal encroachment. MR: magnetic resonance.



**Figure 2.** Thoracolumbar plain radiograph and computed tomography showing anterior longitudinal ligament ossification (white arrow) at more than 4 consecutive levels (A) without evidence of sacroiliitis (B).

complained of tolerable mechanical back pain without neurologic deficits. However, the patient had used TLSO for 6 months, when bridging callus was observed and pain was alleviated.

Similarly, Yu et al<sup>15</sup> reported the therapeutic efficacy of teriparatide in a retrospective study that included 35 patients with osteoporotic thoracolumbar burst fracture but no neurological deficits. Although short-term functional



**Figure 3.** Serial computed tomography coronal and sagittal scans showing solid bony fusion replacing the intravertebral vacuum cleft at 3 months (A), 6 months (B), 10 months (C), and 14 months (D) after trauma.

**Table 1.** Previous Case Reports of Fractures Treated With Teriparatide in Ankylosed Spine.

Author and year	Age	Sex	Fracture	Pathology	Special note	Duration of teriparatide	Outcome
Franco et al. (2013)	52	Male	Pseudarthrosis of C7 fracture	AS	Pseudarthrosis after surgery	2 months	Profuse bone fusion in fracture callus Alleviation of pain
Matsumoto et al. (2015)	70	Male	Delayed union of L2 fracture	DISH	Complete paraplegia	6 months	Hyperplastic bone formation 87% reduction in pain score and 100% improvement in functional score in Barthel Index
Biro et al. (2017)	56	Male	T2 transverse fracture	AS	Refusal to surgery	6 months	Complete healing of T2 fracture

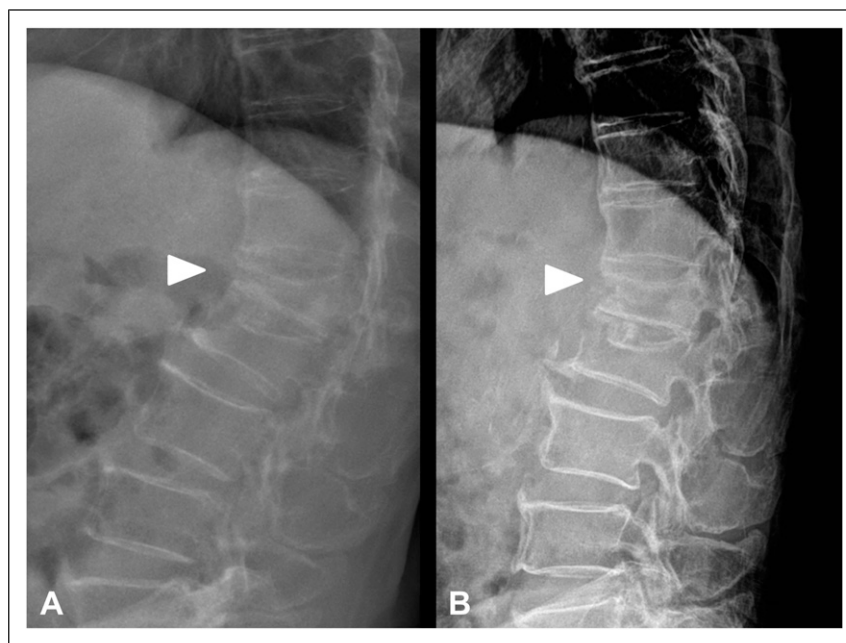
AS: ankylosing spondylitis; DISH: diffuse idiopathic skeletal hyperostosis.

outcomes with structural restoration were better with teriparatide treatment together with vertebroplasty and surgical fixation with fusion groups, similar functional outcomes and solid bony fusion were achieved in the non-surgical treatment with teriparatide only.

Therefore, conservative managements including teriparatide could be carefully considered for potentially unstable fractures at the thoracolumbar junction, without neurological deficit and intractable back pain. Further, the present case suggested the effectiveness of teriparatide

treatment in unstable fracture with IVC at thoracolumbar junction, even in DISH ankylosed patients.

However, further studies are needed to validate our results and appropriate duration of teriparatide injection for solid union of unstable fractures. Moreover, a recent study<sup>16</sup> reported that romosozumab, a humanized monoclonal antibody directed against sclerostin, provided greater BMD gains at the lumbar spine and hip than teriparatide through dual action: increase in bone formation and decrease in bone resorption. In this regard, it would be



**Figure 4.** Preoperative lateral radiographs showing unstable fracture due to intravertebral vacuum cleft (A) in the standing position and (B) in the supine position.

important to study the efficacy of romosozumab in fracture healing and compare it with teriparatide.

## Conclusion

Although surgical management is strongly recommended for unstable fracture in ankylosed spine due to AS and DISH, non-surgical approach might be safer and effective option in bony Chance fracture without neurologic deficit and intractable mechanical pain. Herein, we demonstrated teriparatide, a bone-forming agent that accelerate bone healing, as an effective alternative treatment.

## Declaration of Conflicting Interests

The author(s) declared no potential conflicts of interest with respect to the research, authorship, and/or publication of this article.

## Funding

The author(s) disclosed receipt of the following financial support for the research, authorship, and/or publication of this article: This research was supported by Basic Science Research Program through the National Research Foundation of Korea (NRF) funded by the Ministry of Education (2021R111A1A01059501).

## ORCID iDs

Hyung-Youl Park  <https://orcid.org/0000-0002-0084-8867>  
Jun-Seok Lee  <https://orcid.org/0000-0003-4321-9611>

## References

1. Hunter T, Forster B, Dvorak M. Ankylosed spines are prone to fracture. *Can Fam Physician*. 1995;41:1213-1216.
2. Yeoh D, Moffatt T, Karmani S. Good outcomes of percutaneous fixation of spinal fractures in ankylosing spinal disorders. *Injury*. 2014;45(10):1534-1538. doi:10.1016/j.injury.2014.03.020.
3. Westerveld LA, Verlaan JJ, Oner FC. Spinal fractures in patients with ankylosing spinal disorders: a systematic review of the literature on treatment, neurological status and complications. *Eur Spine J*. 2009;18(2):145-156. doi:10.1007/s00586-008-0764-0.
4. Mathews M, Bolesta MJ. Treatment of spinal fractures in ankylosing spondylitis. *Orthopedics*. 2013;36(9):e1203-e1208. doi:10.3928/01477447-20130821-25.
5. Cortés Franco S, Lorente Muñoz A, Perez Barrero P, Alberdi Viñas J. "Surgical failure in patient with cervical fracture and ankylosing spondylitis treated with teriparatide to try to augment consolidation". *Acta Neurochir*. 2013;155(10):1955-1956. doi:10.1007/s00701-013-1825-7.; discussion 1956
6. Biro I, Bubbear J, Donnelly S, et al. Teriparatide and vertebral fracture healing in ankylosing Spondylitis. *Trauma Case Rep*. 2017;12:34-39. doi:10.1016/j.tcr.2017.10.014.
7. Matsumoto T, Ando M, Sasaki S. Effective treatment of delayed union of a lumbar vertebral fracture with daily administration of teriparatide in a patient with diffuse idiopathic skeletal hyperostosis. *Eur Spine J*. 2015;24(suppl 4):573-576. doi:10.1007/s00586-014-3733-9.
8. Resnick D, Shaul SR, Robins JM. Diffuse idiopathic skeletal hyperostosis (DISH): forestier's disease with extraspinal

- manifestations. *Radiology*. 1975;115(3):513-524. doi:10.1148/15.3.513.
9. Min HK, Ahn JH, Ha KY, et al. Effects of anti-osteoporosis medications on radiological and clinical results after acute osteoporotic spinal fractures: a retrospective analysis of prospectively designed study. *Osteoporos Int*. 2019;30(11):2249-2256. doi:10.1007/s00198-019-05125-0.
  10. Jang HD, Kim EH, Lee JC, Choi SW, Kim K, Shin BJ. Current concepts in the management of osteoporotic vertebral fractures: a narrative review. *Asian Spine J*. 2020;14(6):898-909. doi:10.31616/asj.2020.0594.
  11. Caron T, Bransford R, Nguyen Q, Agel J, Chapman J, Bellabarba C. Spine fractures in patients with ankylosing spinal disorders. *Spine*. 2010;35(11):E458-E464. doi:10.1097/BRS.0b013e3181cc764f.
  12. Lee JS, Ahn DK, Shin WS, Cho KJ, Ko YR, Whang IC. Vertebral body anterior translation, a novel technique for delayed myelopathy due to osteoporotic spine fractures. *Clin Orthop Surg*. 2020;12(4):485-492. doi:10.4055/cios20028.
  13. Riggs D, Redman C, Riggs A. Teriparatide in the management of osteoporosis. *Clin Interv Aging*. 2007;2(4):499-507. doi:10.2147/cia.s241.
  14. Park HY, Ahn JH, Ha KY, et al. Clinical and radiologic features of osteoporotic spine fracture with delayed neurologic compromises. *World Neurosurg*. 2018;120:e1295-e1300. doi:10.1016/j.wneu.2018.09.056.
  15. Yu D, Kim S, Jeon I. Therapeutic effect of teriparatide for osteoporotic thoracolumbar burst fracture in elderly female patients. *J Korean Neurosurg Soc*. 2020;63(6):794-805. doi:10.3340/jkns.2020.0110.
  16. Nealy KL, Harris KB. Romosozumab: a novel injectable sclerostin inhibitor with anabolic and antiresorptive effects for osteoporosis. *Ann Pharmacother*. 2021;55(5):677-686. doi:10.1177/1060028020952764.