

CASE REPORT

Idiopathic spinal cord herniation with postoperative paraplegia—A case report

Syed Ifthekar¹  | Sang-Ha Shin²  | Sang-Ho Lee²  | Junseok Bae² 

¹All Indian Institute of Medical Sciences, Hyderabad, Telangana, India

²Wooridul Spine Hospital, Seoul, South Korea

Correspondence

Sang-Ha Shin, Wooridul Spine Hospital, Cheongdam, Seoul, South Korea.

Email: anconeus@daum.net

Key clinical message

Spinal cord herniation is an uncommon diagnosis. There should be a high index of suspicion to diagnose spinal cord herniation when a patient presents with incomplete neurological deficits. Surgical repair of the hernia can have postoperative complications with new neurological deficits and they should be considered during the treatment.

Abstract

A 37-year-old male presented with insidious onset upper back pain and altered sensations of pain and temperature over the right half of the body below the nipple for 2 months. MRI of the thoracic spine showed an anterolateral defect (left) at the level of T2-T3 vertebra. The defect was covered by a dural graft and the wound was closed with a drain. On the 3rd postoperative day, neurological weakness progressed to paraplegia. Patient was treated by exploration and decompression of the hematoma. The deficits were completely recovered at one-month follow-up. Patients with spinal cord herniation and neurologic deficits when treated timely have good outcomes.

KEYWORDS

Brown-Sequard's syndrome, case report, hernia, paraplegia, spinal cord

1 | BACKGROUND

Spinal cord herniation is an uncommon diagnosis in the field of spine surgery.¹ The etiology is unknown but few theories are attributed to spontaneous herniation like congenital defects in the dura, pressure erosion of the dura, duplication of anterior dura, and traumatic etiology.^{1,2} The usual presentation of spontaneous spinal cord herniation is in the form of progressive Brown-Sequard syndrome.³ Neurological deficits are thought to occur as a result of tethering of herniated cord to the surrounding structures.⁴ The tethering causes a longitudinal stretch and impairs the neuronal oxidative metabolism resulting in a wide

spectrum of neurological deficits.⁴ The neurological deficits stabilize or recover when the herniation is reduced surgically and the dural defect is closed.⁵ We describe a case of a 37-year-old male with progressive back pain and sensory deficits due to spinal cord herniation and a post-operative complication associated with reduction of the hernia.

2 | CASE REPORT

A 37-year-old male patient visited the outpatient clinic with insidious onset of upper back pain and altered sensations of pain and temperature over the right half of

This is an open access article under the terms of the [Creative Commons Attribution-NonCommercial-NoDerivs](https://creativecommons.org/licenses/by-nc-nd/4.0/) License, which permits use and distribution in any medium, provided the original work is properly cited, the use is non-commercial and no modifications or adaptations are made.

© 2023 The Authors. *Clinical Case Reports* published by John Wiley & Sons Ltd.

the body below the nipple 2 months before the examination. The patient did not have motor weakness of lower limbs, abnormal/involuntary movements, or loss of control over the bowel and bladder. There was no history of injury to the back, fever, weight loss, or any other constitutional symptoms. There was no history of Diabetes Mellitus, hypertension, or other co-morbidities. There was no specific tenderness or visible deformity of the spine. The complete neurological examination is described in [Table 1](#).

The radiologic examination was done in the form of X-rays of the thoracic spine in anteroposterior and lateral views. There were no significant findings on the x-ray of the thoracic spine. Magnetic Resonance Imaging (MRI) of the thoracic spine showed an anterolateral defect(left) in the dura at the level of the T2-T3 vertebra ([Figure 1A, B](#)). Computed Tomography (CT) scan of the thoracic spine also showed a defect of the spinal cord at the T2-T3 vertebral level ([Figure 2A-C](#)). A differential diagnosis of spontaneous spinal cord herniation and arachnoid cysts was considered. Surgical intervention was planned as the patient had neurological deficits.

A posterior approach was chosen to repair the spinal cord defect. After laminectomy, the dural defect was assessed and the diagnosis of spontaneous spinal cord herniation was confirmed ([Figure 3A](#)). The cord with roots was reduced into the dura. The defect was covered by a dural graft (Lyodura) and the wound was closed with a drain insitu ([Figure 3B](#)). The patient's sensory deficits improved on the first postoperative day. The output from the drain was 100 mL on the first postoperative day and 50 mL on the second postoperative day. The drain was removed in the evening of second postoperative day. In the early morning of the third post-operative day, the

patient complained of pain over the operated site and inability to move bilateral lower limbs. On examination, there was a marked swelling over the operated site and paraplegia. The motor weakness was also associated with sensory loss below the nipples bilaterally. However, bowel and bladder control was not lost. The patient was immediately taken into the operating room as there was swelling and tenderness over the wound and a hematoma compressing the spinal cord was suspected. The stitches were removed and the wound was explored. There was a hematoma at the operated site which was removed ([Figure 4](#)). The bleeders were identified and cauterized. Repair of the defect was re-examined and was found to be satisfactory. Layer-wise closure was done. The check MRI showed good closure of the defect and compression over spinal cord ([Figure 5A,B](#)). The motor weakness recovered but the sensory paraesthesia persisted till the ninth postoperative day. The patient was discharged on the ninth postoperative day with residual sensory deficits and was kept under regular follow-up. The deficits were completely recovered at one-month follow-up. The recovery was maintained till the last follow-up at 10 years.

3 | DISCUSSION

Thoracic spinal cord herniation is a rarely reported diagnosis in the literature. The rarity may partly be due to the difficulty in arriving at the diagnosis due to inconsistent clinical findings.⁵ The first case was reported by wortzman G et al when high resolution MRI was not available for diagnosis.⁶ The study group identified a progressive Brown-Sequard-like syndrome which was not explained

Examination	Right lower limb	Left lower limb
Tone	Normal	Normal
Myotomes- L2	5/5	5/5
L3	5/5	5/5
L4	5/5	5/5
L5	5/5	5/5
S1	5/5	5/5
Abnormal movements	Absent	Absent
Abdominal reflex	Normal	Normal
Knee reflex	Normal	Normal
Ankle reflex	Normal	Normal
Plantar reflex	Flexor	Flexor
Sensations	Loss of pain and temperature below nipple	Normal
Bowel and bladder	Unaffected	Unaffected

TABLE 1 Complete neurological examination of the patient.

by the usual etiology.⁶ The majority of the spontaneous thoracic cord herniations reported in the literature are in the form of single case reports and we found less than

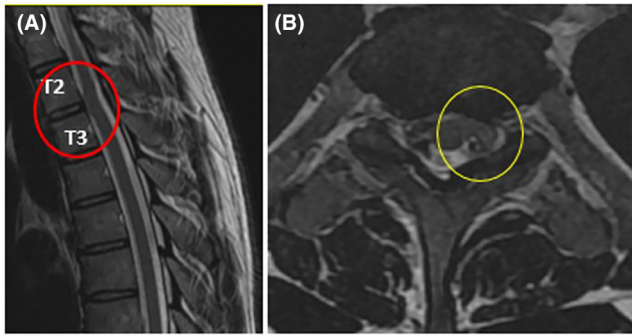


FIGURE 1 (A) Preoperative Sagittal view of MRI showing tethering of the dura at the level of the T2-T3 vertebra. (B) Preoperative Axial view of MRI showing an anterolateral defect(left) in the dura at the level of the T2-T3 vertebra.

220 cases in the entire literature to date.¹ Most of the cases of herniations are localized between the thoracic third and seventh segments in the middle-aged individuals.⁷ The herniation of the spinal cord through the dura usually occurs through the anterior or anterolateral part of the dural sheath.¹ The dorsal herniation is very rare.⁴ There are few postulated theories for the herniation of the spinal cord which include congenital dural deficiency with a preexisting anterior meningocele, traumatic etiology, duplication of anterior dura, and microscopic erosion of anterior dura during repeated flexion and extension but none of these etiologies are proven in literature.^{1,2} So, this condition is often referred to as an idiopathic condition.²

The cases of spinal cord herniation show a wide spectrum of symptoms. The usual presenting symptom is progressive Brown-Sequard type of syndrome with contralateral altered pain and temperature with ipsilateral hemiparesis.³ The neurological deficits may or may not

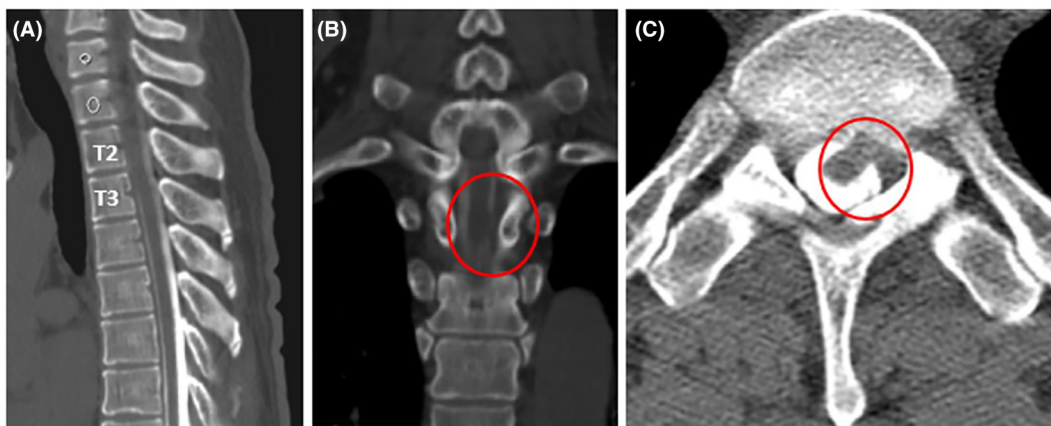


FIGURE 2 (A) Preoperative Sagittal view of CT scan showing tethering of the dura at the level of the T2-T3 vertebra. (B) Preoperative Coronal view of CT scan showing an anterolateral defect(left) in the dura at the level of the T2-T3 vertebra. (C) Preoperative Axial view of CT scan showing an anterolateral defect(left) in the dura at the level of the T2-T3 vertebra.

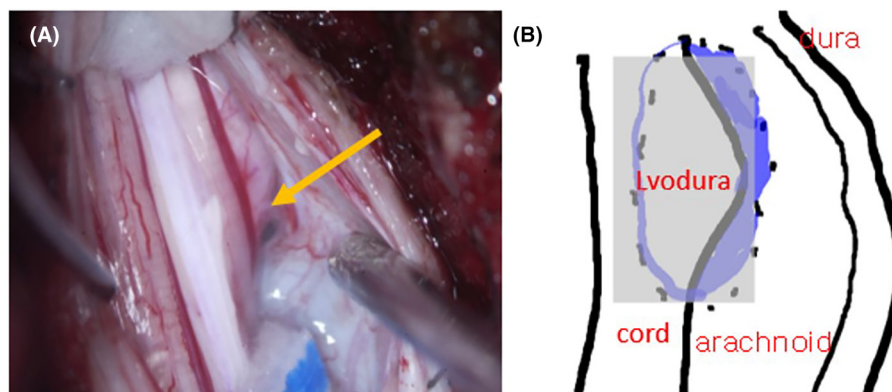


FIGURE 3 (A) Intraoperative image showing the defect in the dura and herniation. (B) An illustrative image showing the defect being covered by Lyodura.

follow the dermatomal/myotomal distribution. The adhesion of the spinal cord to the surrounding structures and resultant vascular compromise are thought to cause neurological deficits.⁴ Due to these non-standard symptoms, many cases of spinal cord herniations were misdiagnosed as medical causes of paraplegia like multiple sclerosis, demyelinating neuropathy, and sub-acute combined degeneration of spinal cord.⁸ With the wide-spread use of MRI for the diagnosis of spinal conditions, many cases of spinal cord herniations are being reported in the recent past. The MRI sagittal view would show focal anterior displacement of the spinal cord and the axial view shows a lateral defect in the dura and herniation of the spinal cord.⁹ Care must be taken not to miss the arachnoid cysts if they are present with spinal cord herniations.⁹ The

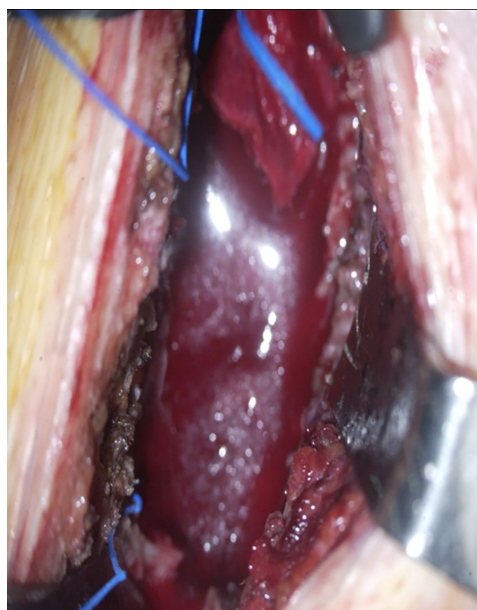


FIGURE 4 Intraoperative image showing hematoma and bleeder.

nerve roots are visible in the periphery of the arachnoid cysts whereas the nerve roots are visible in the dorsal sub-arachnoid region in the case of spinal cord herniations without arachnoid cysts.^{1,9}

The usual treatment in patients presenting with neurological deficits and with a diagnosis of spinal cord herniation is surgical repair of the herniation.¹⁰ The repair is focused on reducing the cord contents into the dura and closing the defect. Reducing the cord into the dura has been shown to improve neurological symptoms.¹¹ There are few cases where the symptoms have deteriorated even after surgical intervention. The cause could be late re-ethering or the development of hematoma causing compression. In our case, although the neurological deficits improved after surgery, there was a sudden deterioration of the neurology on the third day. This is usually due to hematoma causing mechanical compression or occlusion of venous drainage. In our case, the etiology was hematoma and removal of hematoma satisfactorily treated the symptoms. Development of epidural hematoma in the postoperative period is one of the commonest causes for deterioration of neurology. Awad JN et al in their study investigated the risk factors for development of post-operative spinal epidural hematoma. The study group found Non-steroidal anti-inflammatory drugs (NSAIDs), Rh-positive blood group, and patient age of more than 60 years as significant risk factors for post-operative spinal epidural haematoma.¹² Kou et al in their study found multilevel procedures and the presence of a preoperative coagulopathy as significant risk factors.¹³ Amiri AR et al in their study proposed alcohol consumption greater than 10 units a week, multilevel procedure, and previous spinal surgery as risk factors for developing postoperative epidural hematoma.¹⁴ The insitu placement of drain reduces the chances of hematoma by draining the collection. But in few cases where the bleeding does not stop, removal of

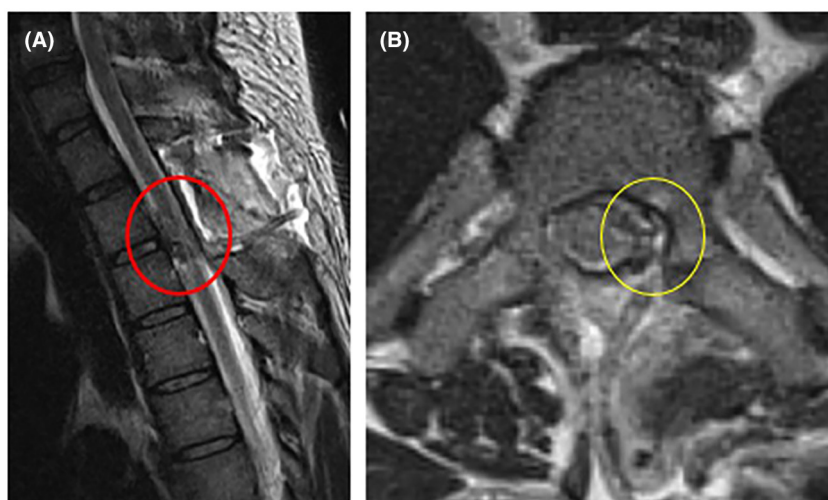


FIGURE 5 (A) Postoperative Sagittal view of MRI showing the repaired defect of the dura at the level of the T2-T3 vertebra. (B) Postoperative Axial view of MRI showing the repaired defect of anterolateral dura at the level of the T2-T3 vertebra.

drain may cause new neurological symptoms as in our case. The treating team can benefit by close evaluation of the patients for the risk factors and prognosticate the patients as well as their relatives regarding the chances of developing postoperative epidural hematoma. The acceptance of complications post-surgery would increase if preoperative counseling is appropriate and evidence based. Ammar et al reported spontaneous retethering in patients with spinal cord herniation after treatment.¹⁵ The patient should be kept in constant follow-up and the retethering symptoms should be explained in detail at discharge.

The evidence available in the literature for treating spontaneous spinal cord herniations is limited to case reports and few case series. As there are reports stating spontaneous reduction of the hernia and deterioration of symptoms after surgery, strong guidelines for the management of spinal cord herniations are lacking.¹ With the extensive use of MRI, the number of cases diagnosed as spinal cord herniation is increasing and strong evidence-based guidelines for which patients to be treated surgically are the need of the hour.

4 | CONCLUSION

Patients with spinal cord herniation and neurologic deficits when treated timely with reduction of the hernia, have good outcomes. A constant watch on neurological deterioration after removal of drain helps in identifying early hematoma collection.

AUTHOR CONTRIBUTIONS

Syed Ifthekar: Data curation; writing – original draft. **Sang-Ha Shin:** Conceptualization; formal analysis; methodology; writing – review and editing. **Sang-Ho Lee:** Conceptualization; investigation; project administration; supervision. **Junseok Bae:** Formal analysis; methodology; resources; validation.

ACKNOWLEDGMENTS

None.

FUNDING INFORMATION

None.

CONFLICT OF INTEREST STATEMENT

None.

DATA AVAILABILITY STATEMENT

The data that support the findings of this study are available from the corresponding author upon reasonable request.

CONSENT

“Written informed consent was obtained from the patient to publish this report in accordance with the journal’s patient consent policy”.

ORCID

Syed Ifthekar  <https://orcid.org/0000-0002-3546-5962>

Sang-Ha Shin  <https://orcid.org/0000-0001-7014-3603>

Sang-Ho Lee  <https://orcid.org/0000-0002-8526-0260>

Junseok Bae  <https://orcid.org/0000-0003-0042-7242>

REFERENCES

- Samuel N, Goldstein CL, Santaguida C, Fehlings MG. Spontaneous resolution of idiopathic thoracic spinal cord herniation: case report. *J Neurosurg Spine*. 2015;23:306-308. doi:10.3171/2014.12.SPINE14950
- Morley S, Naidoo P, Robertson A, Chong W. Thoracic ventral dural defect: idiopathic spinal cord herniation. *Australas Radiol*. 2006;50:168-170. doi:10.1111/j.1440-1673.2006.01547.x
- Cellerini M, Bayon S, Scazzari F, et al. Idiopathic spinal cord herniation: a treatable cause of Brown-Séquard syndrome. *Acta Neurochir*. 2002;144:321-325. doi:10.1007/s007010200044
- Le TC, Grunch BH, Karikari IO, et al. Dorsal thoracic spinal cord herniation: report of an unusual case and review of the literature. *Spine J*. 2012;12:e9-e12. doi:10.1016/j.spinee.2012.09.039
- Jeong K-H, Lee H-W, Kwon Y-M. Spontaneous anterior thoracic spinal cord herniation through dura defect: a case report. *Korean J Spine*. 2016;13:77-79. doi:10.14245/kjs.2016.13.2.77
- Wortzman G, Tasker RR, Rewcastle NB, Richardson JC, Pearson FG. Spontaneous incarcerated herniation of the spinal cord into a vertebral body: a unique cause of paraplegia. *Case Report J Neurosurg*. 1974;41:631-635. doi:10.3171/jns.1974.41.5.0631
- Groen RJM, Middel B, Meilof JF, et al. Operative treatment of anterior thoracic spinal cord herniation: three new cases and an individual patient data meta-analysis of 126 case reports. *Neurosurgery*. 2009;64-65; discussion 159-160. doi:10.1227/01.NEU.0000327686.99072.E7
- Hassler W, Al-Kahlout E, Schick U. Spontaneous herniation of the spinal cord: operative technique and follow-up in 10 cases: clinical article. 2008;9:438-443. doi:10.3171/SPI.2008.9.11.438
- Sioutos P, Arbit E, Tsairis P, Gargan R. Spontaneous thoracic spinal cord herniation. *A Case Report Spine (Phila Pa 1976)*. 1996;21:1710-1713. doi:10.1097/00007632-199607150-00019
- Kawachi I, Nozaki H, Watanabe M, Sato A, Tsuji S. Spontaneous spinal cord herniation. *Neurology*. 2001;56:977. doi:10.1212/wnl.56.7.977
- Eguchi T, Yokota H, Nikaido Y, et al. Spontaneous thoracic spinal cord herniation—case report. *Neurol Med Chir (Tokyo)*. 2001;41:508-512. doi:10.2176/nmc.41.508
- Awad JN, Kebaish KM, Donigan J, Cohen DB, Kostuik JP. Analysis of the risk factors for the development of post-operative spinal epidural haematoma. *J Bone Joint Surg British*. 2005;87-B:1248-1252. doi:10.1302/0301-620X.87B9.16518
- Kou J, Fischgrund J, Biddinger A, Herkowitz H. Risk factors for spinal epidural hematoma after spinal surgery. *Spine (Phila Pa 1976)*. 2002;27:1670-1673. doi:10.1097/00007632-200208010-00016

14. Amiri AR, Fouyas IP, Cro S, Casey ATH. Postoperative spinal epidural hematoma (SEH): incidence, risk factors, onset, and management. *Spine J.* 2013;13:134-140. doi:[10.1016/j.spinee.2012.10.028](https://doi.org/10.1016/j.spinee.2012.10.028)
15. Ammar KN, Pritchard PR, Matz PG, Hadley MN. Spontaneous thoracic spinal cord herniation: three cases with long-term follow-up. *Neurosurgery.* 2005;57:E1067; discussion E1067. doi:[10.1227/01.neu.0000180016.69507.e0](https://doi.org/10.1227/01.neu.0000180016.69507.e0)

How to cite this article: Ifthekar S, Shin S-H, Lee S-H, Bae J. Idiopathic spinal cord herniation with postoperative paraplegia—A case report. *Clin Case Rep.* 2023;11:e8246. doi:[10.1002/ccr3.8246](https://doi.org/10.1002/ccr3.8246)