

# Medial Meniscal Allograft Transplantation With Bone Plugs Using a 3-Tunnel Technique



Shao Jin Teo, M.B.B.S., Marcus Wei Ping Tan, M.B.B.S., M.R.C.S.Ed.,  
Don Thong Siang Koh, M.B.B.S., M.R.C.S.Ed., and  
Kong Hwee Lee, M.B.B.S., M.R.C.S.Ed., M.Med., F.R.C.S.Ed.

**Abstract:** Meniscal allograft transplantation is an area of active research, given that the importance of the meniscus in native knee joint longevity has been increasingly recognized. This article describes a modified meniscal allograft transplantation technique using 3 bone tunnels with allograft fixation through the use of bone plugs. The addition of a third tunnel increases the strength of fixation, avoiding meniscal extrusion and improving load distribution.

The importance of the meniscus in maintaining normal load absorption and distribution in the knee joint is well documented. It plays a critical role in impact absorption and load distribution, shielding the other structures of the knee joint from excessive tension and prolonging longevity of the native knee joint. Meniscus-deficient knees have been shown to experience an accelerated degenerative process, leading to symptomatic osteoarthritis at an earlier age.<sup>1,2</sup> Yet, the regenerative ability of the menisci is limited. In the treatment of meniscal tears and injuries, surgeons previously have largely had to choose between meniscectomy and meniscal repair. In recent years, however,

there has been increasing interest and confidence in meniscal replacement.<sup>3-5</sup> A variety of techniques for performing meniscal allograft transplantation (MAT) have been described in the literature, differing in the number of bone tunnels created, the placement of allograft, the method of root fixation, and even the amount of meniscus transplanted, among other variables.<sup>6-8</sup> This article details our technique of medial MAT using 3 bone tunnels and fixation via bone plugs.

## Surgical Technique

### Patient Selection

The indications for MAT are (1) patients aged younger than 50 years with a nonfunctional medial meniscus as a result of previous partial or total meniscectomy, (2) patients who are functionally limited by localized pain in the medial compartment, (3) patients with cartilage defect severity less than Outerbridge grade II, and (4) patients with normal or correctable knee alignment. Contraindications include (1) patients aged older than 50 years, (2) patients with osteoarthritic changes or chondral loss corresponding to an Outerbridge classification of III or greater, (3) patients with concomitant knee instability due to ligamentous injury, and (4) patients with fixed varus knee deformities.

### Allograft Sizing and Preparation

Preoperative magnetic resonance images of the joint are sent to a certified tissue bank (JRF Ortho, Centennial, CO). An appropriately sized, fresh-frozen medial

*From the Department of Orthopaedic Surgery, Singapore General Hospital, Singapore, Singapore.*

*The authors report the following potential conflicts of interest or sources of funding: S.J.T. receives nonfinancial support from Arthrex for technical support with video editing and surgical equipment. M.W.P.T. receives nonfinancial support from Arthrex for technical support with surgical equipment and production of technique video. D.T.S.K. receives nonfinancial support from Arthrex for technical support with surgical equipment and video production. K.H.L. receives personal fees and nonfinancial support from Arthrex for technical support with surgical equipment and video production and receives speaking/lecture fees from Arthrex regarding surgical technique described in article. Full ICMJE author disclosure forms are available for this article online, as supplementary material.*

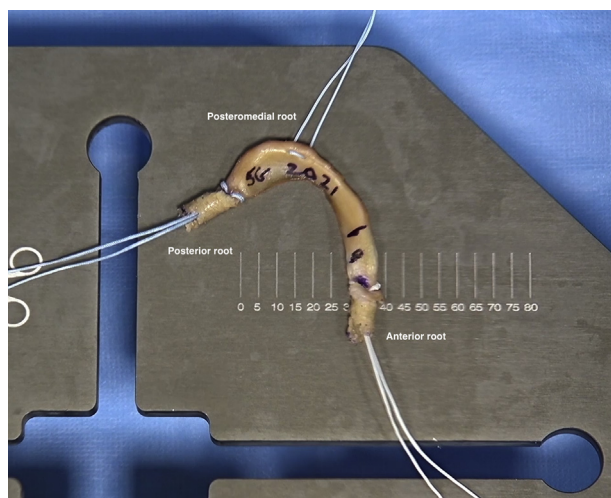
*Received August 15, 2021; accepted October 17, 2021.*

*Address correspondence to Shao Jin Teo, M.B.B.S., Department of Orthopaedic Surgery, Singapore General Hospital, 20 College Road Academia, Level 4, Singapore 169865, Singapore. E-mail: Tsj2395@gmail.com*

© 2021 THE AUTHORS. Published by Elsevier Inc. on behalf of the Arthroscopy Association of North America. This is an open access article under the CC BY-NC-ND license (<http://creativecommons.org/licenses/by-nc-nd/4.0/>).

2212-6287/211184

<https://doi.org/10.1016/j.eats.2021.10.009>



**Fig 1.** Prepared meniscal allograft with FiberLoop sutures passed through anterior and posterior roots and bone plugs. FiberWire suture is used for the posteromedial root. The roots are labeled.

meniscus with bone block allograft, matched for height and weight, is obtained from the bank.

### Graft Preparation

The allograft is placed into the sterile field and thawed in a mixture of 1 g of vancomycin and 200 mL of normal saline solution for a minimum of 30 minutes. The bone block is fixed onto a benchtop, and the meniscal roots are marked with methylene blue. A 2.4-mm drill bit with a curved aiming guide is used to create a tract from the cortical bone inferiorly to the posterior root attachment superiorly (Video 1). The drill bit is replaced with a blunt collared pin, and an 8-mm coring reamer is used to bore a dowel of bone toward the posterior root attachment. The reamer is advanced carefully to prevent allograft damage. Rotational movements of the reamer allow delivery of the bone plug superiorly. This is repeated for the anterior root. The length of each bone plug is trimmed to 10 mm, resulting in a donor meniscus with two 8 × 10-mm bone plugs.

Next, a No. 2 FiberLoop suture (Arthrex, Naples, FL) is passed through the posterior root attachment, and the needle is passed back down into the posterior plug and cut at the free end. This is repeated for the anterior root. A horizontal mattress suture is placed at the posteromedial corner of the meniscus, 2 cm from the posterior root, using No. 2 FiberWire suture (Arthrex) (Fig 1). The graft is then placed in a vancomycin-soaked gauze.

### Patient Positioning and Initial Visualization

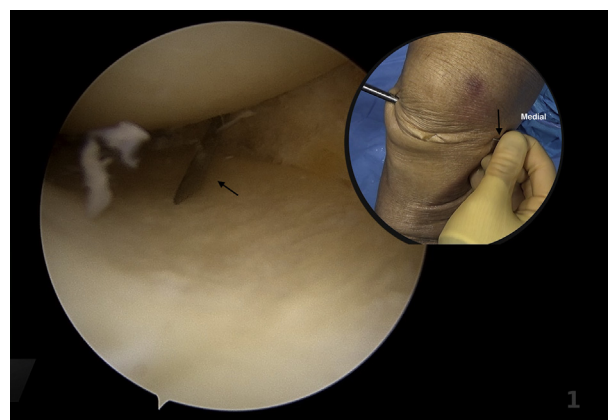
The patient is positioned supine with the operated leg held in an arthroscopic leg holder. The contralateral leg is placed on a stirrup away from the operating field.

After routine skin cleansing and draping, the antero-lateral and anteromedial portals are established. A diagnostic arthroscopy is performed, focusing on the state of the cartilage, anterior cruciate ligament, and remnant medial meniscus. Pie crusting of the medial collateral ligament is performed with an 18-gauge needle, with a valgus force applied to improve medial joint space visualization (Fig 2). The meniscal bed is prepared by debriding the remnant meniscus until bleeding is seen. A radiofrequency probe is used to clear any soft tissues and mark out the root attachments.

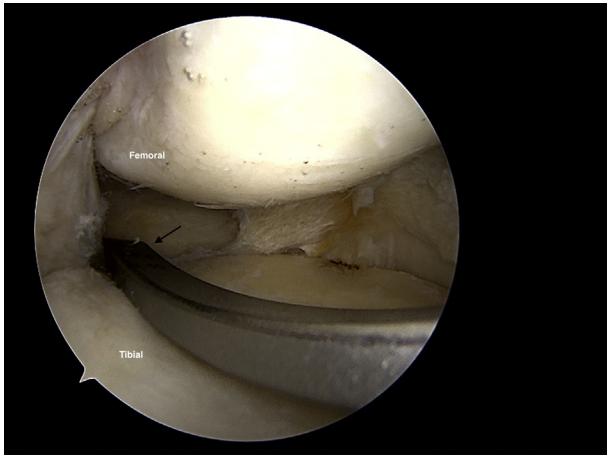
### Bony Tunnel Creation

**Posterior Tunnel.** An aiming guide with a meniscal root marking hook is placed at the posterior root footprint, 1 cm posterior to the apex of the medial eminence (Fig 3). Placing it at the posterior articular margin next to the posterior cruciate ligament may result in the tunnel being drilled too posteriorly. An incision is made over the anteromedial surface of the proximal tibia, and the guide is docked to the anterior cortex. An all-in-one guide pin and retrograde reamer (FlipCutter III; Arthrex) with a diameter of 9 mm is used. The tunnel diameter should be 1 mm larger than the allograft bone plug diameter for ease of implantation. After the guide pin is drilled to the posterior root footprint, the retrograde reamer is deployed under direct vision and reamed to a depth of 15 mm, completing a bony tunnel of 9 × 15 mm. A stiffened relay suture is passed through the bone tunnel and medial portal to be secured outside the knee.

**Posteromedial Tunnel.** An aiming guide with a tibial anterior cruciate ligament marking hook is used to identify the footprint at the articular margin, 2 cm



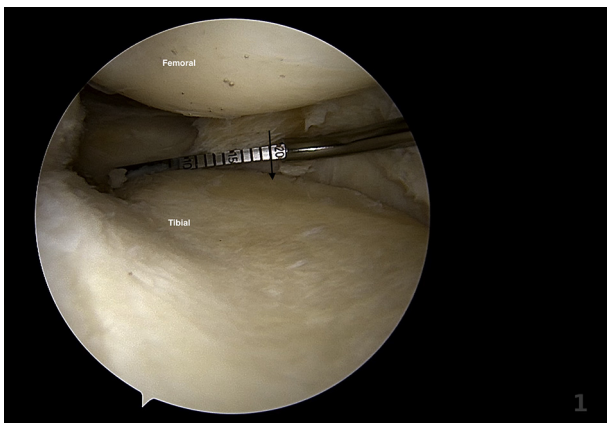
**Fig 2.** Pie crusting of the medial collateral ligament is performed with an 18-gauge needle (arrows), with a valgus force applied to improve medial joint space visualization. Bleeding from pie crusting can also increase neovascularization and promote healing of the allograft.



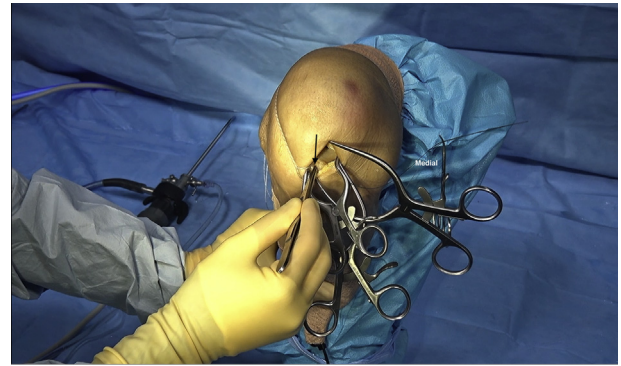
**Fig 3.** An aiming guide with meniscal root marking hook (arrow) is placed at the posterior root footprint, 1 cm posterior to the apex of the medial eminence.

medial to the posterior root attachment (Fig 4). The inferior aspect of the aiming guide is docked just medial to the bone tunnel for the posterior root. A 2.4-mm drill bit is passed to the posteromedial footprint, followed by a relay suture secured outside the knee joint.

**Anterior Tunnel.** The medial arthroscopy portal is extended 2 cm proximally and 1 cm distally to create a 4-cm mini-arthrotomy. Hyperflexion of the knee to 120° aids in visualization of the anterior tibial plateau (Fig 5). A 2.4-mm guidewire is drilled into the anterior root footprint in a posteroinferior manner. This pin is overdrilled with a 9-mm cannulated reamer to a depth of 15 mm and removed. A tunnel passage is created from the reamed tunnel to the anterior tibial cortex using an aiming guide with a tibial marking hook, positioned just lateral to the posterior root tunnel (Fig 6). A 2.4-mm guidewire is



**Fig 4.** The footprint for the posteromedial root is along the articular margin, 2 cm medial to the posterior root footprint (arrow).



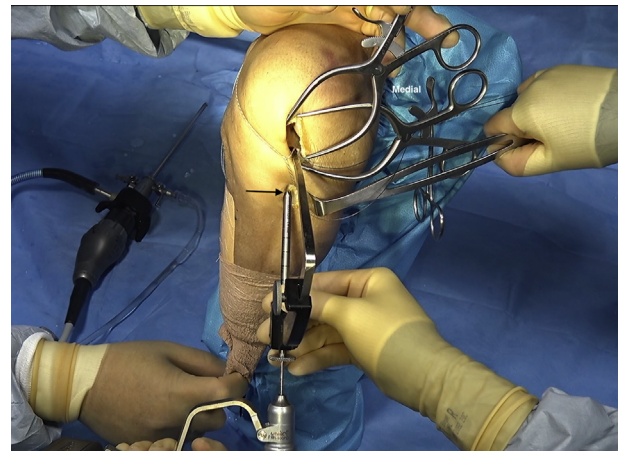
**Fig 5.** Anterior root footprint visible through mini-arthrotomy (arrow). The knee is hyperflexed to 120° to aid direct visualization.

passed through the aiming guide into the base of the anterior root tunnel, followed by a relay suture.

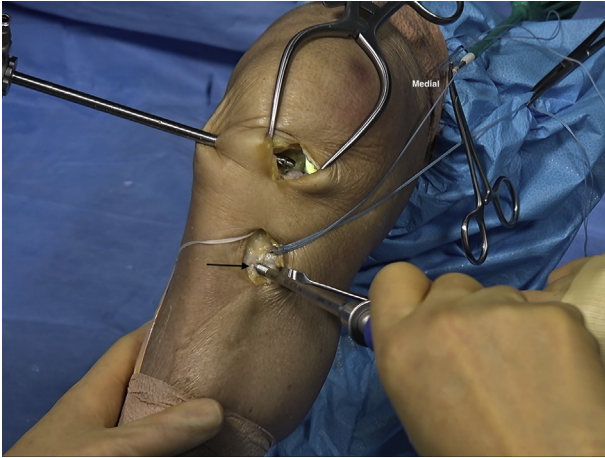
**Meniscal Graft Placement**

The surgeon should ensure that the relay sutures are passing freely through the same soft-tissue window at the medial arthrotomy. Each allograft suture is shuttled through its corresponding relay suture. The posterior and posteromedial sutures are pulled, introducing the allograft into the medial compartment. Pulling both sutures simultaneously prevents allograft inversion. Satisfactory placement is confirmed using the arthroscope. The anterior bone plug is then pulled into the anterior tunnel under direct vision.

All 3 sutures are pulled to tension and are clamped with a hemostat. The anterior and posterior root sutures are secured to the anterior cortex with a fully threaded, knotless bioabsorbable SwiveLock anchor (Arthrex) (Fig 7). The posteromedial suture is fastened using a 12-mm suture button.



**Fig 6.** An anterior tunnel aiming guide with a tibial marking hook is positioned just lateral to the posterior root tunnel (arrow).



**Fig 7.** The anterior and posterior root sutures are secured to the anterior cortex with a fully threaded, knotless bio-absorbable SwiveLock anchor (arrow).

### Meniscocapsular Fixation

The anterior horn is secured first under direct visualization. Two or three No. 2 FiberWire mattress sutures are placed to secure the anterior horn to the anterior capsule. The arthrotomy is closed with No. 1 Vicryl (polyglactin 910; Ethicon, Bridgewater, NJ), and a 3 × 10-mm PassPort cannula (Arthrex) is placed to reconstitute a watertight seal around the medial arthroscopy portal.

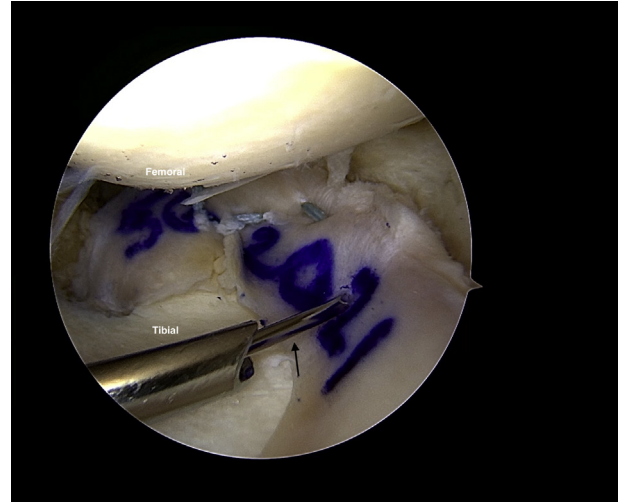
Next, the posterior horn is secured with an all-inside suture technique (FiberStitch; Arthrex). Four to five vertical and horizontal mattress sutures are deployed using a 12° up-curve implant device.

Finally, the midbody of the medial meniscus is secured by an inside-out technique with the ZoneNavigator system (Arthrex). A dual-loaded No. 2-0 FiberWire is passed through a curved cannula and the meniscus and is passed out through the adjacent capsule and skin (Fig 8). This is repeated with the second needle 5 mm superiorly to achieve a vertical mattress construct. Four to six vertical mattress sutures are placed to reduce the capsule to the meniscus. Small stab incisions are made to the skin to tie down each suture to the joint capsule.

### Procedure Completion and Rehabilitation Process

A final arthroscopic inspection is performed from both portals, and the integrity of the fixation is tested with a hook probe (Fig 9). The skin incisions are closed with a nonabsorbable suture, and local anesthesia is administered. A Jones dressing and a hinged knee brace are applied.

Postoperatively, the involved leg is restricted to non-weight bearing for the first month, allowed partial weight bearing for the second month, and allowed full weight bearing from the third month. In the first 2 weeks, the brace is locked in full extension. The

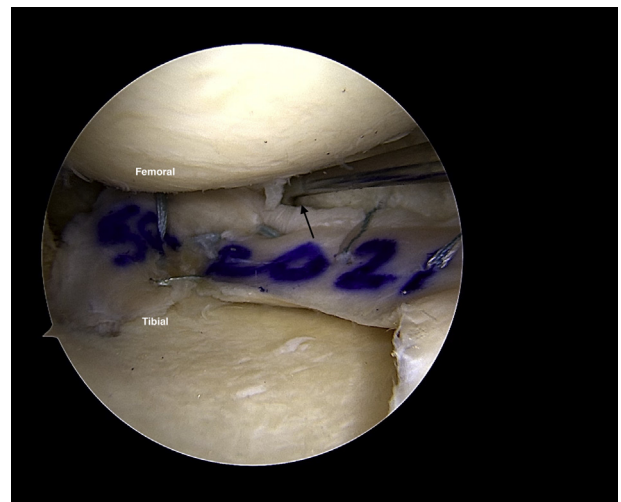


**Fig 8.** The midbody of the allograft is secured by an inside-out technique with the ZoneNavigator system. A dual-loaded No. 2-0 FiberWire is passed through a curved cannula (arrow). The mattress sutures used to secure the posterior horn are visible in the background.

patient is progressed to flexion up to 90° between the third and sixth weeks and is allowed range of motion as tolerated from the seventh week. The patient is placed on a proactive physiotherapy regimen, including weekly assessments and progressive range of motion, strength, and gait training. Hyperflexion should be avoided for at least 6 months, and strenuous activity should only resume after 9 months.

### Discussion

MAT has developed rapidly since it was first described, and a growing pool of evidence supports its



**Fig 9.** A hook probe should be used to test the integrity of the meniscocapsular fixation (arrow) before closure is performed.

**Table 1.** Advantages and Limitations

Advantages	
Increased integrity of fixation with 3 roots and bony plugs	
Good visualization and shorter operating duration with use of mini-arthrotomy as compared with all-arthroscopic techniques	
No requirement for posteromedial portal, avoiding iatrogenic saphenous neurovascular injuries	
Reproducible and simple surgical technique with gentle learning curve	
Limitations	
Extra bony tunnel may result in greater blood loss intraoperatively and pain postoperatively	
Higher cost of surgery	
Cosmetic concern of mini-arthrotomy vs arthroscopic scars	

efficacy, safety, and survivability.<sup>3-7,9</sup> Compared with the technique of MAT using 3 bone tunnels first described by Stone and Walgenbach<sup>10</sup> in 2003, several modifications have been made in the hope of improving patient outcomes.

We use bone plug fixation in securing the anterior and posterior roots of the allograft. As described, a reamer is used to prepare 10 × 8-mm bone plugs. In comparison, the original technique did not include the bone plugs and relied on fibrosis and healing between the meniscal soft tissue and the bone tunnel. A biomechanical study of cadaveric knees by Ambra et al.<sup>11</sup> in 2019 found that bone plug fixation was superior to soft-tissue fixation in restoring physiological load distribution in the knee joint, as measured by tibiofemoral contact area and mean contact pressure.<sup>12</sup> The difference may be due to a higher degree of meniscal extrusion with soft-tissue fixation as compared with bone plug fixation, as reported by Abat et al.<sup>13</sup> in 2012. However, we acknowledge that clinical differences between bone plug and soft-tissue fixation have not been proved, and Kim et al.<sup>14</sup> suggested that soft-tissue fixation can still be stable and secure enough to limit secondary graft extrusion.

The original article described an all-arthroscopic technique,<sup>10</sup> whereas a mini-arthrotomy is performed in our technique. This facilitates the introduction of the allograft and increases placement accuracy. Fixation of the anterior horn to the anterior capsule is also made easier because direct vision is possible. The anterior horn is difficult to access arthroscopically; hence, the mini-arthrotomy gives us greater confidence in the integrity of the fixation. These factors lead to shorter operating durations in comparison to fully arthroscopic techniques.

In comparison to techniques using 2 bone tunnels, our technique using a third tunnel leads to more secure fixation of the meniscus to the medial edge of the tibial plateau. We believe that this helps to minimize extrusion of the meniscus and prevents the meniscus from being pulled outward toward the capsule, leading to functional meniscal deficiency and

increased tibiofemoral contact pressure. In addition, a posteromedial portal is not required, avoiding iatrogenic soft-tissue and saphenous neurovascular injuries. The advantages and limitations are summarized in Table 1.

We have found the described technique to be simple, effective, and reproducible. This modified MAT with 3 bony tunnels has allowed better fixation and placement with greater meniscal conformity. Further clinical studies are currently being undertaken to examine the outcomes and patient satisfaction with our technique, as well as to compare the results against other established MAT techniques.

## References

1. Driban JB, Davis JE, Lu B, et al. Accelerated knee osteoarthritis is characterized by destabilizing meniscal tears and preradiographic structural disease burden. *Arthritis Rheumatol* 2019;71:1089-1100.
2. Fox AJS, Wanivenhaus F, Burge AJ, Warren RF, Rodeo SA. The human meniscus: A review of anatomy, function, injury, and advances in treatment. *Clin Anat* 2015;28:269-287.
3. Smith NA, Parkinson B, Hutchinson CE, Costa ML, Spalding T. Is meniscal allograft transplantation chondroprotective? A systematic review of radiological outcomes. *Knee Surg Sports Traumatol Arthrosc* 2016;24:2923-2935.
4. Doral MN, Bilge O, Huri G, Turhan E, Verdonk R. Modern treatment of meniscal tears. *EFORT Open Rev* 2018;3:260-269.
5. Smith NA, MacKay N, Costa M, Spalding T. Meniscal allograft transplantation in a symptomatic meniscal deficient knee: A systematic review. *Knee Surg Sports Traumatol Arthrosc* 2015;23:270-279.
6. DeFrance M, Ford E, McMillan S. Arthroscopic medial meniscal transplant using multiple fixation techniques. *Arthrosc Tech* 2019;8:1025-1029.
7. Seiter MN, Haber DB, Ruzbarsky JJ, Arner JW, Peebles AM, Provencher MT. Segmental meniscus allograft transplantation. *Arthrosc Tech* 2021;10:697-703.
8. Samitier G, Vinagre G, Alentorn-Geli E, Sava M, Cugat R. All-arthroscopic meniscal allograft transplantation technique with bone plugs and preloaded sutures. *Arthrosc Tech* 2020;9:1357-1362.
9. Bloch B, Asplin L, Smith N, Thompson P, Spalding T. Higher survivorship following meniscal allograft transplantation in less worn knees justifies earlier referral for symptomatic patients: Experience from 240 patients. *Knee Surg Sports Traumatol Arthrosc* 2019;27:1891-1899.
10. Stone KR, Walgenbach AW. Meniscal allografting: The three-tunnel technique. *Arthroscopy* 2003;19:426-430.
11. Ambra LF, Mestriner AB, Ackermann J, Phan AT, Farr J, Gomoll AH. Bone-plug versus soft tissue fixation of medial meniscal allograft transplants: A biomechanical study. *Am J Sports Med* 2019;47:2960-2965.

12. Jauregui JJ, Wu ZD, Meredith S, Griffith C, Packer JD, Henn RF. How should we secure our transplanted meniscus? A meta-analysis. *Am J Sports Med* 2018;46:2285-2290.
13. Abat F, Gelber PE, Erquicia JJ, Pelfort X, Gonzalez-Lucena G, Monllau JC. Suture-only fixation technique leads to a higher degree of extrusion than bony fixation in meniscal allograft transplantation. *Am J Sports Med* 2012;40:1591-1596.
14. Kim SH, Lipinski L, Pujol N. Meniscal allograft transplantation with soft-tissue fixation including the anterior intermeniscal ligament. *Arthrosc Tech* 2019;9: 137-142.