

# Successful Endoscopic Management of Non-Healing Perforated Duodenal Ulcer with Polyglycolic Acid Sheet and Fibrin Glue

Tsuyoshi Mishiro, MD, PhD<sup>1</sup>, Kotaro Shibagaki, MD, PhD<sup>1</sup>, Kayo Matsuda, MD<sup>1</sup>, Chika Fukuyama, MD<sup>1</sup>, Mayumi Okada, MD<sup>1</sup>, Hironobu Mikami, MD<sup>1</sup>, Daisuke Izumi, MD<sup>1</sup>, Noritsugu Yamashita, MD<sup>1</sup>, Eiko Okimoto, MD<sup>1</sup>, Naoki Fukuda, MD<sup>1</sup>, Masahito Aimi, MD, PhD<sup>1</sup>, Nobuhiko Fukuba, MD, PhD<sup>1</sup>, Naoki Oshima, MD, PhD<sup>1</sup>, Toshihiro Takanashi, MD<sup>2</sup>, Takeshi Matsubara, MD, PhD<sup>2</sup>, Norihisa Ishimura, MD, PhD<sup>1</sup>, Shunji Ishihara, MD, PhD<sup>1</sup>, and Yoshikazu Kinoshita, MD, PhD<sup>1</sup>

<sup>1</sup>Department of Gastroenterology and Hepatology, Shimane University School of Medicine, Izumo, Shimane, Japan

<sup>2</sup>Department of Digestive Surgery, Shimane University School of Medicine, Izumo, Shimane, Japan

## ABSTRACT

In recent years, treatment techniques in which polyglycolic acid sheets are applied to various situations with fibrin glue have exhibited great clinical potential, and previous studies have reported safety and efficacy. We describe closure of a non-healing perforated duodenal ulcer with the use of a polyglycolic acid sheet and fibrin glue in an elderly patient who was not a candidate for surgery.

## INTRODUCTION

A perforated peptic ulcer is a complication of peptic ulcer disease in which gas, gastric acid, and bile leak into the peritoneal cavity, with estimated incidence in 6–7 people per 100,000 of the general population.<sup>1,2</sup> Treatment for a perforated peptic ulcer primarily involves surgery, usually with suturing of the defect and placement of either a round ligament from the liver or an omental patch.<sup>1</sup> Traditionally, an open laparotomy method is used, although laparoscopic treatment has become available in recent decades.

## CASE REPORT

A 78-year-old woman with a history of lumbar compression fracture and diabetes mellitus went to another hospital for examination of acute-onset epigastric pain. An emergency computed tomography examination of the abdomen revealed the presence of extraluminal air and contrast material. The patient immediately underwent an exploratory laparotomy, which revealed a perforated ulcer approximately 20 mm in diameter in the upper duodenal angle of the duodenum. The ulcer was then oversewn and reinforced with a round ligament from the liver. The postoperative course was relatively stable until profuse bilious drainage from the foramen of Winslow developed on postoperative day (POD) 10. Treatment included strict bowel rest and total parenteral nutrition. Despite these steps, high-volume output persisted. A reoperation by open surgery was performed on POD 41 to reinforce the affected area with an omental patch. Although output via catheter was reduced, persistence of communication between the duodenal lumen and periduodenal space was demonstrated by upper gastrointestinal contrast radiography performed 6 weeks after the reoperation. The patient continued to suffer from malnutrition after the second operation, so a third surgical procedure was ruled out, and she was referred to our institution for endoscopic treatment on POD 80.

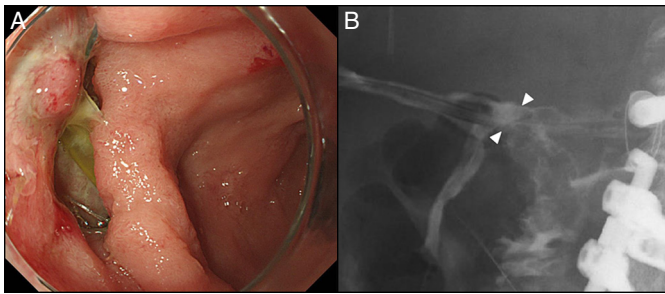
Esophagogastroduodenoscopy and x-ray showed an ulcer approximately 20 mm in diameter located in the upper duodenal angle of the duodenum (Figure 1). First, a guide-wire was passed through the perforated duodenal ulcer

ACG Case Rep J 2016;3(4):e197. doi:10.14309/crj.2016.170. Published online: December 21, 2016.

**Correspondence:** Tsuyoshi Mishiro, Department of Gastroenterology and Hepatology, Shimane University School of Medicine, 89-1, Enya-cho, Izumo, Shimane 693-8501, Japan (tmishiro@med.shimane-u.ac.jp).




Copyright: © 2016 Mishiro et al. This work is licensed under a Creative Commons Attribution-NonCommercial-NoDerivatives 4.0 International License. To view a copy of this license, visit <http://creativecommons.org/licenses/by-nc-nd/4.0>.



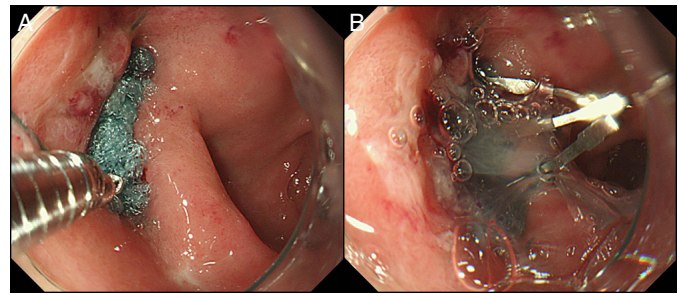
**Figure 1.** (A) Endoscopy showing perforated duodenal ulcer located in the upper duodenal angle of the duodenum. (B) X-ray showing leakage of contrast medium (amidotrizoic acid) into the abdominal cavity through the perforated duodenal ulcer (arrows).

to the side of the drain tube. A Neoveil polyglycolic acid (PGA) sheet (Gunze Co., Kyoto, Japan) was cut into small pieces, then rolled and placed into the rotatable clip devices, and transported to the ulcer through the channel of the scope (Figure 2). Each of these rolled PGA sheet pieces was then pushed out of the clip device and onto the perforated lesion (Figure 3). After the lesion was sufficiently covered with several PGA sheets, they were fixed with clips, after which the tip of the triple lumen tube was placed alongside the guide-wire to the outer layer of the PGA aggregates. Solution A (fibrinogen) (Beriplast P Combi-Set; CSL Behring Pharma, Tokyo, Japan) was applied using a single injection lumen of the cannula tube pushed to the PGA aggregates, followed by spraying solution B (thrombin) using another lumen of the cannula tube to fix the PGA aggregates to the ulcer (Figure 3). The procedure time for shielding with the PGA sheets plus fibrin glue and clip was 24 minutes.

Ten days after endoscopic closure of the perforated duodenal ulcer (POD 90), upper gastrointestinal contrast radiography and esophagogastroduodenoscopy showed that the PGA aggregates continued to cover the ulcer and maintain its closure (Figure 4). Drainage from the wound promptly ceased, oral intake was resumed on POD 92, and the patient was transferred to a nearby convalescent rehabilitation hospital on POD 142 without further complications.



**Figure 2.** (A) A PGA sheet used as an absorbable reinforcement material. (B) A PGA sheet cut into small pieces and rolled, ready for placement into a rotatable clip device with the use of an 18-gauge needle.

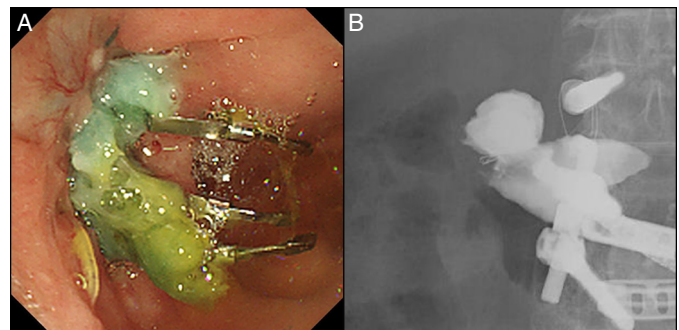


**Figure 3.** (A) A PGA sheet was cut into pieces and rolled into a rotatable clip device for delivery to the ulcer. (B) One side of each PGA piece was fixed to the edge of the ulcer using a clip. A fibrin glue mixture was placed onto each PGA sheet piece to complete adhesion.

## DISCUSSION

A PGA sheet and fibrin glue have firm adherence characteristics over the long term and become naturally absorbed within about 15 weeks, thus are applicable for various situations and have been shown to be safe.<sup>3-5</sup> However, according to the manufacturer's information, various complications may occur because of characteristics of the fibrin glue, especially anaphylactic reactions, while there is also potential risk for transmission of infectious agents. Although several reports of closure of fistulas using PGA sheets and fibrin glue have been presented, this is the first report in the literature regarding the use of these materials for closure of a perforated duodenal ulcer via an endoscopic approach.<sup>3,4</sup>

A PGA sheet can often pick up mucus during a procedure and then cling to biopsy forceps, making it difficult to release to the site of treatment. Use of the rotatable clips made exact placement of the PGA pieces easier in this case. Furthermore, the triple lumen endoscopic retrograde cholangiopancreatography cannula tube (Tandem XL; Boston Scientific, Tokyo, Japan) was used to mix solutions A and B from a Beriplast P Combi-Set, thus avoiding their coagulation within the tube and negating the need for 2 single-lumen tubes.



**Figure 4.** (A) Esophagogastroduodenoscopy showing the PGA sheet pieces attached to the ulcer 10 days after treatment. (B) Upper gastrointestinal series showing no leakage of contrast medium into the abdominal cavity.

The new over-the-scope clip system (Ovesco Endoscopy AG, Tübingen, Germany) was recently developed.<sup>6</sup> Although this system is promising for closure of luminal defects such as perforations and fistulas, a recent study demonstrated its limitations in 2 patients with severe fibrosis and scarring at the fistula site.<sup>7</sup> In addition, the system is more expensive than endoscopic tissue shielding with PGA sheets. Given that the present case also showed severe fibrosis around the perforated site, we chose to use PGA sheets rather than the over-the-scope clip system.

We intend to apply this technique in other patients with perforated ulcers or fistulas of the alimentary tract, and we will report our findings after an accumulation of cases. We consider that our method may be applicable for closure of lesions in difficult cases or in elderly patients for whom surgery is not a reasonable option.

## DISCLOSURES

Author contributions: T. Mishiro, K. Shibagaki, H. Mikami, and N. Yamashita contributed equally to the creation of this manuscript. T. Mishiro wrote the manuscript and is the article guarantor. The other members researched the study and edited the manuscript.

Financial disclosure: None to report.

Informed consent was obtained for this case report.

Received February 24, 2016; Accepted May 31, 2016

## REFERENCES

1. Søreide K, Thorsen K, Harrison EM, et al. Perforated peptic ulcer. *Lancet*. 2015;386:1288-98.
2. Møller MH, Larsson HJ, Rosenstock S, et al. Quality of care initiative in patients treated surgically for perforated peptic ulcer. *Br J Surg*. 2013;100:543-52.
3. Uemura K, Murakami Y, Hayashidani Y, et al. Combination of polyglycolic acid felt and fibrin glue for prevention of pancreatic fistula following pancreaticoduodenectomy. *Hepatogastroenterology*. 2009;56:1538-41.
4. Ueda K, Tanaka T, Hayashi M, et al. Mesh-based pneumostasis contributes to preserving gas exchange capacity and promoting rehabilitation after lung resection. *J Surg Res*. 2011;167:e71-5.
5. Doyama H, Tominaga K, Yoshida N, et al. Endoscopic tissue shielding with polyglycolic acid sheets, fibrin glue and clips to prevent delayed perforation after duodenal endoscopic resection. *Dig Endoscopy*. 2014;26:41-5.
6. Gubler C, Bauerfeind P. Endoscopic closure of iatrogenic gastrointestinal tract perforations with the over-the-scope clip. *Digestion*. 2012;85:302-7.
7. von Renteln D, Denzer UW, Schachschal G, et al. Endoscopic closure of GI fistulae by using an over-the-scope clip (with videos). *Gastrointest Endosc*. 2010;72:1289-96.