

Ectopic thyrotropin secreting pituitary adenoma concomitant with papillary thyroid carcinoma

Case report

Jing Yang, MD^a, Shu Liu, PhD^a, Zhe Yang, PhD^b, Yin Bing Shi, MD, PhD^{a,*}

Abstract

Rationale: Ectopic thyrotropin (TSH)-secreting pituitary adenomas are exceedingly rare. To date, there are only 6 cases reported. Here, we describe an even rarer ectopic TSH-secreting pituitary adenoma (TSH-oma) concomitant with papillary thyroid carcinoma.

Patient concerns: A 27-year-old female was admitted to the hospital in 2002 for neck enlargement and palpitation. Thyroid function test showed increased thyroid hormones and unrepressed TSH. Thyroid ultrasound examination displayed diffuse goiter. The patient was presumptively diagnosed as primary hyperthyroidism and treated with anti-thyroid drugs. Her condition was then improved, but the serum TSH was persistently unrepressed. Therefore, central hyperthyroidism due to TSH-oma or pituitary resistance to thyroid hormone (PRTH) was suspected. Pituitary magnetic resonance imaging (MRI) examination was deservedly performed to rule out TSH-oma, which turned out to be normal. In addition, T3 suppression test was negative. Thus, PRTH, as an uncommon cause of inappropriate TSH secretion, was regarded as the working diagnosis. Triiodothyroacetic acid, which was reported to be effective for PRTH, was then administered. But it did not work well. To control the symptoms completely and normalize the level of thyroid hormones, radioiodine therapy was carried out in 2007, followed by levothyroxine replacement therapy. Consequently, the symptoms were relieved, whereas serum TSH remained at high levels even with adequate levothyroxine. Unexpected, thyroid papillary carcinoma and a neoplasm in her nasopharynx were successively detected in 2012, which were then removed by surgery. Somewhat interestingly, the serum TSH declined to normal after the operation.

Diagnoses: The patient was ultimately diagnosed as an ectopic TSH-secreting pituitary adenoma concomitant with papillary thyroid carcinoma.

Interventions: Thyroidectomy and removal of the ectopic TSH-secreting pituitary adenoma by surgery were carried out, followed by levothyroxine replacement therapy.

Outcome: Three years after the surgery, the patient felt well with levothyroxine 125ug daily. Serum thyroid hormones and TSH kept in normal and no signs of neoplasm recurrence.

Lessons: Although extremely rare, ectopic TSH-secreting pituitary adenoma, as an uncommon cause of thyrotoxicosis, should be taken into consideration among those who have a longstanding hyperthyroidism with unsuppressed TSH.

Abbreviations: EPAs = ectopic pituitary adenomas, MRI = magnetic resonance imaging, PRTH = pituitary resistance to thyroid hormone, PTC = papillary thyroid carcinoma, RTH = resistance to thyroid hormone, RT-PCR = reverse transcription-polymerase chain reaction, TgAb = thyroglobulin antibody, TPOAb = thyroid peroxidase antibody, TSH = thyrotropin, TSH-oma = TSH-secreting pituitary adenoma.

Keywords: ectopic thyrotropin (TSH) secreting pituitary adenoma, hyperthyroidism, inappropriate TSH secretion

Editor: Eleonore Fröhlich.

Ethics committee of the First Affiliated Hospital of Xi'an Jiaotong University approved the study.

Informed consent of patient was given.

The authors report no conflicts of interest.

^a Department of Endocrinology, ^b Department of Pathology, the First Affiliated Hospital of Xi'an Jiaotong University, Xi'an, the People's Republic of China.

* Correspondence: Yin Bing Shi, Department of Endocrinology, the First Affiliated Hospital of Xi'an Jiaotong University, Xi'an 710061, the People's Republic of China (e-mail: shibingy@126.com).

Copyright © 2017 the Author(s). Published by Wolters Kluwer Health, Inc. This is an open access article distributed under the Creative Commons Attribution-NoDerivatives License 4.0, which allows for redistribution, commercial and non-commercial, as long as it is passed along unchanged and in whole, with credit to the author.

Medicine (2017) 96:50(e8912)

Received: 7 June 2017 / Received in final form: 30 October 2017 / Accepted: 7 November 2017

<http://dx.doi.org/10.1097/MD.0000000000008912>

1. Introduction

Thyrotropin (TSH)-secreting pituitary adenomas are an uncommon cause of thyrotoxicosis, accounting for about 0.5% to 3% of all pituitary adenomas.^[1,2] The first case is reported in 1960 and more than 450 cases have been described since then.^[2] It is one form of central hyperthyroidism due to inappropriate secretion of TSH, which is characterized by elevated levels of free thyroxine (FT4) and free triiodothyronine (FT3) with unrepressed TSH in contrast to primary hyperthyroidism, where TSH levels are usually decreased. Similarly, ectopic pituitary adenomas (EPAs) are extremely rare. Since its first description in 1909, there have been around 100 cases published.^[2] Therefore, ectopic TSH-secreting pituitary adenomas are even rarer. To our knowledge, only 6 cases have been reported to date.^[3-8] Moreover, none of them have thyroid neoplasm. Hence, this may be the first report of an ectopic TSH-secreting pituitary adenoma concomitant with papillary thyroid carcinoma (PTC) occurring after radioiodine therapy.

Table 1**Thyroid function assays in 2004–2005.**

| Normal | T3, ng/mL 0.8–2.2 | T4, μ g/dL 4.2–13.5 | FT3, pmol/L 2.91–9.08 | FT4, pmol/L 9.05–25.5 | TSH, μ IU/mL 0.4–3.1 |
|-------------------|----------------------|----------------------------|--------------------------|--------------------------|-----------------------------|
| June 16, 2004 | 4.6 \uparrow | 16.8 \uparrow | 10.0 \uparrow | 31.6 \uparrow | 3.7 \uparrow |
| July 26, 2004 | 4.5 \uparrow | 15.6 \uparrow | 11.1 \uparrow | 36.3 \uparrow | 3.1 |
| August 05, 2004 | 3.051 \uparrow | 18.149 \uparrow | 18.3 \uparrow | 36.77 \uparrow | 3.558 \uparrow |
| August 06, 2004 | 3.680 \uparrow | 17.239 \uparrow | 13.733 \uparrow | 33.084 \uparrow | 2.670 |
| August 10, 2004 | 3.770 \uparrow | 12.621 | 17.590 \uparrow | 21.230 | 2.770 |
| December 14, 2005 | \uparrow | \uparrow | — | — | 3.72 \uparrow |

FT3=free triiodothyronine, FT4=free thyroxine, T3=triiodothyronine, T4=thyroxine, TSH=thyrotropin.

2. Patient information

A 27-year-old female was admitted to the hospital in 2002 for neck enlargement and palpitation. Thyroid function tests showed elevated thyroid hormones and unrepressed TSH. Thyroid ultrasound examination revealed diffuse goiter. In spite of the inappropriate TSH secretion, the patient was presumptively diagnosed as primary hyperthyroidism. Then, methimazole and metoprolol were given. With these drugs, her symptoms gradually improved but not completely. In 2004, she turned to our hospital for further treatment. At that time, her thyroid function test displayed increased FT4 (31.6, normal 9.05–25.5 pmol/L), FT3 (10.0, normal 2.91–9.08 pmol/L), T4 (16.8, normal 4.2–13.5 μ g/dL), T3 (4.6, normal 0.8–2.2 ng/mL), and TSH (3.7, normal 0.4–3.1 μ IU/mL) with negative thyroid peroxidase antibody (TPOAb) and thyroglobulin antibody (TgAb). The remaining anterior pituitary hormones were normal. Therefore, central hyperthyroidism due to TSH-secreting pituitary adenoma (TSH-oma) or pituitary resistance to thyroid hormone (PRTH) was alternatively suspected. Pituitary MRI was deservedly performed to rule out TSH-oma and it turned out to be normal. Thus, it was more likely to be PRTH. Anti-thyroid drugs were then proceeded to control the symptoms. During the following 2 years, the patient suffered from palpitation, nervousness, and diarrhea time to time. No other symptoms or signs such as excessive sweating, weight loss, pretibial myxedema, and oculopathy were found. Thyroid function test indicated elevated thyroid hormones and unrepressed TSH persistently (Table 1). In the meantime, T3 suppression test was performed and it was negative. A repeated pituitary MRI was still normal.

Hence, PRTH was regarded as the working diagnosis in the following 2 years' follow-up. Triiodothyroacetic acid (reported to be effective for RTH) was then administrated for 5 months, but

it did not work well. Therefore, anti-thyroid drugs were prescribed again, while the symptoms and the thyroid function can hardly be improved synchronously. In order to control the refractory symptoms completely and normalize the serum thyroid hormones, radioiodine therapy (12 mCi) was carried out in 2007 followed by levothyroxine replacement therapy. The symptoms of thyrotoxicosis were then relieved completely, while the serum TSH had been maintained at a higher level (fluctuating from 16.2 to 90.8 μ IU/mL, mean 47.11 μ IU/mL) in the following 5 years even with adequate levothyroxine. Unexpectedly, a nodule in the thyroid was found during regular check in 2012 and pathologically confirmed to be thyroid papillary carcinoma by the fine needle aspiration. So, she was admitted to the hospital or thyroidectomy.

On admission, a neoplasm in the patient's nasopharynx was found beyond expectation. Inquired for detailed medical history, she complained of mild nasal obstruction for approximately 10 years. A nonpedunculated mass was then found in her nasopharynx with the electronic nasopharyngolaryngoscope (Fig. 1). An excisional biopsy was performed immediately and it was pathologically interpreted to be granulomatous inflammation. Accordingly, the patient underwent surgery to remove the whole thyroid as well as the nasopharynx neoplasm. The nodule in thyroid was verified to be papillary carcinoma, while the neoplasm in the nasopharynx turned out to be neuroendocrine carcinoma (positive immunohistochemical reactions with cytokeratin, neuron-specific enolase, chromogranin A, synaptophysin, etc.) by postoperative pathological examination. Thereby, she received a secondendoscopic sinus surgery involving the invasive bone, followed by chemotherapy (etoposide 100 mg iv. drip d1-5, cis-platinum 40 mg iv d1-3, 6 cycles). Somewhat interestingly, the serum TSH declined to normal after the surgery with levothyroxine 100 to 125 μ g daily (Table 2). When last seen in March 2015, 3 years postoperatively, the patient felt well with levothyroxine 125 μ g daily. And serum thyroid hormones and TSH kept in normal.

Anatomizing the whole clinical course of this special patient, we wondered why the persistent unrepressed serum TSH declined to normal after the surgery. Nasopharyngeal tumor was most likely to be the source of inappropriately secreted TSH. Then, the following tests were carried out to confirm the speculation.

The mRNA was extracted from the nasopharynx neoplasm and RT-PCR was conducted to amplify human β -TSH gene (351 kb) using specific primer (Forward primer: 5'-GCTCTCTTTCTGATG-TCC-3'; Reverse primer: 5'-GGCTTCATGTATGCAGTC-3'). An expected electrophoretic band was displayed with agarose gel electrophoresis (Fig. 2). The PCR product was sequenced and verified to match the human β -TSH gene on GenBank. Simultaneously, the neoplasm was demonstrated to have positive

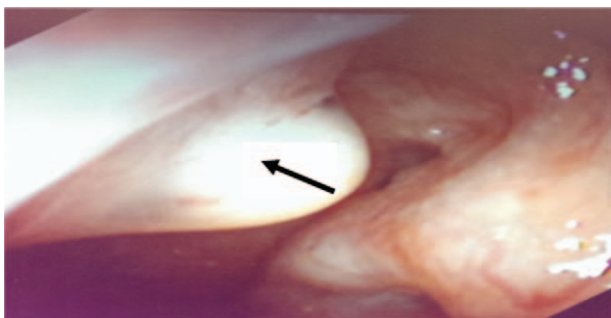


Figure 1. Image of nasopharynx neoplasm under the electronic nasopharyngolaryngoscope.

Table 2
Postoperative thyroid function assays in 2013–2014.

| Normal | T3, ng/mL 0.8–2.2 | T4, μg/dL 4.2–13.5 | FT3, pmol/L 2.91–9.08 | FT4, pmol/L 9.05–25.5 | TSH, μIU/mL 0.25–5 |
|-------------------|----------------------|-----------------------|--------------------------|--------------------------|-----------------------|
| January 14, 2013 | 0.738 | 7.44 | — | — | 5.34↑ |
| February 05, 2013 | 0.933 | 10.5 | 2.94 | 16.8 | 5.09↑ |
| March 01, 2013 | 1.09 | 13.2 | — | — | 4.98 |
| March 04, 2013 | 0.965 | 10.4 | — | — | 2.25 |
| March 25, 2013 | 0.872 | 10.7 | — | — | 2.39 |
| April 12, 2013 | 1.37 | 10.0 | — | — | 1.59 |
| August 02, 2013 | 1.20 | 12.7 | — | — | 0.970 |
| February 21, 2014 | 1.06 | 11.5 | — | — | 2.29 |
| August 19, 2014 | 0.859 | 11.9 | — | — | 0.510 |

FT3=free triiodothyronine, FT4=free thyroxine, T3=triiodothyronine, T4=thyroxine, TSH=thyrotropin.

immunohistochemical reactions to anti-TSH monoclonal antibodies (Fig. 3). Thus, it was demonstrated that the nasopharynx neoplasm was the source of pathogenic TSH. The final diagnosis should be ectopic TSH tumor.

3. Discussion

EPAs, originally described in 1909, are rare. It is generally believed to be derived from the embryonic residues of pituitary, in the vomerosphenoidal junction, along the pathway taken by Rathke pouch. The common sites include sphenoid sinus, cavernous sinus, clivus, nasopharynx, etc. The clinical manifestation associated with these ectopic tumors may be related to space occupying effect (i.e., visual field defects, headache, nasal obstruction, chronic sinusitis, cerebrospinal fluid rhinorrhea, etc.) and /or hormone hypersecretion (i.e., Cushing syndrome, acromegaly, thyrotoxicosis, etc.). The differential diagnosis encompasses neuroendocrine tumors, specific malignant epithelial neoplasms, metastatic

neoplasm, etc.^[3] The positive immunoreactivity with diverse neuroendocrine makers such as chromogranin, synaptophysin, and neuron-specific enolase can hardly differentiate pituitary adenomas from neuroendocrine tumors. Comparatively, immunoreactivity with pituitary hormones has a distinct diagnostic value. In addition to histopathologic confirmation, diagnostic criteria also include radiographic evidence of a normal pituitary.^[3] Our case meets both of the criterions here. With the inappropriate TSH secretion, which returns to normal after resection of the nasopharynx neoplasm, the final diagnosis is an ectopic TSH-secreting pituitary adenoma (TSH-oma).

Ectopic TSH-omas are exceedingly rare. To our knowledge, only 6 cases have been reported by now. Apparently, our patient has a lot in common with the others, such as longstanding hyperthyroidism with diffuse goiter, inappropriate TSH secretion with normal pituitary, unsatisfactory effects of anti-thyroid drugs, long-term nasal obstruction, nasopharynx neoplasm, etc. Nevertheless, among all these 7 cases, our patient is the only one that has received ¹³¹I treatment and subsequently suffered from papillary carcinoma. The cause of the thyroid carcinoma is unclear. But we have some conjectures.

At first, we suspect it may be associated with the ectopic TSH-oma. As we know, TSH can promote the thyroid to produce thyroid hormones as well as induce thyroid cell proliferation. Due to long-term stimulation of high-level serum TSH and the different responses to TSH, the scattered thyroid cells may generate local nodule. Afterwards, malignant transformation can occur. However, it is generally believed that TSH from the ectopic tumor has lower or no activity so that clinical manifestations are usually relatively mild. Hereupon, we speculate that the TSH

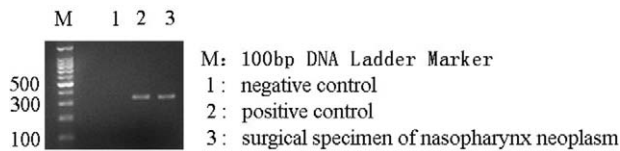


Figure 2. PCR of β -TSH gene in surgical specimen of nasopharynx neoplasm. (Negative control is the sample absent of β -TSH cDNA. Positive control is surgical specimen of a pathologically confirmed TSH-secreting pituitary adenoma.)

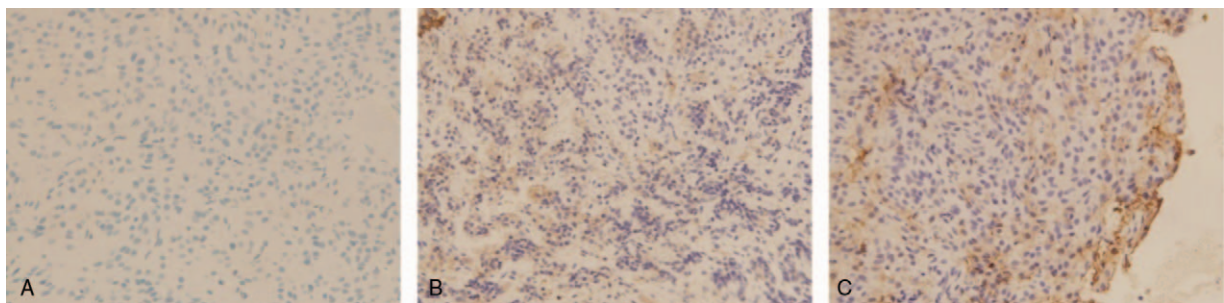


Figure 3. Immunohistochemical assays of β -TSH in tumor tissue. (A) Negative control (absent of anti-TSH monoclonal antibodies): β -TSH staining is negative; (B) positive control (surgical specimen of a pathologically confirmed TSH-secreting pituitary adenoma): β -TSH staining is positive (brown); (C) surgical specimen of the nasopharynx neoplasm in our patient: β -TSH staining is positive (brown).

from ectopic TSH-oma may have a special structure that is more apt to facilitate thyroid cell proliferation rather than thyroid hormone production. Long-term high-level serum TSH results in thyroid cell hyperplasia and malignant transformation. This may be the most possible cause of PTC in our case.

Second, radioiodine maybe involved in the oncogenesis. The patient has attained radioiodine therapy (12 mCi) 5 years before the PTC is found. It is reported that some patients suffer from thyroid carcinoma after radioiodine therapy for hyperthyroidism.^[9] Also, some studies show that radioiodine may increase relative risk for thyroid cancer.^[10] Even that such dosage radioiodine is not likely to be cancerogenic, for this special patient, it may involve in the process with TSH synergistically. Therefore, radioiodine maybe one of the pathogenic factors in our patient, although there is no substantiating evidence indicating it is the main cause.

Finally, it is more likely to be the result of many complex factors. Genetic susceptibility to cancer forms the basis of thyroid carcinoma, while combined effects of TSH and radioiodine facilitate its oncogenesis.

4. Conclusion

As exceedingly rare entities, most of the EPAs are found serendipitously. It is likely that many similar patients are misdiagnosed and lack precise treatment. Therefore, ectopic TSH-secreting pituitary adenoma, as an uncommon cause of thyrotoxicosis, should be taken into consideration during the differential diagnosis of hyperthyroidism especially among those who have a longstanding central hyperthyroidism but do not meet the criterions of eutopic TSH-omas or resistance to thyroid

hormone. This report may be the first case of an ectopic TSH-secreting pituitary adenoma concomitant with PTC occurring after radioiodine therapy. It indeed contributes to the recognition of this uncommon entity and provides an important clue for differential diagnosis of thyrotoxicosis.

References

- [1] Onnestam L, Berinder K, Burman P, et al. National incidence and prevalence of TSH-secreting pituitary adenomas in Sweden. *J Clin Endocrinol Metab* 2013;98:626–35.
- [2] Beck-Peccoz P, Lania A, Beckers A, et al. 2013 European thyroid association guidelines for the diagnosis and treatment of thyrotropin-secreting pituitary tumors. *Eur Thyroid J* 2013;2:76–82.
- [3] Cooper DS, Wenig BM. Hyperthyroidism caused by an ectopic TSH-secreting pituitary tumor. *Thyroid* 1996;6:337–43.
- [4] Pasquini E, Faustini-Fustini M, Sciarretta V, et al. Ectopic TSH-secreting pituitary adenoma of the vomerosphenoidal junction. *Eur J Endocrinol* 2003;148:253–7.
- [5] Collie RB, Collie MJ. Extracranial thyroid-stimulating hormone-secreting ectopic pituitary adenoma of the nasopharynx. *Otolaryngol Head Neck Surg* 2005;133:453–4.
- [6] Tong A, Xia W, Qi F, et al. Hyperthyroidism caused by an ectopic thyrotropin-secreting tumor of the nasopharynx: a case report and review of the literature. *Thyroid* 2013;23:1172–7.
- [7] Song M, Wang H, Song L, et al. Ectopic TSH-secreting pituitary tumor: a case report and review of prior cases. *BMC Cancer* 2014;14:544.
- [8] Nishiike S, Tatsumi KI, Shikina T, et al. Thyroid-stimulating hormone-secreting ectopic pituitary adenoma of the nasopharynx. *Auris Nasus Larynx* 2014;41:586–8.
- [9] Spencer RP, Chapman CN, Rao H. Thyroid carcinoma after radioiodide therapy for hyperthyroidism. Analysis based on age, latency, and administered dose of I-131. *Clin Nucl Med* 1983;8:216–9.
- [10] Pauwels EK, Smit JW, Slats A, et al. Health effects of therapeutic use of ¹³¹I in hyperthyroidism. *Q J Nucl Med* 2000;44:333–9.