


Cutaneous myiasis in cats and dogs: Cases, predisposing conditions and risk factors

Marco Pezzi¹  | Chiara Scapoli¹ | Milvia Chicca¹ | Marilena Leis¹ |
 Maria Gabriella Marchetti¹ | Carlo Nicola Francesco Del Zingaro² | Chiara Beatrice Vicentini¹ |
 Elisabetta Mamolini¹ | Annunziata Giangaspero³ | Teresa Bonacci⁴

¹Department of Life Sciences and Biotechnology, University of Ferrara, Ferrara, Italy

²Veterinary Clinic, Alfonsine, Ravenna, Italy

³Department of the Sciences of Agriculture, Food and Environment, University of Foggia, Foggia, Italy

⁴Department of Biology, Ecology and Earth Science, University of Calabria, Arcavacata di Rende, Cosenza, Italy

Correspondence

Marco Pezzi, Department of Life Sciences and Biotechnology, University of Ferrara, Via L. Borsari 46, 44121 Ferrara, Italy.
 Email: marco.pezzi@unife.it

Funding information

Funding for this study was provided by "Consorzio Futuro in Ricerca" (Ferrara, Italy), code n. COFELEIS42/18, assigned to Marilena Leis.

Abstract

Two cases of cutaneous myiasis diagnosed in 2018 in Emilia-Romagna region (northern Italy) were reported. The first one, described in a domestic cat *Felis silvestris catus* L. (Carnivora: Felidae) and caused by *Calliphora vicina* Robineau-Desvoidy (Diptera: Calliphoridae), was the first one of this type ever reported in Italy in cats. The second one was described in a domestic dog *Canis lupus familiaris* L. (Carnivora: Canidae) and caused by *Lucilia sericata* (Meigen) (Diptera: Calliphoridae) and was unusual because it occurred in absence of lesions. An extensive literature search on cutaneous myiasis in these two domestic animal species was performed in order to draw attention to predisposing conditions and risk factors.

KEYWORDS

Calliphora vicina, cutaneous myiasis, *Lucilia sericata*, pets, predisposing conditions, risk factors

1 | INTRODUCTION

A widely accepted definition of myiasis is the infestation of vertebrates by dipteran larvae that feed on living or dead host tissues (Zumpt, 1965). Myiasis is classified according to the parasite–host relationship (accidental, facultative or obligatory) and host anatomical localization (auricular, cutaneous, gastrointestinal, ophthalmic, oral and urogenital) (Hall & Smith, 1993; Scholl et al., 2009; Singh & Singh, 2015).

Livestock and wildlife are at greater risk of attack by myiasis-causing flies than pets; however, the latter group of animal species, such as owned cats and dogs, can also be exposed.

Here, we describe two cases of cutaneous myiasis in privately owned pets (a cat and a dog). Such cases of myiasis encourage more

studies in this field and an updating of the number of predisposing conditions and risk factors for the onset of myiasis in pet animals. In this case report, an extensive survey of worldwide literature reporting cases of cutaneous myiasis in these two animal species was performed.

2 | CASE HISTORY

Two cases of myiasis were reported in a veterinary clinic near Ravenna (Region Emilia-Romagna, northern Italy), in a domestic cat and a domestic dog (hereafter, respectively, indicated as cat and dog).

Case 1. A 7-year-old female cat, *Felis silvestris catus* L. (Carnivora: Felidae), privately owned in a country village near Ravenna (northern

Annunziata Giangaspero and Teresa Bonacci contributed equally to this work.

This is an open access article under the terms of the Creative Commons Attribution-NonCommercial-NoDerivs License, which permits use and distribution in any medium, provided the original work is properly cited, the use is non-commercial and no modifications or adaptations are made.

© 2020 The Authors *Veterinary Medicine and Science* Published by John Wiley & Sons Ltd

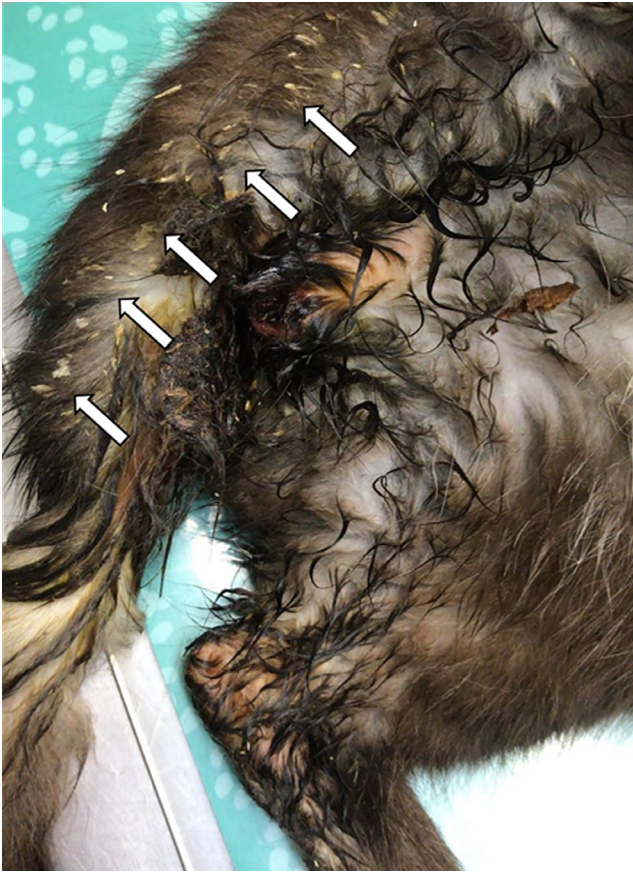

FIGURE 1 Clinical aspects of a cutaneous myiasis in a domestic cat by *Calliphora vicina* (Case 1): lower abdomen and inner side of thighs showing dipteran larvae (arrows) on the fur

Italy), was admitted at a veterinary clinic on 11 April 2018 after she had been run over by a car, suffering a debilitating pelvis fracture followed by immobility. In the lower abdomen and inner side of thighs, the presence of larvae in the fur (Figure 1) and over decubitus ulcers was noticed. A total of 26 live dipteran larvae, 5.98 ± 0.67 mm long, were collected in the fur and over the decubitus ulcers. All other larvae were mechanically removed, the ulcers were washed with hydrogen peroxide and the anti-inflammatory drug meloxicam was prescribed.

Case 2. A 12-year-old male dog, *Canis lupus familiaris* L. (Carnivora: Canidae), privately owned in a country village near Ravenna (northern Italy), became immobile secondary to a spinal disc herniation and was brought to a veterinary clinic on 26 August 2018. The veterinarian detected several larvae in the inner side of the right thigh (Figure 2a–c) where no skin lesions were visible. The veterinarian collected a sample of 38 live dipteran larvae, 8.01 ± 0.75 mm long, mechanically removed all the other ones and washed the skin with hydrogen peroxide.

2.1 | Handling of dipteran larvae

In both cases, the veterinarian took photographs and placed the live larvae in plastic test tubes sealed with a clean cotton cloth. The larvae were brought to the laboratories of the Department of Life Sciences and Biotechnology, University of Ferrara (Ferrara, Italy), for

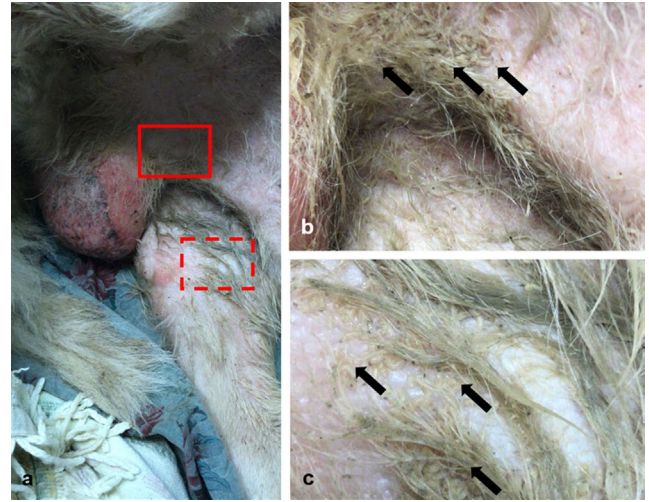


FIGURE 2 Clinical aspects of a cutaneous myiasis in a domestic dog by *Lucilia sericata* (Case 2). (a) Lower abdomen region and inner side of the right thigh with several dipteran larvae. The rectangles outline two heavily infested regions. (b) Detail of Figure 2a (continuous line) showing dipteran larvae (arrows) on the abdomen skin. (c) Detail of Figure 2a (dashed line) showing dipteran larvae (arrows) on the skin of inner thigh

morphological investigations. After a quick immersion in hot water (about 90°C), five larvae were fixed in 80% ethanol and stored in the same liquid at 4°C. The remaining larvae were reared to adults in polyethylene boxes, fed with 90g of ground beef and kept at $25 \pm 2^\circ\text{C}$, 50% relative humidity and 16/8 (L/D) photoperiod. When adults emerged from puparia, they were immediately exposed to CO_2 to induce torpor, individually transferred to a test tube, painlessly sacrificed by exposure to -20°C and stored at the same temperature. Species identification, based on morphology of males examined under a Nikon SMZ 800 stereomicroscope (Nikon Instruments Europe, Amsterdam, The Netherlands), was carried out according to a specific identification key (Szpila, 2012).

2.2 | Literature search

The search was first performed on PubMed and Scopus indexed literature, and then extended until October 2019 to other web engines with no time and language limits. Publications were obtained via Web and/or interlibrary services.

3 | RESULTS AND DISCUSSION

3.1 | Case discussion

Case 1. Based on morphological investigations according to identification keys, the agent of the myiasis was identified as *Calliphora vicina* Robineau-Desvoidy (Diptera: Calliphoridae).

Worldwide, only one other case of cutaneous myiasis in cats by *C. vicina* has been reported (Rodríguez & Perez, 1996). This is the

first case of cutaneous myiasis by *C. vicina* to be described in a cat in Italy. Only two other cases of myiasis by this species have been reported in Italy in cats, but they were, respectively, an ophthalmic and an auricular one (Pezzi et al., 2017).

Case 2. Based on morphological investigations according to identification keys, the agent of the myiasis was identified as *Lucilia sericata* (Meigen) (Diptera: Calliphoridae).

Cases of myiasis by *L. sericata* in dogs have been previously reported in Italy (Principato & Cioffi, 1996), Israel (Rauchbach & Hadani, 1972), Austria (Hinaidy & Frey, 1984; Supperer & Hinaidy, 1975), Germany (Ribbeck et al., 1979), Argentina (Vignau & Arias, 1997), Turkey (Dik et al., 2012; Eren et al., 2010; Işık & Dik, 2015; Sevgili et al., 2009), Korea (Choe et al., 2016) and Iran (Moshaverinia & Kazemi Mehrjerdi, 2016). In some myiasis cases in dogs, *L. sericata* was found in association with other Diptera, among which *Muscina stabulans* (Fallén; Muscidae) and *Sarcophaga portschinskyi* (Rohdendorf; Sarcophagidae) in Italy (Bonacci & Brandmayr, 2016), *Chrysomya albiceps* Wiedemann (Calliphoridae) in Israel (Schnur et al., 2009) and *Wohlfahrtia magnifica* (Schiner; Sarcophagidae) in Turkey (Gökpinar & Karsli, 2018).

3.2 | Cutaneous myiasis: predisposing conditions and risk factors

In the literature, the term “cutaneous myiasis” was already common in the early XX century to indicate infestations by dipteran larvae of humans and animals involving skin (Patton, 1920). In 1965, Zumpt proposed a classification of myiasis introducing the terms “dermal” and “subdermal” synonymous with “cutaneous myiasis”, describing dipteran larvae causing burrows (creeping obligatory myiasis) or boils under the skin (furuncular obligatory myiasis) or invading pre-existing wounds or actively accessing the tissues (obligatory or facultative myiasis). Creeping obligatory myiasis is usually caused by *Gasterophilus* spp. (Diptera: Oestridae), whereas furuncular obligatory myiasis is caused by *Dermatobia hominis* Linnaeus Jr. in Pallas (Diptera: Oestridae) or by *Cordylobia* spp. (Diptera: Calliphoridae) and *Cuterebra* spp. (Diptera: Oestridae). Some genera of Diptera involved in myiasis invading pre-existing wounds or occurring on unwounded skin are *Calliphora* spp., *Chrysomya* spp., *Cochliomyia* spp. and *Lucilia* spp. (Diptera: Calliphoridae), and *Sarcophaga* spp. and *Wohlfahrtia* spp. (Diptera: Sarcophagidae) (Zumpt, 1965).

Thus far, no cases of creeping myiasis have been reported in cats and dogs. Concerning furuncular myiasis, the main risk factor for cats and dogs is prowling, for example, for hunting purposes (Cramer-Ribeiro et al., 2003; Johnson et al., 2016; Rutland et al., 2017) or, for privately owned subjects, to be kept outdoor in infested areas (Johnson et al., 2016; Rutland et al., 2017). A weakened or ill individual is more likely to be attacked, although healthy animals are also at risk (Verocai et al., 2010). Young animals appear more frequently attacked (Ogo et al., 2005, 2009), possibly because of their softer skin or need for care. Removal of larvae *in toto* may be performed using several methods that include application of toxic drugs, localized

hypoxia, mechanical or surgical removal or manual compression (Verocai et al., 2010).

Traumatic myiasis is a type of cutaneous myiasis occurring when larvae feed and develop in traumatic lesions (Hall & Farkas, 2000). The open wound is the main predisposing condition but the key risk factor is improper wound treatment. An untreated wound attracts the dipteran females which lay eggs or larvae. Table 1 summarizes the cases of cutaneous traumatic myiasis reported in literature in domestic cats and dogs and associated predisposing conditions (when reported) and species causing the myiasis. The situations described in the literature leading to improper treatment of wounds and/or neglecting conditions may be the following:

- feral behaviour inducing fear of humans, thus, favouring extensive attacks by agents of myiasis which may be fatal. This condition has been reported in stray cats (de Souza et al., 2010) and in cat colonies where it is difficult to ensure animal welfare (Mendes-de-Almeida et al., 2007);
- privately owned animals with disabilities caused by traumatic events and unable to return home to be treated by their owners: this has been reported in cats found heavily infested some days after a car accident or dog bites (Pezzi et al., 2015, 2017).
- animals whose owners were unable or unwilling to adequately care for their pet and were also unaware of the risks to develop myiasis in untreated wounds (Cansi & Demo, 2011; Farkas et al., 2009; de Souza et al., 2010).

According to literature and to the reported cases, cutaneous myiasis can be also divided into two types: myiasis involving skin lesions and myiasis not involving skin lesions. In both situations, again, neglected health conditions are frequently a risk factor. In cats and dogs, the common predisposing conditions for myiasis involving skin lesions not caused by trauma are immobility, ectoparasite infestations, skin diseases and inadequately treated surgical outcomes. Table 2 summarizes the cases of cutaneous myiasis involving skin lesions not caused by trauma and reported in the literature in domestic cats and dogs, together with predisposing conditions (when reported) and species causing the myiasis. Neglected health conditions play an essential role by causing cutaneous ulcers, as reported in cats where the fur is soiled by urine and faeces (Gatt & Zammit, 2008). Other cases have been reported in three obese neutered cats, neglected because of excessive and inappropriate food and lack of hygiene. Obesity prevented the cats from performing self-cleaning, leading to painful, putrid-smelling ulcers on the thighs and tails (Rodríguez & Perez, 1996). Other cutaneous myiasis involving skin lesions not caused by trauma have been reported in umbilical regions of neglected newborn cats and dogs (Pekmezci et al., 2014; Rawlins et al., 1983).

Immobility due to debilitating fractures or to old age may cause decubitus ulcers which, when untreated, may attract flies and cause myiasis, as reported in the cat in this study (Case 1) and in a previous one (Pezzi et al., 2017). In dogs, untreated infestations due to ectoparasites (ticks) may induce an annoying itch, followed by scratching,

TABLE 1 Cases of cutaneous traumatic myiasis reported in the literature in domestic cats and dogs regarding predisposing conditions and fly species associated with the myiasis (*Ch. bezziana*, *Chrysomya bezziana*; *Co. hominivorax*, *Cochliomyia hominivorax*; *L. sericata*, *Lucilia sericata*; *M. domestica*, *Musca domestica*; *S. argyrostoma*, *Sarcophaga argyrostoma*; *S. haemorrhoidalis*, *Sarcophaga haemorrhoidalis*; *S. tibialis*, *Sarcophaga tibialis*; *W. magnifica*, *Wohlfahrtia magnifica*)

Predisposing conditions	Cat		Dog	
	Species	References	Species	References
Fight	<i>Ch. bezziana</i>	(Han et al., 2018)	<i>Co. hominivorax</i>	(Wendell Snow et al., 1978)
	<i>Co. hominivorax</i>	(Mendes-de-Almeida et al., 2007)	<i>Ch. bezziana</i>	(Chemonges-Nielsen, 2003; Han et al., 2018; McNae & Lewis, 2004)
			<i>L. sericata</i>	(Moshaverinia & Kazemi Mehrjerdi, 2006)
			<i>W. magnifica</i>	(Farkas et al., 2009; Orfanou et al., 2011)
		NA	(Schnur et al., 2009; Singh & Singh, 2007)	
Road accident	<i>L. sericata</i>	(Pezzi et al., 2017)	<i>Ch. bezziana</i>	(Han et al., 2018)
	<i>S. argyrostoma</i>	(Pezzi et al., 2017)	<i>W. magnifica</i>	(Orfanou et al., 2011)
			<i>M. domestica</i>	(Dik et al., 2018)
Bite	<i>L. sericata</i> and <i>S. tibialis</i>	(Pezzi et al., 2015)	<i>L. sericata</i>	(Hinaidy & Frey, 1984)
			<i>S. haemorrhoidalis</i>	(Principato et al., 1994)
			<i>W. magnifica</i>	(Carnevali et al., 2019)
Vampire bat bite	<i>Co. hominivorax</i>	(Rawlins et al., 1983)	–	–
Fall trauma	<i>L. sericata</i>	(Gatt & Zammit, 2008)	–	–
Cactus and bush thorn	–	–	<i>Co. hominivorax</i>	(Wendell Snow et al., 1978)
Barbed wire	–	–	<i>W. magnifica</i>	(Bonacci et al., 2017)

Note: NA, data not available (cases of myiasis reported as caused by different species but without connection between the species and the predisposing conditions).

TABLE 2 Cases of cutaneous myiasis involving lesions not caused by trauma, reported in the literature in domestic cats and dogs regarding predisposing conditions and fly species associated with the myiasis (*Ca. vicina*, *Calliphora vicina*; *Ch. bezziana*, *Chrysomya bezziana*; *Co. hominivorax*, *Cochliomyia hominivorax*; *L. sericata*, *Lucilia sericata*; *P. regina*, *Phormia regina*; *W. magnifica*, *Wohlfahrtia magnifica*)

Predisposing conditions	Cat		Dog	
	Species	References	Species	References
Skin disease	<i>Ch. bezziana</i>	(Han et al., 2018)	<i>Ch. bezziana</i>	(Han et al., 2018; McNae & Lewis, 2004)
			<i>L. sericata</i>	(Hinaidy & Frey, 1984)
			<i>W. magnifica</i>	(Bonacci et al., 2013; Moshaverinia & Kazemi Mehrjerdi, 2016)
Ectoparasite infestation	–	–	<i>Co. hominivorax</i>	(Rawlins, 1985; Rawlins et al., 1983; Wendell Snow et al., 1978)
			NA	(Schnur et al., 2009)
			US	(Choi et al., 2015)
Inadequately treated surgery	<i>Ch. bezziana</i>	(Han et al., 2018)	<i>Co. hominivorax</i>	(Rawlins, 1985; Rawlins et al., 1983)
	<i>Co. hominivorax</i>	(Rawlins, 1985; de Souza et al., 2010)	<i>L. sericata</i>	(Moshaverinia & Kazemi Mehrjerdi, 2016)
			<i>W. magnifica</i>	(Fois et al., 2012)
Untreated wounds	<i>Ca. vicina</i>	(Rodríguez & Pérez, 1996)	<i>Co. hominivorax</i>	(Rawlins et al., 1983)
	<i>Co. hominivorax</i>	(Rawlins et al., 1983)		
	<i>L. sericata</i>	(Gatt & Zammit, 2008; Choe et al., 2016)		
	<i>P. regina</i>	(Pekmezci et al., 2014)		
Immobility	<i>L. sericata</i>	(Pezzi et al., 2017)	<i>L. sericata</i>	(Case 2, present report)
	<i>C. vicina</i>	(Case 1, present report)		

Note: NA, data not available (cases of myiasis reported as caused by different species but without connection between the species and the predisposing conditions); US, unidentified species.

excoriations and lesions, which may attract the dipteran female (Choi et al., 2015; Rawlins, 1985; Rawlins et al., 1983; Schnur et al., 2009; Wendell Snow et al., 1978). Untreated or neglected skin diseases have

also been reported as predisposing conditions, for example, in dogs with acute skin inflammation (Hinaidy & Frey, 1984), bursted epidermal cysts (Bonacci et al., 2013), bacterial, fungal and atopic dermatitis,

demodiosis and tumours (Han et al., 2018; Moshaverinia & Kazemi Mehrjerdi, 2016). Sporotrichosis has also been reported as a predisposing condition for myiasis in cats (Han et al., 2018). Other predisposing conditions involve inadequately treated surgical incisions in cats (Han et al., 2018; Rawlins, 1985; de Souza et al., 2010) and in dogs (Fois et al., 2012; Moshaverinia & Kazemi Mehrjerdi, 2016; Rawlins, 1985; Rawlins et al., 1983). There are also reports of myiasis in dogs due to unusual predisposing conditions such as abrasions due to tight collars (Tannahill et al., 1980), branding scars (Rawlins, 1985) and pododermatitis (Han et al., 2018; McNae & Lewis, 2004).

Cutaneous myiasis in the absence of skin lesions has been reported in sheep and other farm animals and described as “fly strike” (Wall & Lovatt, 2015). This myiasis is caused by species of the family Calliphoridae and involves relevant economic losses in ovine farms in British Isles, southern Africa and Australia (Morris & Titchener, 1997). In cats and dogs, this type of cutaneous myiasis is unusual but it has occurred in Case 2 reported in this study, involving a dog that became immobile, but that had no primary skin lesions. Besides immobility, a possible predisposing factor was the release of odours able to attract the females of *L. sericata*.

Myiasis occurring in intact skin has been reported in a debilitated kitten with skin desquamation possibly attracting fly ovideposition (Madeira et al., 1989) and in neglected dogs (Choe et al., 2016; Muñoz-García et al., 2016) or with matted hair (Han et al., 2018). A case of myiasis by *Lucilia eximia* (Wiedemann) (Diptera: Calliphoridae), apparently without any predisposing conditions, was reported in a dog in Brazil (Azeredo-Espin & Madeira, 1996).

Generally, approaches to prevent cutaneous myiasis (e.g. removing predisposing conditions and avoiding exposure) are the best way to minimize fly colonization. The use of repellents containing N,N-diethyl-meta-toluamide (DEET) may also help. Therapeutic procedures usually involve mechanical removal of larvae by tweezers and rinsing with antiseptic drugs (povidone-iodine). When required, surgical exploration to remove larvae or necrotic tissues, followed by wound suturing, should be performed. Topical and/or systemic antibiotic administration to prevent secondary infection may be necessary (Francesconi & Lupi, 2012; Hall et al., 2016; Robbins & Khachemoune, 2010).

4 | CONCLUSIONS

Two cases of myiasis in northern Italy, respectively, occurring in a cat and in a dog, were described in this study. The case described in a cat was the first one ever reported in Italy of cutaneous myiasis by *C. vicina* in cats. The case described in a dog and caused by *L. sericata* was also unusual because there were no apparent skin lesions associated with the myiasis.

These cases and others derived from an extensive literature search for cases of myiasis in these domestic species allow predisposing conditions and risk factors to be highlighted. These data may be useful for veterinarians but also suitable to alert owners and caretakers about problems that may occur when the domestic animals

become immobile or in situations that attract dipteran female flies, such as lack of hygiene, care by the owners, protection from fly contact and proper veterinarian care.

ACKNOWLEDGMENTS

The authors wish to thank Paola Ancarani for valuable technical assistance.

CONFLICT OF INTEREST

The authors declare that they have no conflict of interest.

AUTHOR CONTRIBUTION

Marco PEZZI: Conceptualization; Data curation; Investigation; Methodology; Supervision; Writing-original draft; Writing-review & editing. **Chiara Scapoli:** Supervision; Writing-original draft; Writing-review & editing. **Milvia Chicca:** Supervision; Validation; Writing-original draft; Writing-review & editing. **Marilena Leis:** Funding acquisition; Writing-original draft; Writing-review & editing. **Maria Gabriella Marchetti:** Supervision; Writing-original draft; Writing-review & editing. **Carlo Nicola Francesco Del Zingaro:** Investigation; Methodology; Writing-original draft. **Chiara Beatrice Vicentini:** Investigation; Writing-original draft. **Elisabetta Mamolini:** Supervision; Writing-original draft. **Annunziata Giangaspero:** Investigation; Supervision; Writing-original draft; Writing-review & editing. **Teresa Bonacci:** Investigation; Supervision; Writing-original draft; Writing-review & editing.

ORCID

Marco Pezzi  <https://orcid.org/0000-0003-2817-7185>

REFERENCES

- Azeredo-Espin, A. M., & Madeira, N. G. (1996). Primary myiasis in dog caused by *Phaenicia eximia* (Diptera: Calliphoridae) and preliminary mitochondrial DNA analysis of the species in Brazil. *Journal of Medical Entomology*, 33, 839–843. <https://doi.org/10.1093/jmedent/33.5.839>
- Bonacci, T., & Brandmayr, P. (2016). *Primi dati sui ditteri che causano miasi canine in Calabria*. Proceedings of the 25th National Italian Congress of Entomology. June 20 to 24, Padua, Italy. p. 315
- Bonacci, T., Curia, G., Leoncini, R., & Whitmore, D. (2017). Traumatic myiasis in farmed animals caused by *Wohlfahrtia magnifica* in southern Italy (Diptera: Sarcophagidae). *Fragmenta Entomologica*, 49, 57–60. <https://doi.org/10.4081/fe.2017.230>
- Bonacci, T., Greco, S., Whitmore, D. & Curcio, U. (2013). First data on myiasis caused by *Wohlfahrtia magnifica* (Schiner, 1862) (Insecta: Diptera: Sarcophagidae) in Calabria, southern Italy. *Life: the Excitement of Biology*, 1, 197–201. [https://doi.org/10.9784/LEB1\(4\)Bonacci.02](https://doi.org/10.9784/LEB1(4)Bonacci.02)
- Cansi, E. R., & Demo, C. (2011). Ocorrência de miasas em animais de companhia no Distrito Federal, Brasil. *Acta Scientiae Veterinariae*, 39, 1–5.
- Carnevali, F., Franchini, D., Otranto, D., Giangaspero, A., Di Bello, A., Ciccarelli, S., Szpila, K., Valastro, C., & van der Esch, A. S. (2019). A formulation of neem and hypericum oily extract for the treatment of the wound myiasis by *Wohlfahrtia magnifica* in domestic animals. *Parasitology Research*, 118, 2361–2367. <https://doi.org/10.1007/s00436-019-06375-x>
- Chemonges-Nielsen, S. (2003). *Chrysomya bezziana* in pet dogs in Hong Kong: A potential threat to Australia. *Australian Veterinary Journal*, 81, 202–205. <https://doi.org/10.1111/j.1751-0813.2003.tb11471.x>

- Choe, S., Lee, D., Park, H., Jeon, H. K., Kim, H., Kang, J. H., Jee, C. H., & Eom, K. S. (2016). Canine wound myiasis caused by *Lucilia sericata* (Diptera: Calliphoridae) in Korea. *Korean Journal of Parasitology*, 54, 667–671. <https://doi.org/10.3347/kjp.2016.54.5.667>
- Choi, J., Kim, H., Na, J., Kim, S. H., & Park, C. (2015). Cutaneous myiasis associated with tick infestations in a dog. *Journal of Veterinary Clinics*, 32, 473–475. <https://doi.org/10.17555/jvc.2015.10.32.5.473>
- Cramer-Ribeiro, B. C., Sanavria, A., Monteiro, H. H. M. S., de Oliveira, M. Q., & de Souza, F. S. (2003). Inquiry of cases of myiasis by *Dermatobia hominis* in dogs (*Canis familiaris*) of the Northern and Western zone of Rio de Janeiro city in 2000. *Brazilian Journal of Veterinary Research and Animal Science*, 40, 21–28.
- de Souza, C. P., Verocai, G. G., & Ramadina, R. H. (2010). Myiasis caused by the New World screwworm fly *Cochliomyia hominivorax* (Diptera: Calliphoridae) in cats from Brazil: Report of five cases. *Journal of Feline Medicine and Surgery*, 12, 166–168. <https://doi.org/10.1016/j.jfms.2009.08.003>
- Dik, B., İlhan, C., Ceylan, O., & Uzunlu, E. O. (2018). The first case of traumatic myiasis caused by *Musca domestica* in a dog in Konya, Turkey. *Turkish Journal of Veterinary and Animal Sciences*, 42, 1–4. <https://doi.org/10.3906/vet-1803-65>
- Dik, B., Uslu, U., & İşik, N. (2012). Myiasis in animals and human beings in Turkey. *Kafkas Üniversitesi Veteriner Fakültesi Dergisi*, 18, 37–42. <https://doi.org/10.9775/kvfd.2011.4654>
- Eren, H., Aypak, S., Ural, K., & Seven, F. (2010). Traumatic myiasis in a dog and ocular myiasis in a cat cases due to *Lucilia sericata* (Diptera: Calliphoridae) larvae. *Kafkas Üniversitesi Veteriner Fakültesi Dergisi*, 16, 883–886. <https://doi.org/10.9775/kvfd.2010.1844>
- Farkas, R., Hall, M. J., Bouzagou, A. K., Lhor, Y., & Khallaayoune, K. (2009). Traumatic myiasis in dogs caused by *Wohlfahrtia magnifica* and its importance in the epidemiology of wohlfahrtiosis of livestock. *Medical and Veterinary Entomology*, 23(Suppl 1), 80–85.
- Fois, F., Mereu, P. P., Cappai, S., Vanin, S., Maistrello, L., Deiana, A. M., Cabras, P. A., & Liciardi, M. (2012). Myiasis by *Wohlfahrtia magnifica* (Diptera: Sarcophagidae) in different mammals in Sardinia. Proceedings of the 27th National Congress of Italian Society of Parasitology. June 26 to 29; Alghero, Italy. p. 107.
- Francesconi, F., & Lupi, O. (2012). Myiasis. *Clinical Microbiology Reviews*, 25, 79–105. <https://doi.org/10.1128/CMR.00010-11>
- Gatt, P., & Zammit, T. (2008). First record of *Oestrus ovis* Linnaeus, 1758 from Malta, and case reports of myiasis from the Maltese Islands (Diptera: Brachycera). *Bulletin of the Entomological Society of Malta*, 1, 5–10.
- Gökpınar, S., & Karsli, B. (2018). Traumatic myiasis associated with *Wohlfahrtia magnifica* and *Lucilia sericata* larvae in dog. *Van Veterinary Journal*, 29, 55–57.
- Hall, M. J. R., & Farkas, R. (2000). Traumatic myiasis of humans and animals. In L. B. Papp, & B. Darvas (Eds.), *Contributions to a manual of Palaearctic Diptera, Volume 1. General and applied dipterology* (pp. 751–768). Science Herald.
- Hall, M. J. R., & Smith, K. G. C. (1993). Diptera causing myiasis in man. In R. P. Lane, & R. W. Crosskey (Eds.), *Medical insects and arachnids* (pp. 429–469). Chapman and Hall.
- Hall, M. J., Wall, R. L., & Stevens, J. R. (2016). Traumatic myiasis: A neglected disease in a changing world. *Annual Review of Entomology*, 61, 159–176. <https://doi.org/10.1146/annurev-ento-010715-023655>
- Han, H. S., Toh, P. Y., Yoong, H. B., Loh, H. M., Tan, L. L., & Ng, Y. Y. (2018). Canine and feline cutaneous screw-worm myiasis in Malaysia: Clinical aspects in 76 cases. *Veterinary Dermatology*, 29, 442–e148. <https://doi.org/10.1111/vde.12672>
- Hinaidy, H. K., & Frey, H. (1984). Weitere Fakultativmyiasis-Fälle bei Wirbeltieren in Österreich. *Wiener Tierärztliche Monatsschrift*, 71, 237–238.
- İşik, N., & Dik, B. (2015). Bir köpekte *Lucilia sericata* (Diptera: Calliphoridae)'dan kaynaklanan travmatik myiasis olgusu. *Eurasian Journal of Veterinary Sciences*, 31, 242–244.
- Johnson, S. A., Gakuya, D. W., Mbutia, P. G., Mande, J. D., Afakye, K., & Maingi, N. (2016). Myiasis in dogs in the Greater Accra region of Ghana. *Vector-Borne and Zoonotic Diseases*, 16, 54–57. <https://doi.org/10.1089/vbz.2015.1811>
- Madeira, N. G., Silveira, G. A. R., & Pavan, C. (1989). The occurrence of primary myiasis in cats caused by *Phaenicia eximia* (Diptera: Calliphoridae). *Memórias do Instituto Oswaldo Cruz*, 84, 341. <https://doi.org/10.1590/S0074-02761989000800060>
- McNae, J. C., & Lewis, S. J. (2004). Retrospective study of Old World screwworm fly (*Chrysomya bezziana*) myiasis in 59 dogs in Hong Kong over a one year period. *Australian Veterinary Journal*, 82, 211–214. <https://doi.org/10.1111/j.1751-0813.2004.tb12677.x>
- Mendes-de-Almeida, F., Labarthe, N., Guerrero, J., Landau-Remy, G., Rodrigues, D. P., Borja, G. E., & Pereira, M. J. (2007). *Cochliomyia hominivorax* myiasis in a colony of stray cats (*Felis catus* Linnaeus, 1758) in Rio de Janeiro, RJ. *Veterinary Parasitology*, 146, 376–378. <https://doi.org/10.1016/j.vetpar.2007.02.021>
- Morris, O. S., & Titchener, R. N. (1997). Blowfly species composition in sheep myiasis in Scotland. *Medical and Veterinary Entomology*, 11, 253–256. <https://doi.org/10.1111/j.1365-2915.1997.tb00403.x>
- Moshaverinia, A., & Kazemi Mehrjerdi, H. (2016). Canine myiasis and its causal agents in northeastern Iran. *Iranian Journal of Parasitology*, 11, 91–97.
- Muñoz-García, C. I., Lorenzo-Burgunder, D., Gumi-Castillo, G., Perelló-Undreiner, D. B., Zenteno-Nava, E., & Orozco-Gregorio, H. (2016). Canine myiasis by *Lucilia eximia* in North America. *Tropical Biomedicine*, 33, 494–499.
- Ogo, I. N., Mwansat, G. S., Jambalang, A., Ogo, M. F., Onovoh, E., Ogunsan, E. A., Dogo, G. I., Banyigyi, S., Odoya, E. M., Chukwu, O. O. C., Yako, A. B., & Inyama, P. U. (2005). Retrospective study on the prevalence of canine myiasis in Jos - South Local Government area of Plateau State, Nigeria. *Journal of Pest Disease and Vector Management*, 6, 385–390.
- Ogo, N. I., Onovoh, E., Ayodele, D. R., Ajayi, O. O., Chukwu, C. O., Sugun, M., & Okeke, I. O. (2009). Cutaneous canine myiasis in the Jos metropolis of Plateau State, Nigeria, associated with *Cordylobia anthropophaga*. *Veterinarski Arhiv*, 79, 293–299.
- Orfanou, D. C., Papadopoulou, E., Cripps, P. J., Athanasiou, L. V., & Fthenakis, G. C. (2011). Myiasis in a dog shelter in Greece: Epidemiological and clinical features and therapeutic considerations. *Veterinary Parasitology*, 181, 374–378. <https://doi.org/10.1016/j.vetpar.2011.04.006>
- Patton, W. S. (1920). Some notes on Indian Calliphorinae. part I *Chrysomya bezziana* Villeneuve, the common Indian Calliphorinae whose larvae cause cutaneous myiasis in man and animals. *Indian Journal of Medical Research*, 8, 17–29.
- Pekmezci, D., Pekmezci, G. Z., Açıci, M., Gökalp, G., & Tütüncü, M. (2014). A case of auricular, anal and umbilical myiasis caused by the larvae of *Phormia regina* (Meigen) (Diptera: Calliphoridae) in neonatal kittens. *Türkiye Parazitoloji Dergisi*, 38, 71–75. <https://doi.org/10.5152/tpd.2014.3275>
- Pezzi, M., Whitmore, D., Bonacci, T., Del Zingaro, C. N. F., Chicca, M., Lanfredi, M., & Leis, M. (2017). Facultative myiasis of domestic cats by *Sarcophaga argyrostoma* (Diptera: Sarcophagidae), *Calliphora vicina* and *Lucilia sericata* (Diptera: Calliphoridae) in northern Italy. *Parasitology Research*, 116, 2869–2872. <https://doi.org/10.1007/s00436-017-5582-z>
- Pezzi, M., Whitmore, D., Chicca, M., Lanfredi, M., & Leis, M. (2015). Traumatic myiasis caused by an association of *Sarcophaga tibialis* (Diptera: Sarcophagidae) and *Lucilia sericata* (Diptera: Calliphoridae) in a domestic cat in Italy. *Korean Journal of Parasitology*, 53, 471–475. <https://doi.org/10.3347/kjp.2015.53.4.471>
- Principato, M., & Cioffi, A. (1996). Notes on the incidence of the *Lucilia* genus (Diptera: Calliphoridae) in Umbria, Central Italy. A case of myiasis by *Lucilia ampullacea* (Villen 1922) in *Testudo graeca*. Proceedings

- of the 20th International Congress of Entomology. August 25 to 31, Florence, Italy. p. 769.
- Principato, M., Pepe, M., Arcelli, R., & Polidori, G. A. (1994). Myiasis in a dog in Umbria by *Sarcophaga haemorrhoidalis* (Fallen) (Diptera: Sarcophagidae): A fly infecting also man. *Parassitologia*, 36(Suppl. 1), 117.
- Rauchbach, K., & Hadani, A. (1972). Hauntmyiasis bei Gans und Hund durch die Goldfliegenart *Lucilia sericata* (Meigen 1826). *Deutsche Tierärztliche Wochenschrift*, 79, 365–366.
- Rawlins, S. C. (1985). Current trends in screwworm myiasis in the Caribbean region. *Veterinary Parasitology*, 18, 241–250. [https://doi.org/10.1016/0304-4017\(85\)90050-0](https://doi.org/10.1016/0304-4017(85)90050-0)
- Rawlins, S. C., Alexander, F. C., Moe, V., Caesar, E., Moll, K., & Applewhaite, L. (1983). Screwworm (Diptera: Calliphoridae) myiasis in the southern Caribbean, and proposals for its management. *Journal of Economic Entomology*, 76, 1106–1111. <https://doi.org/10.1093/jee/76.5.1106>
- Ribbeck, R., Schroder, E., & Schumann, H. (1979). *Lucilia-sericata*-Larven als Erreger von Wundmyiasis bei Hund und Katze. *Monatshefte Für Veterinärmedizin*, 34, 383–384.
- Robbins, K., & Khachemoune, A. (2010). Cutaneous myiasis: A review of the common types of myiasis. *International Journal of Dermatology*, 49, 1092–1098. <https://doi.org/10.1111/j.1365-4632.2010.04577.x>
- Rodríguez, J. M., & Pérez, M. (1996). Cutaneous myiasis in three obese cats. *Veterinary Quarterly*, 18, 102–103. <https://doi.org/10.1080/01652176.1996.9694627>
- Rutland, B. E., Byl, K. M., Hydeskov, H. B., Minitier, B., & Johnson, C. A. (2017). Systemic manifestations of *Cuterebra* infection in dogs and cats: 42 cases (2000–2014). *Journal of the American Veterinary Medical Association*, 12, 1432–1438. <https://doi.org/10.2460/javma.251.12.1432>
- Schnur, H. J., Zivotofsky, D., & Wilamowski, A. (2009). Myiasis in domestic animals in Israel. *Veterinary Parasitology*, 161, 352–355. <https://doi.org/10.1016/j.vetpar.2009.01.026>
- Scholl, P. J., Catts, E. P., & Mullen, G. R. (2009). Myiasis (Muscoidea, Oestroidea). In G. Mullen, & L. Durden (Eds.), *Medical and veterinary entomology*, 2nd ed. (pp. 309–338). Academic Press, Elsevier.
- Sevgili, M., Altaş, M. G., & Gökçen, A. (2009). Bir köpekte oral myiasis olgusu. *Türkiye Parazitoloji Dergisi*, 33, 92–94.
- Singh, A., & Singh, Z. (2015). Incidence of myiasis among humans - a review. *Parasitology Research*, 114, 3183–3199. <https://doi.org/10.1007/s00436-015-4620-y>
- Singh, D., & Singh, A. (2007). A study on the incidence of myiasis among pet dogs in the state of Punjab. *Journal of Punjab Academy of Sciences*, 4, 99–102.
- Supperer, R., & Hinaidy, H. K. (1975). Myiasis bei Mensch und Tier in Österreich. *Wiener Tierärztliche Monatsschrift*, 62, 255–258.
- Szpila, K. (2012). Key for identification of European and Mediterranean blowflies (Diptera, Calliphoridae) of medical and veterinary importance - adult flies. In D. Gennard (Ed.), *Forensic Entomology, an introduction*, 2nd ed. (pp. 77–81). Wiley-Blackwell.
- Tannahill, F. H., Coppedge, J. R., & Snow, J. W. (1980). Screwworm (Diptera: Calliphoridae) myiasis on Curaçao: Reinvasion after 20 years. *Journal of Medical Entomology*, 17, 265–267. <https://doi.org/10.1093/jmedent/17.3.265>
- Verocai, G. G., Fernandes, J. I., Correia, T. R., de Souza, C. P., Melo, R. M. P. S., & Scott, F. B. (2010). Furuncular myiasis caused by the human bot-fly *Dermatobia hominis* in a domestic cat from Brazil. *Journal of Feline Medicine and Surgery*, 12, 491–493. <https://doi.org/10.1016/j.jfms.2009.12.019>
- Vignau, M. L., & Arias, D. O. (1997). Myiasis cutáneo-ulcerosas en pequeños animales. *Parasitología Al Día*, 21, 36–39.
- Wall, R., & Lovatt, F. (2015). Blowfly strike: Biology, epidemiology and control. *In Practice*, 37, 181–188. <https://doi.org/10.1136/inp.h1434>
- Wendell Snow, J., Coppedge, J. R., Baumhover, A. H., & Gorsira, R. (1978). The screwworm *Cochliomyia hominivorax* (Diptera: Calliphoridae) reinfests the island of Curaçao, Netherlands Antilles. *Journal of Medical Entomology*, 14, 592–593. <https://doi.org/10.1093/jmedent/14.5.592>
- Zumpt, F. (1965). *Myiasis in man and animals in the world*. Butterworth & Co.

How to cite this article: Pezzi M, Scapoli C, Chicca M, et al. Cutaneous myiasis in cats and dogs: Cases, predisposing conditions and risk factors. *Vet. Med. Sci.* 2021;7:378–384. <https://doi.org/10.1002/vms3.370>