

# Ureteral injury during abdominal and pelvic surgery: immediate versus deferred repair

Alfredo Aguilera, Juan Gomez Rivas, Luis M. Quintana Franco, Jose Quesada-Olarte, Diego M. Carrion, Luis Martinez-Piñeiro

Department of Urology, La Paz University Hospital, Madrid, Spain

**Citation:** Aguilera A, Gomez Rivas J, Quintana LM, Quesada-Olarte J, Carrion DM, Martínez-Piñeiro L. Ureteral injury during abdominal and pelvic surgery: immediate versus deferred repair. Cent European J Urol. 2019; 72: 312-318.

## Article history

Submitted: Sept. 5, 2018

Accepted: Aug. 9, 2019

Published online: Aug. 20, 2019

## Corresponding author

Luis M. Quintana Franco  
Hospital Universitario  
La Paz  
Department of Urology  
261 Paseo de la Castellana  
28046 Madrid, Spain  
phone: +34 606 620 986  
luismi.quintanafranco@gmail.com

**Introduction** The incidence of ureteral damage during abdominal surgery is <1%. Repair of these lesions can be performed immediately when the injury is detected or deferred when it has been missed.

**Material and methods** We retrospectively reviewed ureteral injuries that required surgical repair and were made during gynaecological and general surgery procedures between the years 2004 and 2016. We compared the clinical and functional outcomes between immediate and deferred repair.

**Results** We registered 84 lesions after 4000 abdominal procedures (2.1%). A total of 20 injuries were noted during general surgery interventions (24%) and 64 during gynaecological procedures (76%). The approach was laparoscopic in 66 of these cases and open in the other 18. Mean time of follow-up was 24 months. Immediate repair was accomplished in 35 cases (41%) and deferred in 49 (59%), with a median time to repair of 5.7 months. The laparoscopic approach was more frequent in deferred repairs (76% vs. 16%), while the open approach was more common in immediate repairs (54% vs. 40%).

Procedures used for ureteral repair included 62 ureteral reimplantations using a psoas hitch technique, 8 end-to-end ureteral anastomoses, 6 ureterorrhaphies and 6 ureteral catheterisations. Two nephrectomies were also performed. Success rates and complications were similar for both immediate and deferred procedures (68% vs. 73% and 26% vs. 23% respectively, both  $p > 0.05$ ).

**Conclusions** The occurrence of ureteral injury during abdominal surgery is low. Immediate repair is preferred when feasible, but delayed recognition of the injury is more common. We found no difference between immediate and deferred repair in terms of success rates.

**Key Words:** abdominal surgery ◊ pelvic surgery ◊ repair ◊ ureteral injury

## INTRODUCTION

Iatrogenic injury to the urogenital tract, although rare, is an important subject for any urologist. Appropriate investigation and treatment of suspected trauma, whether in the acute or delayed setting, is critical to reduce the potential impact of later complications. Ureteral injuries are possible complications during abdominal and pelvic interventions. The overall incidence of ureteral injury varies between 0.5% and 10% [1]. Gynecological procedures are the main cause of these kinds of lesions; yet the injury rate is less than 1% [2]. Among gynecological

procedures, hysterectomy and surgery involving pelvic tumours are the most frequent cause of ureteral injuries, followed by deep endometriosis and caesarean section. Colorectal (especially abdominoperineal resection and sigmoid colectomy) and urologic operations (especially endoscopic interventions) are also causes of ureteral injuries. In ureteroscopic procedures, most lesions are minor but may sometimes be serious (e.g. complete ureteral avulsion) [3]. Iatrogenic ureteral lesions can result from various mechanisms: ligation or kinking while suturing, crushing from a clamp, partial or complete transection, thermal injury, or ischaemia from devascularisation.

Occult ureteric injuries occur more often than are reported and not all of them are diagnosed intraoperatively [3].

Management of these injuries depends on many factors including their nature and location and in some cases ureteral repair is needed. The aim of urologic reconstructive procedures is to excise an obstructing segment. Such segments are usually from scar tissue from trauma or iatrogenic causes. Following excision of an obstructed segment (or scar tissue), mobilization of the two ends of reconstructive areas is done; this is followed by performing a tension-free anastomosis. If there is any tension, recurrence of this stricture or anastomotic disruption may occur. Thus, tension-free anastomosis is critical [4].

There is no significant difference between the open and laparoscopic approach for ureteral lesions, although fewer injuries to the ureter are recognized immediately with the laparoscopic approach. In case of recognition of the ureteral lesion during surgery, immediate repair should be performed. This can save the patient further complications and surgical procedures. When these injuries go unnoticed, early or delayed postoperative complications may arise (ileus, fever, high drainage discharge, flank pain, oliguria/anuria, vaginal leaking in case of fistula, renal atrophy). In these cases, upper urinary tract drainage and deferred repair are proposed due to the ongoing inflammatory reaction and risk of surgical failure [5, 6].

The aim of this study was to review our 12-year experience in ureteral injury repair, comparing clinical and functional outcomes between immediate and deferred interventions.

## MATERIAL AND METHODS

We retrospectively reviewed the ureteral injury lesions which occurred during gynaecological and general surgery procedures in our centre between the years 2004 and 2016. This study received ethical committee approval from our institution. Preoperative data collected from patient's charts was: age, gender, body mass index (BMI), previous abdominal interventions, previous radiotherapy and condition that lead to surgery and surgical approach (open vs. laparoscopic).

We clustered ureteral injuries into two groups depending on the time of recognition of the lesion (immediate/intraoperative vs. delayed). We defined immediate repair when the injury was noticed and corrected within the first 72 hours after surgery and delayed when managed afterwards. For the delayed group, clinical manifestations that led to ureteral injury recognition were also recorded. Location of the

lesion (above or below the iliac vessels) and surgical technique applied to repair the injury (including the need of nephrectomy) was collected for each group.

## Injury management

Diverse reparation techniques can be applied to restore the damaged ureter. Immediate diagnosis of a ligation injury can be managed by de-ligation and stent placement. Partial injuries can be repaired immediately with a stent or urinary diversion by a nephrostomy tube. The surgical approach for an immediate repair relied on the initial approach of the main surgery. In laparoscopic procedures, the injury management was also laparoscopic, and open repair was used in open procedures.

Injuries diagnosed later are usually treated initially by a nephrostomy tube with or without stenting. Retrograde stenting is often unsuccessful in this setting. The surgical approach in these cases was laparoscopic when feasible. Open surgery was reserved to those cases where a difficult laparoscopic approach was foreseen (i.e. multiple abdominal surgeries, radiotherapy). To be noted, laparoscopy was not completely established in our department at the beginning of this study, so a few initial cases were directly managed by open surgery too. Deferred surgical repair is often necessary based on the location and the degree of injury. The most common methods of ureteral reconstruction include ureteroureterostomy and ureteroneocystostomy. For distal ureteral lesions (most common) we performed a ureteral reimplantation using the Lich-Gregoire technique. A psoas-hitch was also performed when needed to achieve a tension-free anastomosis. In general, ureteral stents inserted during these procedures were withdrawn after 4–6 weeks.

## Follow-up

Intravenous urography (IVU) or computerized tomography (CT)-urogram were routinely performed one month after the ureteral reparation to confirm that there was no anastomotic leak. Technetium 99m (Tc99m) and MAG-3 renogram were also performed after reparation to determine renal functional uptake ratio and excretion. Blood tests including serum creatinine were performed at 3 and 9 months, 1 year and 2 years after surgery.

Outcomes and success rates for both groups were determined by the following parameters: blood tests such as creatinine and glomerular filtration rate (GFR), renal loss function or atrophy in renogram studies (we recognized renal atrophy when renal functional uptake ratio was lower than 20%); vesico-

**Table 1.** Demographics and clinical manifestations

Age median (range)	49 (22–83)
Gender N (%)	
Male	15 (17)
Female	69 (83)
Surgical Dept. N (%)	
General surgery	20 (23)
Gynaecology	64 (77)
Condition N (%)	
Benign	44 (53)
Malignant	40 (47)
Radiotherapy N (%)	13 (15)
Abdominal surgery N (%)	25 (29)
Laparoscopic	66 (78)
Open	18 (22)
Lesion location N (%)	
Suprailiac	10 (12)
Infrailiac	74 (88)
Clinical manifestations N (%)	
Flank pain	26 (53)
Vaginal leaking	17 (35)
Fever	4 (8)
Renal failure	1 (2)
Anuria	1 (2)

ureteral reflux (VUR) grade 2 or higher demonstrated by voiding cystourethrogram (VCUG), and ureteral stenosis shown by IVU or CT-urogram. Median follow-up time was 24 months (2–144).

### Statistical analysis

Data was analyzed with SPSS v.11.5. Statistical significance was considered when  $p < 0.05$ . Quantitative variables were described in terms of mean and standard deviation values. Qualitative variables were described in terms of absolute and percentage values. Association between qualitative values were analyzed with Chi-square test or Fisher's exact test. Association between quantitative variables was analyzed with ANOVA test or Student's t test when indicated.

## RESULTS

We registered 84 cases of ureteral injury in over 4000 surgical interventions (2.1%). Sixty-four of them (76%) occurred during gynecological procedures, while the other 20 cases (24%) during general surgery procedures. Patient's demographics are shown in Table 1.

The surgical approach related with the ureteral lesion was laparoscopy in 78% of the cases (66) and open surgery for the other 22% (18). The location of the lesion was more frequently below the ureteral crossing of the iliac artery (distal ureter) when compared to middle or proximal (88% vs. 12%). A total of 3 cases of bilateral lesions were reported (2 of them

**Table 2.** Characteristics of immediate versus deferred reparation

	Immediate N (%)	Deferred N (%)	p-value
Initial approach			
Open	11 (31)	7 (14)	<0.05
Laparoscopic	24 (69)	42 (86)	<0.05
Repair approach			
Laparoscopic	14 (40)	37 (76)	<0.05
Open	19 (54)	8 (16)	<0.05
Endoscopic	2 (6)	4 (8)	>0.05
Repair procedure			
Direct reimplantation	20 (57)	42 (86)	<0.05
Open	20	7	
Laparoscopic	–	35	
T–T anastomosis	7 (20)	1 (2)	<0.05
Open	7	1	
Laparoscopic	–	–	
Ureterorrhaphy	6 (17)	–	–
Open	6	–	
Laparoscopic	–	–	
Pigtail catheter	2 (6)	4 (8)	>0.05
Nephrectomy	–	2 (4)	–
Open	–	–	
Laparoscopic	–	2	
Late complications	9 (26)	11 (23)	>0.05
Renal atrophy	4 (11)	5 (11)	
Vesicoureteral reflux	1 (2)	2 (4)	
Ureterohydronephrosis	4 (11)	4 (8)	
No complications	24 (68)	36 (73)	>0.05
Exitus	2 (6)	2 (4)	>0.05

during laparoscopic hysterectomy and the other one during open hysterectomy).

Ureteral lesions were misdiagnosed in 49 of the patients (59%), 42 of them after laparoscopy and 7 during open surgery. The main clinical manifestation was flank pain and hydronephrosis documented by renal ultrasound. Other clinical manifestations are listed in Table 1.

Imaging techniques used to confirm the diagnosis and study the ureteral lesion were CT urogram, IVU and/or antegrade pyelography if a percutaneous nephrostomy was placed. Vesico-vaginal fistula was recognised in 17 cases (20%).

Delayed ureteral reparation was accomplished after ureteral catheterization or percutaneous nephrostomy, in a mean time of 5.7 months (1–14). Intraoperative ureteral reparation was performed in 35 cases (41%).

Data referring to the elective surgical approach for the ureteral injury repair and the type of surgery performed, are shown in Table 2. To be noted, open surgery was the elective approach for immediate reparation (19 vs. 8;  $p < 0.05$ ), in contrast to delayed procedures, where a laparoscopic approach was preferred (37 vs. 14;  $p < 0.05$ ). Also, ureteral reimplantation was the most performed procedure in deferred repair, while direct anastomosis was the most frequent choice for immediate repair. Two cases ended in nephrectomy (one case of pyelonephritis with multifocal abscesses after percutaneous nephrostomy, the other after chronic pyelonephritis and renal atrophy).

As for late complications regarding the ureteral lesion, we found no statistical significance between immediate and delayed reparation. Most frequent late complications were renal atrophy and ureterohydronephrosis in both groups, followed by vesicoureteral reflux. Two patients passed away in each group, all of them because of their previous medical condition. Complete data are recorded in Table 2.

Success rate was achieved in over 70% of cases, expressed in terms of clinical improvement, measured by patient satisfaction in the first outpatient clinic visit and improvement in excretion of contrast by the affected kidney in intravenous urography (IVU) done at 6 months and resolution of obstructive pattern in the affected kidney renogram at 6 months, defined as urine excretion improvement with diuretics (furosemide).

## DISCUSSION

In this study, we present a large series on ureteral injury lesions. The ureteral lesion rate during abdominal surgery is very low (2.1%). Immediate ureteral reparation was more frequent in cases of open than laparoscopic surgeries (open: 11 vs. 7; laparoscopic: 24 vs. 42;  $p < 0.05$  respectively). For the same reason, the open approach was also significantly higher in immediate reparations and the laparoscopic approach for deferred cases. Success rates were similar for both open and laparoscopic approaches (68 vs. 73,  $p < 0.05$ ). Also, no significant differences were seen between the open and laparoscopic approach in terms of late complications.

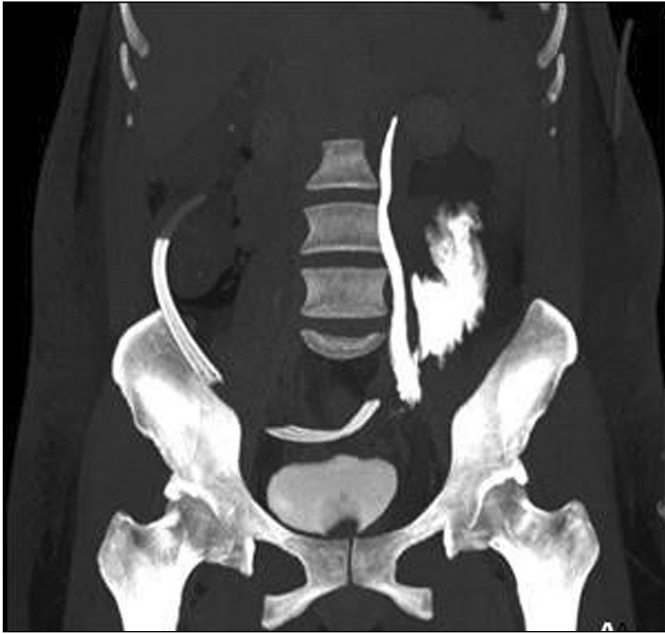Immediate ureteral lesion repair requires the intraoperative diagnosis of the injury, which in many cases does not occur, especially during laparoscopic procedures. Vakili et al. [7] present a series of cases with a recognition rate of intraoperative ureteral lesions between 6.7–12.5% and up to 35% when vesical lesions occurred. In our series, most cases (59%) were diagnosed during the immediate postopera-

tive phase. Patel et al. [8] made a systematic review of the literature on this topic, and concluded that routine intraoperative cystoscopy improves the lesion detection rate for both ureteral and vesical lesions. We do not perform systematic cystoscopy to our patients for various reasons. First, a high percentage of lesions (ischemic lesions, partial ureteral obstructions) will have a late onset and still will not be detected with this measure. Moreover, even if intraoperative cystoscopy indeed improves the injury detection rate, we do not believe this measure is applicable on a daily basis, because of the high volume of interventions. It could be useful in complex cases and/or those where the suspicion of ureteral lesion is high [3].

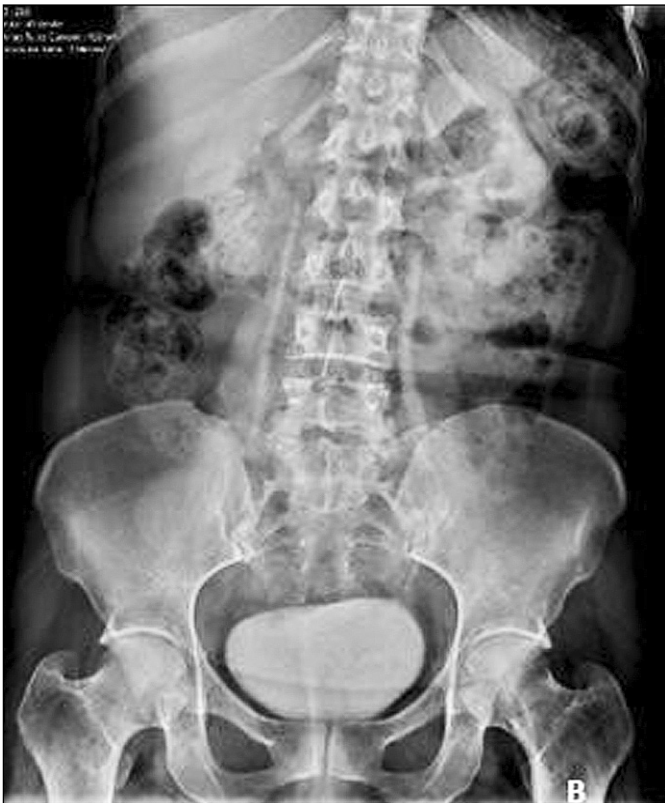Laparoscopic procedures are settling as the gold standard approach for a steadily growing number of procedures, due to the upward tendency for minimally invasive techniques. A study from Moen et al [9] showed a reduction in the number of open hysterectomies from 77% to 35.2% in favour of laparoscopic hysterectomies between the years 1989 and 2009. The laparoscopic approach clearly has a higher rate of ureteral injury lesions in our series (78% vs. 22%). This could be explained by two overlapping reasons: the extension of the laparoscopic technique throughout the different fields of surgery and the growing laparoscopic training process that comes with it. Our research started in 2004, coinciding with the implementation of the laparoscopic technique in both gynaecology and general surgery in our centre. In addition to this fact, our institution is a nationwide reference centre in the field of deep pelvic endometriosis, with many complex cases that lead to a higher number of ureteral lesions (Figures 1A-C).

We do not believe that the laparoscopic approach has a higher rate of ureteral lesions than the open approach if the surgeon has enough laparoscopic experience. However, it is likely that the laparoscopic approach has a lower rate of intraoperative injury detection, due to the reduced operative field. In our series, from the 18 cases of ureteral injury during open surgery, 11 of them (61%) were immediately diagnosed, while only 36% of the ureteral injuries (24 of 66 cases) were recognised intraoperatively. This is the reason why deferred ureteral reparation is more frequent.

In our series, the laparoscopic approach was preferred for deferred ureteral reconstruction (76% of the cases), in comparison to 40% when reparation is immediate. It is true that the surgical approach in immediate ureteral reconstruction cases is subject to the one decided for the original surgery and to the laparoscopic experience of the urological team attending the emergency. Our mean time to reparation

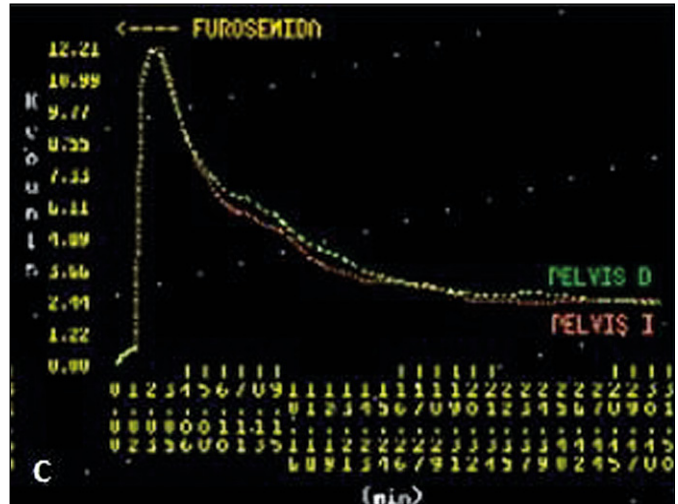


**Figure 1A.** CT-urogram of a left ureteral injury lesion after a hysterectomy procedure.



**Figure 1B.** Urography performed after ureteral reimplantation.

was 5.7 months (1–14). This wide range of time to reparation is due to a patient with a delayed ureteral reimplantation due to a misdiagnosed ureteral lesion



**Figure 1C.** MAG-3 renogram performed after ureteral reimplantation, showing symmetrical excretory function of both kidneys.

after laparoscopic hysterectomy, who also had other concomitant complications.

For many urological procedures, laparoscopic access has been shown to be effective in reducing morbidity, postoperative length of hospital stay, time of return to working life, and improving the aesthetics of the scar, while not compromising the functional results of conventional open surgery. New advances in this area include the development of other techniques such as surgery through natural orifices (natural orifice transluminal endoscopic surgery [NOTES]) and through laparoendoscopic single port surgery (laparoscopic-endoscopic single site surgery [LESS]). NOTES, in its strictest sense, implies not using any abdominal port. The obvious disadvantage of this type of surgery involves the complete loss of triangulation, partial loss of visibility, insufficient traction and a serious conflict of space. Laparoscopic surgery using small ports is another step towards gaining better cosmetics results [9–13].

Neocystostomy with ureteral reimplantation is indicated in patients with distal ureteral obstruction secondary to stricture, fibrosis, radiation changes, iatrogenic causes, etc. The goal is to bypass the obstructed ureteral segment and reimplant the ureter into a separate site in the bladder. In all our patients, we adhered to the prescribed surgical principles for repair of ureteral transections. These involve adequate ureteral debridement and careful mobilization, a spatulated, tension-free, watertight anastomosis over a ureteral stent, and placement of a drain. However, the main concern with direct anastomosis is that the blood supply to the ureter could be compromised, resulting in stricture formation, ureteral

stenosis, or obstruction. Therefore, care must be taken not to skeletonize and disrupt the ureter's blood supply [4, 9–10, 14].

We observed that complication rates are similar for both immediate and delayed ureteral reparations (26% vs. 23%,  $p < 0.05$ ). A more profound analysis shows that the worst complication – considered to be renal atrophy and posterior nephrectomy – is more frequent among deferred reparations, because of the late recognition of the lesion. It must be taken into account that deferred reparations mean adding more surgeries and could generate psychological repercussions for the patient. On the other hand, in our series we performed 6 simple ureterorrhaphies in minor ureteral lesions, all of them intraoperatively. This could result in a statistical bias favouring the immediate reparation.

Success rates in our series are similar to those described in the literature. Wenske et al. [15] reported an 81% success rate – thus meaning hydronephrosis resolution – in 100 ureteral reimplantations. The majority of the cases were deferred reparations and the clinical diagnosis was a ureteral tumour. Literature reviews show a better result when reparation is performed within 3 weeks after the injury [2, 15]. In our experience, we believe this is not entirely certain. Reconstructive surgery within the first 3 weeks after the lesion can be very complex and add even more iatrogenic complications. The scarring process is still developing at the time and in many occasions urinoma, which can also become infected, is formed in the abdominal cavity. As for other consequences, it is also noted that patients who underwent hysterectomy and suffered a ureteral lesion were 70 times more prone to sue the surgeon [16].

Our study has several drawbacks: its retrospective nature, which provides a lack of randomization, a short cohort of patients, single centre analysis and loss to follow-up of some patients. Heterogeneity during follow-up regarding blood tests and imaging techniques is also another limitation. However, our

results reflect those described in the previous literature and show some interesting results regarding the different approaches for ureteral injury repair.

Efforts should be made in the prevention of iatrogenic ureteral lesions based on visual identification of the ureters and cautious intraoperative dissection. Prophylactic preoperative ureteric stent insertion assists visualisation and palpation, and it is commonly used in complicated cases. However, it does not decrease the rate of injury. Apart from its evident disadvantages (potential complications and cost), a stent may alter the location of the ureter and diminish flexibility. Stenting is probably useful as secondary prevention by facilitating detection of the injury. Routine prophylactic stenting is usually not cost effective, and it is estimated to become cost effective in hysterectomy when the rate of lesions exceeds 3.2%; therefore, it is advocated only in selected patients with risk factors [3].

## CONCLUSIONS

The rate of occurrence of ureteral injury lesions in abdominal surgery is low. Immediate reparation is the best way to proceed if ureteral lesions are diagnosed during abdominopelvic surgery. Delayed recognition of these lesions might lead to a deferred ureteral reconstruction, which requires an initial derivative procedure (ureteral catheterisation or percutaneous nephrostomy) and posterior repairing of the lesion after at least 3 months. This implies greater morbidity, number of interventions and negative psychological repercussions for the patient. As for the surgical approach, both open and laparoscopic techniques have similar success and complication rates. Yet, we prefer laparoscopic repair in deferred lesions when feasible due to its aesthetic and fast recovery benefits.

## CONFLICTS OF INTEREST

The authors declare no conflicts of interest.

## References

- Al-Awadi K, Kehinde EO, Al-Hunayan A, Al-Khayat. Iatrogenic ureteric injuries: incidence, aetiological factors and the effect of early management on subsequent outcome. *Int Urol Nephrol.* 2005; 37: 235-241.
- Gopinath D, Jha S. Urological complications following gynaecological surgery. *Obstet Gynaecol Reprod Med.* 2016; 26: 291-296.
- Summerton DJ, Kitrey ND, Lumen N, Serafetinidis E, Nenad Djakovic. EAU Guidelines on Iatrogenic Trauma. *Eur Urol.* 2012; 62: 628-639.
- Gomez Rivas J, Cisneros Ledo J. Principios de la cirugía reconstructiva del tracto urinario. *Arch Esp Urol.* 2017; 70: 379-384.
- Parpala-Sparman T, Paananen I, Santala M, Ohtonen P, Hellström P. Increasing numbers of ureteric injuries after the introduction of laparoscopic surgery. *Scand J Urol Nephrol.* 2008; 42: 422-427.
- Bañuelos B, Aguilera A, López D, Peña J. Lesiones genitourinarias en cirugía ginecológica y general. Una revisión de 3 años. *Rev Int Androl.* 2014; 13: 20-26.
- Vakili B, Chesson RR, Kyle BL, Shobeiri SA, Echols KT, Gist R et al. The incidence of urinary tract injury during hysterectomy: a prospective analysis based on universal cystoscopy. *Am J Obstet Gynecol.* 2005; 192: 1599-1604.

8. Patel H, Bhatia N. Universal cystoscopy for timely detection of urinary tract injuries during pelvic surgery. *Curr Opin Obstet Gynecol.* 2009; 21: 415-418.
9. Moen M, Noone M, Cholkeri-Singh A, Vassallo B, Locker B, Miller C. Progressive reduction in abdominal hysterectomy rates: impact of laparoscopy, robotics and surgeon factors. *J Robot Surg.* 2014; 8: 13-17.
10. De Cicco C, Schonman R, Craessaerts M, Van Cleynenbreugel B, Ussia A, Koninckx PR. Laparoscopic management of ureteral lesions in gynecology. *Fertil Steril.* 2009; 92: 1424-1427.
11. Seideman CA, Huckabay C, Smith KD, Permpongkosol S, Nadjafi-Semnani M, Lee BR, Richstone L, Kavoussi LR. Laparoscopic ureteral reimplantation: technique and outcomes. *J Urol.* 2009; 181: 1742-1746.
12. Han CM, Tan HH, Kay N, Wang CJ, Su H, Yen CF, Lee CL. Outcome of laparoscopic repair of ureteral injury: follow-up of twelve cases. *J Minim Invasive Gynecol.* 2012; 19: 68-75.
13. Núñez-Mora C, García-Mediero JM, Cabrera PM, Hernández E, García-Tello A, Angulo JC. Tratamiento de la estenosis de uréter distal mediante reimplantación urétero-vesical laparoscópica. *Actas Urológicas Españolas.* 2011; 35: 31-36.
14. Rassweiler JJ, Gözen AS, Erdogru T, Sugiono M, Teber D. Ureteral reimplantation for management of ureteral strictures: a retrospective comparison of laparoscopic and open techniques. *Eur Urol.* 2007; 51: 512-522.
15. Wenske S, Olsson CA, Benson M. Outcomes of distal ureteral reconstruction through reimplantation with psoas hitch, Boari flap, or ureteroneocystostomy for benign or malignant ureteral obstruction or injury. *Urology.* 2013; 82: 231-236.
16. Haestier A, Sherwin R. Urological complications following gynaecological surgery. *Obstet Gynaecol Reprod Med.* 2010; 21: 15-19. ■